

Degenerative Cervical Myelopathy: Natural History, Clinical Presentation, Current Diagnosis and Treatment Review

Fernando Luís Maeda¹, MD; Andrei Fernandes Joaquim², MD, PhD

1 Neurosurgery Resident. Department of Neurosurgery, University of Campinas (UNICAMP), Campinas, Brazil;

2 Professor of Neurosurgery. Department of Neurosurgery, University of Campinas (UNICAMP), Campinas, Brazil.

Conflict-of-interest statement: The author(s) declare(s) that there is no conflict of interest regarding the publication of this paper.

Open-Access: This article is an open-access article which was selected by an in-house editor and fully peer-reviewed by external reviewers. It is distributed in accordance with the Creative Commons Attribution Non Commercial (CC BY-NC 4.0) license, which permits others to distribute, remix, adapt, build upon this work non-commercially, and license their derivative works on different terms, provided the original work is properly cited and the use is non-commercial. See: <http://creativecommons.org/licenses/by-nc/4.0/>

Correspondence to: Fernando Luís Maeda, MD, Department of Neurosurgery, University of Campinas (UNICAMP), 126, Tessália Vieira de Camargo, Campinas, São Paulo, 13083-887, Brazil.
Email: fernandomaeda89@gmail.com
Telephone: +55-19986020004
Fax: +55-1935217483

Received: May 25, 2020

Revised: July 5, 2020

Accepted: July 10 2020

Published online: August 28, 2020

ABSTRACT

Degenerative cervical myelopathy is a chronic, nontraumatic compression and progressive disease of the cervical spinal cord. Osteoarthritic degeneration (spondylosis, facet hypertrophy, degenerative disc disease), ligament changes (ossification of the posterior longitudinal ligament, hypertrophy of the ligamentum flavum) and ischemia (secondary ischemic injury) may lead to spinal cord compression and result in neurological deficits. Clinically, the appendicular function is mainly affected, as well as gait and urinary function. Duration and degrees of compression are negatively correlated with prognosis. Non-operative treatment can be performed in mild symptomatic cases; however, surgical treatment may possibly improve the natural course of cervical myelopathy disease by

stopping progression or avoiding deterioration and, in some cases, restoring some neurological function.

Key words: Cervical Myelopathy; Degenerative Cervical Myelopathy; Degenerative Disc Disease; Cervical Spondylotic Myelopathy; Ossification of Posterior Longitudinal Ligament; Ossification of Ligamentum flavum; Anterior Cervical Discectomy and Fusion

© 2020 The Author(s). Published by ACT Publishing Group Ltd. All rights reserved.

Maeda FL, Joaquim AF. Degenerative Cervical Myelopathy: Natural History, Clinical Presentation, Current Diagnosis and Treatment Review. *International Journal of Orthopaedics* 2020; 7(4): 1313-1321 Available from: URL: <http://www.ghrnet.org/index.php/ijo/article/view/2909>

ABBREVIATIONS

ACDF: Anterior cervical discectomy and fusion
CSM: Cervical spondylotic myelopathy
CT: Computed tomography
DCM: Degenerative cervical myelopathy
DDD: Degenerative disc disease
DTI: Diffusion tensor imaging
JOA Score: Japanese Orthopaedic Association Score
LF: Ligamentum flavum
mJOA: score modified Japanese Orthopaedic Association Score
MRI: Magnetic resonance imaging
OLF: Ossification of ligamentum flavum
OPLL: Ossification of the posterior longitudinal ligament
PEEK: Polyetheretherketone
PLL: Posterior Longitudinal Ligament
QALY Scale: Quality Adjusted Life Year Scale
SCI: Spinal Cord Injury
VAS: Visual analog scale

INTRODUCTION

Degenerative Cervical Myelopathy (DCM) is a chronic, non-traumatic condition caused by disc, bone, and ligament changes in the cervical spine, which results in dynamic and static spinal cord narrowing and compression^[1].

DCM includes a combination of disc disease [e.g. degenerative

disc disease (DDD)], bone changes [e.g. cervical osteoarthritis (spondylosis), spondylolisthesis, spondylolysis] and ligament impairment [e.g. hypertrophy, calcification, ossification of the ligamentum flavum and calcification of the posterior longitudinal ligament (OPLL)]^[2,3] (Figure 1). All these anatomical changes contribute to the static and dynamic compression of the spinal cord. Flexion and extension movements can cause narrowing of the cervical canal through the “Pincer mechanism”^[4,5] (Figure 2).

DCM is the main cause of nontraumatic spinal cord compression worldwide. Usually, it affects patients during the fifth or the sixth decade of life^[6,7]. Patients can be asymptomatic or even present severe deficits, according to the compression degree and ischemic spinal cord injuries^[8]. Fortunately, the majority of the cases are asymptomatic or mildly symptomatic. Symptoms include tingling, numbness, weakness, gait impairment, neck pain, radiculopathy, loss of coordination, fine motor skills deteriorations, and difficult bladder control^[9,10]. Because of the mild cases, the incidence (4.1 / 100.000) and prevalence (60.5 / 100.000) seem to be underestimated^[6,11-13].

Clinically, it causes a slow and progressive neurological impairment, with a stepwise pattern of quiescent disease periods before deterioration. Naturally, 20 to 62% of patients with DCM will deteriorate neurologically within 3 to 6 months^[14]. Otherwise, acute presentation is not common, except when precipitated by trauma or acute disc herniation^[15].

Asymptomatic and mildly symptomatic patients with evidence of spinal cord compression must be closely monitored, clinically and radiologically, and surgery should not be done unless they become more symptomatic^[16,17]. Moderate and severe cases should be surgically treated^[16,18]. However, long-term compression, age, spinal cord atrophy, low signal on T1-weighted images, and high signal on T2-weighted on MRI are signs of poor outcome^[19-21].

PATHOPHYSIOLOGY

Classically, the CSM pathophysiology is explained by a mixture of mechanical dysfunction and genetic disorders. Static factors (e.g. spondylosis, disc degeneration, OPLL, ossification of the ligamentum flavum, congenital stenosis, etc.) contribute to narrow the spinal canal and may cause direct spinal cord compression^[10]. Dynamic dysfunctions (e.g. neck flexion and extension) contribute to additional narrowing of the spinal canal by the Pincer mechanism^[14,22]. Neck flexion could result in anterior spinal cord compression against cervical osteophytes, hypertrophy, or OPLL, while neck extension could result in posterior spinal cord compression against hypertrophy of the uncinate process or facet and ossification or hypertrophy of ligamentum flavum^[3,4,23]. Furthermore, additional stretching forces during flexion-extension movements could make the spinal cord more susceptible to physiological changes and secondary damage^[5,24].

However, these mechanisms are not enough to explain differences in clinical presentations in patients with similar degrees of compression. Secondary injuries (e.g. decreased spinal cord perfusion, venous congestion, and spinal cord ischemia) and endogenous responses (e.g. neuroinflammation and apoptosis) are a complementary mechanism to the pathophysiology of CSM. The additional molecular mechanism remains unclear^[25].

NATURAL HISTORY

Cervical Myelopathy (CM) most occurs in men (2.4:1) between the 5th and 6th decade of life^[12]. The most frequently involved level is C5-6^[26]. Historically, CM was described as a constellation of symptoms. At the onset, the patient may present clumsiness,

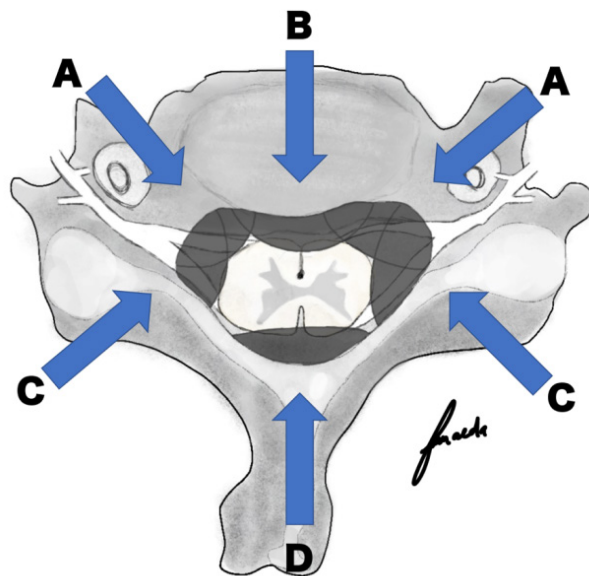


Figure 1 Cervical Spinal Cord normal anatomy and degenerative process. A: Uncinate process hypertrophy; B: Osteophyte, Hypertrophy of Posterior Longitudinal Ligament (PLL) or Ossification of PLL; C: Uncovertebral joint hypertrophy; D: Ossification or hypertrophy of ligamentum flavum.

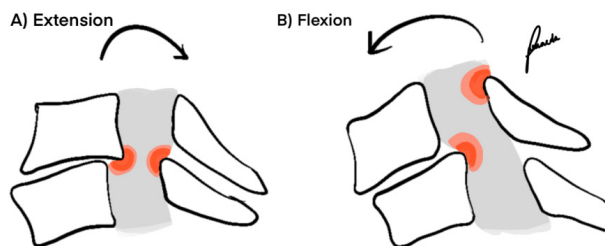


Figure 2 Pincer mechanism. Narrowing of the cervical spinal canal due to flexion and or extension movement.

Table 1 NURICK Clinical Scale^[31].

Grading	Description
0	Signs or symptoms of root involvement but without evidence of spinal cord disease
1	Signs of spinal cord disease but no difficulty in walking
2	Slight difficulty in walking which does not prevent full-time employment
3	Difficulty in walking which prevented full time employment or the ability to do all housework, but which was not so severe as to require someone else's help to walk
4	Able to walk only with someone else's help or with the aid of a frame.
5	Chairbound or bedridden.

gait impairment, weakness, daily activity compromises, neck pain, shoulder pain, and neurogenic bladder^[1,8]. Once clinical manifestations start, remission to normality usually does not occur. Motor changes persist and tend to progress over time.

Patients present mild symptoms at the initial phase, usually described as Nurick grade II 27 (Table 1)^[28]. Diagnosis and referral to a specialist are usually delayed and may result in later surgical treatment^[29]. Good access to health care providers, greater technical knowledge about CSM, and improvements in diagnostic methods facilitated the diagnosis^[30]. However, this reduction in time does not seem enough. In the 1950s, the delay in diagnosis from the first symptoms was 6.3 years, while recent studies show a delay of 2.2 years^[29,31]. Since symptoms start, remission to normality does not occur and motor changes usually persist and tend to progress. Deterioration may occur in three different patterns. Stepwise

progression is the most common form and occurs in 75% (Figure 3A). It means a sequence of stable and sudden worsening periods. In 20% of cases, occur slow and steady deterioration (Figure 3B) and only 5% of patients experience stability after an initial symptom 10 (Figure 3C).

Clinical treatment may be useful in the early stages and mild symptoms. Nevertheless, since symptoms get worse, especially in Nurick III, IV, and V, surgery should be considered^[16].

EVALUATION AND DIAGNOSIS

Symptomatic cervical spondylosis (CS) may present axial neck pain, radiculopathy, myelopathy, or a combination of these entities. The medical history and clinical evaluation should be considered in order to differentiate and exclude the differential diagnosis^[32], which should receive some special attention. Amyotrophic lateral sclerosis, multiple sclerosis, low hydrocephalus pressure, carpal tunnel, and radiculopathies can cause misdiagnosis^[33].

Myelopathy may present itself with weakness, clumsiness, gait impairment, neurogenic bladder. Axial cervical pain may result in muscular strain, regional myofascial pain, referred shoulder pain, while radiculopathy generates symptoms along with nerve roots^[34].

The unspecific symptoms delay the diagnosis in early myelopathic stages. Limb weakness and gait impairment tend to be undervalued. Evaluation by an expert and monitoring with assessment tools facilitate the follow-up of these patients and the decision for the best treatment. Nurick score and modified Japanese Orthopedic Association score (mJOA) are the most common, useful and standardized assessment tools for CSM evaluation. However, Cooper myelopathy scale (CMS), Prolo Scale (PS) and European Myelopathy Score (EMS) also have their relevance^[28,35-37].

The physical examination should include cervical range motion, evaluation of pyramidal signs (Hoffmann, Tromner, Babinski, ankle clonus), sensorial, tendon reflexes, gait and balance evaluation^[38-40]. Classical findings include limitations of cervical motion, spasticity, hyperreflexia, pyramidal signs, and abnormal gait^[41-43]. As a degenerative disease of the spinal cord, concomitant lumbar spinal stenosis may be present in 15 to 33 % of CSM patients^[44,45]. In these cases, lower limb hyporeflexia may be present as well.

Spurling maneuver composed by cervical extension, side bending, and axial compression may reproduce ipsilateral radicular pain, generally in the setting of an ipsilateral foraminal stenosis^[46]. In myelopathic patients, cervical flexion may trigger a sudden transient electric-like shock extending down the spine (Lhermitte's sign)^[47].

Evaluation of strength, sensitivity, and tendon reflexes contributes to the differentiation between cervical radiculopathy, peripheral nerve compression syndromes, and global deficits 48. Special signs contribute to cervical myelopathy diagnosis, including shoulder girdle muscular atrophy, fasciculations and myelopathic hand defined by failing in 10 seconds of grip and release test (10SGRT), 30-meter walking test (30MWT), 10 seconds step test (10SST), uncoordinated finger motion and Wartenberg's sign (finger escape sign)^[49-52].

The finger escape sign is involuntary abduction of the fifth finger caused by weakness in finger adduction in CSM evidenced by keeping the fingers extended and abducted for 30-60 seconds^[53]. The 10SGRT is used to assess impairment in the upper limbs and manual dexterity. This test is positive when the patient is unable to rapidly open and close the hand into a fist at least 20 times in 10 seconds^[54]. The 30 MWT and the 10SST are used in clinical practice and research to objectively measure gait impairment^[55,56].

In myelopathic patients, not only gait balance is impaired, but also the gait pattern. Instead of heel-to-toe walk, severe myelopathic

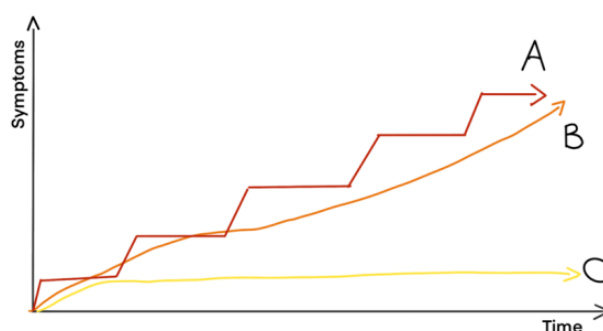


Figure 3 Three different patterns of clinical deterioration of CSM patients. A: Stepwise pattern; B: Slow and steady deterioration and C: stability after initial symptom.

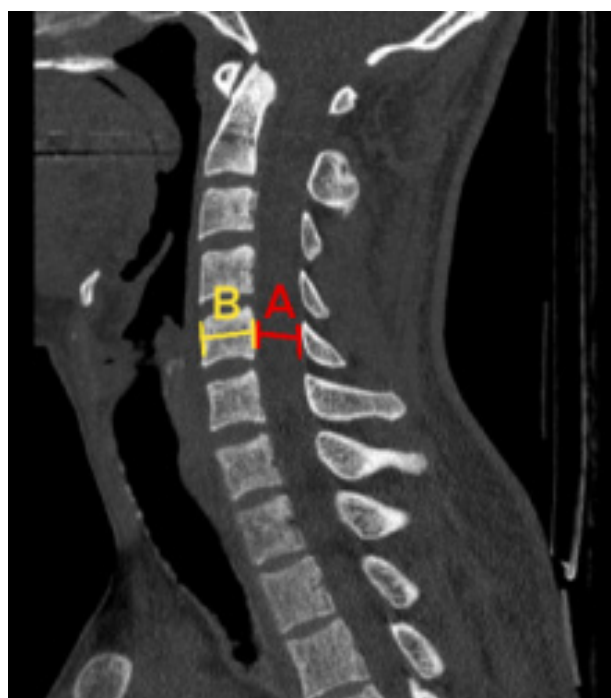


Figure 4 Cervical canal measure for stenosis evaluation. Torg-Pavlov ratio: canal / vertebral body width (A/B).

Table 2 Torg-Pavlov ratio (canal / vertebral body width).

Normal	> 1.2
Moderate	0.8 - 1.2
Severe	< 0.8
Poor Outcome	< 0.4

gait is characterized by limited propulsion due to weakness in the lower limb and compensation by the proximal hip musculature^[57,58]. It results in decreased knee flexion, limb hyperextension, decreased step speed and length and increased stance width in stance phase, and slower plantar flexion in the swing phase^[59].

Imaging methods are essential for diagnosis, outcome, surgical planning, and postoperative follow-up. Radiography, computed tomography (CT) and magnetic resonance image (MRI), have specific peculiarities and goals. All patients with a compatible clinical history and neurological abnormalities detected during the physical examination should be evaluated with a cervical spine MRI^[60]. Anteroposterior cervical X-ray may reveal a cervical rib or scoliosis, while the lateral view may reveal a reduced disc space, osteophytes, and sagittal alignment. Besides, dynamic examination with flexion and extension x-rays can provide important information

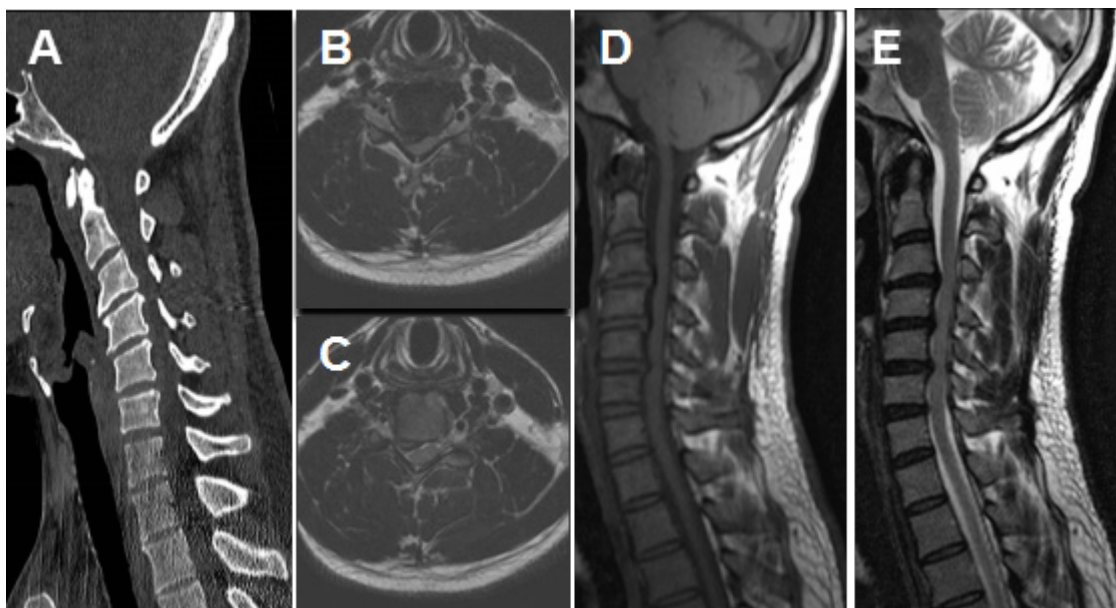


Figure 5 Pre-operative images. A: Sagittal CT of cervical spine showing C3/4, C4/5, C5/6 cervical stenosis and degenerative process. B and C: Axial MRI of cervical spine showing spinal cord compression mainly on antero-lateral portion. D: Sagittal T1 MRI showing C3/4, C4/5 and C5/6 anterior compression. E: Sagittal T2 MRI showing C3/4, C4/5 and C5/6 anterior compression.

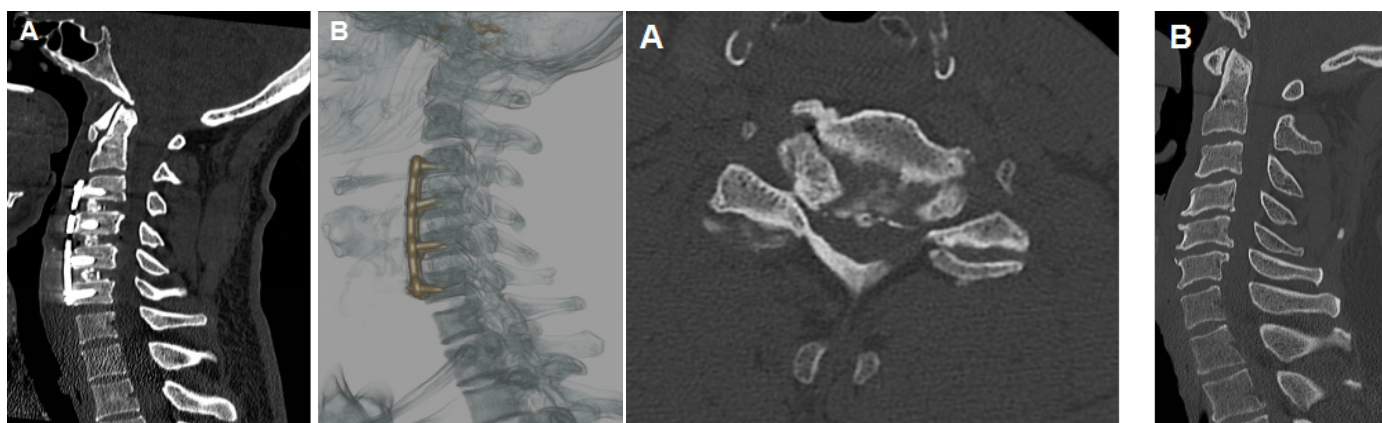


Figure 6 Post-operative images. A: Sagittal CT showing Anterior cervical discectomy and fusion C3/4, C4/5 and C5/6. B: Sagittal view of 3D-CT reconstruction of ACDF.

Figure 7 Pre-operative CT images. A: Axial view of cervical spine at most critical cervical stenosis level (C5/6). B: Sagittal view of cervical spine showing C4/5 and C5/6 cervical stenosis.

about segmental instability, usually adjacent to hypomobile segments^[61]. CT allows visualization of details of bone anatomy, evaluation of spondylosis, OPLL, ossification of the ligament flavum, bone compression and it is also useful for surgical instrumentation planning, and 3D reconstruction^[62]. However, it is limited to soft tissue analysis^[63]. MRI gives details of soft tissue anatomy, spinal cord compression, intervertebral disks, ligaments, microhemorrhage, syrinx, myelomalacia, intramedullary signal change, but it lacks information regarding bone anatomy^[64]. Of note, MRI is considered the gold standard exam for CSM diagnosis and to rule out differential diagnosis.

The normal diameter of the cervical spinal canal on the sagittal plane varies from 17 mm on C3 to 13 mm on the C7 level^[65]. Cervical canal stenosis can be measured in the midsagittal plane through the ratio between the spinal canal and the vertebral body diameter of the same level (Figure 4). Ratio < 0.8 represents severe cervical stenosis, while ratio < 0.4 is related to poor outcome (table 1)^[66-68]. In the axial plane, spondylosis causing narrowing greater than 30% or below 60 mm² is related to compression of long tracts and appearance of

symptoms^[69].

Meantime, isolated radiological findings without clinical symptoms do not confirm a diagnosis of cervical myelopathy. Degenerative changes are commonly found in asymptomatic patients and tend to become more prevalent with aging. In patients up to 50 years old, only 25-50% of the MRI show degenerative changes, while at a 65-year-old population almost 75-85% present degeneration and that is due to aging^[13,70]. Therefore, the diagnosis of CSM should always consider the medical history and physical examinations compatible with the clinical condition.

Electrophysiological tests usually provide additional information to clinical and neuroimaging findings^[34,71]. They are useful to localize spinal cord lesions or radiculopathy syndromes in pre-operative evaluation. They are also useful for post-operative evaluation and follow-up. Somatosensory Evoked Potential (SSEP) and Motor Evoked Potential (MEP) are helpful to evaluate the integrity of the spinal cord tracts, while Electromyography (EMG) and Nerve Conduction Study (NCS) are sensitive tests used to differentiate peripheral nerve disorders that can mimic CSM^[72].

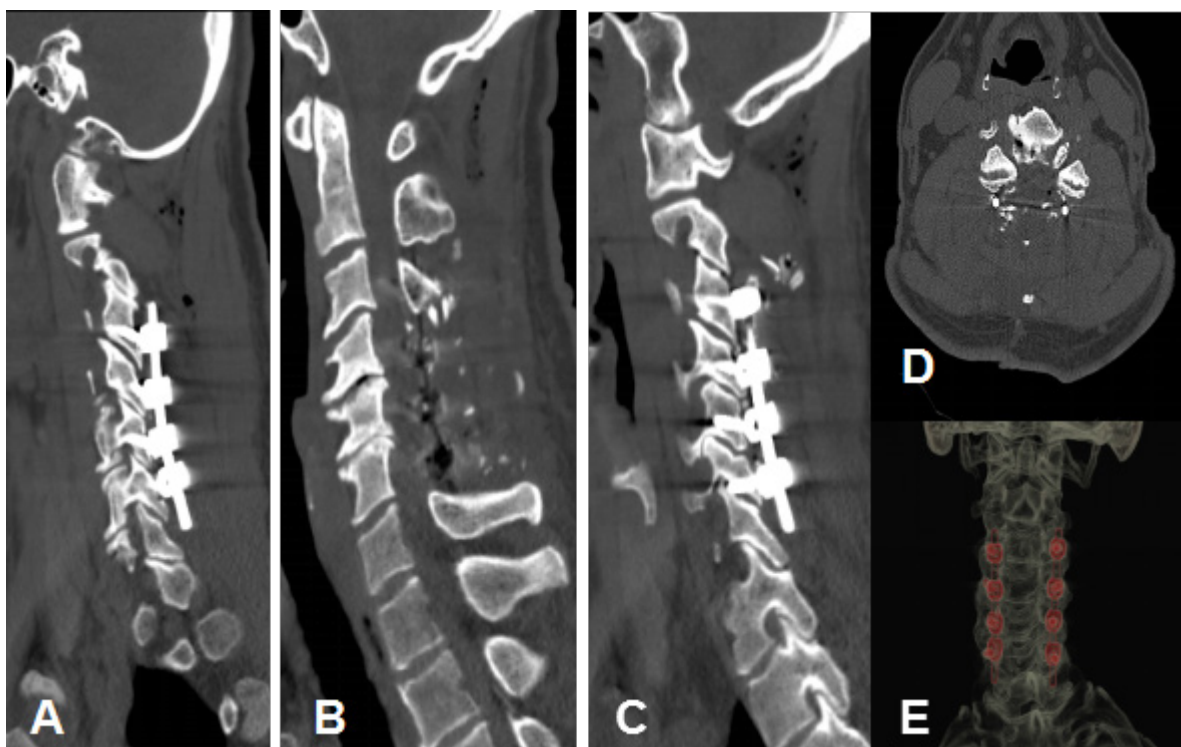


Figure 8 Post-operative images. A: Left posterior cervical fusion C3-6. B: Posterior cervical spinal canal decompression C4-6. C: Right posterior cervical fusion C3-6. D: Axial view of posterior cervical decompression. E: Coronal 3D-CT reconstruction of posterior cervical fusion.

PROGNOSTIC FACTORS

Many prognostic factors in CSM has been studied and evaluated. Patient's age, duration of symptoms, preoperative neurological status, radiological findings including the number of levels of compression, effective canal diameter, and intrinsic signal changes in the cord, are the most important of them^[36,73-75]. Understanding the clinical factors that predict a proper surgical treatment outcome is of fundamental importance to make therapeutic decisions^[76].

Studies differ concerning the cutoff point of the age group that would present the best prognosis for surgical treatment^[77-79]. It is known that younger patients have a greater chance of clinical improvement, especially when they are under 65 years old^[80].

On MRI studies, preoperative spinal cord area and intramedullary signal changes are related to poor outcome^[81]. The intramedullary signal is related to tissue relaxation and increased water content in spinal cord injuries. Due to this fact, T2 sequences are affected earlier than T1 and T1 hypointense signals will always be accompanied by T2 hyperintense signals^[82]. Therefore, T2 hyperintense signal is a marker of early myelopathy and the T1 hypointense signal is correlated to advanced spinal cord injury^[83,84]. The hyperintense signs of the spinal cord were described as three types of Increased Signal Intensity (ISI) on T2-weighted MRI images: Type-1: none, Type-2: light and diffuse area, and Type-3: bright, strong hyperintense well-circumscribed^[85]. Only the Type-2 was correlated to poor outcome^[86].

Prolonged MEPs and SSEPs, MRI abnormalities, and symptomatic radiculopathy have been described as important predictors of early myelopathy development^[87]. When compared to MRI, electrophysiological tests tend to detect earlier the risk of progression into myelopathy^[88].

TREATMENT

Asymptomatic patients with positive MRI or electrophysiological tests should be observed closely due to the risk of myelopathy

development. Mild symptomatic patients may be treated non-operatively with bed rest, physical therapy, medication, injections, and orthoses. Recent studies showed similar outcomes for conservative and surgical treatment used in mild symptomatic patients ($mJOA \geq 13$)^[89-91].

Moderate and severe CSM cases should be surgically treated since the disease will progress with neurological deterioration in the majority of the cases^[92]. Surgery should be done as soon as possible because when performed at earlier stages it presents better functional outcomes^[93].

The objectives of surgical treatment are to decompress the cervical spine, restore cervical alignment, and ensure the stabilization of the involved segments. To obtain these results, several anterior, posterior, or combined approaches were described. The choice of the most appropriate technique is out of the scope of this review, but should consider the patient's age, general medical condition, number of levels to be treated, site of compression, cervical alignment, and instability, previous treatment, bone quality, and surgeon's preference^[94-97].

CLINICAL CASES

Case 1

We report two illustrative cases. A 46-year-old man who had cervical pain radiating to his right upper arm with weakness sensation in both arms. He was diagnosed with CSM and radiculopathy and underwent surgical treatment 2 months after the diagnosis. During the physical examination, he had normal motricity, a positive Spurling maneuver, pyramidal sign (Hoffman and Tromner) in the right side. He had a Nurick Scale grade 1 and scored 15 on mJOA scale.

Pre-operative Cervical computed tomography showed three levels of cervical stenosis (C3/4, C4/5 and C5/6). Further evaluation with MRI showed three levels of anterior compression due to herniated disc and posterior ligament hypertrophy on the right portion of spine canal (Figure 5).

Initially, the patient was treated conservatively with pain killers, however, pain became unbearable with limitation of daily activities. We performed three levels of anterior cervical discectomy and fusion (ACDF), with good decompression, lordosis restoration and clinical improvement (Figure 6).

Patient evaluated with pain control and improved muscle strength in the right side. According to clinical evaluation scales, patient improved his results. He scored 18 at mJOA and was classified as Nurick grade 0.

Case 2

We present a 64-year-old man with difficulty to walk and weakness in his right side. He was diagnosed with CSM and underwent surgical treatment after 3 months. The patient presented instable gait and needed support to walk. Babinski reflex, Hofmann and Tromner signs were bilaterally present. He scored 12 at mJOA scale and was classified as Nurick grade 3.

Imaging evaluation demonstrated cervical stenosis at C4/5 and C5/6 levels (Figure 7). Patient underwent surgical treatment with posterior cervical decompression and fusion (Figure 8).

Patient improved his gait and strength. He scored 17 at mJOA scale and was reclassified as Nurick 1.

CONCLUSION

CSM is the main cause of spinal cord dysfunction in adults. Symptoms may be unspecified, which delays the diagnosis. From the point when patients present neurological impairment, it usually tends to progress over time, with a stepwise progression occurring in 75% of the cases.

Mild symptomatic cases could be treated non-operatively by an expert with bed rest, physical therapy, medications, injections, and orthoses. A regular follow-up should be done to assess the clinical conditions. If the symptoms progress and the patient gets a worse score at mJOA or Nurick scale, a surgery should be done.

Surgical treatment aims to decompress the spinal canal, keep the cervical alignment, and avoid or correct cervical instability. Anterior, posterior or combined approaches for the cervical spine were described. The choice for the best treatment should consider the patient's age, comorbidities, clinical status, previous surgery, bone quality, number of levels to treat, site of compression, cervical alignment, and stability. When there is no evidence of the superiority of any techniques, the surgeon's preference must be considered.

REFERENCES

1. Toledano M, Bartleson JD. Cervical Spondylotic Myelopathy. *Neurol Clin.* 2013; **31(1)**: 287-305. [PMID: 23186905]; [DOI: 10.1016/j.ncl.2012.09.003]
2. Nishida N, Kato Y, Imajo Y, Kawano S, Taguchi T. Biomechanical analysis of cervical spondylotic myelopathy: The influence of dynamic factors and morphometry of the spinal cord. *J Spinal Cord Med.* 2012; **35(4)**: 256-261. [PMID: 22925752]; [PMCID: PMC3425882]; [DOI: 10.1179/2045772312Y.0000000024]
3. Nishida N, Kanchiku T, Kato Y, et al. Biomechanical analysis of cervical myelopathy due to ossification of the posterior longitudinal ligament: Effects of posterior decompression and kyphosis following decompression. *Exp Ther Med.* 2014; **7(5)**: 1095-1099. [PMID: 24940393]; [PMCID: PMC3991514]; [DOI: 10.3892/etm.2014.1557]
4. Fujimoto Y, Oka S, Tanaka N, Nishikawa K, Kawagoe H, Baba I. Pathophysiology and treatment for cervical flexion myelopathy. *Eur Spine J.* 2002; **11(3)**: 276-285. [PMID: 12107798]; [PMCID: PMC3610521]; [DOI: 10.1007/s005860100344]

5. Ichihara K, Taguchi T, Sakuramoto I, Kawano S, Kawai S. Mechanism of the spinal cord injury and the cervical spondylotic myelopathy: new approach based on the mechanical features of the spinal cord white and gray matter. *J Neurosurg.* 2003; **99(3 Suppl)**: 278-285. [PMID: 14563145]; [DOI: 10.3171/spi.2003.99.3.0278]
6. Boogaarts HD, Bartels RHMA. Prevalence of cervical spondylotic myelopathy. *Eur Spine J.* 2015; **24(2)**: 139-141. [PMID: 23616201]; [DOI: 10.1007/s00586-013-2781-x]
7. Tetreault L, Goldstein CL, Arnold P, et al. Degenerative cervical myelopathy: A spectrum of related disorders affecting the aging spine. *Neurosurgery.* 2015; **77(4)**: S51-S67. [DOI: 10.1227/NEU.0000000000000951]
8. Yarbrough CK, Murphy RKJ, Ray WZ, Stewart TJ. The Natural History and Clinical Presentation of Cervical Spondylotic Myelopathy. *Adv Orthop.* 2012; **2012**: 1-4. [PMID: 22235378]; [PMCID: PMC3253434]; [DOI: 10.1155/2012/480643]
9. Rao R. Neck pain, cervical radiculopathy, and cervical myelopathy: Pathophysiology, natural history, and clinical evaluation. *J Bone Jt Surg.* 2002; **84(10)**: 1872-1881. [PMID: 12377921]; [DOI: 10.2106/00004623-200210000-00021]
10. Bakhsheshian J, Mehta VA, Liu JC. Current Diagnosis and Management of Cervical Spondylotic Myelopathy. *Glob Spine J.* 2017; **7(6)**: 572-586. [PMID: 28894688]; [PMCID: PMC5582708]; [DOI: 10.1177/2192568217699208]
11. Wu J-C, Ko C-C, Yen Y-S, et al. Epidemiology of cervical spondylotic myelopathy and its risk of causing spinal cord injury: a national cohort study. *Neurosurg Focus.* 2013; **35(1)**: E10. [PMID: 23815246]; [DOI: 10.3171/2013.4.FOCUS13122]
12. Nouri A, Tetreault L, Singh A, Karadimas SK, Fehlings MG. Degenerative cervical myelopathy: Epidemiology, genetics, and pathogenesis. *Spine (Phila Pa 1976).* 2015; **40(12)**: E675-E693. [PMID: 25839387]; [DOI: 10.1097/BRS.0000000000000913]
13. Yamaguchi S, Mitsuhashi T, Abiko M, Takeda M, Kurisu K. Epidemiology and Overview of the Clinical Spectrum of Degenerative Cervical Myelopathy. *Neurosurg Clin N Am.* 2018; **29(1)**: 1-12. [PMID: 29173421]; [DOI: 10.1016/j.nec.2017.09.001]
14. Karadimas SK, Erwin WM, Ely CG, Dettori JR, Fehlings MG. Pathophysiology and natural history of cervical spondylotic myelopathy. *Spine (Phila Pa 1976).* 2013; **38(22 Suppl 1)**: 5-12. [PMID: 23963004]; [DOI: 10.1097/BRS.0b013e3182a7f2c3]
15. Bednařik J, Sládková D, Kadaňka Z, et al. Are subjects with spondylotic cervical cord encroachment at increased risk of cervical spinal cord injury after minor trauma? *J Neurol Neurosurg Psychiatry.* 2011; **82(7)**: 779-781. [PMID: 20587498]; [DOI: 10.1136/jnnp.2009.198945]
16. Fehlings MG, Tetreault LA, Riew KD, et al. A Clinical Practice Guideline for the Management of Patients With Degenerative Cervical Myelopathy: Recommendations for Patients With Mild, Moderate, and Severe Disease and Nonmyelopathic Patients With Evidence of Cord Compression. *Glob Spine J.* 2017; **7(3 supplement)**: 70S-83S. [PMID: 29164035]; [PMCID: PMC5684840]; [DOI: 10.1177/2192568217701914]
17. Fehlings MG, Arvin B. Surgical management of cervical degenerative disease: The evidence related to indications, impact, and outcome. *J Neurosurg Spine.* 2009; **11(2)**: 97-100. [PMID: 19769487]; [DOI: 10.3171/2009.5.SPINE09210]
18. Matz PG, Anderson PA, Holly LT, et al. The natural history of cervical spondylotic myelopathy. *J Neurosurg Spine.* 2009; **11(2)**: 104-111. [PMID: 19769489]; [DOI: 10.3171/2009.1.SPINE08716]
19. Chatley A, Kumar R, Jain VK, Behari S, Sahu RN. Effect of spinal cord signal intensity changes on clinical outcome after surgery for cervical spondylotic myelopathy - Clinical article. *J Neurosurg Spine.* 2009; **11(5)**: 562-567. [PMID: 19929358]; [DOI: 10.3171/2009.6.SPINE091]

20. Zhang JT, Wang LF, Wang S, Li J, Shen Y. Risk factors for poor outcome of surgery for cervical spondylotic myelopathy. *Spinal Cord*. 2016; **54(12)**: 1127-1131. [PMID: 27137121]; [DOI: 10.1038/sc.2016.64]
21. Zileli M, Maheshwari S, Kale SS, Garg K, Menon SK, Parthiban J. Outcome Measures and Variables Affecting Prognosis of Cervical Spondylotic Myelopathy: WFNS Spine Committee Recommendations. *Neurospine*. 2019; **16(3)**: 435-447. [PMID: 31607075]; [PMCID: PMC6790741]; [DOI: 10.14245/ns.1938196.098]
22. Karadimas SK, Gatzounis G, Fehlings MG. Pathobiology of cervical spondylotic myelopathy. *Eur Spine J*. 2015; **24(2)**: 132-138. [PMID: 24626958]; [DOI: 10.1007/s00586-014-3264-4]
23. Taylor AR. Mechanism and treatment of spinal-cord disorders associated with cervical spondylosis. *Lancet*. 1953; **261(6763)**: 717-720. [PMID: 13036140]; [DOI: 10.1016/s0140-6736(53)91847-9]
24. Baptiste DC, Fehlings MG. Pathophysiology of cervical myelopathy. *Spine J*. 2006; **6(6 SUPPL.)**: 190-197. [PMID: 17097538]; [DOI: 10.1016/j.spinee.2006.04.024]
25. Mattei TA, Goulart CR, Milano JB, Dutra LPF, Fasset DR. Cervical Spondylotic Myelopathy: Pathophysiology, Diagnosis, and Surgical Techniques. *ISRN Neurol*. 2011; **2011**: 1-5. [PMID: 22389818]; [PMCID: PMC3263543]; [DOI: 10.5402/2011/463729]
26. de Oliveira Vilaça C, Orsini M, Leite MAA, et al. Cervical spondylotic myelopathy: What the neurologist should know. *Neurol Int*. 2016; **8(4)**: 69-73. [PMID: 27994827]; [PMCID: PMC5136752]; [DOI: 10.4081/ni.2016.6330]
27. Wilson JR, Tetreault LA, Kim J, et al. State of the art in degenerative cervical myelopathy: An update on current clinical evidence. *Clin Neurosurg*. 2017; **80(3)**: S33-S45. [PMID: 28350949]; [DOI: 10.1093/neuros/nyw083]
28. Nurjck S. The pathogenesis of the spinal cord disorder associated with cervical spondylosis. *Brain*. 1972; **95(1)**: 87-100. [PMID: 5023093]; [DOI: 10.1093/brain/95.1.87]
29. Behrbalk E, Salame K, Gilad J, Keynan O, Czyk BB, Lidar Z. Delayed diagnosis of cervical spondylotic myelopathy by primary care physicians. *Neurosurg Focus*. 2013; **35(1)**: E1. [PMID: 23815245]; [DOI: 10.3171/2013.3.FOCUS1374]
30. Davies BM, Mowforth OD, Smith EK, Kotter MRN. Degenerative cervical myelopathy. *BMJ*. 2018; **360(February)**: 1-4. [PMID: 29472200]; [PMCID: PMC6074604]; [DOI: 10.1136/bmj.k186]
31. Sadasivan KK, Reddy RP, Albright JA. The natural history of cervical spondylotic myelopathy. *Yale J Biol Med*. 1994; **66(3)**: 235-242. [DOI: 10.5005/jp/books/12823_7]
32. Kim HJ, Tetreault LA, Massicotte EM, et al. Differential Diagnosis for Cervical Spondylotic Myelopathy. *Spine (Phila Pa 1976)*. 2013; **38(22)**: S78-S88. [PMID: 23962997]; [DOI: 10.1097/BRS.0b013e3182a7eb06]
33. Vigna FE, Tortolani PJ. Cervical myelopathy: Differential diagnosis. *Semin Spine Surg*. 2004; **16(4)**: 228-233. [DOI: 10.1053/j.semss.2004.10.003]
34. Dvorak J, Sutter M, Herdmann J. Cervical myelopathy: Clinical and neurophysiological evaluation. *Eur Spine J*. 2003; **12(SUPPL. 2)**: 181-187. [PMID: 14551827]; [PMCID: PMC3591830]; [DOI: 10.1007/s00586-003-0631-y]
35. Vitzthum HE, Dalitz K. Analysis of five specific scores for cervical spondylogenic myelopathy. *Eur Spine J*. 2007; **16(12)**: 2096-2103. [PMID: 17922150]; [PMCID: PMC2140133]; [DOI: 10.1007/s00586-007-0512-x]
36. Pumberger M, Froemel D, Aichmair A, et al. Clinical predictors of surgical outcome in cervical spondylotic myelopathy: An analysis of 248 patients. *Bone Jt J*. 2013; **95 B(7)**: 966-971. [PMID: 23814251]; [DOI: 10.1302/0301-620X.95B7.31363]
37. Tetreault L, Kopjar B, Nouri A, et al. The modified Japanese Orthopaedic Association scale: establishing criteria for mild, moderate and severe impairment in patients with degenerative cervical myelopathy. *Eur Spine J*. 2017; **26(1)**: 78-84. [PMID: 27342612]; [DOI: 10.1007/s00586-016-4660-8]
38. Glaser JA, Curé JK, Bailey KL, Morrow DL. Cervical spinal cord compression and the Hoffmann sign. *Iowa Orthop J*. 2001; **21**: 49-52. [PMID: 11813951]; [PMCID: PMC1888193]
39. Houten JK, Noce LA. Clinical correlations of cervical myelopathy and the Hoffmann sign. *J Neurosurg Spine*. 2008; **9(3)**: 237-242. [PMID: 18928217]; [DOI: 10.3171/SPI/2008/9/9/237]
40. Harrop JS, Hanna A, Silva MT, Sharan A. Neurological manifestations of cervical spondylosis: An overview of signs, symptoms, and pathophysiology. *Neurosurgery*. 2007; **60(1 SUPPL.)**: 14-20. [PMID: 17204875]; [DOI: 10.1227/01.NEU.0000215380.71097.EC]
41. Cook C, Roman M, Stewart KM, Leithe LG, Isaacs R. Reliability and diagnostic accuracy of clinical special tests for myelopathy in patients seen for cervical dysfunction. *J Orthop Sports Phys Ther*. 2009; **39(3)**: 172-178. [PMID: 19252263]; [DOI: 10.2519/jospt.2009.2938]
42. Cook CE, Wilhelm M, Cook AE, Petrosino C, Isaacs R. Clinical tests for screening and diagnosis of cervical spine myelopathy: A systematic review. *J Manipulative Physiol Ther*. 2011; **34(8)**: 539-546. [PMID: 21899892]; [DOI: 10.1016/j.jmpt.2011.08.008]
43. Denno JJ, Meadows GR. Early diagnosis of cervical spondylotic myelopathy: A useful clinical sign. *Spine (Phila Pa 1976)*. 1991; **16(12)**: 1353-1355. [PMID: 1771463]; [DOI: 10.1097/00007632-199112000-00001]
44. LaBan MM, Green ML. Concurrent (Tandem) Cervical and Lumbar Spinal Stenosis: A 10-yr Review of 54 Hospitalized Patients. *Am J Phys Med Rehabil*. 2004; **83(3)**: 187-190. [PMID: 15043352]; [DOI: 10.1097/01.phm.0000113405.48879.45]
45. Williams SK, Eismont FJ. Concomitant Cervical and Lumbar Stenosis: Strategies for Treatment and Outcomes. *Semin Spine Surg*. 2007; **19(3)**: 165-176; [DOI: 10.1053/j.semss.2007.06.005]
46. Tong HC, Haig AJ, Yamakawa K. The Spurling test and cervical radiculopathy. *Spine (Phila Pa 1976)*. 2002; **27(2)**: 156-159. [PMID: 11805661]; [DOI: 10.1097/00007632-200201150-00007]
47. Kempster PA, Rollinson RD. The Lhermitte phenomenon: Variant forms and their significance. *J Clin Neurosci*. 2008; **15(4)**: 379-381. [PMID: 18280165]; [DOI: 10.1016/j.jocn.2007.05.002]
48. Matsumoto M, Ishikawa M, Ishii K, et al. Usefulness of neurological examination for diagnosis of the affected level in patients with cervical compressive myelopathy: prospective comparative study with radiological evaluation. *J Neurosurg Spine*. 2005; **2(5)**: 535-539. [PMID: 15945427]; [DOI: 10.3171/spi.2005.2.5.0535]
49. Rhee JM, Heflin JA, Hamasaki T, Freedman B. Prevalence of physical signs in cervical myelopathy: A prospective, controlled study. *Spine (Phila Pa 1976)*. 2009; **34(9)**: 890-895. [PMID: 19352222]; [DOI: 10.1097/BRS.0b013e31819c944b]
50. Nakashima H, Yukawa Y, Ito K, et al. Validity of the 10-s step test: Prospective study comparing it with the 10-s grip and release test and the 30-m walking test. *Eur Spine J*. 2011; **20(8)**: 1318-1322. [PMID: 21380747]; [PMCID: PMC3175849]; [DOI: 10.1007/s00586-011-1733-6]
51. Bohm PE, Fehlings MG, Kopjar B, et al. Psychometric properties of the 30-m walking test in patients with degenerative cervical myelopathy: results from two prospective multicenter cohort studies. *Spine J*. 2017; **17(2)**: 211-217. [PMID: 27592193]; [DOI: 10.1016/j.spinee.2016.08.033]
52. Yukawa Y, Nakashima H, Ito K, Machino M, Kanbara S, Kato F. Quantifiable tests for cervical myelopathy: 10-s grip and release test and 10-s step test: Standard values and aging variation from 1230 healthy volunteers. *J Orthop Sci*. 2013; **18(4)**: 509-513. [PMID: 23564077]; [DOI: 10.1007/s00776-013-0381-6]
53. Sakai N. Finger motion analysis of the patients with cervical myelopathy. *Spine (Phila Pa 1976)*. 2005; **30(24)**: 2777-2782. [PMID: 16371902]; [DOI: 10.1097/01.brs.0000190452.33258.72]

54. Omori M, Shibuya S, Nakajima T, et al. Hand Dexterity Impairment in Patients with Cervical Myelopathy: A New Quantitative Assessment Using a Natural Prehension Movement. *Behav Neurol.* 2018; **2018**: 5138234. [PMID: 30073036]; [PMCID: PMC6057419]; [DOI: 10.1155/2018/5138234]
55. Yukawa Y, Kato F, Ito K, et al. Ten second step test as a new quantifiable parameter of cervical myelopathy. *Spine (Phila Pa 1976).* 2009; **34(1)**: 82-86. [PMID: 19127165]; [DOI: 10.1097/BRS.0b013e31818e2b19]
56. Arnold PM, Bohm P, Fehlings MG, Kopjar B. A 30-Meter Walking Test as a Measure of Cervical Spondylotic Myelopathy Severity: Test Characteristics and Results from Two Multicenter Cohort Studies. *Spine J.* 2015; **15(10)**: S95. [DOI: 10.1016/j.spinee.2015.07.035]
57. Malone A, Meldrum D, Bolger C. Gait impairment in cervical spondylotic myelopathy: Comparison with age- and gender-matched healthy controls. *Eur Spine J.* 2012; **21(12)**: 2456-2466. [PMID: 22825630]; [PMCID: PMC3508234]; [DOI: 10.1007/s00586-012-2433-6]
58. Nishimura H, Endo K, Suzuki H, Tanaka H, Shishido T, Yamamoto K. Gait analysis in cervical spondylotic myelopathy. *Asian Spine J.* 2015; **9(3)**: 321-326. [PMID: 26097646]; [PMCID: PMC4472579]; [DOI: 10.4184/asj.2015.9.3.321]
59. Maezawa Y, Uchida K, Baba H. Gait analysis of spastic walking in patients with cervical compressive myelopathy. *J Orthop Sci.* 2001; **6(5)**: 378-384. [PMID: 11845345]; [DOI: 10.1007/s007760170002]
60. Martin AR, Tadokoro N, Tetreault L, et al. Imaging Evaluation of Degenerative Cervical Myelopathy: Current State of the Art and Future Directions. *Neurosurg Clin N Am.* 2018; **29(1)**: 33-45. [PMID: 29173434]; [DOI: 10.1016/j.nec.2017.09.003]
61. Alizada M, Li RR, Hayatullah G. Cervical instability in cervical spondylosis patients: Significance of the radiographic index method for evaluation. *Orthopade.* 2018; **47(12)**: 977-984. [PMID: 30255359]; [PMCID: PMC6267126]; [DOI: 10.1007/s00132-018-3635-3]
62. Waly FJ, Abduljabbar FH, Fortin M, Nooh A, Weber M. Preoperative Computed Tomography Myelography Parameters as Predictors of Outcome in Patients With Degenerative Cervical Myelopathy: Results of a Systematic Review. *Glob Spine J.* 2017; **7(6)**: 521-528. [PMID: 28894681]; [PMCID: PMC5582716]; [DOI: 10.1177/2192568217701101]
63. Shafaie FF, Wippold FJ, Gado M, Pilgram TK, Riew KD. Comparison of Computed Tomography Myelography and Magnetic Resonance Imaging in the Evaluation of Cervical Spondylotic Myelopathy and Radiculopathy. *Spine (Phila Pa 1976).* 1999; **24(17)**: 1781. [PMID: 10488507]; [DOI: 10.1097/00007632-199909010-00006]
64. Sarbu N, Lolli V, Smirniotopoulos JG. Magnetic resonance imaging in myelopathy: a pictorial review. *Clin Imaging.* 2019; **57(November 2018)**: 56-68. [PMID: 31129392]; [DOI: 10.1016/j.clinimag.2019.05.002]
65. Morishita Y, Naito M, Hymanson H, Miyazaki M, Wu G, Wang JC. The relationship between the cervical spinal canal diameter and the pathological changes in the cervical spine. *Eur Spine J.* 2009; **18(6)**: 877-883. [PMID: 19357877]; [PMCID: PMC2899662]; [DOI: 10.1007/s00586-009-0968-y]
66. Pavlov H, Torg JS, Robie B, Jahre C. Cervical spinal stenosis: determination with vertebral body ratio method. *Radiology.* 1987; **164(3)**: 771-775. [PMID: 3615879]; [DOI: 10.1148/radiology.164.3.3615879]
67. Yue WM, Tan SB, Tan MH, Koh DCS, Tan CT. The Torg-Pavlov ratio in cervical spondylotic myelopathy: A comparative study between patients with cervical spondylotic myelopathy and a nonspondylotic, nonmyelopathic population. *Spine (Phila Pa 1976).* 2001; **26(16)**: 1760-1764. [PMID: 11493847]; [DOI: 10.1097/00007632-200108150-00006]
68. Song KJ, Choi BW, Kim SJ, Kim GH, Kim YS, Song JH. The relationship between spinal stenosis and neurological outcome in traumatic cervical spine injury: an analysis using Pavlov's ratio, spinal cord area, and spinal canal area. *Clin Orthop Surg.* 2009; **1(1)**: 11-18. [PMID: 19884992]; [PMCID: PMC2766695]; [DOI: 10.4055/cios.2009.1.1.11]
69. Penning L, Wilmink JT, Van Woerden HH, Knol E. CT myelographic findings in degenerative disorders of the cervical spine: Clinical significance. *Am J Roentgenol.* 1986; **146(4)**: 793-801. [PMID: 3485355]; [DOI: 10.2214/ajr.146.4.793]
70. Taylor JAM, Bussi eres A. Diagnostic imaging for spinal disorders in the elderly: a narrative review. *Chiropr Man Ther.* 2012; **20(1)**: 16. [PMID: 22625868]; [PMCID: PMC3438046]; [DOI: 10.1186/2045-709X-20-16]
71. Witiw CD, Mathieu F, Nouri A, Fehlings MG. Clinico-Radiographic Discordance: An Evidence-Based Commentary on the Management of Degenerative Cervical Spinal Cord Compression in the Absence of Symptoms or With Only Mild Symptoms of Myelopathy. *Glob Spine J.* 2018; **8(5)**: 527-534. [PMID: 30258760]; [PMCID: PMC6149046]; [DOI: 10.1177/2192568217745519]
72. Sim  M, Szirmai I, Ar nyi Z. Superior sensitivity of motor over somatosensory evoked potentials in the diagnosis of cervical spondylotic myelopathy. *Eur J Neurol.* 2004; **11(9)**: 621-626. [PMID: 15379741]; [DOI: 10.1111/j.1468-1331.2004.00863.x]
73. Yamazaki T, Yanaka K, Sato H, Uemura K, Tsukada A, Nose T. Cervical Spondylotic Myelopathy: Surgical Results and Factors Affecting Outcome with Special Reference to Age Differences. *Neurosurgery.* 2003; **52(1)**: 122-126. [PMID: 12493108]; [DOI: 10.1097/00006123-200301000-00015]
74. Karpova A, Arun R, Davis AM, et al. Predictors of surgical outcome in cervical spondylotic myelopathy. *Spine (Phila Pa 1976).* 2013; **38(5)**: 392-400. [PMID: 23448898]; [DOI: 10.1097/BRS.0b013e3182715bc3]
75. Tetreault LA, Karpova A, Fehlings MG. Predictors of outcome in patients with degenerative cervical spondylotic myelopathy undergoing surgical treatment: results of a systematic review. *Eur Spine J.* 2015; **24(2)**: 236-251. [PMID: 23386279]; [DOI: 10.1007/s00586-013-2658-z]
76. Shimomura T, Sumi M, Nishida K, et al. Prognostic factors for deterioration of patients with cervical spondylotic myelopathy after nonsurgical treatment. *Spine (Phila Pa 1976).* 2007; **32(22)**: 2474-2479. [PMID: 18090088]; [DOI: 10.1097/BRS.0b013e3181573aee]
77. Nagashima H, Dokai T, Hashiguchi H, et al. Clinical features and surgical outcomes of cervical spondylotic myelopathy in patients aged 80 years or older: A multi-center retrospective study. *Eur Spine J.* 2011; **20(2)**: 240-246. [PMID: 21197553]; [PMCID: PMC3030708]; [DOI: 10.1007/s00586-010-1672-7]
78. Maeno T, Okuda S, Yamashita T, et al. Age-related surgical outcomes of laminoplasty for cervical spondylotic myelopathy. *Glob Spine J.* 2014; **5(2)**: 118-123. [PMID: 25844284]; [PMCID: PMC4369199]; [DOI: 10.1055/s-0034-1396759]
79. Wilson JR, Badhiwala JH, Jiang F, et al. The impact of older age on functional recovery after surgical decompression for degenerative cervical myelopathy: results from an international, multicentre, prospective dataset in 757 patients. *Spine J.* 2019; **19(9)**: S135-S136. [DOI: 10.1016/j.spinee.2019.05.294]
80. Nakashima H, Tetreault LA, Nagoshi N, et al. Does age affect surgical outcomes in patients with degenerative cervical myelopathy? Results from the prospective multicenter AOSpine International study on 479 patients. *J Neurol Neurosurg Psychiatry.* 2016; **87(7)**: 734-740. [PMID: 26420885]; [PMCID: PMC4941131]; [DOI: 10.1136/jnnp-2015-311074]
81. Okada Y, Ikata T, Yamada H, Sakamoto R, Katoh S. Magnetic resonance imaging study on the results of surgery for cervical compression myelopathy. *Spine (Phila Pa 1976).* 1993; **18(14)**:

- 2024-2029. [PMID: 8272953]; [DOI: 10.1097/00007632-199310001-00016]
82. Nouri A, Martin AR, Mikulis D, Fehlings MG. Magnetic resonance imaging assessment of degenerative cervical myelopathy: a review of structural changes and measurement techniques. *Neurosurg Focus*. 2016; **40(6)**: E5. [PMID: 27246488]; [DOI: 10.3171/2016.3.FOCUS1667]
 83. Uchida K, Nakajima H, Takeura N, et al. Prognostic value of changes in spinal cord signal intensity on magnetic resonance imaging in patients with cervical compressive myelopathy. *Spine J*. 2014; **14(8)**: 1601-1610. [PMID: 24411833]; [DOI: 10.1016/j.spinee.2013.09.038]
 84. Chen H, Pan J, Nisar M, et al. The value of preoperative magnetic resonance imaging in predicting postoperative recovery in patients with cervical spondylosis myelopathy: A meta-analysis. *Clinics*. 2016; **71(3)**: 179-184. [DOI: 10.6061/clinics/2016(03)10]
 85. Kim TH, Ha Y, Shin JJ, Cho YE, Lee JH, Cho WH. Signal intensity ratio on magnetic resonance imaging as a prognostic factor in patients with cervical compressive myelopathy. *Med (United States)*. 2016; **95(39)**. [PMID: 27684796]; [PMCID: PMC5265889]; [DOI: 10.1097/MD.0000000000004649]
 86. Vedantam A, Jonathan A, Rajshekhar V. Association of magnetic resonance imaging signal changes and outcome prediction after surgery for cervical spondylotic myelopathy: Clinical article. *J Neurosurg Spine*. 2011; **15(6)**: 660-666. [PMID: 21923236]; [DOI: 10.3171/2011.8.SPINE11452]
 87. Kadanka Z, Adamova B, Kerkovsky M, et al. Predictors of symptomatic myelopathy in degenerative cervical spinal cord compression. *Brain Behav*. 2017; **7(9)**: 1-10. [DOI: 10.1002/brb3.797]
 88. Martin AR, De Leener B, Cohen-Adad J, et al. Monitoring for myelopathic progression with multiparametric quantitative MRI. Toft M, ed. *PLoS One*. 2018; **13(4)**: e0195733. [PMID: 29664964]; [PMCID: PMC5903654]; [DOI: 10.1371/journal.pone.0195733]
 89. Hirpara KM, Butler JS, Dolan RT, O'Byrne JM, Poynton AR. Nonoperative Modalities to Treat Symptomatic Cervical Spondylosis. *Adv Orthop*. 2012; **2012**: 1-5. [PMID: 21991426]; [PMCID: PMC3168941]; [DOI: 10.1155/2012/294857]
 90. Rhee JM, Shamji MF, Erwin WM, et al. Nonoperative management of cervical myelopathy: a systematic review. *Spine (Phila Pa 1976)*. 2013; **38(22 Suppl 1)**. [PMID: 23963006]; [DOI: 10.1097/BRS.0b013e3182a7f41d]
 91. Rhee J, Tetreault LA, Chapman JR, et al. Nonoperative Versus Operative Management for the Treatment Degenerative Cervical Myelopathy: An Updated Systematic Review. *Glob Spine J*. 2017; **7(3 supplement)**: 35S-41S; [DOI: 10.1177/2192568217703083]
 92. Fouyas IP, Sandercock PA, Statham PF, Lynch C. Surgery for cervical radiculomyelopathy. *Cochrane Database Syst Rev*. 2007 Jul 18; **(2)**: CD001466. [PMID: 17636675]; [DOI: 10.1002/14651858.CD001466.pub2]
 93. K Y. Cervical radiculopathy and myelopathy: When and what can surgery contribute to treatment? *Eur Spine J*. 2000; **9(1)**: 1-7. <http://www.embase.com/search/results?subaction=viewrecord&from=export&id=L30706572>.
 94. Joaquim AF, Ghizoni E, Tedeschi H, Hsu WK, Patel AA. Management of degenerative cervical myelopathy - An update. *Rev Assoc Med Bras*. 2016; **62(9)**: 886-894. [PMID: 28001265]; [DOI: 10.1590/1806-9282.62.09.886]
 95. Ames CP, Blondel B, Scheer JK, et al. Cervical Radiographical Alignment. *Spine (Phila Pa 1976)*. 2013; **38(23)**: S149-S160. [PMID: 24113358]; [DOI: 10.1097/BRS.0b013e3182a7f449]
 96. Montano N, Ricciardi L, Olivi A. Comparison of Anterior Cervical Decompression and Fusion versus Laminoplasty in the Treatment of Multilevel Cervical Spondylotic Myelopathy: A Meta-Analysis of Clinical and Radiological Outcomes. *World Neurosurg*. 2019; **130**: 530-536.e2. [PMID: 31254693]; [DOI: 10.1016/j.wneu.2019.06.144]
 97. Hirai T, Yoshii T, Arai Y, et al. A Comparative Study of Anterior Decompression with Fusion and Posterior Decompression with Laminoplasty for the Treatment of Cervical Spondylotic Myelopathy Patients with Large Anterior Compression of the Spinal Cord. *Clin Spine Surg*. 2017; **30(8)**: E1137-E1142. [PMID: 28099187]; [DOI: 10.1097/BSD.0000000000000500]