

Proximal Femoral Nailing for Intertrochanteric Fracture in Birmingham Hip Resurfacing Arthroplasty

Piyush Setia¹, Atul Gaitonde¹

1 Senior Clinical Fellow, Princess of Wales Hospital, United Kingdom.

Conflict-of-interest statement: The author(s) declare(s) that there is no conflict of interest regarding the publication of this paper.

Open-Access: This article is an open-access article which was selected by an in-house editor and fully peer-reviewed by external reviewers. It is distributed in accordance with the Creative Commons Attribution Non Commercial (CC BY-NC 4.0) license, which permits others to distribute, remix, adapt, build upon this work non-commercially, and license their derivative works on different terms, provided the original work is properly cited and the use is non-commercial. See: <http://creativecommons.org/licenses/by-nc/4.0/>

Correspondence to: Piyush Setia, Senior Clinical Fellow, Princess of Wales Hospital, United Kingdom.
Email: Piyush.setia@gmail.com

Received: August 12, 2020

Revised: November 20, 2020

Accepted: November 24 2020

Published online: December 28, 2020

ABSTRACT

Neck of femur fractures in elderly patients with hip resurfacing in situ are rarely reported injuries. We report a case of intertrochanteric fracture in a 62 year old man with ipsilateral Birmingham Hip Resurfacing (BHR) arthroplasty, successfully treated with internal fixation using proximal femoral nail. There were no intraoperative or postoperative complications and the patient returned to his normal level of activities within 6 months after the fixation. In conclusion we have demonstrated that fixation with proximal femoral nails can be an alternative safer option in treatment of these complex injuries.

Key words: Proximal femur nailing; Hip resurfacing; Intertrochanteric fracture, Fixation

© 2020 The Author(s). Published by ACT Publishing Group Ltd. All rights reserved.

Setia P, Gaitonde A. Proximal Femoral Nailing for Intertrochanteric

Fracture in Birmingham Hip Resurfacing Arthroplasty. *International Journal of Orthopaedics* 2020; 7(6): 1410-1412 Available from: URL: <http://www.ghrnet.org/index.php/ijo/article/view/2970>

INTRODUCTION

Neck of femur fractures in hip resurfacing patients are rarely reported injuries. According to a large cohort follow up study done on 3076 Birmingham hip resurfacing, the prevalence of neck of femur fractures was found to be 1.1%^[1]. Hip resurfacing arthroplasty has been gaining popularity in recent years and is usually used for young patients with hip arthritis with physically demanding jobs as its advantages include less bone resection, lower dislocation rates, and possible lower wear and long term survival rate^[2]. Complications associated with the procedure include femoral neck fractures particularly intra operative subcapital fractures related to operative technique and range around 0.5-4%^[3-6].

However other patterns including intertrochanteric and subtrochanteric are also seen following trivial trauma to the prosthetic hip. The complex fracture pattern along with the associated osteoporosis in the geriatric population makes the surgical management challenging. Various management options include conservative^[7], internal fixation using proximal femoral nail^[8], cancellous cannulated screws^[9], proximal femoral locking compression plate^[10], and revision to total hip arthroplasty. We present a case report of the use of proximal femoral nail with trochanteric entry and dual fixation in neck for the treatment of intertrochanteric fracture in hip resurfacing patient. To our knowledge, there has been no case report described in the literature demonstrating successful long term follow up of the patient.

CASE REPORT

62 year old gentleman, a retired police personnel by profession presented after a fall on his left hip when he tripped over a step in his garden and presented with pain in left hip and inability to weight-bear. The preoperative X rays depicted below confirmed the complex injury with stable grade 1 (Boyd and Griffin) intertrochanteric fracture with bilateral resurfacing hip arthroplasty in situ (Figures 1 and 2). This was an isolated and closed injury with no associated neurovascular deficit. Prior to the fall, he used to mobilise independently and his Harris Hip score at two year follow up following BHR was 88 for right and 84 for left side. Past medical history including oral steroids intake in the past for Psoriasis and Hypertension.

The case was discussed in a multidisciplinary meeting in the department and it was decided to fix the fracture while retaining the prosthesis in an attempt to avoid major reconstruction and also considering the fact that he had no problems with respect to his resurfaced hip prior to the fall. There was no evidence of loosening or osteolysis of the BHR implants on preoperative X rays.

Patient was taken to theatre within 36 hours of admission. Satisfactory reduction was achieved intraoperatively after closed reduction on the traction table. The fracture was fixed using Expert Lateral Femoral Nail (Synthes) and two proximal locking screws were inserted, one superior and one inferior to the central peg of BHR femoral component. Care was also taken to avoid drilling near the prosthesis so that the prosthesis fixation would not be jeopardized.

Post operatively he was allowed to mobilise without any weight bearing restrictions and he was discharged on 3rd postoperative day with no complications. Post operative radiographs taken on day 2 were satisfactory (Figures 3 and 4). He made a successful recovery and within 6 months he had returned to his normal level of activities. Examination of hip at follow up showed a painless range of movement equal to that of his other hip. Radiographs at 6 month follow up confirmed the healing of the fracture site (Figures 5 and 6).

Figures 1 and 2 show pre op images with fracture while figures 3 and 4 show immediate post operative pics while 5 and 6 show union

of fracture at 6 months.

DISCUSSION

Although an intertrochanteric fracture is a very common injury it is extremely unusual to have this in a hip resurfacing patient. Various management options include nonoperative, internal fixation and revision arthroplasty. The choice depends on the fracture pattern and physiological status of the patient. It is always a surgical dilemma to whether retain a well fixed resurfacing implant with stable internal fixation of the fracture or to revise to total hip arthroplasty. Annig *et al*^[8] reported good results following intramedullary fixation along with cerclage wires in their case report of a patient with a comminuted fracture of the proximal femur with birmingham hip resurfacing implant in situ. Whittingham-Jones^[10] reported fixation of a subtrochanteric fracture femur around a hip resurfacing in a 32 year old female following a road traffic accident fixed with non locking broad AO DCP. They felt using an intramedullary nail could cause further comminution or could have inadequate fixation in the femoral neck due to fixed angulation of locking screws of the nail being precluded by the stem of the resurfacing implant. However, we did not encounter any of the above problems during the procedure.

We describe an alternative technique that could be considered as a

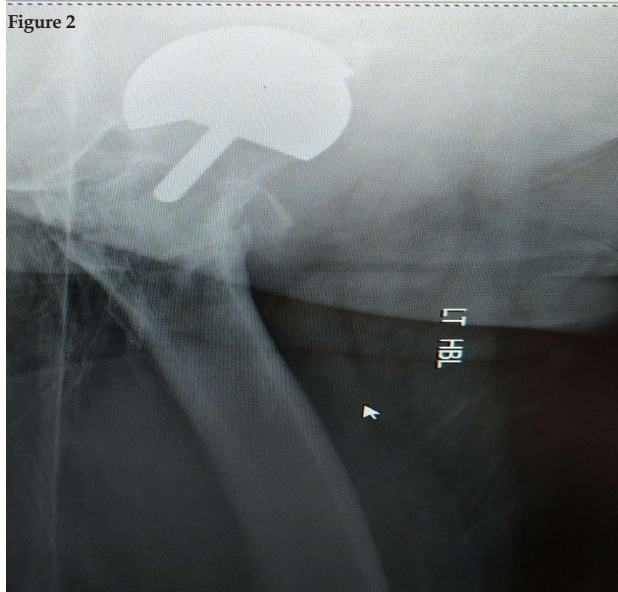
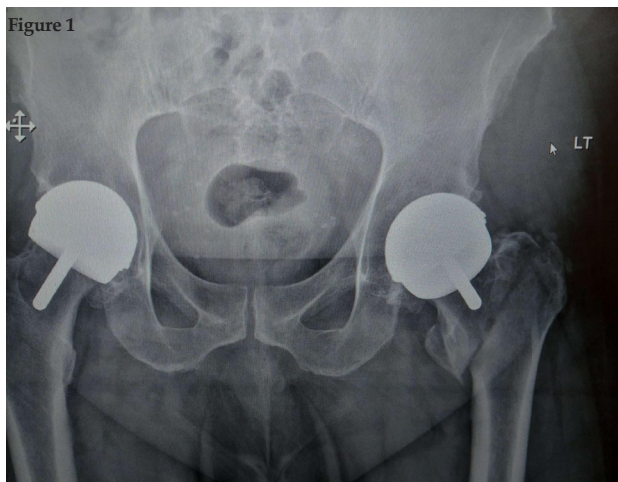


Figure 1 and 2 Preoperative AP and Lateral depicting inter trochantric fracture left hip.

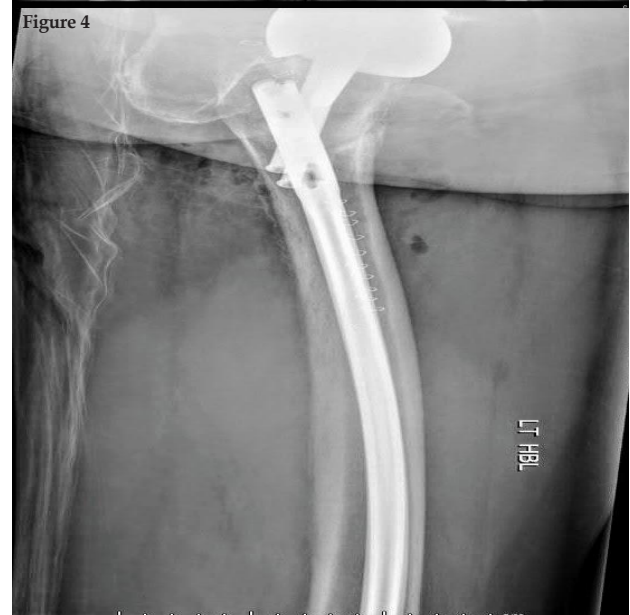
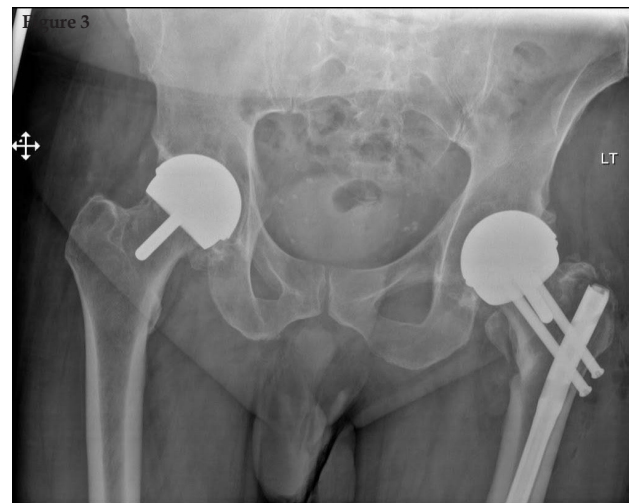
Figure 3 and 4 depict immediate post operative pictures.

method of choice for internal fixation due to inherent advantages of an intramedullary nail over plating, which include early full weight bearing mobilisation and less blood loss and early recovery. We feel the success of the technique relies on achieving stable and near anatomic reduction of fracture and offers clear advantage in dealing with unstable intertrochanteric fracture with comminution or reverse oblique pattern. It also allows preservation of bone stock and retention of previous well functioning prosthesis.

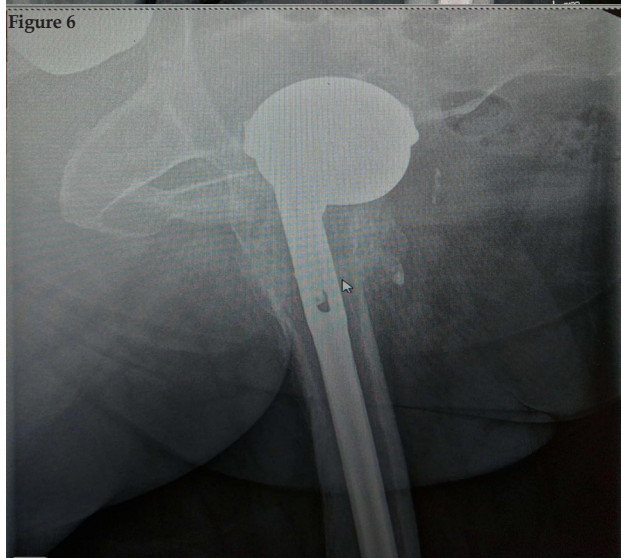
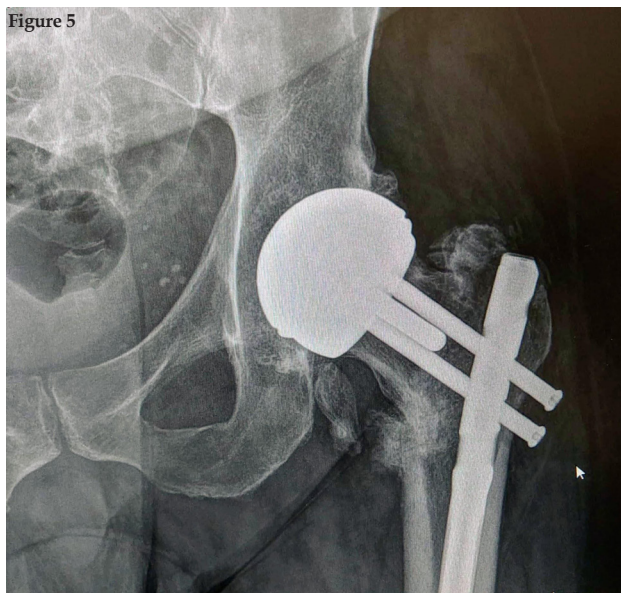


Figure 5 and 6 depict 6 month follow up pictures with union at fracture site.

CONCLUSION

Proximal femoral nail can be considered an option in treating intertrochanteric periprosthetic fractures in the presence of a Birmingham hip resurfacing implant. With meticulous preoperative planning and precise attention to the surgical technique, favourable results can be achieved to manage these challenging fractures.

REFERENCES

1. Matharu GS, McBryde CW, Revell MP, Pynsent PB. Femoral neck fracture after Birmingham Hip Resurfacing Arthroplasty: prevalence, time to fracture, and outcome after revision. *J Arthroplasty.* 2013;28(1):147-153. [PMID: 22819379]; [DOI: 10.1016/j.arth.2012.04.035].
2. Daniel J, Pynsent PB, McMinn DJ. Metal-on-metal resurfacing of the hip in patients under the age of 55 years with osteoarthritis. *J Bone Joint Surg Br.* 2004;86(2):177-184. [PMID: 15046429]; [DOI: 10.1302/0301-620x.86b2.14600].
3. Marker DR, Seyler TM, Jinnah RH, Delanois RE, Ulrich SD, Mont MA. Femoral neck fractures after metal-on-metal total hip resurfacing: a prospective cohort study. *J Arthroplasty.* 2007;22(7 Suppl 3):66-71. [PMID: 17919597]; [DOI: 10.1016/j.arth.2007.05.017].
4. Zustin J, Krause M, Breer S, et al. Morphologic analysis of periprosthetic fractures after hip resurfacing arthroplasty. *J Bone Joint Surg Am.* 2010;92(2):404-410. [PMID: 20124068]; [DOI: 10.2106/JBJS.H.01113].
5. Steffen RT, Foguet PR, Krikler SJ, Gundle R, Beard DJ, Murray DW. Femoral neck fractures after hip resurfacing. *J Arthroplasty.* 2009;24(4):614-619. [PMID: 18555654]; [DOI: 10.1016/j.arth.2008.04.008].
6. Shimmin AJ, Back D. Femoral neck fractures following Birmingham hip resurfacing: a national review of 50 cases. *J Bone Joint Surg Br.* 2005;87(4):463-464. [PMID: 15795193]; [DOI: 10.1302/0301-620X.87B4.15498].
7. Mauffrey C. Intertrochanteric fracture below Birmingham Hip Resurfacing: successful non-operative management in two cases. *Injury.* 2009;40(3):338-339. [PMID: 19243777]; [DOI: 10.1016/j.injury.2008.10.040].
8. Aning J, Aung H, Mackinnon J. Fixation of a complex comminuted proximal femoral fracture in the presence of a Birmingham hip resurfacing prosthesis. *Injury.* 2005;36(9):1127-1129. [PMID: 15979622]; [DOI: 10.1016/j.injury.2005.02.011].
9. Kutty S, Pettit P, Powell JN. Intracapsular fracture of the proximal femur fracture after hip resurfacing treated by cannulated screws. *J Bone Joint Surg Br.* 2009;91(8):1100-1102. [PMID: 19651844]; [DOI: 10.1302/0301-620X.91B8.22334].
10. Whittingham-Jones P, Charnley G, Francis J, Annapureddy S. Internal fixation after subtrochanteric femoral fracture after hip resurfacing arthroplasty. *J Arthroplasty.* 2010;25(2):334.e1-334.e3344. [PMID: 19056223]; [DOI: 10.1016/j.arth.2008.10.015].