

## Management of Vertebral Compression Fractures Using a Titanium Expandable Device and a Demineralised Bone Matrix Graft

Ali Alhaddad<sup>1</sup>, MB, BCh, BAO (NUI, RCSI); Mahdi Bassi<sup>2</sup>, MBBS

1 Orthopaedic Surgery, National Guard Hospital, Soliman Fakeeh Hospital, Jeddah, Saudi Arabia;

2 FRCS Canada, fellowship AOspine, Head of Orthopaedic Department, Saudi Arabia.

**Conflict-of-interest statement:** The author(s) declare(s) that there is no conflict of interest regarding the publication of this paper.

**Open-Access:** This article is an open-access article which was selected by an in-house editor and fully peer-reviewed by external reviewers. It is distributed in accordance with the Creative Commons Attribution Non Commercial (CC BY-NC 4.0) license, which permits others to distribute, remix, adapt, build upon this work non-commercially, and license their derivative works on different terms, provided the original work is properly cited and the use is non-commercial. See: <http://creativecommons.org/licenses/by-nc/4.0/>

**Correspondence to:** Ali Alhaddad, Orthopaedic Surgery, National Guard Hospital, Soliman Fakeeh Hospital, Jeddah, Saudi Arabia; Email: [alil\\_nz@hotmail.com](mailto:alil_nz@hotmail.com)

Received: August 18, 2020

Revised: January 30, 2021

Accepted: February 2 2021

Published online: February 28, 2021

### ABSTRACT

**OBJECTIVE:** This study was conducted to evaluate the efficacy of using expandable mesh with DBM bone graft in short- and long-term treatment clinically, back to normal activities and complications.

**QUESTIONS/PURPOSES:** An alternative treatment with less cement related complication to treat vertebral compression fractures.

**Patients and Methods:** Forty patients with thoracolumbar vertebral compression fractures underwent this operation over 2 years period, at one centre under one surgeon at Soliman Fakeeh Hospital. We evaluated pain relief and improvement of daily activity function using visual analogue scale (VAS) score and Oswestry disability index (ODI) system pre-, post and one year after the operation. At the same times, we also assessed kyphotic angles (KA) and Cobb angle (CA) using plain x-rays and computed tomography (CT).

**RESULTS:** We found significant improvement of daily activity

functions and pain relief as we found a statistically significant decrease in VAS score when compared pre-operatively ( $8.80 \pm 1.13$ ) to immediately and two years post-operatively respectively ( $4.2 \pm 1.27$ ,  $1.18 \pm 1.36$ ,  $p = 0.018$ ). There was also a statistically significant decrease in ODI system scores when pre-operative scores ( $91.35\% \pm 2.24\%$ ) were compared to immediate and two years post-operative scores ( $40.3\% \pm 16.43\%$ ,  $29.40\% \pm 16.63\%$ ,  $p = 0.012$ ). Both KA and CA showed significant improvements postoperatively (KA  $20.33 \pm 6.16^\circ$  to  $10.55 \pm 4.11^\circ$ ,  $p = 0.002$ / CA  $10.5^\circ \pm 4.273^\circ$  to  $7.12^\circ \pm 2.99^\circ$ ,  $p = 0.001$ ). There was no statistically significant difference in terms of KA and CA during the follow-up period ( $p > 0.05$ ).

**Conclusions/Clinical Relevance:** This approach is effective in treatment of such cases providing better quality of life by immediate and sustained relief of pain and less hospital stay. It also improves both KA and CA immediately after the operation with maintenance of stable radiological progression through the period of follow-up. Also, it is also a safe procedure.

**Key words:** Fractures; Osteoporosis; Spine; Compression fracture

© 2021 The Author(s). Published by ACT Publishing Group Ltd. All rights reserved.

Alhaddad AI, Bassi M. Management of Vertebral Compression Fractures Using a Titanium Expandable Device and a Demineralised Bone Matrix Graft. *International Journal of Orthopaedics* 2021; 8(1): 1436-1440 Available from: URL: <http://www.ghrnet.org/index.php/ijo/article/view/2973>

### INTRODUCTION

Vertebral compression fractures (VCF) are becoming increasingly common in individuals over 70 years old. In fact, 20% of elderly people (over 70) are affected. In addition, it has been shown that 20% of over the age of 50 have suffered from a vertebral fracture<sup>[4]</sup>, resulting in direct social, economic, physical and psychological consequences to the patients and their families<sup>[2]</sup>. In patients with no neurological deficits, the standard management of VCF consists of pain management through vertebral body stabilisation. In these cases, associated back pain usually remains incapacitating for a few weeks and, though it gradually diminishes in severity, pain remains intense for 2-3 months<sup>[8]</sup>.

VCF management strategies include non-invasive options, such as painkillers or braces. These approaches have the potential to eventually facilitate the control of pain in less than 20%-25% of patients. Well-established techniques involving minimally invasive procedures such as Vertebro-plasty and Kypho-plasty, are also an option<sup>[2]</sup>. As these treatment strategies are cement-based, they carry an increased risk of both extra-vertebral cement leakage and re-fracture, which occur in 65%<sup>[1]</sup> and 63%<sup>[7]</sup> of patients, respectively. Another disadvantage of cement-based treatment modalities is the low capacity of the required polymethyl methacrylate (PMMA) cement to be absorbed. This results in an implant that remains rigid throughout the duration of its use, which is a characteristic that can promote adjacent vertebral fractures.

Previously, the effects of extensive filling of a vertebral body with cement, and whether they have a negative impact on vertebral healing, have not been well established. Cement-based techniques have been associated with several procedural problems including the loss of the restored height (4%) and contributing to the occurrence of new fractures (26%)<sup>[6]</sup>. In order to overcome these disadvantages, we used expandable titanium mesh cages with demineralised bone matrix (DBM) bone grafts to manage cases of vertebral compression fractures. DBM is allograft bone that has been decalcified to produce a product consisting of both collagen and non-collagenous proteins with fusion rates produced at one-year or greater post-surgery of 54% and 74% for the allograft/DBM and auto-graft groups, respectively.

DBM technology is currently being used by some orthopaedic surgeons to repair bones broken by injuries, tumours, and other defects. This study, however, demonstrates the effectiveness of the treatment of fractured vertebrae using bone graft technology fitted with implants using a combination of clinical assessment and imaging. The surgery accurately and efficiently healed fractured vertebrae, which can be used to improve the condition of an injured patient. It can also increase the discharge rates in clinics, since bone heal rapidly when DBM technology is used relative to other clinical methods. This clinical trial was conducted to evaluate the suitability of using titanium mesh with bone grafts as an alternative to cement-based treatments in the management of fractured vertebrae.

## METHODS AND MATERIALS

A population of 40 total patients was included in the study. Adults of both genders who presented to an emergency department or clinic with vertebral fractures of one or two over a period of two years were included. Inclusion criteria for the study included the presence of persistent, painful, dorsal or lumbar vertebral injury (confirmed using X-ray and MRI) classified as A1.1, A1.2, or A1.3 fractures of the at the thoracic and/ or lumbar spine and intractable pain that persisted two-weeks after the administration of conservative treatment. Exclusion criteria included neurological deficits, spinal canal involvement due to posterior vertebral wall fracture and sensitivity to DBM. The mean age of patients (29 males, 11 female) was  $43.58 \pm 13.8$  years. The average duration of symptoms was 7.6 weeks (ranging from 2 to 16 weeks). Twenty-four patients presented after experiencing significant trauma that resulted in fracture and sixteen patients presented with osteoporotic fractures.

The radiological assessment of patients was performed using standing anterior-posterior and lateral radiographs at six distinct time points. The first scans were taken pre-surgery, while the following six were taken post-operatively, and one-month, three-months, six-months, one-year and two-years post-operatively. Moreover, an additional CT scan was used to evaluate the condition and progression of healing. We assessed changes in sagittal alignment of the posterior

(Hp), middle (Hm), and anterior vertebral body height (Ha) compared with defined points within fractured vertebra (Figure 1A-F). The sagittal index (SI), which was used as a measure of the segmental kyphosis of one spine segment, was calculated from the posterior and anterior height.

The kyphotic angle (KA) of the vertebral body was measured using means of the intersections connecting points AE and BF. The Cobb angle was used as a measure of the sagittal alignment of the fracture. The angle was determined from the intersection of the tangents of endplates of the corresponding vertebral bodies superior and inferior to the injury. We assessed kyphotic angles (KA) and Cobb angle (CA) pre-operatively, post-operatively, and after one year of follow-up. The clinical follow-up included the evaluation of pain using a visual analogue scale (VAS) pre-, post- one-year and two-years post-surgery. The Oswestry disability index was also used as standardised subjective and functional assessment of the spine<sup>[29]</sup> pre-, 6 weeks post-, one-year post and two-year-surgery<sup>[5]</sup> (Figure 1).

The surgical procedure aimed to reduce and stabilise the collapse of the vertebral body. To accomplish this, patients were brought into a prone position on a Jackson's table while ensuring that the thoracolumbar area was neutral or slightly extended to facilitate the expansion of the vertebral body. With the standard preparations and drappings, an 0.8-1.4 cm dorso-lateral incision was made vertically, 0.5 mm lateral of the boarder of the pedicle shadow after the fluoroscopic identification of the injured vertebra using orthogonal views. Using a targeting needle, two K-wires were placed across the pedicle and into the vertebral body under fluoroscopic control. In this step the tip of the wire was positioned away from the upper end plate, if possible.

The K-wire passed through two dilators, which was followed by cannulated drilling of the pathway into the anterior third of the vertebral body. A titanium implant delivery system facilitated the insertion of two titanium mesh cages, which had been selected from three available sizes (4.5, 5.5 and 6.5 mm) based on preoperative planning using preoperative CT scans. A mechanical actuation system was used to deploy expandable cages in a controlled manner, and the same probes used to pass the cement in vertebroplasty procedures were used for grafting an average of 3 mm bone to each portal. Postoperatively, full weight bearing movements were immediately allowed in accordance with the pain threshold of the patient. Patients were instructed to avoid bending forward for the three months following surgery. In addition, we used calcium and vitamin D to initiate the healing process.

The study was approved by the review board of our institution and is in accordance with the declaration of Helsinki and Good Clinical Practice Guidelines. Further, written informed consent was obtained from all patients enrolled in this study.

To perform data analyses, the IBM SPSS Statistics 20 programme was used. A confidence interval (CI) of 95% ( $p < 0.05$ ) was used as the limit of statistical significance. T-test and chi-square test were conducted (Figure 2).

## RESULTS

This study was conducted using forty adult patients ( $43.58 \pm 13.8$  years) of both gender with vertebral compression fractures to evaluate the efficacy of the minimally invasive implantation of an expandable device and the injection of DBM. The assessment of the effectiveness of treatment utilised variables such as time required to return to normal activity post-surgery, mean hospital stay and radiological and functional measures. The mean duration that patients remained in the hospital after receiving the operation was  $51 \pm 8.2$  h. The mean duration to return to mild work was  $2.3 \pm 1.1$  weeks,  $6.3 \pm 2.4$  weeks

for soft work and  $12.3 \pm 2.7$  weeks were required, on average, before returning to work fully.

**Radiological Findings**

Successful vertebral body restoration was demonstrated using KA measurements, revealing significant ( $p = 0.002$ ) improvements from  $20.33^\circ \pm 6.16^\circ$  ( $10^\circ$ - $27^\circ$ ) to  $10.55^\circ \pm 4.11^\circ$  ( $2^\circ$ - $26^\circ$ ). Throughout the duration of follow-up, an insignificant ( $p > 0.05$ ) loss of attained restoration was observed  $10.81^\circ \pm 4.61^\circ$  ( $5^\circ$ - $26^\circ$ ) (Figure 1). Intraoperative vertebral body restoration was achieved regarding the height with respect to body angle and decreases in the kyphotic angulation of adjacent vertebral segments.

The Cobb angle, a parameter assessing the sagittal alignment of the fracture, improved from  $10.5^\circ \pm 4.27^\circ$  ( $1^\circ$ - $20^\circ$ ) to  $7.12^\circ \pm 2.99^\circ$  ( $4^\circ$ - $14^\circ$ ). Further, decreases in kyphosis were observed ( $p = 0.012$ ). Throughout the duration of follow-up, a slight and insignificant return of kyphosis was observed ( $7.13^\circ \pm 2.81^\circ$ ;  $4^\circ$ - $14^\circ$ ;  $p > 0.05$ ) (Figure 3).

Follow-up X-rays and CT scans two-years post-surgery revealed good bony healing in all patients and no implant dislocations were observed. Throughout the duration of the study, we did not detect any vertebral fractures adjacent to initially injured vertebrae (Table 1).

**Functional Results**

Pain progress, as evaluated by VAS, was  $8.80 \pm 1.13$  (7-10) preoperatively and improved significantly to  $4.2 \pm 1.27$  (3-6) postoperatively. A further significant improvement was observed two-years post-surgery ( $1.18 \pm 1.36$ ; 0-5;  $p = 0.018$ ) (Figure 1). The subjective and functional spinal assessment using Oswestry disability index (ODI) system scores, revealed a statistically significant decreases when pre-operative scores ( $91.35\% \pm 2.24\%$ ) were compared to immediate and two year post-operative scores ( $40.3\% \pm 16.43\%$ ;  $29.40\% \pm 16.63\%$ ;  $p = 0.012$ ) (Table 2).

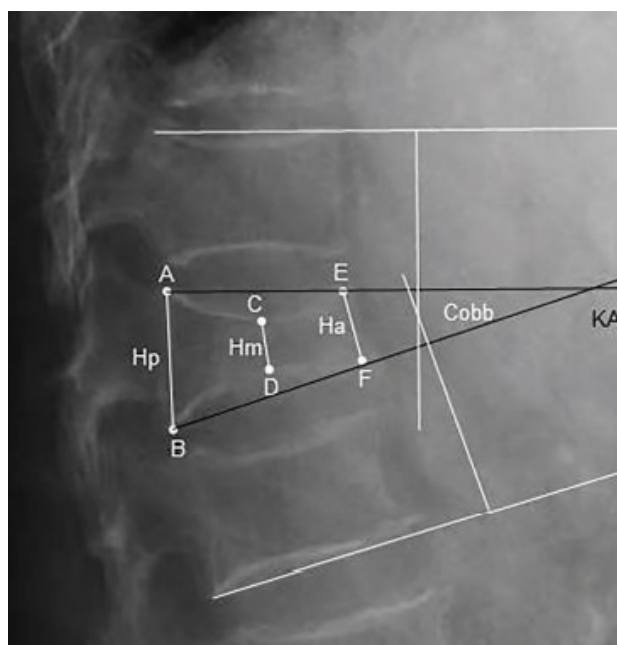
**DISCUSSION**

The cementless stabilisation method of surgical repair using an expandable titanium device with a DBM bone graft provided an adequate level of primary reduction and stable fixation using a minimally invasive, percutaneous method. Pain relief and quality of life measures were superior to those produced using traditional, cement-based methods that produce many complications including cement loss or leakage within the disc or epidural spaces of severe types of fractures.

Our study showed that the vertebral body was restored to its initial height. This was shown using KA measurements, in which pre-surgery values of  $20.33^\circ \pm 6.16^\circ$  ( $10^\circ$ - $27^\circ$ ) were significantly improved post-surgery, producing an average angle of  $10.55^\circ \pm 4.11^\circ$  ( $2^\circ$ - $26^\circ$ ;  $p$

$= 0.002$ ). These findings were similar to those determined by Eschler et al, who reported that the average KA angle for adjacent vertebral segments post-surgery were  $10.7^\circ \pm 3.0^\circ$  ( $7^\circ$ - $21^\circ$ ). The value was significantly lower than the average angle of  $14.5^\circ \pm 2.2^\circ$  ( $6^\circ$ - $19^\circ$ ) measured pre-surgery. A slight and insignificant ( $p > 0.05$ ) loss of the observed reduction occurred, where the mean angle one-year post-surgery was  $10.81^\circ \pm 4.61^\circ$  ( $5^\circ$ - $26^\circ$ ), in comparison to  $12.1^\circ \pm 2.9^\circ$  ( $3^\circ$ - $21^\circ$ ), which reported in another study. Another study by Eschler et al[3] showed that KA improved significantly ( $p < 0.001$ ) when comparing pre-operative angles of  $13.7^\circ \pm 1.2^\circ$  ( $2^\circ$ - $21^\circ$ ) with post-operative values of  $7.4^\circ \pm 0.8^\circ$  ( $2^\circ$ - $17^\circ$ ), with a slight loss of reduction of improvement observed after an extended period producing a mean angle of  $8.3^\circ \pm 1.1^\circ$  ( $2^\circ$ - $18^\circ$ ).

The Cobb angle as parameter for the sagittal alignment of the level of fracture was also significantly improvement ( $p = 0.012$ ) from  $10.5^\circ \pm 4.27^\circ$  ( $1^\circ$ - $20^\circ$ ) pre-operatively to  $7.12^\circ \pm 2.99^\circ$  ( $4^\circ$ - $14^\circ$ ) post-operatively. Eschler et al reported a similar improvement from  $10.1^\circ \pm 1.8^\circ$  ( $6^\circ$ - $14^\circ$ ) pre-surgery to  $8.3^\circ \pm 1.2^\circ$  ( $5^\circ$ - $13^\circ$ ) post-surgery (28)<sup>[3]</sup>. Other work showed that the Cobb angle improved significantly ( $p$



**Figure 1** Radiological measurements of a fractured vertebral body of the thoracolumbar spine. Height in the sagittal alignment is defined using the six points shown (A-F) and was used to produce cobb and vertebra body kyphotic angle values. A and B are on the most dorsal-superior and dorsal-inferior endplate margins, respectively. E and F correspond to the most anterior-superior and anterior-inferior margins, respectively. C and D are on the midpoint of a perpendicular line drawn from A to E and B to F on the superior and inferior vertebral endplates. Resulting Cobb and vertebra body kyphotic angle.

**Table 1** Showing the radiological findings pre-, post and one year after the operation.

	KA Preoperatively	KA Postoperatively	KA two year after the operation	CA Preoperatively	CA Postoperatively	CA two year after the operation
Mean	20.33°	10.55°	10.81°	10.50°	7.12°	7.13°
Standard Deviation	6.16°	4.11°	4.61°	4.27°	2.99°	2.81°
Range	10-27°	2-26°	5-26°	1-20°	4-14°	5-14°

**Table 2** Showing the functional evaluation results pre-, post and one year after the operation.

	ODI Preoperatively	ODI Postoperatively	ODI two year after the operation	VAS Preoperatively	VAS Postoperatively	VAS two year after the operation
Mean	91.35%	40.30%	29.40%	8.8	4.2	1.18
Standard Deviation	2.24%	16.43%	16.63%	1.13	1.27	1.36
Range	86%-94%	26%-80%	20%-72%	7-10	3-6	0-5

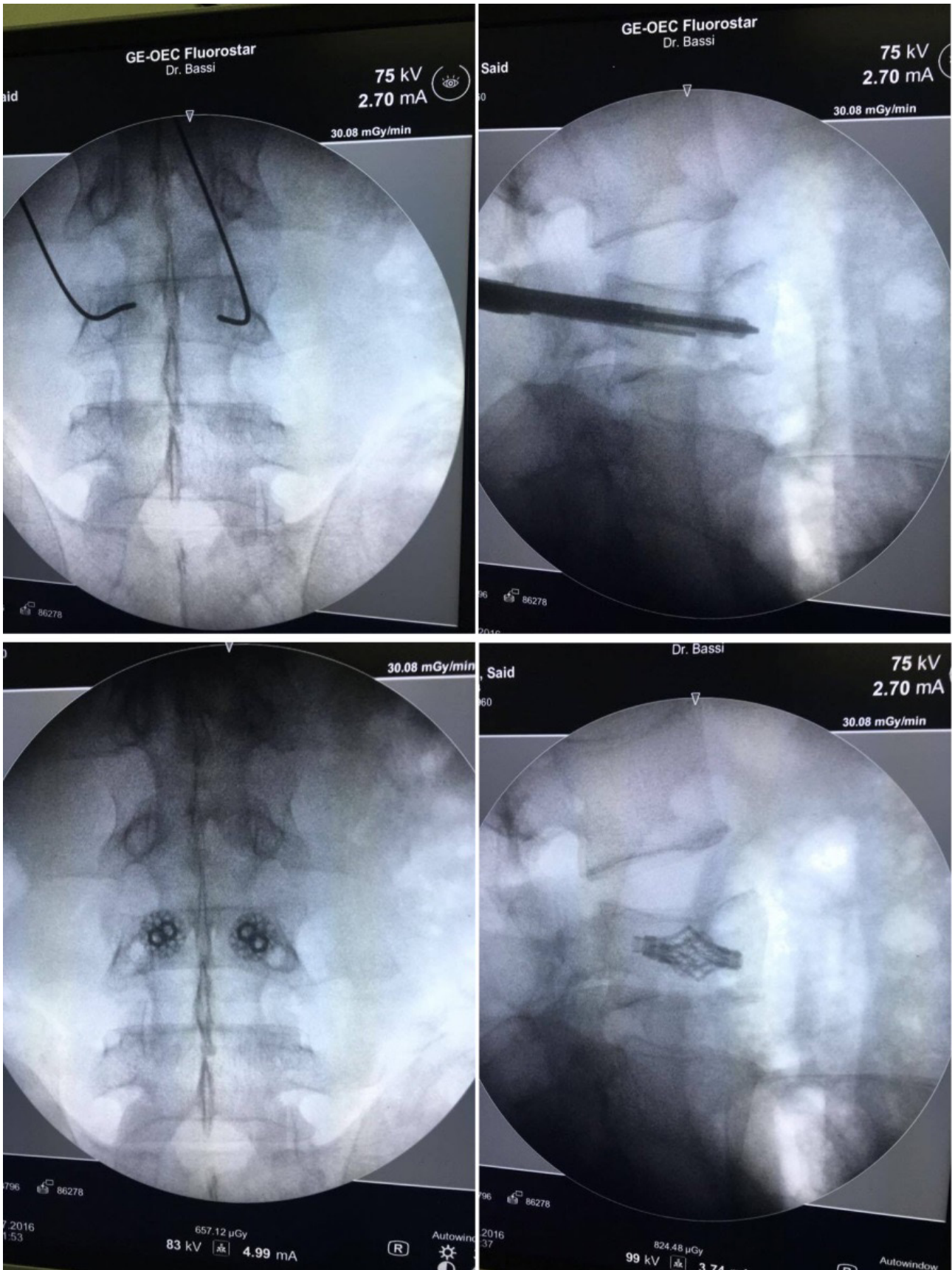


Figure 2 Steps of the surgical technique include (A) the insertion of the guide wire after positioning using the insertion of the guide needle, (B) drilling and cage insertion and (C) cage expansion.

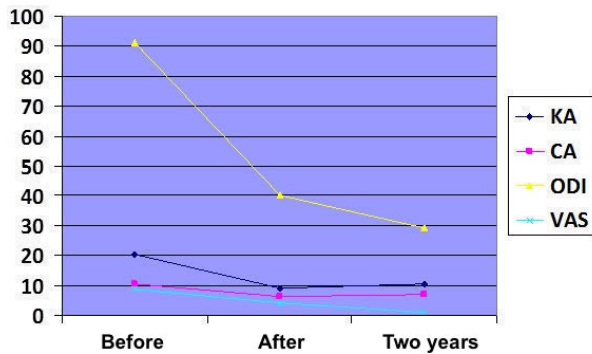


Figure 3 Radiological and functional evaluation of patient progress throughout the duration of the study.

< 0.002) from  $9.6 \pm 1.1^\circ$  ( $2^\circ$ - $28^\circ$ ) pre-surgery to  $6.0^\circ \pm 0.9^\circ$  ( $1^\circ$ - $22^\circ$ ) post-surgery with final follow-up value of  $8.7^\circ \pm 1.7^\circ$  ( $1^\circ$ - $22^\circ$ ) (30<sup>[3]</sup>). While changes observed within our study throughout the duration of follow-up were insignificant ( $p > 0.05$ ), rekyphosis was observed  $7.13^\circ \pm 2.81^\circ$  ( $4^\circ$ - $14^\circ$ ). Other reports examining angulation six-28- and months post-surgery obtained values of  $8.9^\circ \pm 1.1^\circ$  ( $5^\circ$ - $12^\circ$ ) and  $10.7^\circ \pm 1.3^\circ$  ( $5^\circ$ - $13^\circ$ ), respectively.

Our functional assessment of the surgery showed that VAS improved significantly from  $8.80 \pm 1.13$  (7-10) pre-operatively to  $4.2 \pm 1.27$  (3-6) post-operatively in comparison to  $8.8 \pm 3.5$  (8-10) preoperatively which improved to  $4.8 \pm 6.4$  (3-7) on the first day post-surgery as determined by Eschler *et al*<sup>[3]</sup>. A further significant improvement ( $p = 0.018$ ) was produced in our study during the follow-up period two-years post-surgery in which VAS values produced were  $1.18 \pm 1.36$  (0-5). This finding was in accordance with those reported by Eschler *et al* in which final observed VAS values were  $2.8 \pm 7.5$  (1-5) (28)<sup>[4]</sup>. A different study, also conducted by Eschler *et al*, showed that pre-operative VAS scores of  $7.6 \pm 0.5$  (2-10) improved significantly ( $p < 0.001$ ) to  $5.7 \pm 0.6$  (0-9) directly post-surgery and further decreased to  $2.6 \pm 0.4$  (0-6) after extended follow-up<sup>[3]</sup>.

Pre-operative ODI values of  $91.35\% \pm 2.24\%$  statistically significantly ( $p = 0.012$ ) decrease of to  $40.3\% \pm 16.43\%$  immediately post-surgery and continued to decrease, resulting in a mean ODI of  $29.40\% \pm 16.63\%$  determined two-years post-surgery. These results are similar to findings of Eschler *et al*, who reported that the ODI confirmed moderate disability with  $26.3\% \pm 8.1\%$  (10-53%) throughout a six-month follow-up period, which further declined to  $20.0\% \pm 3.6\%$  (6-30%) at final follow-up (28)<sup>[4]</sup>.

When the proposed surgical technique was compared to other methods in terms of cost effectiveness, it was found that the cost of the proposed study was about \$6,600 while the cost of kyphon and truss were \$5,300 and \$1,300 respectively<sup>[10]</sup>. (31) This difference in cost, however, is offset when the early recovery and rapid return to work of patients enrolled in our study is compared to the recovery periods required in patients receiving other methods of management.

Our study does have some limitations. First, the analysis of the cost effectiveness of the studies should be compared using a more appropriate model. Next, there was likely a level of selection bias and data collection error. Finally the study was not randomised or controlled

and was relatively short-term. Additional work will be required to overcome these limitations.

In Conclusion, use of a minimally invasive, expandable-device with the injection of DBM results in significantly relieving pain and enhancing the quality of life of patients, while minimalizing the risk of complication from the procedure. These features make the procedure a comparable alternative to established traditional cement-based techniques for the treatment of vertebral compression fractures.

## REFERENCES