

Expression of Cathepsin K by Wear Debris Histiocytes in Patients with Total Joint Prostheses

Anton Alexander Nolte Peterlin¹, MD; Charles M Lombard², MD

1 Department of Orthopaedic Surgery, Herlev Hospital, Capital Region, Denmark;

2 Department of Pathology, El Camino Hospital, Mountain View, CA, United States.

Conflict-of-interest statement: The author(s) declare(s) that there is no conflict of interest regarding the publication of this paper.

Open-Access: This article is an open-access article which was selected by an in-house editor and fully peer-reviewed by external reviewers. It is distributed in accordance with the Creative Commons Attribution Non Commercial (CC BY-NC 4.0) license, which permits others to distribute, remix, adapt, build upon this work non-commercially, and license their derivative works on different terms, provided the original work is properly cited and the use is non-commercial. See: <http://creativecommons.org/licenses/by-nc/4.0/>

Correspondence to: Anton Alexander Nolte Peterlin, Department of Orthopaedic Surgery, Herlev Hospital, Capital Region, Denmark.

Email: a.peterlin@gmail.com

Received: August 28, 2020

Revised: December 5, 2020

Accepted: December 8 2020

Published online: February 28, 2020

ABSTRACT

AIM: To determine whether Cathepsin K, a cysteine protease and key in bone remodeling, is upregulated in wear debris histiocytes found in association with prosthetic joints and in lymph nodes draining those joints as compared to histiocytes found in a variety of other disorders of bone, joints, and lymph nodes.

MATERIALS AND METHODS: Histopathologic samples from 12 patients with wear debris associated pathologies and 13 control samples were examined for Cathepsin K expression. Leica Bond immunostainer with an antibody from Cell Marque was used in immunohistochemistry staining. Immunohistochemistry Cathepsin K H-scores were divided into three categories: negative, focally positive and nonfocally positive (homogenously diffuse).

RESULTS: Histiocytes from wear debris pathologies were all

homogenously diffuse, while control samples were negative. Known-group hypothesis testing was calculated using the Mann-Whitney U test. There was a significant difference in H-scores between known groups, with a p-value of 0.000011.

CONCLUSION: We demonstrated of the overexpression of Cathepsin K by wear debris histiocytes in comparison to histiocytes found in other bone, joint, and lymph node pathologies. The significance of the finding in the pathogenesis of prosthetic joint failure is discussed.

Key words: Wear debris; Total joint arthroplasty; Cathepsin K; Prosthetic joint failure; Aseptic loosening

© 2020 The Author(s). Published by ACT Publishing Group Ltd. All rights reserved.

Peterlin AAN; Lombard CM. Expression of Cathepsin K by Wear Debris Histiocytes in Patients with Total Joint Prostheses. *International Journal of Orthopaedics* 2020; 8(1): 1425-1430 Available from: URL: <http://www.ghrnet.org/index.php/ijo/article/view/2977>

INTRODUCTION

Total joint arthroplasty (TJA) is the most clinically successful and cost-effective surgical procedure for end stage osteoarthritis (OA^[1]). Compared to current TJAs, it is projected that by 2040, the primary total hip and knee arthroplasties (THA, TKA) will increase by 284% and 401% respectively^[2]. Risk factors for TJA failure and revisional surgery include young age and obesity. Young age is a known risk factor for increased periprosthetic osteolysis, and the risk of lifetime revision is up to 35%, while morbid obesity (BMI \geq 40) also carries a 5 times greater risk for focal osteolysis^[3-5]. Considering this evidence, the impact of increasing the number of primary TJAs and revisions will have extensive effects on the world healthcare and its economic burden.

TJA failure is a complex multifactorial process. Polymers such as polyethylene (PE) and polymethylmethacrylate (PMMA) as well as metals and ceramics are capable of initiating an adverse tissue reaction, orchestrated by cells of macrophage/monocyte lineages^[6]. They initiate proinflammatory responses, including the activation of the MAP kinase pathway, transcription factors (including NFkB), and suppressors of cytokine signaling, all of which mediate the recruit-

ment, migration, differentiation, and ultimately activation of bone-resorbing processes^[7]. Besides its expression in osteoclasts, Cathepsin K (CatK) has also been found in other bone and joint associated cells, including synovial fibroblasts and macrophages^[8,9]. CatK is a papain-like cysteine protease, with strong collagenolytic activity, which plays a central role in bone remodeling^[10]. There is evidence that wear debris represents a leading cause of periprosthetic osteolysis in failed TJAs with aseptic loosening and failure^[5,11]. Prosthetic implants undergo microtrauma to the weight bearing surfaces, producing microscopic fragments of wear debris. These particulates contribute to periprosthetic bone resorption, osteolysis, aseptic loosening, and prosthetic joint failure (PJF)^[1,12].

In this manuscript, we examine CatK stained histologic sections of wear debris pathologies involving joints and lymph node tissues and compare them to control histologic sections of a wide variety of other disorders involving the same organs. This study was designed to test our hypothesis that CatK is upregulated in wear debris histiocytes found in association with prosthetic joints and in lymph nodes draining those joints as compared to histiocytes found in a variety of other disorders of bone, joints, and lymph nodes. Finally, we discuss the significance of our findings with an emphasis on the role of this over-expression of CatK in the pathogenesis of PJF and with an exploration of possible future selective therapies with the aim of decreasing the incidence of TJA failure.

METHODS

The pathology files at El Camino Hospital were searched for wear debris-associated lymph node and joint pathologies. A variety of

other lymph node and joint non-wear debris-associated pathologies were chosen for comparison. Hematoxylin and eosin stained slides and CatK stained immunohistochemistry (IHC) slides were examined. CatK IHC stains were performed on the Leica Bond immunostainer with an antibody from Cell Marque, with retrieval conditions on the Leica Bond at ER2 for 20 minutes. CatK IHC was measured quantitatively with an H-score, divided into two parameters, the staining intensity (SI) and the proportion score (PS). The SI was graded on a scale of 0 to 3 (0 = no staining; 1 = minimal; 2 = moderate; 3 = strong). The PS was recorded on a scale of 0 to 100% (none = 0; <30% = 1; 30 - 60% = 2; >60% = 3). By multiplying intensity and percentage scores an H score (0-9) was calculated. H scores were broken into 3 categories. H-score of 0-2 was considered negative, H-scores 4, focally positive, and H-scores ≥ 6 , non-focally positive. Homogenous (diffuse) or heterogeneous CatK staining of histiocytes staining were also noted. Statistical analyses were performed using the Statistical Package for the Social Sciences (SPSS Version 25). The overall level of significance was set to $p < 0.05$ for this study. Known-group and hypothesis testing were calculated using the Mann-Whitney U test.

RESULTS

This study demonstrated distinctly different CatK staining results with regards to wear debris histiocytes in comparison to histiocytes in other non-wear debris pathologies. CatK staining results in histiocytes from both wear debris and control pathologies are shown in Table 1.

Wear debris pathologies included wear debris associated

Table 1 Descriptive characteristics of wear debris and control histiocyte immunohistochemistry staining.

Pathology	Site	Tissue Type	SP	SI	PS	H-score
Wear debris change	Pelvic	Lymph Node	He	3	3	9
Wear debris lymphadenopathy	Inguinal	Lymph Node	Ho	3	3	9
Wear debris associated osteolysis	Pelvic	Lymph Node	Ho	3	3	9
Wear debris associated changes	Pelvic	Lymph Node	Ho	3	3	9
Wear debris change	Pelvic	Lymph Node	Ho	2	3	6
Wear debris associated osteolysis	L. knee Osteolytic lesion	Bone	Ho	3	3	9
Wear debris changes	R. knee failed prosthesis	Bone	Ho	3	3	9
Wear debris changes	R. knee failed prosthesis	Bone	Ho	3	3	9
Wear debris associated changes	R. foot	Bone	Ho	3	2	6
Wear debris changes	L. knee failed prosthesis	Synovium	Ho	3	3	9
Wear debris changes	R. knee failed prosthesis	Synovium	Ho	3	3	9
Wear debris associated changes	L. knee failed prosthesis	Synovium	Ho	2	3	6
Controls						
Kikuchi's lymphadenitis	Cervical	Lymph Node	He	1	1	1
Anthracotic change; benign	Mediastinal	Lymph Node	Ho	0	0	0
Benign sinus histiocytes	Peripancreatic	Lymph Node	Ho	0	0	0
Sinus histiocytosis	Pelvic	Lymph Node	Ho	0	0	0
Degenerative joint disease	L. femoral head	Bone	He	1	2	2
Osteomyelitis	R. great toe	Bone	He	2	1	2
Degenerative joint disease	L. knee	Bone	He	2	1	2
Osteomyelitis	L. 5th metatarsal head	Bone	Ho	1	1	1
Rheumatoid arthritis	R. knee	Bone	He	1	1	1
Degenerative joint disease	R. femoral head	Bone	Ho	0	0	0
Avascular necrosis	L. femoral head	Bone	Ho	0	0	0
Giant cell tumor of tendon sheath	R. 5th finger	Synovium	He	1	1	1
Rosai-Dorfman disease	Soft tissues of back	Soft Tissue	Ho	0	0	0

Abbreviations: Heterogenous (He); Homogenous; (Ho); Left (L); Right (R), Staining Pattern (SP); Staining Intensity (SI); Porportion Score (PS).

osteolysis, lymphadenopathy and synovitis. Control cases were from various bone, joint and degenerative diseases as well as lymph node conditions where inflammatory processes and associated histiocytes are known to be prominent. Wear debris histiocytes display strong diffuse/homogenous IHC CatK staining (brown pigment in histological specimens), all of which are diffusely and strongly positive. Failed TJA synovitis with histiocytic infiltrate methyl acrylate (red arrow), titanium wear debris, and diffuse/homogeneous, H-score 9, positive CatK staining of wear debris histiocytes were consistent findings (Figure 1).

The same strong diffuse homogenous CatK staining of histiocytes is seen in wear debris associated lymphadenopathy, including rare titanium fragments and prominent numbers of plasma cells, red and yellow arrows respectively (Figure 2). Comparatively, non-wear debris histiocytes displayed weak and non-specific CatK staining. As seen in Figure 4, with degenerative change in the wall of cysts (red arrow), H-score 2, low intensity CatK staining of histiocytes, with only multinucleated osteoclasts (blue arrows) staining homogeneously for CatK. Figure 3 displays again the complete absence of CatK staining in reactive sinus histiocytosis, H-score 0. Statistically, the Mann-Whitney U test confirms a significant difference in H-scores between known groups, with a p-value of 0.000011. The median CatK H-score for wear debris histiocytes is 9. All wear debris cases are diffusely positive with an H-score of 6 or 9. Importantly, histiocytes from the various control cases have negative CatK staining with H-scores all under 2 (Figure 5). Seen in this figure

are each individual H-scores of wear debris (red) and the control groups (blue, orange and green), with each column representing the area between the 25th to 75th percentile distribution of each subgroup. Rosai-Dorfman disease is a typically a disease of the lymph nodes but as in our case, may involve the soft tissues. It may also cause joint disease and we have grouped it with synovium for visual representation.

DISCUSSION

This study demonstrates that the expression of CatK is increased in histiocytes in bone, synovium and lymph nodes from various wear debris associated pathologies. These pathologies, when identified associated with tissues from prosthetic joints are associated with prosthetic joint failure. This overexpression of CatK supports our hypothesis that wear debris histiocytes play an important role in prosthetic joint failure (PJF).

All wear debris cases were strongly positive for CatK (Table 1), while those from non-wear debris cases were all negative or only weakly positive. These other cases included a variety of pathologic conditions involving bones, joints and lymph nodes, where there are also prominent numbers of histiocytes. The differential expression of CatK between the wear debris histiocytes and histiocytes found in the other conditions tested is statistically significant. It is widely accepted that wear debris stimulates an immune response, and in this setting histiocytes play a central role

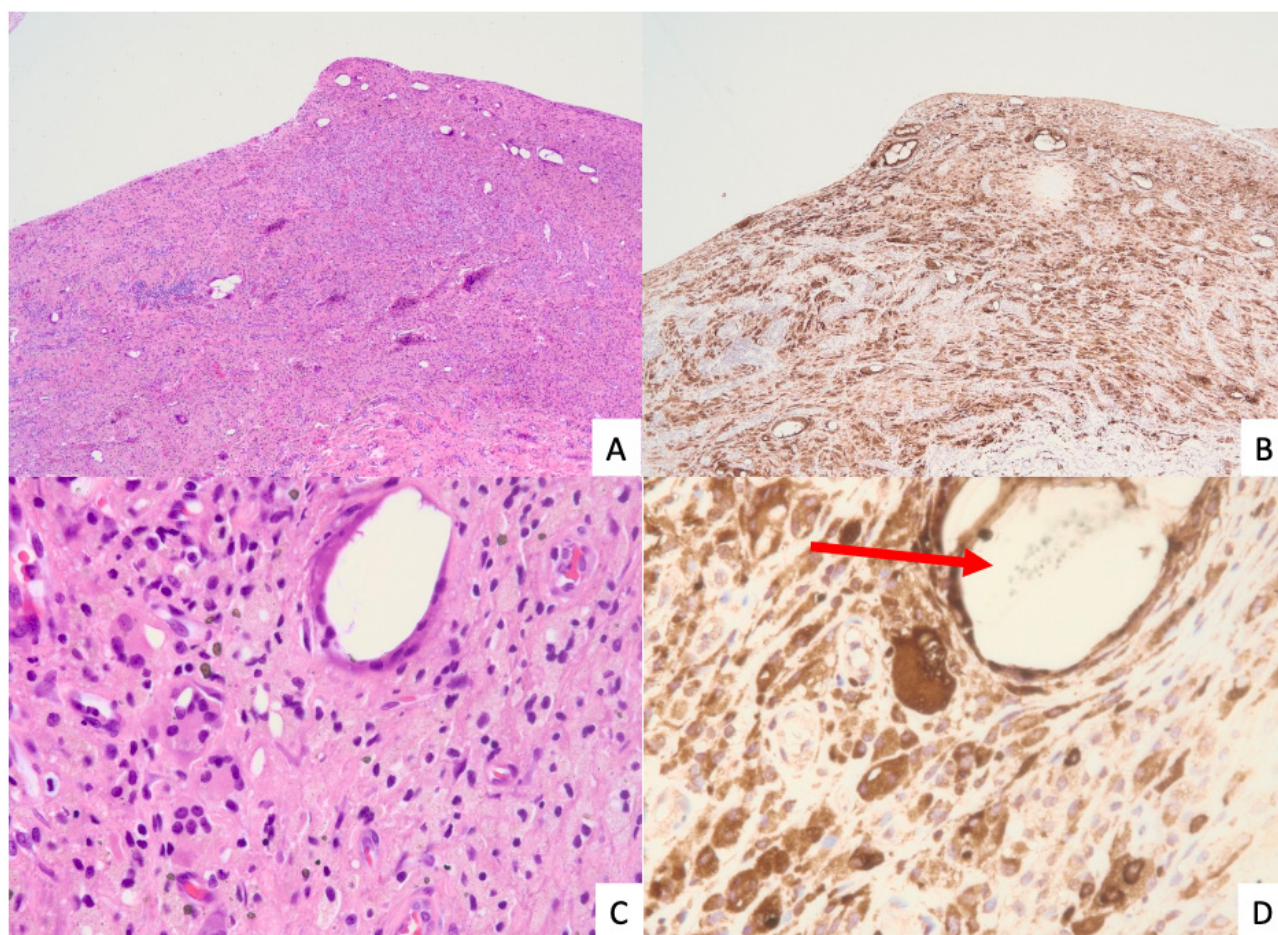


Figure 1 Failed left knee total joint arthroplasty synovitis. (A-D): A) hematoxylin and eosin; 40X, B) strong homogenous (diffuse) Cathepsin K (CatK) staining of wear debris histiocytes, immunohistochemistry score 9 (CatK; 400X), C) Wear debris histiocytes without inflammatory infiltrates (hematoxylin and eosin; 400X), D) Methyl acrylate wear debris (red arrow) with strong diffuse CatK staining (CatK; 400X).

in the inflammatory cascade via secretion of pro-inflammatory and pro-osteoclastic factors^[13]. However, the degree to which wear debris histiocytes express CatK has not been fully investigated. Why histiocytes in the presence of wear debris overexpress CatK is not yet known.

Our study demonstrates high levels of expression of CatK in wear debris histiocytes associated with prosthetic joints and PJF. As joint replacements are being extended to younger patients, a known risk

factor for TJA failure, one can project that wear debris associated PJF will become an increasing problem. Considering the potent collagenolytic, elastolytic, and proteoglycan-degrading activity of CatK^[8], we propose that CatK-positive histiocytes are involved in pathologic matrix remodeling, leading to periprosthetic osteolysis and aseptic loosening of prosthetic joints. Thus, histological analyses of CatK expressing wear debris histiocytes in prosthetic joint failure provides valuable insight into possible treatment/management

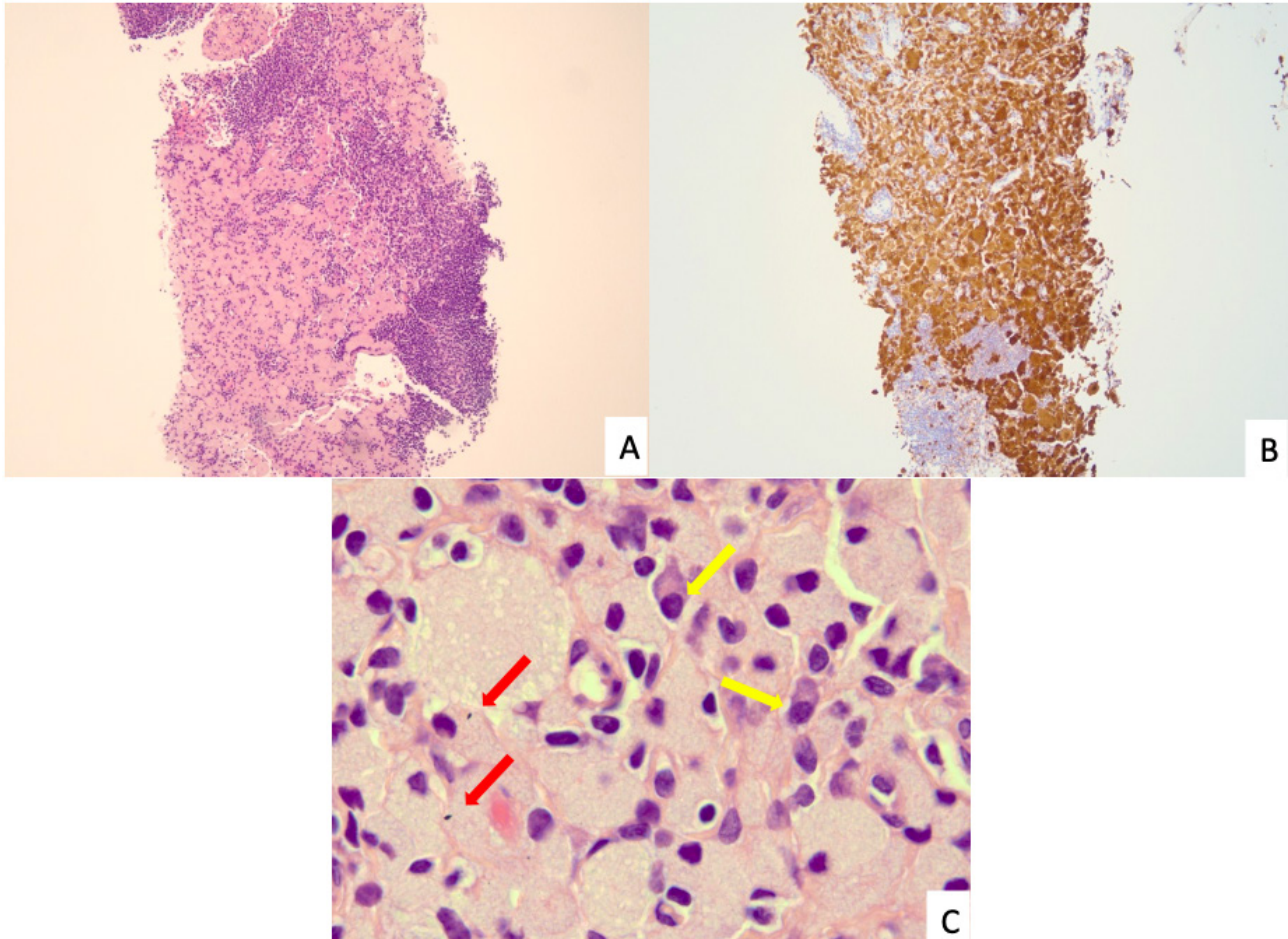


Figure 2 Inguinal lymphadenopathy from failed hip prosthesis. (A-C): A) Lymph node with histiocytic infiltrate (hematoxylin and eosin; 40 X), B) Wear debris histiocytes with infiltrate, strong diffuse staining, score 9 (CatK; 40X), C) Wear debris histiocytes, note red arrows are wear debris particles, yellow arrows are plasma cells (hematoxylin and eosin; 1,000X)

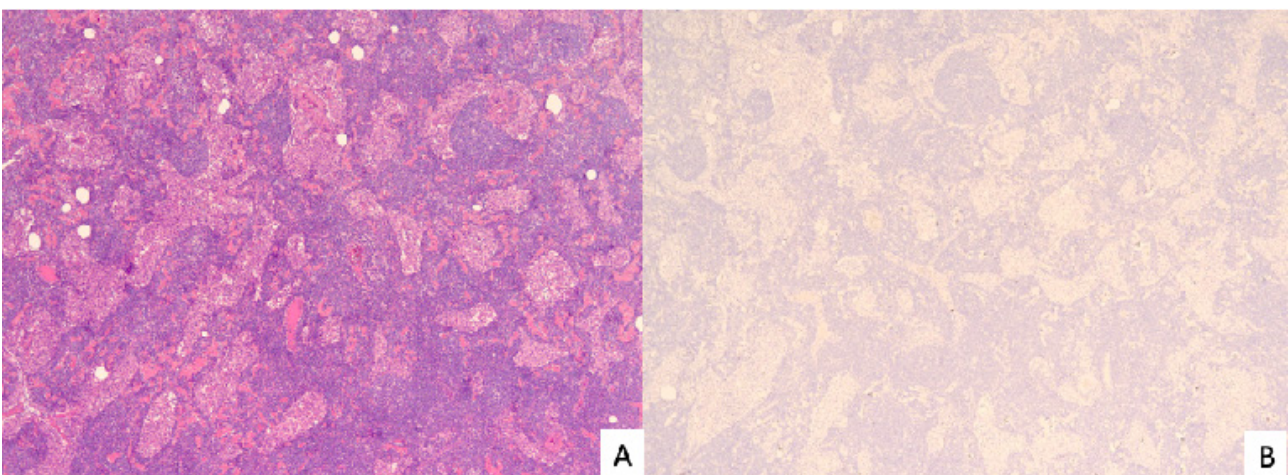


Figure 3 Pelvic lymph node with reactive sinus histiocytosis. (A, B): A) Sinus histiocytosis, yet no wear debris present (hematoxylin and eosin; 40X), B) Sinus histiocytes show no reactive to cathepsin k staining. (CatK; 40X).

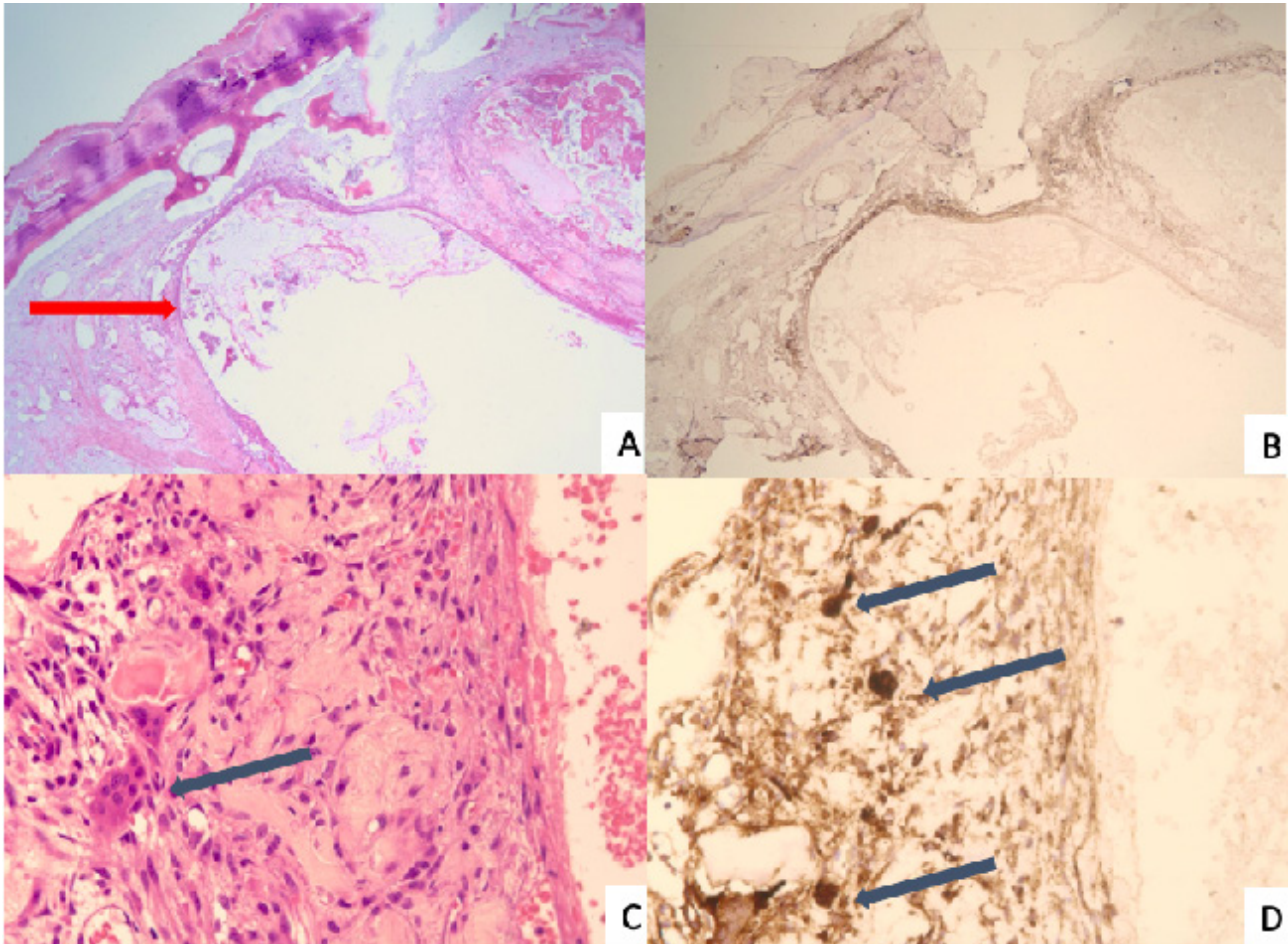


Figure 4 Degenerative joint disease of the left femoral head. (A-D): A) Degenerative change with histiocyte proliferation in the wall of the cysts (red arrow) (hematoxylin and eosin; 20X), B) Minimal scattered positive staining (CatK; 40X), C) Wall of cyst with histiocytes and osteoclasts (blue arrow) (hematoxylin and eosin; 400X), D) Histiocytes with weak nonspecific staining with a score of 2, note multinucleate osteoclasts stain strongly (blue arrows) (Cathepsin K; 400X).

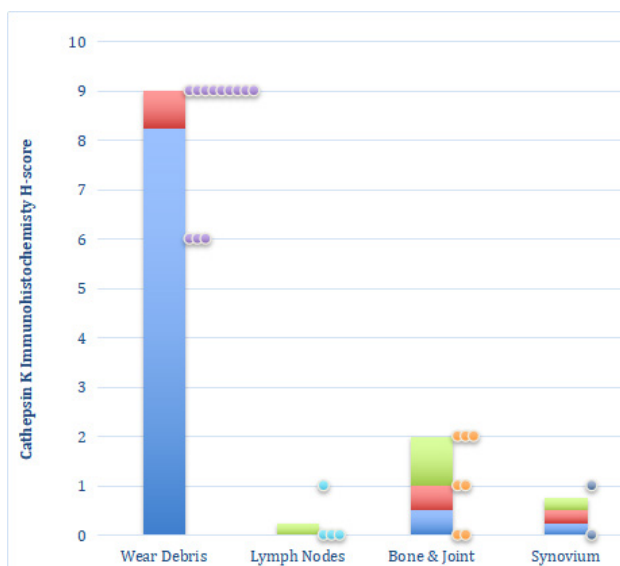


Figure 5 Graphical representation of wear debris cases and control subgroups. X-axis includes wear debris cases and different control subgroups. Each column represents the area between the 25th to 75th percentile distribution of each group. Color scatter points represent the individual data points for that group. CatK H-score medians for respective groups from left to right are 9, 0, 1 and 0.5.

decisions in patients who have undergone TJA. These possibilities include: First, monitoring of CatK activity in joint fluid may provide prognostic information regarding the likelihood of PJF. Evaluation of Cathepsin enzyme activity has been reported in patients with rheumatoid arthritis (RA) and osteoarthritis where patients with RA were found to have high levels of expression of Cathepsin B, but very low levels of CatK activity^[14]. This finding helps underscore the special role of wear debris histiocytes in the elaboration of CatK. Second, selective inhibition of CatK may provide a potential therapeutic intervention that theoretically could delay/prevent PJF due to wear debris associated osteolysis. Our study adds morphologic evidence for the clinical significance of finding a selective CatK inhibitor as a potential target for delaying/preventing PJF. Systemic selective CatK inhibitors have been developed, such as MIV-711, Odanacatib and Balicatib, all effective bone antiresorptive and chondroprotective agents^[15,16]. Yet there are currently no approved medical therapies for periprosthetic osteolysis with MIV-711 only in animal trials and both Odanacatib and Balicatib having unforeseen cerebrovascular, skin and pulmonary adverse events, respectively¹⁵. However, optimal delivery systems for CatK inhibitors have not been fully investigated. Local delivery, for example, including impregnation of prosthetic joint devices with CatK inhibitors might represent a way to avoid the systemic complications that can arise from systemic use of CatK inhibitors.

CONCLUSION

In this retrospective study, we demonstrated of the overexpression of CatK by wear debris histiocytes in comparison to histiocytes found in other bone, joint, and lymph node pathologies. Recognition of the important pathogenetic role of CatK secretion by wear debris histiocytes in bone resorption and aseptic loosening of prosthetic joints may lead to novel insights into possible new treatment strategies aimed at delaying/preventing PJJ.

REFERENCES

1. Goodman SB, Gómez Barrena E, Takagi M, Konttinen YT. Biocompatibility of total joint replacements: A review. *J Biomed Mater Res A*. 2009; **90**(2): 603-618. [PMID: 18508337]; [DOI: 10.1002/jbm.a.32063]
2. Singh JA, Yu S, Chen L, Cleveland JD. Rates of Total Joint Replacement in the United States: Future Projections to 2020-2040 Using the National Inpatient Sample. *J Rheumatol*. 2019; **46**(9): 1134-1140. [DOI: 10.3899/jrheum.170990]
3. Bayliss LE, Culliford D, Monk AP, et al. The effect of patient age at intervention on risk of implant revision after total replacement of the hip or knee: a population-based cohort study. *Lancet (London, England)*. 2017; **389**(10077): 1424-1430. [PMID: 28209371]; [PMCID: PMC5522532]; [DOI: 10.1016/S0140-6736(17)30059-4]
4. Workgroup of the American Association of Hip and Knee Surgeons Evidence Based Committee. Obesity and total joint arthroplasty: a literature based review. *J Arthroplasty*. 2013; **28**(5): 714-721. [PMID: 23518425]; [DOI: 10.1016/j.arth.2013.02.011]
5. Kandahari AM, Yang X, Laroche KA, Dighe AS, Pan D, Cui Q. A review of UHMWPE wear-induced osteolysis: the role for early detection of the immune response. *Bone Res*. 2016; **4**: 16014. [PMID: 27468360]; [PMCID: PMC4941197]; [DOI: 10.1038/boneres.2016.14]
6. Drake MT, Clarke BL, Oursler MJ, Khosla S. Cathepsin K Inhibitors for Osteoporosis: Biology, Potential Clinical Utility, and Lessons Learned. *Endocr Rev*. 2017; **38**(4): 325-350. [PMID: 28651365]; [PMCID: PMC5546879]; [DOI: 10.1210/er.2015-1114]
7. Purdue PE, Koulouvaris P, Nestor BJ, Sculco TP. The Central Role of Wear Debris in Periprosthetic Osteolysis. Published online 2006: 102-113. [PMID: 18751821]; [PMCID: PMC2488166]; [DOI: 10.1007/s11420-006-9003-6]
8. Hou WS, Li Z, Gordon RE, Chan K, Klein MJ, Levy R, Keysser M, Keyszer G, Brömme D. Cathepsin k is a critical protease in synovial fibroblast-mediated collagen degradation. *Am J Pathol*. 2001; **159**(6): 2167-2177. [DOI: 10.1016/S0002-9440(10)63068-4]
9. Punturieri BA, Filippov S, Allen E, Caras I, Murray R, Reddy V, Weiss SJ. Regulation of Elastolytic Cysteine Proteinase Activity in Normal and Cathepsin K – deficient Human Macrophages. 2000; 192(6).
10. Schurigt U, Eilenstein R, Gajda M, Leipner C, Sevenich L, Reinheckel T, Peters C, Wiederanders B, Bräuer R. Decreased arthritis severity in cathepsin L-deficient mice is attributed to an impaired T helper cell compartment. Matsuno H, ed. *Inflamm Res*. 2012; **61**(9): 1021-1029. [PMID: 22674323]; [DOI: 10.1007/s00011-012-0495-x]
11. Nich C, Takakubo Y, Pajarinen J, Gallo J, Konttinen YT, Takagi M, Goodman SB. The Role of Macrophages in the Biological Reaction to Wear Debris from Artificial Joints. *J Long Term Eff Med Implants*. 2016; **26**(4): 303-309. [PMID: 29199615]; [DOI: 10.1615/JLongTermEffMedImplants.2017011287]
12. Athanasou NA. The pathobiology and pathology of aseptic implant failure. *Bone Joint Res*. 2016; **5**(5): 162-168. [PMID: 27146314]; [PMCID: PMC4921050]; [DOI: 10.1302/2046-3758.55.BJR-2016-0086]
13. Doorn PF, Campbell PA, Amstutz HC. Metal versus polyethylene wear particles in total hip replacements. A review. *Clin Orthop Relat Res*. 1996; (329 Suppl): S206-16. [PMID: 8769335]; [DOI: 10.1097/00003086-199608001-00018]
14. Hashimoto Y, Kakegawa H, Narita Y, Hachiya Y, Hayakawa T, Kos J, Turk V, Katunuma N. Significance of cathepsin B accumulation in synovial fluid of rheumatoid arthritis. *Biochem Biophys Res Commun*. 2001; **283**(2): 334-339. [PMID: 11327703]; [DOI: 10.1006/bbrc.2001.4787]
15. Drake MT, Clarke BL, Oursler MJ, Khosla S. Cathepsin K Inhibitors for Osteoporosis: Biology, Potential Clinical Utility, and Lessons Learned. Published online 2017: 325-350.
16. Lindström E, Rizoška B, Tunblad K, et al. The selective cathepsin K inhibitor MIV-711 attenuates joint pathology in experimental animal models of osteoarthritis. *J Transl Med*. 2018; **16**(1): 56. [PMID: 29523155]; [PMCID: PMC5845353]; [DOI: 10.1186/s12967-018-1425-7]