

The Incomplete Proximal Femoral Osteotomy for Legg-Calvé-Perthes Disease in Children

Nguyen Ngoc Hung¹, MD, PhD; Hoang Hai Duc¹, MD, PhD; Le Tuan Anh¹, MD

¹ Viet Nam National Hospital for Pediatrics, Ha Noi, Viet Nam

Conflict-of-interest statement: The author(s) declare(s) that there is no conflict of interest regarding the publication of this paper.

Open-Access: This article is an open-access article which was selected by an in-house editor and fully peer-reviewed by external reviewers. It is distributed in accordance with the Creative Commons Attribution Non Commercial (CC BY-NC 4.0) license, which permits others to distribute, remix, adapt, build upon this work non-commercially, and license their derivative works on different terms, provided the original work is properly cited and the use is non-commercial. See: <http://creativecommons.org/licenses/by-nc/4.0/>

Correspondence to: Nguyen Ngoc Hung, MD, PhD, Associate Professor, VietNam National Hospital for Pediatrics, 18/879 La Thanh Road, Dong Da District, Ha Noi, Viet Nam.

Email: ngocyenhung@gmail.com

Telephone: +84-0902 585658

Received: June 8, 2020

Revised: June 26, 2020

Accepted: July 1 2020

Published online: August 28, 2020

ABSTRACT

BACKGROUND: Legg-Calvé-Perthes disease is a childhood hip disorder that can lead to deformed hips and poor functioning. The purpose of this study is to introduce our technique of incomplete proximal femoral osteotomy for Legg-Calvé-Perthes in children and to describe technical details, postoperative complications, the duration of treatment, and the advantages and disadvantages of this system.

METHODS: We analyzed the results of 14 patients (14 hips) who underwent incomplete Proximal Femoral osteotomy for Legg-Calvé-Perthes in our institute since 2008. to 2018. Patients may undergo a long-term examination. Hips are classified with the classification system of Catterall and Herring. Patients were divided into two variants, hip with Catterall II and III in variant 1; Catterall IV is included in variant 2. All hip functions (flexion, internal rotation, external rotation) have been tested. When checking the results using

Morse Classification. Long-term results were assessed after an average follow-up of 8.2 years.

RESULTS: There was Catterall group: Group II: 2, and Group III: 10, Group IV: 2; Herring group: Herring A: 3, Herring B: 7, Herring C: 4; Stulberg Classification: II: 11, III: 2, IV: 1. Wiberg angle: 17.0° in preoperative surgery and 31.07° in PostOperation with $P_{\text{valiated}} = 0.0007$; Morse Classification: Good: 5 (35.7%), Fair: 8 (57.2%), Poor: 1 (7.1%). Patients were 6 to 9 years old with all satisfactory results; 100%; Patient was upper 9 years old with satisfactory results: 83.3% and Poor: 16.7%.

CONCLUSION: Incomplete proximal femoral osteotomy of Legg-Calvé-Perthes disease in children has long-term results for Legg-Calvé-Perthes disease was surgical technique is simple and safe.

Key words: Legg-Calvé-Perthes disease; Proximal femoral osteotomy; Long-term results; Varus osteotomy; Valgus osteotomy

© 2020 The Author(s). Published by ACT Publishing Group Ltd. All rights reserved.

Hung NN, Duc HH, Anh LT. The Incomplete Proximal Femoral Osteotomy for Legg-Calvé-Perthes Disease in Children. *International Journal of Orthopaedics* 2020; 7(4): 1335-1345 Available from: URL: <http://www.ghrnet.org/index.php/ijo/article/view/2981>

INTRODUCTION

About 100 years ago, literature described a special self-limited condition of the hip, in which the head of the femur experienced a bone collapse of the head of the femur after avascular necrosis, and the cause of the disease has not been established, and there is no consensus on the optimal year treatment.

In recognition of Legg's contributions in the United States, by Jacques Calvé in France and George Perthes in Austria, this condition is known as Legg-Calvé-Perthes Disease (LCPD). The treatment aims to prevent the head of the femur being deformed due to early intervention during the treatment of the disease. Later treatment options in the course of the disease have also been mentioned.

The diagnostic age is usually 4-12 years, the average is 6 years^[1]. The '80% rule is helpful; It is said that nearly 80% of cases are seen in boys, 80% of cases have a unilateral manifestation and 80% develop it between 4 and 8 years of age^[2]. The incidence varies from

1: 10,000 children in the US to 2.97 per 10,000 children in southern India^[3]. About 25% of cases show bilateral participation^[2].

These authors reported positive results for most non-surgical patients such as braces and castings^[4]. Others believe that the disease can lead to deformed hips and poor functioning and recommend surgery for most patients^[5]. Good results with Salter's bone resection have been reported^[6]. Others recommend different surgical interventions including joints and bones^[7]. Chiari Osteotomy^[8], and shelf joints^[9]. The Legg-Calvé-Perthes disease group designed a study that looked at whether any treatments could change the outcome of LCPD and whether specific factors could predict the outcome for the outcome. Whether or not the patient has LCPD. However, patients are only available for follow up until skeleton maturation^[10].

Proximal femoral varus osteotomy for LCPD is a treatment for accommodating heads^[11]. Rescue surgery in the form of valgus bone resection is performed at non-capacity ends^[12]. Varus bone resection improves the final result in a spherical form of the femur head and should be performed before advanced fragmentation^[13,14]. Valgus bone resection enhances the fit of an untreatable tip and should be the preferred treatment to improve the range of hip movement, reduce hip pain, delay osteoarthritis and improve abduction mechanisms^[12,15].

Various devices have been used osteotomy the proximal femur. For internal fixation, devices such as Wagner plates, angle cutters, dynamic screws or compression plates have been used^[16]. They provide rigid immobility, but require an additional procedure for transplant removal, extensive tissue damage during dissection and a longer surgical period^[16]. Most of the previous research was on internal devices fixed in proximal femoral osteotomy.

The aim of our study was to introduce our technique of the incomplete Proximal Femoral osteotomy for Legg-Calvé-Perthes disease in children and to describe the technical details, postoperative complications, duration of treatment, and advantages and disadvantages of this system.

MATERIALS AND METHODS

A retrospective study was conducted to evaluate the results of surgical techniques on patients with Legg Calvé Perthes disease conducted from June 2008 to June 2018 in 16 patients (16 hips) had LCPD.

Informed consent was obtained from all participants. The study had the approval of the Ethical Review Committee of our Institute and was carried out in accordance with the tenets of the Declaration of Helsinki.

Two patients (two hips) were excluded from the study due to insufficient follow-up. The remaining 14 patients (14 hips) formed the basis of this study; There were 2 girls (14.3%) and 12 boys (85.7%). Unilaterally in all patients, with the left hip affected in 10 patients (71.4%) and right hip affected in 4 patients (28.6%). The average age of patients was 8.9 years old (about 6.6 years old to 12.6 years old). The average follow-up was 6 years and 2 months (approximately: 2.1 years - 11.8 years). Patients were divided into two variants, hip with Catterall II and III in variant 1; Catterall IV is included in variant 2.

Clinical parameters

Before the surgery, information is obtained about the type and amount of medication that has a history of trauma, the age at which symptoms began, the time when symptoms occurred. The main complaint patients have is hip pain with limping and accompanying knee pain. Clinical complaints and their onset were recorded, and

flexion, abduction, adduction and internal and external rotation of the hips and limbs were also recorded using a voltage meter, and they are evaluated before and after the surgery.

During physical examination, differences in limb length were assessed by clinical measurements of the distance between the preminent pelvic spine and the sternum and detecting differences in foot length.

Testing Trendelenberg: A positive Trendelenburg test proves that hip abductors are inactive due to weakness or pain suppression and cannot perform a pelvic stabilizing role on weight-bearing legs. To perform the test, the patient stands on the unaffected leg and bends the other knee to a right angle. The pelvis must be level or slightly tilted on the weightless side. The patient then stands on the affected leg and bends the knee of the other leg. If the pelvis is reduced on the unweighted side, this represents a positive Trendelenberg test.

Radiography

As the main radiographic outcome parameter, most recent radiofrequency and frog leg scans have been reviewed. The parameters assessed include: flattening of the femur head, acetabular changes, femoral neck shortening, trochanter enlargement, angelic femur neck abnormalities and femur head enlargement. Signs of osteoarthritis are considered secondary results parameter^[17]. Radiological assessment is performed by an experienced radiologist. Anterior pelvic X-ray is obtained at neutral, internal abduction, abduction and abduction positions as well as views of frog legs for all patients. The involvement of epiphyseal or femoral head is classified according to the classification of Catterall^[18] and Herring *et al*^[19]. Both extruded index^[20] and CE Wiberg angle^[21] were measured and classified, and patient risk factors were also identified.

Wiberg center angle^[21] is defined as the angle between the line connecting the acetabulum rim, the center of the femur and the vertical line. This method is also often used to determine the severity of LCPD. Wiberg angle must be between 25 and 40 degrees. In protrusion acetabulum it exceeds 40 degrees.

Coxa magna. The asymmetrical circumferential enlargement of the femoral head, is an important sequela of pediatric disorders such as Legg-Calvé-Perthes disease. Definitions vary because of lack of controls and a scarcity of research on the distribution of the femoral head asymmetry (define coxa magna above 10%)^[22].

The Shenton's line is an imaginary curve drawn along the inferior contour of high-end ramus (the higher contour of the obturator foramen) and along the infertility of the femur neck. This line must be continuous and smooth.

An outstanding sublimation was considered if the Shenton Hay line was broken (Stulberg *et al*^[23] 1981). Postoperative suppression was assessed by visual impression on X-rays that took 2-3 months.

Postoperatively, the head of the femur is considered to be present if the head of the femur is in acetabulum. The flatness of acetabulum was measured in unilateral cases both on the affected side and the other side showed no signs of LCPD.

Radiographic evaluation

Catterall classification: According to Catterall classification, there are 4 patient groups. In group 1, radiological changes are limited to the previous part of the capital chart. In group 2, there is about 50% involvement at the front, with the middle and lateral sections of the femoral head intact, plus metaphysical anterior lesions. In group 3, about 75% of the heads are involved, including the latter, with diffuse metaphysical reactions. In group 4, whole epiphysis is involved. 4 signs of risk include the Gage sign - a radioactive CV

on the lateral part of epiphysis, lateral calcification for epiphysis, lateral subluxation of the femoral head and a horizontal physical^[24]. Although the Catterall system has been widely used for many years in most studies, previous studies have found that it does not provide acceptable levels of interobserver and interobserver^[24]. Other studies have found acceptable levels of interobserver and interobserver^[25].

It was published in 1992, because of Catterall's poor regeneration capacity. It is also known as roadside pillar classification. For its author, the head of the femur is divided into three pillars: (1) Side pillars make up 15 to 30% of the side of the head - Center pillars, center 50%; (2) Intermediate pillars, on average 20 - 35%.

This classification distinguishes 3 groups according to their level of participation. Herring further describes the B / C border stage, which is characterized by a preserved side pillar: (1) The presence of a clear side image (sign of "V de Gage") (2) The eccentricity of the head or lateral subluxation; (3) The horizontal position of the conjugal plate; (4) The presence of a metaphyseal reaction; (5) The presence of lateral calcifications.

Radiographs were rated using the Stulberg classification^[23]. Class I hip is defined as a completely normal hip joint. Class II hips are defined as spherical (same concentric circle on AP radiographs and frog legs), but with a larger head than usual (although spherical), a shorter neck of the femur or a steeply sloping acetabulum often. Type III heads are described as spherical, ovoid, mushroom-shaped or umbrella-shaped, but not flat. Class IV hips are described as having a flat head of the femur with abnormalities of the neck of the femur and acetabulum. Class V hips are described as those with a flat head and a flat neck of the femur and acetabulum.

Surgical treatment

The indication for Operation: The indication for operation was subluxation of the femoral head or severe disease (Catterall's groups II-IV with signs of head-at-risk or progression of the disease despite conservative treatment).

The decision to treat was based on age at onset, the Catterall grade^[24], persistent limitation of movement of the hip (particularly if there was less than 30° of abduction), and severe subluxation and/or a metaphyseal cyst.

Operative technique: Patients divided into two Variants: Variant 1 with Catterall II-III; Variant 2 with Catterall IV.

General anesthesia was used for all patients. The patients were positioned in the supine position on a radiolucent orthopedic table. A lateral surgical approach to the proximal femur with incomplete osteotomy was used. Osteotomy was done at the lesser trochanter level in such a way that the greater trochanteric apophysis did not disturb. Used straight osteotome and osteotomy line must be perpendicular with along the axis of the femur and directed toward opposite femoral wall, femoral cortex was left intact to provide stability; with half the diameter of the femur in variant 1 (Figure 1); two-thirds of the diameter of the femur in Variant 2 (Figure 2).

The patient in Variant 2, Performed inserted 1 Kirschner wire 2 mm from greater trochanter to opposite femoral wall (Figure 2).

Eight weeks spica cast was performed in all patients as part of standard postoperative treatment after surgery. After this period, partial weight bearing was allowed until osteotomy united. Postoperatively, patients were followed up monthly for 1 year and then every 3 months after 1 year.

Method of evaluating results

In the study of therapeutic results, we used the Mose method (1964)^[28] using a transparent device described by Edgren (1965)^[29]. Good

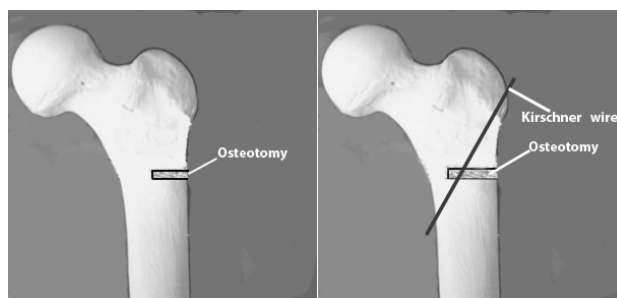


Figure 1 Osteotomy in Variant 1.

Figure 2 Osteotomy and Inserted Kirschner in Variant 2.

results include spherical ends with equal radius on the front and rear radiographs. (All side viewing angles are taken at the position Lauenstein Plate). The fair result has the ends deviated from the circle by up to 2 mm. Poor results have irregular heads, with different contours of more than 2 mm. Although this system does not account for the relationship between the head and acetabulum, it provides a very important analysis of the anatomical results of the disease and has significant prognostic value, because of the spherical shape of the femur head. Seemingly important for functional durability of the hip joint^[28,29].

Statistical analysis

SPSS version 16.0 software for Windows (SPSS, Chicago, IL, USA, 2007) was used for statistical analysis. The signed Wilcoxon rank test was applied to the results and $p < 0.05$ was deemed significant.

RESULT

June 2008 to June 2018 in 14 patients (14 hip) with LCPD were operated. None of the patients had a history of birth trauma, direct trauma, or other congenital anomalies.

The mean age of the patients was 8.9 years (range: 6.6-12.6 years). The average follow-up was 6 years and 2 months (range: 2.1 years - 11.8 years).

All patients had a tendency for limping gait, limited abduction at the hip, and lateral and internal rotation of the hip. Preoperatively, radiography of hips in all patients. We performed operatively according to variant 1 in 12 hips (14 patients) and according to variant 2 in 2 hip (2 patients). Long-term follow-up showed Good results in 5 hips (35.7%), fair results in 8 hips (57.2%), and poor results in 1 hip (7.1%).

Mean age at Operation: 8.9 years (6.9-12.6); Male: 12, Female: 2; Side: Left: 10, Right: 4; Total Patients without history trauma; Those Patients without Transient synovitis symptom; Pain PreOperation/PostOperation: 57.1% / 7.1%. Radiograph stage: Initial: 6, Fragmentation: 8; Catterall group: Group II: 2, Group III: 10, Group IV: 2 (Table 1); Herring group: Herring A: 3, Herring B: 7, Herring C: 4 (Table 2); Follow-up time: 8.2 years; Stulberg: II: 11, III: 2, IV: 1; Wiberg angle (°) Pre/PostOperation: 17.0° / 31.07° (Pvalue: 0.0007); Mose's Methods: Good: 5 (35.7%), Fair: 8 (57.2%), Poor: 1 (7.1%). Satisfactory Result Variant 1 / Variant 2: 91.7% / 100% (Pvalue 0.320). Patients was 6 to 9 years old (Number: 1, 4, 5, 6, 8, 9, 10, 13) with all satisfactory results (100%); Patients was up 9 years old (Number 2, 3, 7, 11, 12, 14) with Satisfactory results 5 (83.3%), and Poor 1 (16.7%).

Pre-and PostOperatively, All Function of the hip (Flexion, Abduction, Internal rotation, External rotation) with $p < 0.05$ (Statistical significance); Clinical Parameter (Limb length discrepancy, Limping, Trendelenberg test) with $p > 0.05$ (No statistical significance)

Complications: (1) There were no wound infections or neuromuscular complications; (2) Fracture at the osteotomy site: No; (3) Nonunion at the osteotomy site: No; (4) Kirschner broken: No; (5) Coxa Magna: No.

Illustration

1. The patient number 13 (Figures 3-8), Male, onset of LCPD 12 months, age at Surgery 7.8 years old, Left Hip.

Radiograph stage: Fragmentation; Caterall group: 4 (Table 1); Herring group: C (Table 2); Stulberg: III; Wiberg angle (°) Pre/PostOperative: 18°/20°. The Patient have Operated according to Variant 1.

Total function of the Hip at Pre/PostOperation: Flexion 130°/130°; Abduction: 20°/45°; Internal Rotation: 10°/50°; External Rotation: 58°/60°; Limb length discrepancy: 2.0cm/2.0cm; Limping: positive/positive; Trendelenberg test: positive / positive; Mose Classification at last result: Fair

2. The patient number 9 (Figures 9-13), Male, onset of LCPD 8 months, age at Surgery 6.9 years old, Left Hip, Radiograph stage: Initial; Caterall group: 3 (Table 1); Herring group: B (Table 2); Stulberg: II; Wiberg angle (°) Pre/PostOperative: 19°/39°. The Patient have Operated according to Variant 2.

Total function of the Hip at Pre/PostOperation: Flexion 85°/90°; Abduction: 15°/45°; Internal Rotation: 10°/50°; External Rotation: 55°/60°; Limb length discrepancy: No/No; Limping: Negative/ Negative; Trendelenberg test: Negative /Negative; Mose Classification at last result: Good.

DISCUSSION

Cause of Legg-Perthes Disease

Despite the general agreement, at least in recent years, the essential medical condition is ischemia or avascular necrosis^[30] the primary cause of vascular insults continues to be difficult Trauma^[31], synovial effusion^[32], infection, embolism^[31] constitutional tendencies and genetic factors^[33] are related but no unified concept has been found adequately explain all epidemiological data. It seems that avascular necrosis at the tip of the femur may be the last common pathway for some of the initial disorders, all of which interrupt the vascular supply of tissue that responds quite strongly to ischemia and its delay healing mechanism, is due to its delay healing mechanism. Very slow to recover. Trueta^[34] has clearly shown in epiphyseal, or retinaculum, post-mortem samples, the vessels of the posterior hip cyst are the only source of the head of the femur, at least in whites at age four to ten. This middle age is a period of high risk for LCPD, according to almost all reports. In this study, total Patients without history trauma and family history (Table 3).

The regular reported dominance of boys in nearly all series^[33] is about four one and a similar predominance of men in childhood fracture series^[31] shows trauma such as at least an occasional cause of vascular insults. No difference in vascular supply in men compared to women was found in a study of Trueta^[34]. Injury does not adequately explain the bilateral occurrence rate of 12 to 20 percent. All patients in this study was unilateral hip only (Table 3).

Transient synovitis of the hip^[32] has been reported as a precondition for this condition in 18% of patients with LCPD^[35]. The mechanism by which some observers believe is that pinching the vessels of the posterior follicles with increased hydrostatic pressure. Others^[36] do not believe that transient bursitis leads to vascular changes. It appears that synovitis may do so, but it is not common; Perhaps it does not account for the majority of cases. In this study, total Patients without Transient synovitis syndrome of the hip (Table 3).

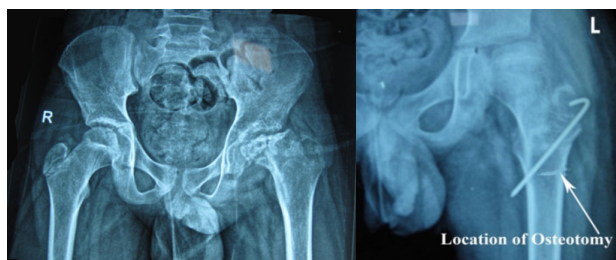


Figure 3 PreOperation (Number 13).

Figure 4 PostOperative 3 months (Variant 2).

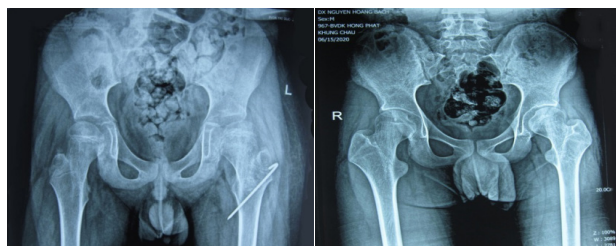


Figure 5 PostOperative 6 months.

Figure 6 PostOperatively, latest result (4.6 years).

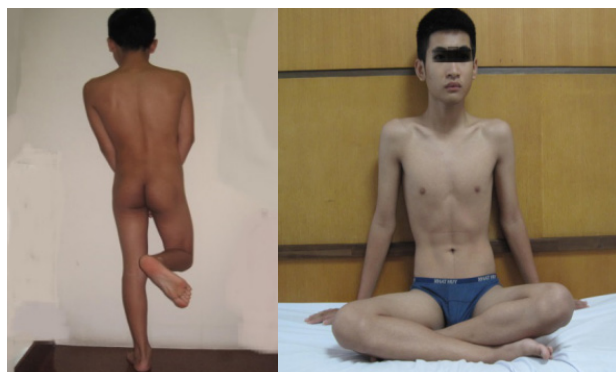

Figure 7 Latest result (4.6 years), Negative Trendelenberg.

Figure 8 Latest result (4.6 years), Sitting cross leg.

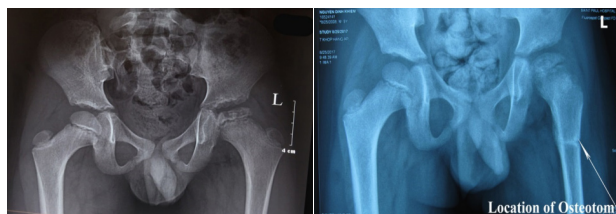


Figure 9 PreOperation (Number 9).

Figure 10 PostOperative 3 months (Variant 1).

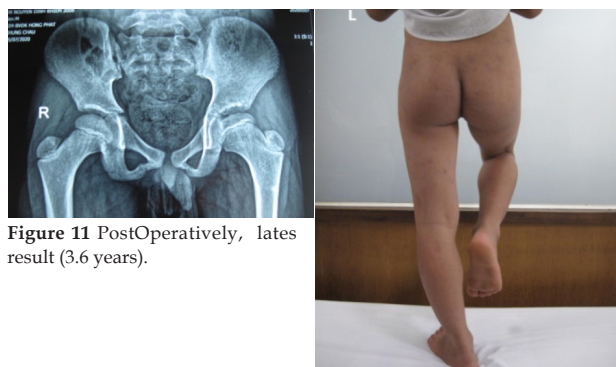

Figure 11 PostOperatively, latest result (3.6 years).

Figure 12 Latest result (3.6 years), Negative Trendelenberg.

Table 1 Catterall Classification [24]

Grade	Description	Prognosis
Grade I	Very anterior involvement of epiphysis No metaphyseal involvement	Excellent Prognosis without treatment t any age
Grade II	Anterior involvement < 50%	< 4 y.o.: good prognosis
	Possible metaphyseal involvement	> 4 y. o.: 50% of good prognosis without treatment
Grade III	Anterior Involvement > 50%	Poor prognosis
	Frequent metaphyseal involvement	
Grade IV	Total epiphyseal involvement	Poor or bed prognosis
	Metaphyseal involvement	

Table 2 Herring Classification [27]

Group	Description	Prognosis	
Group A	No involvement of lateral pillar	Stulberg 1 et 2 in 100% of group A patients	Excecelent prognosis
Group B	> 50% of lateral pillar height maintained	< 9 years Stulberg 1 and 2: 92%	Fair prognosis
		> 9 years	
		Stulberg 2: 30%	
		Stulberg 3: 50%	
Group C	Involvement of lateral pillar heigh > 50%	Stulberg 3: 30%	Poor prognosis
		Stulberg 3: 30%	
		Stulberg 3: 30%	

Age

Children over nine years of age when symptoms begin to have flat femoral head and acetabulum, with some hips becoming symptoms in adolescence^[37]. The worst result is a flattened femur head in a circular acetabulum, like an osteoporotic adult hip bone, which usually occurs in children over eleven years of age when symptoms begin to develop^[23]. Young children are often better than older people, but a small percentage of young children experience significantly delayed healing and permanent deformity at the top of the femur^[38]. The reported results are varied, with good results in sixty-four out of eighty hips in a series^[39] of three of the forty-nine hips in another^[40], and there are no thirty-four. hip in another^[41]. Some authors consider LCPD to be a mild disorder requiring little treatment, while others believe that prognosis is unfavorable and recommend surgery for most patients^[40, 42]. In a different disorder, it is important to identify factors that give clinicians an accurate prognosis. In addition, it is necessary to have a reproducible classification to compare results between studies.

Patients older than 9 years have relatively poor prognosis with a degree of head involvement^[43]. Age is an important variable. Hips in children under 10 years of age have better results than children over 10 years of age^[44].

In this study, Patients was 6 to 9 years old (Number: 1, 4, 5, 6, 8, 9, 10, 13) with all satisfactory result (100%); Patients was upper 9 years old (Number 2, 3, 7, 11, 12, 14) with Satisfactory 5 (83.3%), and Poor 1 (16.7%) Pvalue > 0.05 (Table 3).

Classification

Relevance or severity of the disease can be classified using the following classifications:

Catterall classification: Based on the level of epiphyseal involvement and the rate of collapse as seen in X-rays (both AP & Lateral views)^[18]. In group I, only the previous part of epiphysis is involved. Group II, is more related to the previous epithelium with the presence of central epithelium with maintaining epithelial height. Group III, showing that most of the epiphysis is isolated with the unaffected part located at the medial or side of the central epithelium. Group IV, showing the isolation of the entire epiphysis (Table 1). In this study, Catterall classification with Group II: 2 (14.3%); Group III: 10 (71.4%); Group IV: 2 (14.3%).

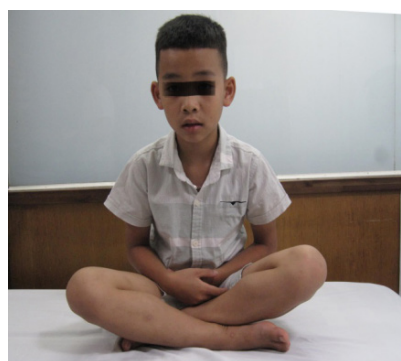

Figure 13 Lates result (4.6 years), Sitting cross leg.

Herring Classification (lateral pillar classification):

Classification of fragmentation into 3 groups. According to this head classification is divided into 3 pillars; intermediates, parties and centers. An intact side column acts as a weight support to protect the central vascular segment. Group A, showing the minimum density change in the side column without losing height, Group B shows the loss in height of the side column but less than half and the central segment collapses below the side column and Group C including loss of side column height of 50% inseparable from central and lateral segments^[45] (Table 2). In this study, Herring classification: Herring A: 3 (21.4%), Herring B: 7 (50%), Herring C: 4 (28.6%).

Salter Thompson classification: Based on subdural fractures of the femoral head due to stress on this area. When this epidural fracture or rib Caffey present sign involves less than 50% of the head of the femur, it is grouped under ‘A and moreover are grouped in B’^[46].

Modified Classification Elizabeth Town: X-ray classification of the natural process of LCPD, is divided into four stages: (a) Sclerosis, which is divided into no loss of height / height loss (duration - 220 days); (b) Fragmentation, possibly sooner or later (time 240 days); (c) Treatment, possibly peripheral > 1/3 epiphysis (duration - 255 days) and (d) Heal.

Stulberg classification: The Stulberg classification has also been considered, with two authors (J.A.H. and H.T.K.) and the research team using the original descriptions of Stulberg et al^[47] to review and classify the most.

Radiographs of the anterior and frog legs were recently observed by all research groups, and once again it was impossible to reach

Table 3a Data of Patient.

Patient No	Age at Surgery (years)	Sex	Hip	History Trauma	Pain	
					PreOp.	PostOp
1	6.9	Male	Left	(-)	(-)	(-)
2	10.5	Male	Left	(-)	(+)	(-)
3	10.9	Female	Left	(-)	(-)	(-)
4	8.3	Male	Right	(-)	(-)	(-)
5	7.6	Male	Left	(-)	(-)	(-)
6	8.5	Male	Left	(-)	(+)	(-)
7	11.4	Male	Left	(-)	(+)	(-)
8	8.4	Female	Right	(-)	(-)	(-)
9	6.9	Male	Left	(-)	(-)	(-)
10	8.2	Male	Left	(-)	(+)	(-)
11	12.6	Male	Right	(-)	(+)	(+)
12	10.4	Male	Left	(-)	(+)	(-)
13	7.8	Male	Right	(-)	(+)	(-)
14	9.2	Male	Left	(-)	(+)	(-)
Mean	8.9	Male: 12	R: 4		8/14	1/14
		Female:2	L: 10		-57.10%	-7.10%
SD	9.1					
Pvalue					0	

PreOp: PreOperation; PostOp: PostOperation; Mose Clasifi: Mose Classification.

Table 3b Data of Patient (Continuous).

Patient No	Radiograph stage	Catterall group [18]	Herring group [19]	Wiberg angle (°) PreOp PostOp [21]		Follow-up time (years)	Stulberg (I-V) [23]	Mose’s Method [28]
				PreOp	PostOp			
1	Initial	2	A	17	40	10.2	II	Good
2	Fragmentation	3	C	15	34	2.1	II	Fair
3	Fragmentation	2	B	18	34	5.9	II	Fair
4	Fragmentation	3	B	16	38	7.8	II	Good
5	Initial	3	B	17	40	11.5	II	Good
6	Initial	3	A	19	32	12.6	II	Fair
7	Fragmentation	3	B	18	33	13.3	II	Fair
8	Initial	3	B	14	36	4.3	II	Good
9	Fragmentation	3	B	19	39	3.6	II	Good
10	Fragmentation	3	A	16	25	10.5	II	Fair
11	Initial	3	B	14	15	11.8	IV	Poor
12	Initial	3	C	19	30	7.9	II	Fair
13	Fragmentation	4	C	18	20	4.6	III	fair
14	Fragmentation	4	C	18	19	8.3	III	Fair
Mean	Initial: 6	2:02	A: 3	17	31.071	8.2	II: 11	Good: 5 (35.7%)
	Fragmentation:8	3:10	B: 7				III: 2	Fair: 8 (57.2%)
		4:02	C: 4				IV: 1	Poor: 1 (7.1%)
SD				1.754	8.231	42.894		
Pvalue				0.001				

PreOp: PreOperation; PostOp: PostOperation.

consensus on their classification. After further review, we created a new classification group called the B / C border group for these cases. We have determined that the X-ray findings in this group are (1) a very narrow lateral column (2 to 3 mm wide) that is 50% higher than the original height, (2) one side column has very little effect. rhinestones but at least 50% of the original height, or (3) an lateral column with exactly 50% of the original height is pressed down from the central post. The definition of group A is still that there is no change in density in the side column and no loss of height in the side column. Group B includes hips with a lateral column> 50% of the original height, a width of a few millimeters and significant fossils. Group C is defined as hip with the collapse of the side

column in excess of 50% of its original height. In this study, Stulberg classification: Stulberg: II: 11 (78.6%), Stulberg: III: 2 (14.3%), Stulberg: IV: 1 (7.1%)

We have used classification of Catterall, Herring, and Stulberg (Table 3) in this study. (Catterall group: Group II: 2, Group III: 10, Group IV: 2; Herring group: Herring A: 3, Herring B: 7, Herring C: 4; Stulberg: II: 11, III: 2, IV: 1).

Treatment Legg-Calvé-Perthes disease

A variety of treatments are used in LCPD to maintain the motion range of the hip joint and to reduce clinical symptoms (especially pain) and contain the hip joint. Treatments can be classified as

Table 4 Clinical outcomes After Incomplete Proximal femoral Osteotomy.

Patient	Flexion		Abduction		Internal rotation		External rotation		Limb length discrepancy (cm)		Limping		Trendelenberg Test	
	PreOp	PostOp	PreOp	PostOp	PreOp	PostOp	PreOp	PostOp	PreOp	PostOp	PreOp	PostOp	PreOp	PostOp
1	70	95	21	45	15	14	32	22	0.5	0.5	-	-	-	-
2	128	130	15	34	20	60	33	75	1	1	+	+	-	-
3	135	135	20	64	11	29	10	80	1	1	+	+	-	-
4	120	125	25	55	13	43	18	54	1	0.5	+	-	-	-
5	85	80	28	40	15	45	34	35	No	No	-	-	+	-
6	96	100	30	40	10	35	45	65	1	0.5	-	-	-	-
7	90	92	30	51	5	45	40	54	1.5	1.2	+	+	-	-
8	80	85	15	52	5	50	38	35	1	0.5	+	-	-	-
9	85	90	25	50	15	45	55	60	No	No	-	-	-	-
10	79	80	31	45	10	35	60	75	1.5	1.5	+	+	+	+
11	88	90	18	50	0	40	35	82	No	No	+	+	-	-
12	90	95	20	40	5	46	42	55	1.5	1.2	+	+	-	-
13	130	130	20	45	10	50	58	60	2	2	+	+	+	+
14	130	130	25	52	15	55	32	48	1.5	1.2	+	+	+	+
Mean	100.42	104.07	23.07	47.357	10.64	42.285	38	57.142	1.22	0.75	Posit: 10 (71.2%)	Posit: 8 -57.10%	Posit: 4 -28.60%	Posit: 3 -21.40%
SD	22.99	20.86	5.427	7.662	5.4	11.498	14	17.93	0.41	6.345				
Pvalue	0.048		0		0		0		0.424		0.348		0.304	

PreOp.: PreOperation; PostOp.: PostOperation; (+) Posit.: Positive, (-) Negat.: Negative

Table 5 Comparison of Results by Mose’s Method[28].

Author	No. of patients	Good (%)	Fair (%)	Poor (%)	Total Satisfactory (%)
Mose[28]	209	55	18	27	73
Katz[72]	284			20	80
Petrie & Bitenc[73]	60	60.3	30.9	8.8	91.2
Axer[74]	34	53	38	9	91
Present study	14	35.7	57.2	7.1	92.9

surgical and non-surgical. Although the initial description of LCPD was made over a hundred years ago^[18], there is a lack of consensus about the most appropriate form of treatment for the condition and the groups of patients to apply. There is no general agreement on whether surgical or non-surgical treatment is beneficial^[48]. Most surgical modifications for LCPD are made to increase the ability to prevent the head of the femur in acetabulum by surgical removal of the femur or femur. A combination of congenital femur and jawbone has also been proposed by several researchers^[49].

Factors to consider when deciding on treatment include: (1) A child’s age at the onset of symptoms; (2) Presence of femoral head; (3) The range of hip motion; (4) The evolutionary stage of the disease^[13,14].

Non-operative Treatment

The majority of patients in Perthes can be treated without surgery. The force exerted on the hips can be reduced by avoiding weight bearing or sports activities and using crutches when walking toes. Should swim. The role of traction has been discussed by some workers^[27]. They favored the tensile force in bending at this position the maximum hip volume, thus avoiding complications due to increased internal joint pressure. The abduction of limbs can be maintained by keeping the limbs in a cast (broomstick, Petrie cast) or abducted braces (braces, Synder sling, Atlanta Scottish Rite Brace). These abduction measures have been used with various success reports^[6]. Initial reports were encouraging by these workers, however,

recent studies have not shown such favorable results^[42]. Long-term immobility has negative consequences, including muscle atrophy, contraction, weight gain and social exclusion. It has been noted that a brace on radiographs is necessary to ensure the correct number of abductions. Another conservative protocol includes weightless exercises at home with intermittent traction, and actor Petrie also doesn’t show good results. The results of the untreated group were similar to that of the braces group and the range of the motor group at all ages and the severity of the disease^[41].

Operative treatment

Treatment planning: The variables to consider for treatment decisions include the age of the child at the onset of symptoms, the appearance of the head of the femur, the extent of hip motion and the stage of illness^[48]. Outlines of decision making for early treatment of LCPD during treatment are shown in Table 3.

Some active treatments for LCPD: Surgical options include: (1) pelvis; (2) proximal femoral Varus or Valgus; and (3) a combination of both. Others recommend various surgical interventions including joint and osteoarthritis^[49]. Chiari bone resection^[50], arthroscopic surgery^[51] and triple bone (Steel bone)^[52]; Remove the first femur Varus or Valgus only or cut the combined Iliac bone (Figure 14).

Varus or valgus osteotomies and variations

The goal is to improve hip focus by rearranging the head and neck of the femur by reducing (varus) or increasing (valgus) the femoral neck axis. The hip must be mobile for more than 90° bend. Abduction of more than 15° is required to correct varus and an addition of more than 15° is shed valgus bone. Evaluation of the motion range of the joint should be performed under general anesthesia with or without surgical excision (addictive substance, psoas...).

Varus osteotomies: With this technique, the head of the femur can be readjusted, the contact surface can be modified, the pressure can be reduced on the affected area and the gluteal muscles can be relaxed. The inconvenience is shortening of the femur and bulge. Kim et al. suggest that a modest 10-15 ° angina is sufficient for

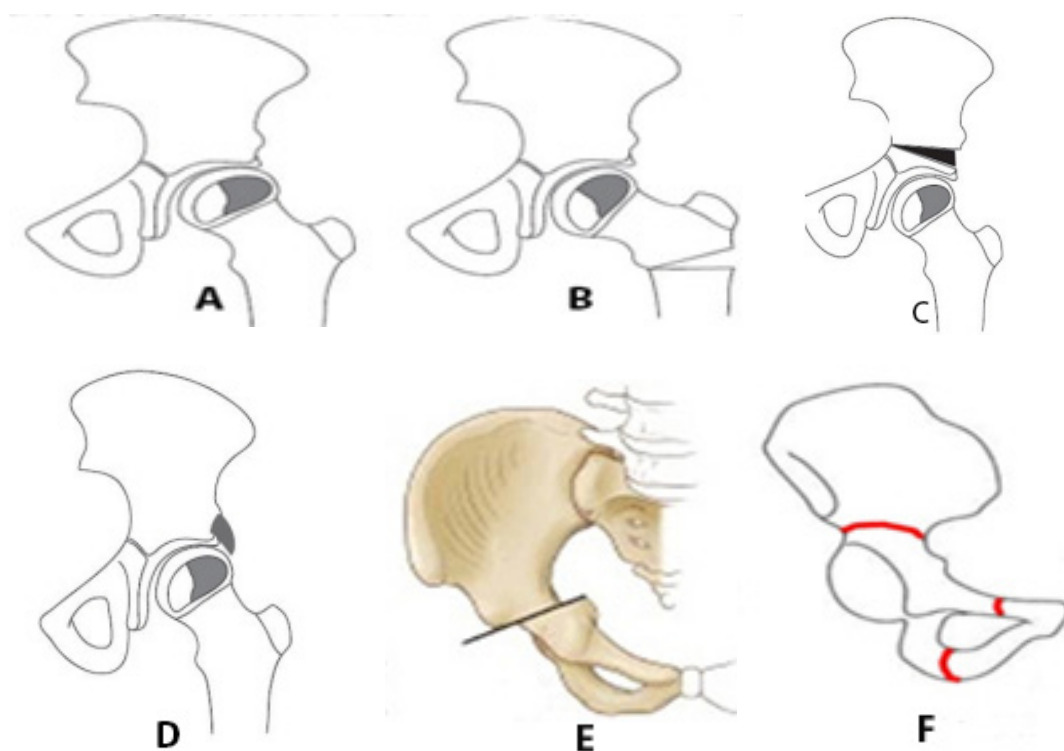


Figure 14 Schematic diagram of surgical options for containment of an extruded avascular femoral epiphysis (A) include proximal femoral varus osteotomy (B) innominate osteotomy (C) shelf procedure (D) Chiari osteotomy (E) and Triple osteotomy (Steel) (F).

adequate containment by femoral resection^[53]; The author likes to create a 20° varus angle^[13,48].

Valgus osteotomy: Valgus osteotomies is beneficial in LCP and SCFE^[54]. They fix instability and improve fit because they fix abduction hinges. They advocate the reconstruction of the femur head in children, increase abduction and hip flexion and reduce pain. They reduce limping by regenerating the intermediate muscle after lowering the larger trochanter. In an inherited or obtained coxavara, the head of the femur can be readjusted and the Hilgenreiner Epiphyseal (HE) angle must be less than 35°, which can be corrected. This angle is a necessary prognostic factor for recurrence: usually 16° (0-25°)^[55]. Due to the compression from valgus correction, foci are stimulated, leading to the healing of triangular defect in congenital vara. Removing valgus bones when performed to abduct hinges reduces pain and improves functional scores but in a small percentage of the hips (~ 10%), the head of the femur will remain spherical and end in Stulberg Class I or II (spherical head); most will fall into Class III and IV (not spheres)^[54,55]. The role of containment at this stage of the disease is still uncertain^[56,57].

Iliac osteotomy

Salter osteotomy: Salter or Innominate osteotomy in LCPD is performed as described for the developmental dislocation of the hip^[58]. It is designed to achieve anterior and posterior coverage of the femoral head by rotating acetabular^[59].

The front and front areas of the hips are the largest areas of intense stress. Prevention is never absolute, because the head of the femur is larger than acetabulum. The improved coverage is achieved by the cost of the back cover of the femur. Although difficult to visualize using radiotherapy, this bone resection surgery also replaces the medical term acetabulum 1 to 1.5 cm, thus reducing the mechanical compressive force on the hip joint^[59]. It also replaces the distal femur head with a similar amount that improves the often-related lower

limb length difference.

Triple innominate osteotomy: Triple innominate osteotomy (TIO)^[60] has yielded even better head-related cases. TIO concentrates the femoral head in acetabulum during fragmentation and regeneration, allowing the spherical acetabulum to serve as a template for biological femoral head during healing (blood vessel regeneration). Although TIO allows the adjustment of acetabular orientation and suppression of the femoral head^[60], it can also inadvertently cause overlap, resulting in pincer morphology and later symptomatic femoral images. (FAI), is a preclinical condition^[61].

Chiari's osteotomy: Chiari's osteotomy^[62] was first described in 1974 and recommended LCPD treatment to improve the lateral coverage of the deformed femoral head. This resection has an intermediate effect on the center of the head of the femur towards the center of gravity. Therefore, it reduces the swing arm on the hip, reduces the internal pressure. However, this bone removal does not reduce the imitations within the abduction and may exacerbate the abduction's weakness. Another important point is that the additional weight surface of acetabulum does not provide a curved cartilage crust, but only a permeable flat surface although the shape of acetabulum has a great influence on the late outcome in LCP^[63]. Moreover, this surgical procedure may cause a small shortening of the lower limb due to the upward and intermediate displacement of the innermost segment of the innate bone^[64], and when it is performed in young children, Wiberg's angle^[65] was shown during growth^[64]. However, improvements in femur head coverage and hip fit have been reported following this procedure^[66].

In 1960, a patient who was being treated for Legg-Calve-Perthes disease, fell and sustained an un displaced intertrochanteric fracture of the involved hip. After the fracture, which was treated with plaster-cast immobilization, shown clinical impression that the rate of healing of the disease had accelerated greatly^[66]. Clancy. 1985^[67] have reported "The Effect of an Incomplete Intertrochanteric

Osteotomy on Legg-Calve-Perthes Disease”.

From 2008, we performed incomplete proximal femoral osteotomy for LCPD in 14 patients. We shown this technique was simple and safe. Some functions of the hip was improved. Compared Pre and PostOperatively, Flexion, Abduction, Internal rotation, External rotation, Pain at the hip with $p < 0.05$ with statistical significance.

Varus osteotomy for LCPD with average varus angle needed is approximately 25 to 35 degrees, which causes a shortening of 1 to 2 cm^[68]. Our surgical technique didn't Varus or Valgus Osteotomies so Clinical Parameter (Limb length discrepancy, Limping, Trendelenberg test) with $P > 0.05$ No statistical significance (Table 4).

We agree Won's opinion that “The osteotomy in the proximal femur results in overgrowth, increased blood supply to the femoral head, and subsequently alters the biomechanics around the hip joint”^[69]; and Arnoldi *et al*^[70] have also shown that osteotomy decreases the elevated intraosseous pressure and improves venous circulation in coxarthrosis.

Comparison

The results of surgical treatment for LCPD are difficult to evaluate, making the optimal treatment for these patients controversial. Many authors have described the results of different treatments for LCPD. Because the disease is relatively rare, most reports are based on a limited number of patients. The availability of different treatments in different countries also increases uncertainty and makes it difficult to facilitate the comparison of the results of different treatments^[71].

In this study, Our result according to Mose's Method [28] were 92.9 % satisfactory result (Table 5).

Limitations in this study

There are some limitations in our research. The number of patients is limited to 14 patients. The studies described as our retrospective in nature and although the follow-up was performed by a surgeon. On the other hand, the sample size is very small in this study and the surgical results may not be a reflection of surgical results in all patients with LCPD in our community. Another limitation of this study is that the age of surgical intervention in different patients may have a significant effect on disease presentation and results. Age in the evaluation of results is heterogeneous so the results are very different.

CONCLUSION

According to our research, the latest results of the incomplete Proximal Femoral Osteotomy is safe and effective. This surgical technique is an acceptable method to manage patients with Legg-Calve-Perthes. This surgery has resulted in pain reduction, limping and increased range of motion. Signs that the activity is sublimated of the femur head or severe disease (Catterall male group II-IV) show signs of a head at risk or progression of the disease despite conservative treatment, especially if it is below 30° abduction.

REFERENCES

1. Singh A, Srivastava RN, Shukla P, Pushkar A, Ali S. Management of late onset perthes: Evaluation of distraction by external fixator - 5 years follow up. *Advances in Orthopaedics*; 2014. (Article ID 135236: 6)
2. Tripathy S, Sen R, Dhatt S, Goyal T. Legg-calve-perthes disease current concepts. *Webmed Central Orthopaedics*. 2010; **1(11)**: WMC001173.
3. Joseph P, Chacko V, Rao BS, Hall AJ. The epidemiology of perthes disease in South India. *Int J Epidemiology*. 1988; **17**: 603-07. [DOI: 10.1093/ije/17.3.603]
4. Cooperman DR, Stulberg SD. Ambulatory containment treatment inPerthes' disease. *ClinOrthop*. 1986; **203**: 289-300. [PMID: 3955992]
5. Nomura T, Terayama K, Watanabe S. Perthes' disease: a comparisonbetween two methods of treatment, Thomas'splint and femoral osteotomy. *Arch Orthop Trauma Surg*. 1980; **97**: 135-140. [DOI: 10.1007/BF00450935]
6. Paterson DC, Leitch JM, Foster BK. Results of innominate osteotomyin the treatment of Legg-Calve'-Perthes disease. *ClinOrthop*. 1991; **266**: 96-103]
7. Olney BW, Asher MA. Combined innominate and femoral osteotomy forthe treatment of severe Legg-Calve'-Perthes disease. *J Pediatr Orthop*. 1985; **5**: 645-651. [DOI: 10.1097/01241398-198511000-00003]
8. Cahuzac JP, Onimus M, Trottmann F, Clement JL, Laurain JM, Lebarbier P. Chiari pelvic osteotomy in Perthes disease. *J PediatrOrthop*. 1990; **10**: 163-166. [PMID: 2312693]
9. Willett K, Hudson I, Catterall A. Lateral shelf acetabuloplasty: anoperation for older children with Perthes' disease. *J PediatrOrthop*. 1992; **12**: 563-568. [PMID: 1517413]
10. Herring JA, Kim HT, Browne R. Legg-Calve'-Perthes disease. Part II: prospective multicenter study of the effect of treatment on outcome. *Bone Joint Surg Am*. 2004; **86-A**: 2121-2134. [PMID: 15466720]
11. Copeliovitch L. Femoral varus osteotomy in Legg-Calve-Perthes disease. *J Pediatr Orthop* 2011; **31**: 189-191. [DOI: 10.1097/BPO.0b013e318223b55c]
12. Choi IH, Yoo WJ, Cho TJ, Moon HJ. The role of valgus osteotomy in LCPD. *J Pediatr Orthop* 2011; **31**: 217-222. [DOI: 10.1097/BPO.0b013e318223b404]
13. Joseph B, Rao N, Mulpuri K, Varghese G, Nair S. How does a femoral varus osteotomy alter the natural evolution of Perthes' disease? *J Pediatr Orthop B* 2005; **14**: 10-15. [DOI: 10.1097/01202412-200501000-00002]
14. Joseph B, Nair NS, Mulpuri K, Varghese G. Optimal timing for containment surgery for Perthes disease. *J Pediatr Orthop* 2003; **23**: 601-606. [DOI: 10.1097/00004694-200309000-00006]
15. Myers GJ, Mathur K, O'Hara J. Valgus osteotomy: a solution for late presentation of hinge abduction in Legg-Calvé-Perthes disease. *J Pediatr Orthop* 2008; **28**: 169-172. [DOI: 10.1097/BPO.0b013e3181653b13]
16. Uthhoff HK, Poitras P, and Backman DS. Internal plate fixation of fractures: short history and recent developments. *J Orthop Sci*. 2006; **11(2)**: 118-126. [DOI: 10.1007/s00776-005-0984-7]
17. Neyt JG, Weinstein SL, Spratt KF, Dolan L, Morcuende J, Dietz FR, et al. Stulberg classification system for evaluation of Legg-Calvé-Perthes disease: intra-rater and inter-rater reliability. *J Bone Joint Surg Am*. 1999; **81**: 1209-16. [DOI: 10.2106/00004623-199909000-00002]
18. Catterall A. Legg-Calve'-Perthes disease. Churchill Livingstone, New York, pp 8-33, 81-109. 1982
19. Hosalkar H, Munhoz da Cunha AL, Baldwin K, Ziebarth K, Wenger DR. Triple innominate osteotomy for Legg-Calve'-Perthes disease in children: does the lateral coverage change with time? *Clin Orthop Relat Res* 2012; **470**: 2402-2410 [DOI: 10.1007/s11999-011-2189-z]
20. Green NE, Beauchamp RD, Griffin PP. Epiphyseal extrusion as a prognostic index in Legg-Calve'-Perthes disease. *JBJS Am* 1981; **63(6)**: 900-905 [PMID: 7240330]
21. Wiberg G. Shelf operation in congenital dysplasia of the acetabulum and in subluxation and dislocation of the hip. *JBJS Am* 1953; **35(1)**: 65-80 [PMID: 13022708]
22. Ernest YY, Jeremy JG, Navkirat B, Cooperman DR, and Nicholas UA. Femoral Head Asymmetry and Coxa Magna: Anatomic Study. *J Pediatr Orthop* 2014; **34**: 415-420. [DOI: 10.1097/

- BPO.000000000000132]
23. Stulberg S D, Cooperman D R, Wallensten R. The natural history of Legg-Calvé-Perthes disease. *J Bone Joint Surg (Am)* 1981; **63** (7): 1095-1108. [PMID: 7276045]
 24. Catterall A. The natural history of Perthes' disease. *J Bone Joint Surg Br.*1971; **53**: 37-53. [PMID: 5578764]
 25. Christensen F, Soballe K, Ejsted R. The Catterall classification of Perthes' disease: an assessment of reliability. *J Bone Joint Surg Br.*1986; **68**: 614-615. [PMID: 3733840]
 26. Meurer A, Schwitalle M, Humke T, Rosendahl T, Heine J. [Article in German] Comparison of the prognostic value of the Catterall and Herring classification in patients with Perthes disease [in German]. *Z OrthopHrreGrenzgeb.* 1999; **137**: 168-172. [DOI: 10.1055/s-2008-1039353]
 27. Herring JA. LCPD. In Tachdjian's Paed Orthopaedics. 3rd ed. WB Saunders Co.; 655-704. 2000
 28. Mose K. Legg-Calvé-Perthes' disease. Universitets Forlaget, Aarhus. 1964
 29. Edgren W. Coxa plana. *Acta orthop. Scand* 1965; **Suppl. 84**. 1965
 30. Zemansky AP Jr: The pathology and pathogenesis of Legg-Calvé-Perthes' disease. *Osteochondritis juvenilis deformans coxae. Am J Surg* 1928; **4**: 169-184.
 31. Caffey J. The early roentgenographic changes in essential coxa plana-Their significance in pathogenesis. *Am J Roentgenol* 1968; **103**: 620-634. [DOI: 10.2214/ajr.103.3.620]
 32. Tachdjian MO, Grana L. Response of the hip joint to increased intra-articular hydrostatic pressure. *Clin Orthop* 1968; **61**: 199-212. [PMID: 5704409]
 33. Goff CW, Shutkin NM, and Hersey MR. Legg-Calvé-Perthes Syndrome and Related Osteochondroses of Youth. Springfield, Ill., Charles C Thomas, 1954. [DOI: 10.1002/ajpa.1330130115]
 34. Trueta J. The normal vascular anatomy of the human femoral head during growth. *J Bone Joint Surg* 1957; **39-B**: 358-394. [PMID: 13438980]
 35. Jacobs BW. Synovitis of the hip in children and its significance. *Pediatrics* 1971; **47**: 558-566.
 36. Adams JA. Transient synovitis of the hip joint in children. *J Bone Joint Surg* 1963; **45-B**: 471-476. [DOI: 10.3109/17453678609156820]
 37. Willett K, Hudson I, Catterall A. Lateral shelf acetabuloplasty: an operation for older children with Perthes' disease. *J Pediatr Orthop.* 1992; **12**: 563-8. [PMID: 1517413]
 38. Snyder CR. Legg-Perthes disease in the young hip-does it necessarily do well? *J Bone Joint Surg Am.* 1975; **57**: 751-9. [PMID: 1158909]
 39. Kelly FB Jr, Canale ST, Jones RR. Legg-Calvé-Perthes disease. Long-term evaluation of non-containment treatment. *J Bone Joint Surg Am.* 1980; **62**: 400-7. [PMID: 7364810]
 40. Sponseller PD, Desai SS, Millis MB. Comparison of femoral and innominate osteotomies for the treatment of Legg-Calvé-Perthes disease. *J Bone Joint Surg Am.* 1988; **70**: 1131-9. [PMID: 3417698]
 41. Martinez AG, Weinstein SL, Dietz FR. The weight-bearing abduction brace for the treatment of Legg-Perthes disease. *J Bone Joint Surg Am.* 1992; **74**: 12-21. [PMID: 1734000]
 42. Kamegaya M, Shinada Y, Moriya H, Tsuchiya K, Akita T, Someya M. Acetabular remodelling in Perthes' disease after primary healing. *J Pediatr Orthop.* 1992; **12**: 308-14. [DOI: 10.1097/01241398-199205000-00006]
 43. Ippolito E, Tudisco C, Farsetti P. The long-term prognosis of unilateral Perthes' disease. *J Bone Joint Surg Br* 1987; **69**: 243-50. [PMID: 3818755]
 44. Kenneth JN, Charles T, Stanley JK and Michael P. Results of Femoral Varus Osteotomy in Children Older Than 9 Years of Age With Perthes Disease. *Journal of Pediatric Orthopaedics* 2001; **21**: 198-204 [PMID: 11242250]
 45. Browne RH. The lateral pillar classification of LCPD. *J Paed Orthop.* 1992; **12**(2): 143-50. [DOI: 10.1097/01241398-199203000-00001]
 46. Salter RB, Thompson GH. LCPD. The prognostic significance of the subchondral fracture and a two group classification of the femoral head involvement. *JBJS Am.* 1984; **66**(4): 479-89. [PMID: 6707027]
 47. Stulberg SD, Cooperman DR, Wallensten R. The natural history of Legg-Calvé-Perthes disease. *J Bone Joint Surg Am.* 1981; **63**: 1095-108. [PMID: 7276045]
 48. Joseph B, Srinivas G, Thomas R. Management of perthes disease of late onset in southern India. The evaluation of a surgical method. *JBJS Br.* 1996; **78**: 625-30. [PMID: 8682832]
 49. Crutcher JP, Staheli LT. Combined osteotomy as a salvage procedure for severe Legg-Calvé-Perthes disease. *J Pediatr Orthop.* 1992; **12**: 151-156. [DOI: 10.1097/01241398-199203000-00002]
 50. Cahuzac JP, Onimus M, Trottmann F, Clement JL, Laurain JM, P Lebarbier P. Chiari pelvic osteotomy in Perthes disease. *J Pediatr Orthop* 1990; **10**: 163-6. [PMID: 2312693]
 51. Kruse RW, Guille JT, Bowen JR. Shelf arthroplasty in patients who have Legg-Calvé-Perthes disease. A study of long-term results. *J Bone Joint Surg Am.* 1991; **73**: 1338-13347. [PMID: 1918116]
 52. Steel HH. Triple osteotomy of the innominate bone. *J Bone Joint Surg Am.* 1973; **55**(2): 343-50. [PMID: 4572223]
 53. Beer Y, Smorgick Y, Oron A, Mirovsky Y, Weigl D, Agar G, Shitrit R, Copeliovitch L. Long-term results of proximal femoral osteotomy in Legg-Calvé-Perthes disease. *J Pediatr Orthop* 2008; **28**: 810-24. [DOI: 10.1097/BPO.0b013e31818e122b]
 54. Myers S, Eijer H, Ganz R. Anterior femoroacetabular impingement after periacetabular osteotomy. *Clin Orthop* 1999; **63**: 93-9. [PMID: 10379309]
 55. Raney EM, Grogan DP, Hurley ME, Ogden MJ. The role of proximal femoral valgus osteotomy in Legg-Calvé-Perthes disease. *Orthopedics* 2002; **25**: 513-7. [PMID: 12046910]
 56. Yoo WJ, Choi IH, Chung CY, Cho TJ, Kim HY. Valgus femoral osteotomy for hinge abduction in Perthes' disease: decision making and outcomes. *J Bone Joint Surg Br* 2004; **86**: 726-30. [DOI: 10.1302/0301-620x.86b5.13897]
 57. Chang JH, Kuo KN, Huang SC. Outcomes in advanced Legg-Calvé-Perthes disease treated with the Staheli procedure. *J Surg Res* 2011; **168**: 237-42. [DOI: 10.1016/j.jss.2009.09.056]
 58. Salter RB. Innominate osteotomy in the treatment of congenital dislocation and subluxation of the hip. *J Bone Joint Surg Br.* 1961; **43**: 518-539. [PMID: 369757]
 59. Rab GT. Biomechanical aspects of Salter osteotomy. *Clin Orthop Relat Res.* 1978; **132**: 82-87. [PMID: 679558]
 60. Kumar D, Bache CE, O'Hara JN. Interlocking triple pelvic osteotomy in severe Legg-Calvé-Perthes disease. *J Pediatr Orthop.* 2002; **22**: 464-470. [PMID: 12131442]
 61. Wenger DR, Pring ME, Hosalkar HS, Caltoun CB, Lalonde FD, Bastrom TP. Advanced containment methods for Legg-Calvé-Perthes disease: results of triple pelvic osteotomy. *J Pediatr Orthop.* 2010; **30**: 749-757. [DOI: 10.1097/BPO.0b013e3181f5a0de]
 62. Olney BW, Asher MA. Combined innominate and femoral osteotomy for the treatment of severe Legg-Calvé-Perthes disease. *J Pediatr Orthop.* 1985; **5**(6): 645-651. [DOI: 10.1097/01241398-198511000-00003]
 63. Handelsman JE. The Chiari pelvic sliding osteotomy. *Orthop Clin North Am.* 1980; **11**(1): 105-125. [PMID: 7360496]
 64. Salvati EA, Wilson PD. Treatment of irreducible hip subluxation by Chiari's iliac osteotomy. A report of results in 19 cases. *Clin Orthop Relat Res.* 1974; **(98)**: 151-161. [DOI: 10.1097/00003086-197401000-00017]
 65. Tönnis D. Normal values of the hip joint for the evaluation of X-rays in children and adults. *Clin Orthop Relat Res.* 1976; **(119)**: 39-47. [PMID: 954321]

66. Crutcher JP, Staheli LT. Combined osteotomy as a salvage procedure for severe Legg-Calvé-Perthes disease. *J Pediatr Orthop*. 1992; 12(2): 151-156. [DOI: 10.1097/01241398-199203000-00002]
67. Clancy M, Steel HH. The Effect of an Incomplete Intertrochanteric Osteotomy on Legg-Calve-Perthes Disease. *Journal of Bone and Joint Surgery*, 1985; **67-A (2)**: 213-216. [PMID: 3968112]
68. Copeliovitch L. Femoral Varus Osteotomy in Legg-Calve-Perthes Disease. *J Pediatr Orthop* 2011; **31**: 189-191. [DOI: 10.1097/BPO.0b013e318223b55c]
69. Won PK, Shah IP, Ramanathan AK, Lee TJ and Song HR. Proximal femoral osteotomy in Legg-Calvé-Perthes disease using a monolateral external fixator: surgical technique, outcome, and complications. *Journal of Pediatric Orthopaedics B* 2017; **26**: 329-335. [DOI: 10.1097/BPB.0000000000000399]
70. Arnoldi C, Linderholm H, Mnschlicher H. Venous engorgement and intraosseous hypertension in osteoarthritis of the hip. *J. Bone Jt Surg* 1972; **54-B**: 409-421. [PMID: 5053885]
71. Curtis BH, Gunther SF, Gossling HR, and Paul SW. Treatment for Legg Perthes' disease with the Newington ambulation abduction brace. *Journal of Bone and Joint Surgery A* 1974; **56(6)**: 1135-1146 [PMID: 4436350]
72. Katz JF. Conservative treatment of Legg-Calve-Perthes disease. *J. Bone Jt Surg* 1967; **49-A**, 1043 [PMID: 6038855]
73. Petric JG, Bitenc I. The abduction weight bearing treatment in Legg. *J Bone Joint Surg Br*. 1971; 53(1): 54-62. [PMID: 5578766]
74. Axer A, Schiller MG, Segal D, Rzetelny and Dershuni-Gord DH. Subtrochanteric Osteotomy in the Treatment of Legg-Calve-PerthesSyndrom (L.C.P. s). *Actaorthop. Scand* 1973; **44**: 31-54. [DOI: 10.3109/17453677308988671]