

## Congenital Absence of the Long Head of Biceps and Posterior Radial Head Dislocation

Paramita Mitra<sup>1</sup>, Anestis Iossifidis<sup>1</sup>

<sup>1</sup> Department of Trauma and Orthopaedic Surgery Croydon University Hospital, London, United Kingdom.

**Conflict-of-interest statement:** The author(s) declare(s) that there is no conflict of interest regarding the publication of this paper.

**Open-Access:** This article is an open-access article which was selected by an in-house editor and fully peer-reviewed by external reviewers. It is distributed in accordance with the Creative Commons Attribution Non Commercial (CC BY-NC 4.0) license, which permits others to distribute, remix, adapt, build upon this work non-commercially, and license their derivative works on different terms, provided the original work is properly cited and the use is non-commercial. See: <http://creativecommons.org/licenses/by-nc/4.0/>

**Correspondence to:** Anestis Iossifidis, MD, FRCS Ed, FRCS Ed (orth.) Head of Orthopaedic Surgery, Croydon University Hospital, 530 London Road, Croydon, London, CR7 7YE, United Kingdom.

Email: [anestis.iossifidis@gmail.com](mailto:anestis.iossifidis@gmail.com)

Telephone: +0044 (0) 7802404708

Received: June 10, 2020

Revised: June 28, 2020

Accepted: July 1 2020

Published online: August 28, 2020

### ABSTRACT

Congenital absence of long head of biceps is an uncommon condition. We report the first case of bilateral congenital absence of long head of biceps tendon in a young male presenting with recurrent anterior right shoulder dislocation associated with an ipsilateral congenital radial head dislocation. This association has not hitherto been described. We present the clinical, imaging and arthroscopic findings, as well as a review of literature to promote awareness of this rare pathology and discuss its role in joint instability and associated congenital abnormalities.

**Key words:** Shoulder surgery; Shoulder instability; Congenital biceps absence; Congenital radial head dislocation

© 2020 The Author(s). Published by ACT Publishing Group Ltd. All rights reserved.

Mitra P, Iossifidis A. Congenital Absence of the Long Head of Biceps and Posterior Radial Head Dislocation. *International Journal of Orthopaedics* 2020; 7(4): 1346-1348 Available from: URL: <http://www.ghrnet.org/index.php/ijo/article/view/2982>

### INTRODUCTION

Congenital absence of the long head of biceps tendon (LHBT) is an extremely rare condition with only eleven cases reported, 7 unilateral and 4 bilateral. Presentation usually falls into categories of shoulder pain, shoulder instability following an innocuous traumatic episode, or rotator cuff pathology with impingement. Clinical diagnosis is challenging as this pathology can commonly be seen by imaging and arthroscopy. Presence of this agenesis should prompt the clinician to exclude other congenital pathologies and vice versa.

### CASE REVIEW

A 28 year old male with no comorbidities presented with right shoulder anterior instability due to recurrent anterior dislocation caused by minimal traumatic episodes. His contralateral left shoulder was asymptomatic. Examination of the right shoulder confirmed anterior instability with apprehension. A bony prominence posterior to the olecranon of the right elbow was also noticed. The elbow joint had full range of motion and remained pain free. Radiographs confirmed a posterolateral dislocation of the radial head with an associated hypoplastic capitellum and chronic convexity of the radial head articular margin with a rounded appearance to the radial head-neck junction (Figure 1). Magnetic resonance arthrogram (MRA) of the right shoulder showed a shallow posterior Hill Sach's defect and a chronic anteroinferior labral tear of the ALPSA type (Anterior Labroligamentous Periosteal Sleeve Avulsion) (Figures 2 and 3).

An arthroscopic stabilization was performed including a labral repair and a superior capsular shift. As the long head of biceps tendon was found to be absent on arthroscopy, a retrospective review of the right shoulder MRA by a musculoskeletal radiologist revealed an absent long head of biceps tendon and hypoplastic bicipital groove. An ultrasound scan of the asymptomatic left shoulder also revealed absence of the long head of biceps tendon and hypoplasia of the bicipital groove (Figure 4). The patient regained good shoulder function and remained asymptomatic without recurrence at 5 years follow up.

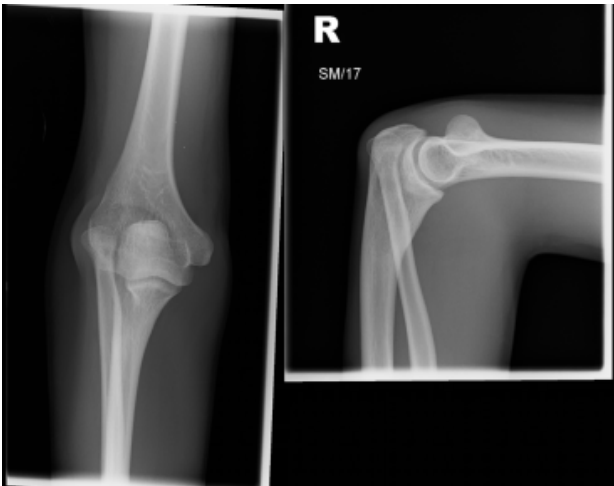


Figure 1 Radiographs of Right Elbow AP, Lat views.

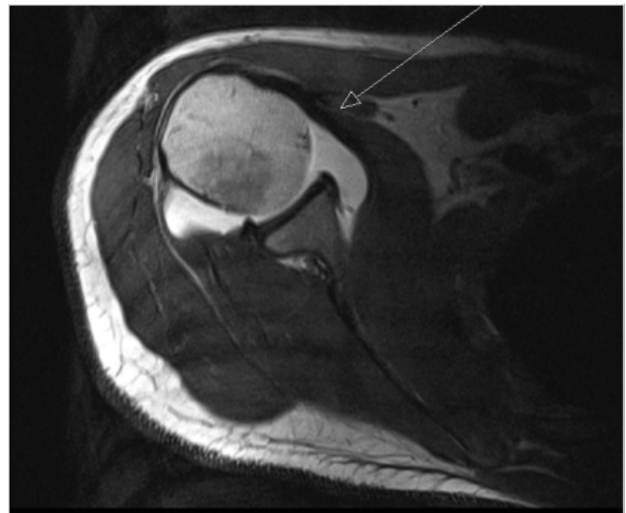


Figure 2 MRI Arthrogram. T1 Fat saturated axial with intra articular gadolinium showing hypoplastic bicipital groove and absent long head of biceps tendon.

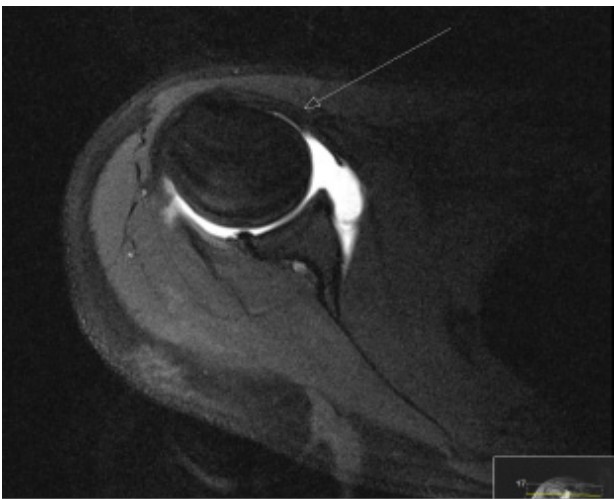


Figure 3 T1 without fat saturation with intra articular gadolinium showing ALPSA lesion.

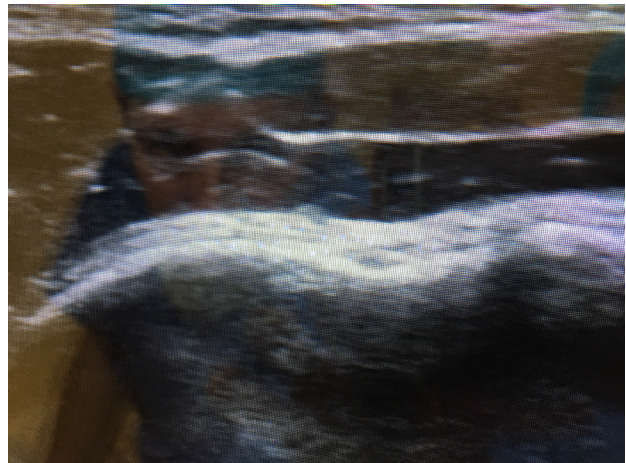

Figure 4 Ultrasound scan of left shoulder showing Hypoplastic groove and absent lhbt.

## DISCUSSION

Anatomically, the long biceps tendon originates from both the supraglenoid tubercle and superior labrum. Embryological development of the long head of biceps occurs along with the glenoid labrum and joint capsule from the embryonic mesoderm. Subsequently, the capsule and the ligaments differentiate from the synovial layer. Differentiation of the biceps tendon occurs during the 6th and 8th week of embryonic development, hence any alterations at this crucial period may result in long biceps tendon malformations<sup>[1]</sup>. In some cases agenesis of LHBT may be associated with other congenital malformations such as glenoid dysplasia<sup>[2]</sup>, Radial defects<sup>[3]</sup> and, as in our case, a congenital posterior dislocation of the elbow.

Review of the literature showed that in congenital absence of the long head of biceps tendon, the patient is often male (10 out of 11 cases) with a mean age of 28 (range 17 to 40), presenting with either shoulder instability (5 cases) or shoulder pain (6 cases) with impingement in 3 of these cases. Biceps muscle bulk and strength are usually normal. A ‘pop eye’ sign is never observed, which differentiates this condition from a tear of the long head of biceps. Imaging studies such as magnetic resonance imaging (MRI) or MRA with gadolinium intra articular contrast are able (a) to detect a shallow or hypoplastic bicipital groove with an absent tendon on T1 fat saturated axial

images and (b) differentiate between a ruptured tendon with distal retraction and agenesis. Commonest associated MRI findings were labral tears and redundant capsular-ligamentous complex. In our case, an ultrasound scan could also detect a shallow hypoplastic bicipital groove and an absent biceps tendon. Most arthroscopic procedures in the literature involved repairs of Labrum and / or capsulorrhaphy. All patients had a satisfactory recovery and did not have any recurrence of symptoms<sup>[2-11]</sup>.

The LHBT has been shown to act as a dynamic stabiliser and a depressor of the humeral head during abduction of the glenohumeral joint in the scapular plane<sup>[12]</sup>. Additionally, it acts as an anterior stabiliser by decreasing the forces across the inferior glenohumeral ligament complex<sup>[13]</sup>. It is thought therefore that LHBT absence may predispose the joint to instability. We believe however that this is a correlation and not a causation. It is possible that a capsular malformation occurring during the critical embryonic period of abnormal differentiation and biceps agenesis, may be responsible for the future joint instability. Indeed the most common arthroscopic findings are those of capsular redundancy and labral tears. In addition following capsular ligamentous repair the joint stability is maintained, in our case for 5 years, without recurrence despite LHBT absence, which we think is merely a coexisting developmental pathology.

## CONCLUSION

Agenesis of long head of biceps is a rare condition and most reported cases present with the common symptoms of shoulder joint instability. Awareness of this condition is paramount and should prompt the clinician to exclude other associated congenital malformations.

## REFERENCES

1. Murillo-González J, De La Cuadra-Blanca C, Arráez-Aybara LA, Herrera-Lara ME, Minuesa-Asensiob A, Mérida-Velasco JR. Development of the long head of the biceps brachial tendon: A possible explanation of the anatomical variation. *Annals of Anatomy* 218; **2018**: 243-9. [PMID: 29730466]; [DOI: 10.1016/j.aanat.2018.04.004]
2. Sayeed SA, Shah JP, Collins MS, Dahm D. Absence of the long head of the biceps tendon associated with glenoid dysplasia and posterior labral tear," *Clinical Anatomy*, 2008; **21(7)**: 728-32. [PMID: 18816444]; [DOI: 10.1002/ca.20713]
3. Maldjian C, Borrero C, Adam R. Nature abhors avacuum: bilateral prominentrotator cable in bilateral congenital absence of the long head of the biceps tendon. *Skeletal Radiology* 2014; **43**: 75-78. [PMID: 23995304]; [DOI: 10.1007/s00256-013-1716-2]
4. Franco JC, Knapp TP, Mandelbaum BR. Congenital absence of the long head of the biceps tendon: A case report. *J Bone Joint Surg Am* 2005 Jul; **87(7)**: 1584-6. [PMID: 15995127]; [DOI: 10.2106/JBJS.D.02459]
5. Gaskin CM, Golish SR, Blount KJ, Diduch DR. Anomalies of the long head of the biceps brachii tendon: Clinical significance, MR arthrographic findings, and arthroscopic correlation in two patients. *Skeletal Radiol* 2007 Aug; **36(8)**: 785-9. [PMID: 17380328]; [DOI: 10.1007/s00256-007-0291-9]
6. Glueck DA, Mair SD, Johnson DL. Shoulder instability with absence of the long head of the biceps tendon. *Arthroscopy* 2003 Sep; **19(7)**: 787-9. [PMID: 12966389]; [DOI: 10.1016/s0749-8063(03)00392-x]
7. Keefe DT, Lowe WR. Symptomatic superior labral anterior posterior lesion with absence of the long head of the biceps tendon: A case report. *Am J Sports Med* 2005 Nov; **33(11)**: 1746-50. [PMID: 16093547]; [DOI: 10.1177/0363546505274933]
8. Mariani PP, Bellelli A, Botticella C. Arthroscopic absence of the long head of the biceps tendon. *Arthroscopy* 1997 Aug; **13(4)**: 499-501. [PMID: 9276058]; [DOI: 10.1016/s0749-8063(97)90130-4]
9. Koplas MC, Winalski CS, Ulmer Jr WH, Recht M. Bilateral congenital absence of the long head of the biceps tendon. *Skeletal Radiology* 2009 Jul; **38**: 715-9. [PMID: 19290522]; [DOI: 10.1007/s00256-009-0688-8]
10. Kuhn KM, Carney J, Solomon D, and Provencher M. Bilateral absence of the long head of the biceps tendon," *Mil Med* 2009 May; **174(5)**: 548-50. [PMID: 20731291]; [DOI: 10.7205/milmed-00-6608]
11. Smith EL, Matzkin EG, Kim DH, Harpstrite JK, Kan DM. Congenital absence of the long head of the biceps brachii tendon as a VATER association. *Am J Orthop (Belle Mead NJ)*. 2002 Aug; **31(8)**: 452-4. [PMID: 12216966]
12. Warner JJP, McMahon PJ. The role of the long head of the biceps brachii in superior stability of the glenohumeral joint. *J bone Joint Surg Am* 1995 Mar; **77(3)**: 366-72. [PMID: 7890785]; [DOI: 10.2106/00004623-199503000-00006]
13. Etoi E, Kuechle DK, Newman SR, Morrey BF, An KN. Stabilizing function of the biceps in stable and unstable shoulders. *J Bone Joint Surg Br* 1993 Jul; **75B(4)**: 546-50. [PMID: 8331107]