

Primary Synovial Chondromatosis of the Elbow

Paramita Mitra¹, Anestis Iossifidis¹

¹ Department of Trauma and Orthopaedic Surgery Croydon University Hospital, London, United Kingdom.

Conflict-of-interest statement: The author(s) declare(s) that there is no conflict of interest regarding the publication of this paper.

Open-Access: This article is an open-access article which was selected by an in-house editor and fully peer-reviewed by external reviewers. It is distributed in accordance with the Creative Commons Attribution Non Commercial (CC BY-NC 4.0) license, which permits others to distribute, remix, adapt, build upon this work non-commercially, and license their derivative works on different terms, provided the original work is properly cited and the use is non-commercial. See: <http://creativecommons.org/licenses/by-nc/4.0/>

Correspondence to: Anestis Iossifidis, MD, FRCS Ed, FRCS Ed (orth.) Head of Orthopaedic Surgery, Croydon University Hospital, 530 London Road, Croydon, London, CR7 7YE, United Kingdom.
Email: anestis.iossifidis@gmail.com
Telephone: +0044 (0) 7802404708

Received: June 10, 2020

Revised: June 20, 2020

Accepted: July 25 2020

Published online: August 28, 2020

ABSTRACT

We present a rare case of primary synovial chondromatosis of the elbow joint as well as a review of the literature and discuss the clinical, imaging, histological findings and clinical outcome of this condition. It is a benign condition characterized by nodular proliferation and metaplasia of the synovium. Histology findings however suggest that the condition is not solely a metaplasia as the cartilage is often very cellular and could be interpreted as a neoplastic process. This may explain in rare cases the incidence of recurrences and malignant transformation of this condition. Awareness of the atypical histology is paramount and therefore referral to a tertiary oncology centre is mandatory. An experienced pathologist is crucial for the correct diagnosis, prognosis and management of this condition.

Key words: Elbow joint; Synovial osteochondromatosis; Osteochondral loose bodies

© 2020 The Author(s). Published by ACT Publishing Group Ltd. All rights reserved.

Mitra P, Iossifidis A. Primary Synovial Chondromatosis of the Elbow. *International Journal of Orthopaedics* 2020; 7(4): 1349-1351 Available from: URL: <http://www.ghrnet.org/index.php/ijo/article/view/2983>

INTRODUCTION

Primary synovial chondromatosis (PSC) is an uncommon benign mono-articular disorder characterised by chondrometaplasia of the synovium resulting in cartilaginous deposits in the synovium, and multiple intra articular loose bodies mainly of the knee joint. We present a rare case of primary synovial chondromatosis of the elbow joint as well as a review of the literature and discuss the clinical, imaging, histological findings and clinical outcome of this condition.

CASE REVIEW

A 42 year old doctor presented three months following a hyperextension injury with persistent left nondominant elbow anterolateral pain and stiffness restricting his daily activities. Examination revealed deep tenderness in the anterolateral aspect of the elbow joint. The range of motion of the elbow was restricted from 40 to 120 degrees of flexion and the Mayo Elbow Performance Score was 50 out of 100 points. Plain radiographs of the elbow showed multiple intra articular ossified bodies anteriorly (Figures 1 and 2). Magnetic resonance imaging (MRI) confirmed a large ossified body in the coronoid fossa and avulsion of the coronoid tip as well as several low signal foci along with synovial thickening and ulnar trochlear joint arthropathy (Figures 3, 4, 5). Arthroscopy of the elbow revealed synovitis (Figure 6).

A large 8×8 mm and 6 small osteochondral loose bodies were removed (Figure 7). Synovial tissue samples and loose bodies were all sent for histology. The patient was discharged the same day and advised to follow a protocol of active elbow exercises under physiotherapy supervision. Histology confirmed the diagnosis of primary synovial chondromatosis and showed loose bodies composed of mature cartilage with a number of them showing ossifications. Synovial tissue histology revealed focal perivascular lymphocytic infiltrate with occasional plasma cells. At 12 weeks the patient had regained a range of motion of active 10 to 145 degrees of flexion and almost full elbow function with a Mayo Elbow Performance score of 95.

DISCUSSION

Primary Synovial Chondromatosis (PSC) is a rare and benign condition

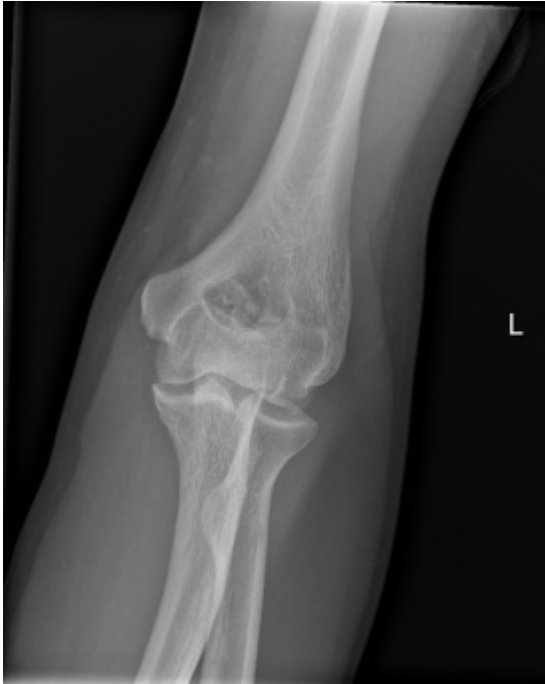

Figure 1 AP view of elbow- Calcified loose bodies in coronoid fossa with mild ulna humeral joint degenerative changes.

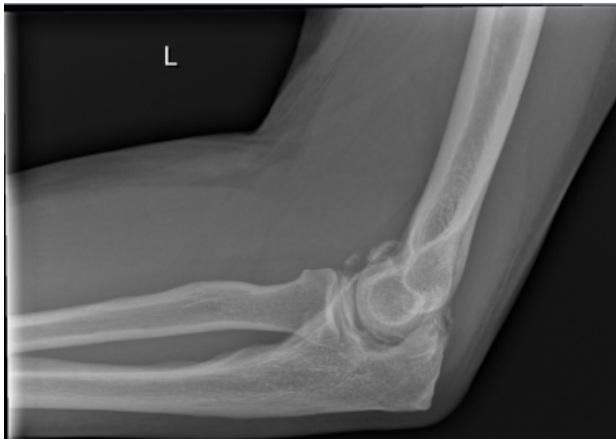

Figure 2 Lateral view of elbow -Calcified loose bodies anteriorly in the coronoid fossa and tip of coronoid process.

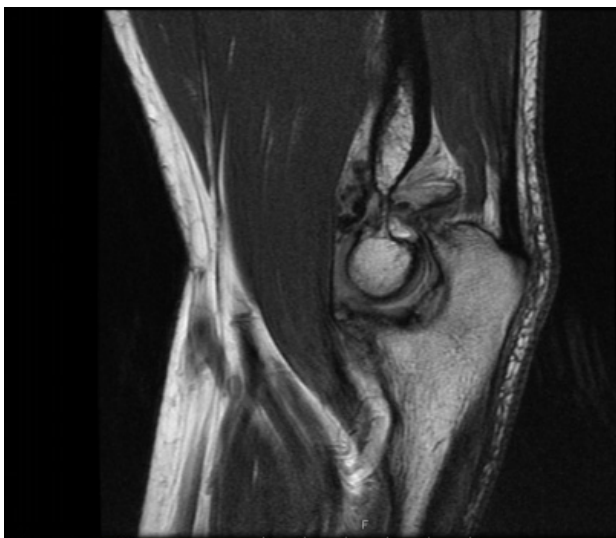


Figure 3 MRI Sagittal T1 sequence showing low signal multiple loose bodies anteriorly in the joint, tip of coronoid process and ulna trochlear arthropathy

characterized by nodular proliferation and metaplasia of the synovium. This can occur in all areas lined by synovium including extra-articular bursa and tendon sheaths. Once the nodules of hyaline cartilage are formed in the synovium, fragmentation may occur resulting in multiple intrarticular loose bodies of various sizes and calcification. PSC has preponderance for males (57%), typically monoarticular and presenting in those aged between 20 and 50 years old. In two large studies of 231

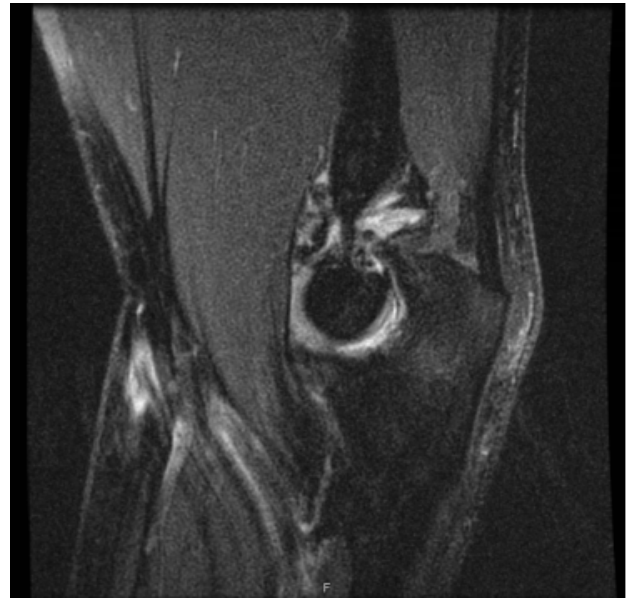

Figure 4 MRI Sagittal T2 sequence showing joint effusion, synovial hypertrophy, low signal loose bodies.

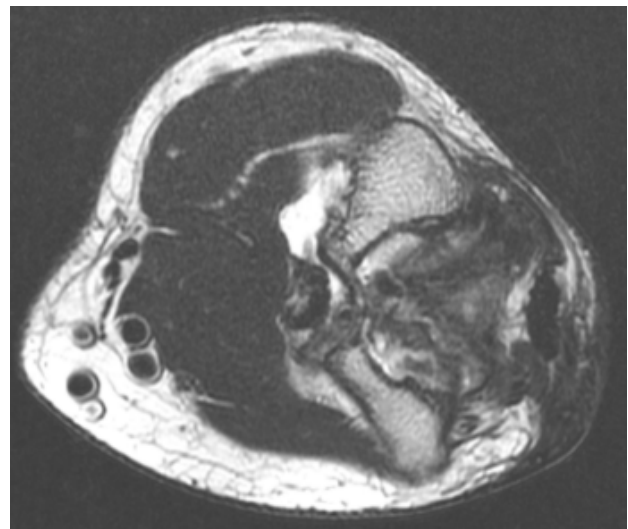


Figure 5 Axial view showing loose bodies in coronoid fossa.

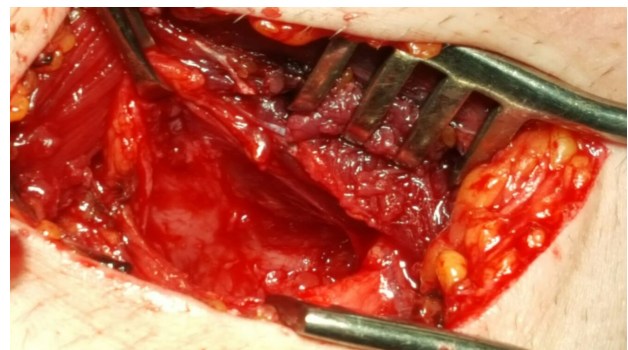


Figure 6 Hypertrophy and inflammation of Synovium.

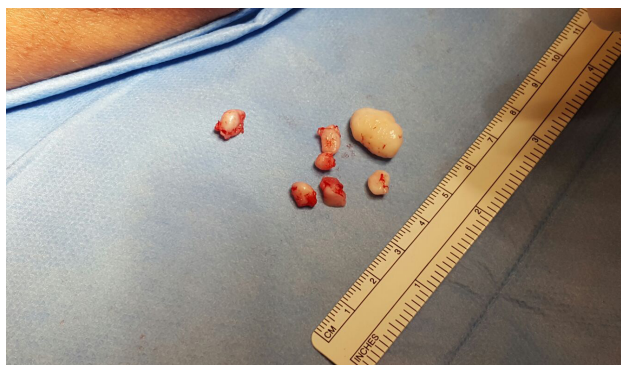

Figure 7 One large and 6 smaller loose bodies removed.

cases the lower limb was affected in 70.9% of cases, primarily the Knee (42%) and Hip (21.2%) joints. Less frequently affected joints are: the foot (5.1%), ankle (2.5%), hand (13.8%), shoulder (5.6%), wrist (3.4%) and elbow^[1,2].

PSC of the elbow is extremely rare with only 44 cases reported over 59 years (1957-2016) with a mean 0.7 elbow cases per year and an incidence of 5.2% of reported PSC (17 elbow joints in 326 PSC cases)^[1,7].

The condition may present in three different phases. Active intrasynovial disease, active intrasynovial proliferation with loose bodies or multiple osteochondral bodies without synovial activity^[5]. The advanced stage may be associated with features of articular degenerative changes.

Clinical symptoms are usually nonspecific in the form of mechanical pain exacerbated by exerting the joint, progressive stiffness, swelling and episodes of locking and catching particularly in the elbow and knee joints^[6,8]. The duration of clinical symptoms before diagnosis varies between 2.5 and 6 years^[3,6,9]. Diagnosis can be achieved with plain radiographs showing multiple intra articular smooth rounded loose bodies with characteristic “ring and arc” chondroid mineralisation and in some cases bone erosions. Magnetic resonance imaging can show low signal cartilaginous deposits or loose bodies, and can assess the extent of synovial involvement, the presence of arthropathy and joint effusion on both T1 and T2 phases^[10]. Differential diagnoses include osteoarthritis, rheumatoid arthritis, neuropathic joints, sequelae of infectious arthropathy, or osteochondral defects.

Treatment of the condition involves arthroscopic or open removal of the loose bodies with partial synovectomy. Both approaches give satisfactory results^[8]. Satisfactory outcome has also been reported following arthroscopic removal of loose bodies in the hip^[11].

Histological features show discreet foci of hyaline cartilage nodules in various stages of calcification and ossification and chondrocytes manifest various atypical features. Lymphocytic and plasma cell infiltrates in the synovium indicate synovitis. These atypical features could suggest a malignant neoplasm to the less experienced pathologist^[2].

The pathogenesis of the condition remains unclear. It is thought to be a cartilage metaplasia although several reports have described malignant transformation after recurrences. The findings suggest that the condition is not solely a metaplasia as the cartilage is often very cellular with binucleate forms and marked nuclear pleomorphism which could be interpreted as a neoplastic process. It appears to occupy a position between enchondroma and chondrosarcoma which may explain in rare cases the incidence of recurrences and malignant transformation of this condition^[1,7]. PSC is indeed usually benign and although it can be locally aggressive with a tendency to recur it has no metastatic potential^[2].

The reported rate of recurrence is between 7.1 % and 15%^[6,9,11].

Malignant transformation rarely occurs as suggested by the fact that only 0.6% of chondrosarcomas are secondary to PSC^[2]. The mean rate of Chondrosarcomatous transformation as reported in three large series is 4.1% (range 2.5% to 6.4%). 2.5% rate in the first series with 3 hips and 1 elbow in 155 PSC cases, 5% rate in the second series with 3 Knees in 53 PSC cases, and 6.4% rate in the third series with 4 hips and 1 knee in 78 PSC cases^[1,2,9]. This rate however is higher than the rate of malignant transformation of other benign conditions. Paget has a rate of

0.7% with 8 cases out of 1078^[12]. Fibrous dysplasia has a rate of 2.4% with 28 cases out of 1122^[13]. The median time from PSC diagnosis to malignant transformation is 20 years (range 2.5 to 39). It is of note that older patients, multiple recurrences and marrow invasion are highly suspicious of malignant transformation^[2].

In conclusion primary synovial chondromatosis is a rare and benign condition of the elbow. Patients presenting with common symptoms of pain, restricted extension and episodes of locking should raise the suspicion of PSC and appropriate imaging with radiographs and MRI scans should be obtained. Removal of loose bodies and biopsies remains the treatment of choice. Awareness of the atypical histology is paramount and therefore referral to a tertiary oncology centre is mandatory. An experienced pathologist is crucial for the correct diagnosis, prognosis and management of this condition.

REFERENCES

1. McCarthy C, et al. Primary synovial chondromatosis: a reassessment of malignant potential in 155 cases. *Skeletal Radiol.* 2016; **45(6)**: 755-62. [PMID: 26919862]; [DOI: 10.1007/s00256-016-2353-3]
2. Evans S, Boffano M, Chaudry S, Jeys L, Grimer R. Synovial chondrosarcoma arising in synovial chondromatosis. *Sarcoma.* 2014; **2014**: 647939. [PMID: 24737946]; [PMCID: PMC3967817]; [DOI: 10.1155/2014/647939]
3. Kamineni S, O'Driscoll SW, Morrey BF. Synovial osteochondromatosis of the elbow. *J Bone Joint Surg Br* 2002; **84**: 961- 966. [PMID: 12358386]; [DOI: 10.1302/0301-620x.84b7.12766]
4. Mueller T, Barthel T, Cramer A, Werner A, Gohlke F. Primary synovial chondromatosis of the elbow. *J Shoulder Elbow Surg* 2000; **9**: 319-322. [PMID: 10979529]; [DOI: 10.1067/mse.2000.106744]
5. Milgram JM, “Synovial osteochondromatosis: a histopathological study of thirty cases,” *Bone Joint Surg Am.* 1977 Sep; **59(6)**: 792-801. [PMID: 908703]
6. Maurice H, Crone M, Watt I. Synovial chondromatosis. *J Bone Joint Surg Br.* 1988; **70(5)**: 807-811. [PMID: 3192585]
7. Davis RI, Foster H, Arthur K, Trewin S, Hamilton PW, Biggart DJ. Cell proliferation studies in primary synovial chondromatosis. *J Pathol.* 1998; **184**: 18-23. [PMID: 9582522]; [DOI: 10.1002/(SICI)1096-9896(199801)184:1<18::AID-PATH956>3.0.CO;2-J]
8. Flury MP, Goldhahn J, Drerup S, Simmen BR. Arthroscopic and Open Options for Surgical Treatment of Chondromatosis of the Elbow. *Arthroscopy.* 2008 May; **24(5)**: 520-5.e1. [PMID: 18442683]; [DOI: 10.1016/j.arthro.2007.12.002]
9. Davis RI, Hamilton A, Biggart JD. Primary synovial chondromatosis: a clinico-pathologic review and assessment of malignant potential. *Hum Pathol.* 1998; **29(7)**: 683-688 [PMID: 9670824]; [DOI: 10.1016/s0046-8177(98)90276-3]
10. Houbart MA, Passoglou V, Gérard L, Mustapha SB, Kurth W, E. Mutijima WE, Si-moni P. Primary (osteo)chondromatosis of the elbow JBR-BTR, 2014, **97**: 154-155. [PMID: 25223124]; [DOI: 10.5334/jbr-btr.57]
11. De Sa D, Horner NS, MacDonald A, et al. Arthroscopic surgery for synovial chondromatosis of the hip: a systematic review of rates and predisposing factors for re-occurrence. *Arthroscopy* 2014; **30**: 1499.e2-504.e2. [PMID: 25064754]; [DOI: 10.1016/j.arthro.2014.05.033]
12. Hadjipavlou A, Lander P, Srolovitz H, Enker IP. Malignant transformation in Paget disease of bone. *Cancer.* 1992 Dec 15; **70(12)**: 2802-8. [PMID: 1451058]; [DOI: 10.1002/1097-0142(19921215)70:12<2802::aid-cncr2820701213>3.0.co;2-n]
13. Ruggeri P, SIM FH, Bond JR, Unni KK. Malignancies in fibrous dysplasia, *Cancer* 1994; **73**: 1411-1424. [PMID: 8111708]; [DOI: 10.1002/1097-0142(19940301)73:5<1411::aid-cncr2820730516>3.0.co;2-t]