

Arthroscopic Repair of Acute Bony Bankart Lesions: An Analysis of Risk Factors for Instability Recurrence

Jose María Silberberg Muiño¹, Alessandro Nilo Fulvi²

1 Orthopaedic Surgery and Traumatology Head Department. Sport Medicine Unit. Clínica Universidad de Navarra- Madrid, Spain;

2 Orthopaedic Surgery and Traumatology Head Department. Chief of Upper Limb Unit at Centro de Especialidad Articular. Hospital Faro Del Mayab, Mérida-Yucatán, México.

Conflict-of-interest statement: The author(s) declare(s) that there is no conflict of interest regarding the publication of this paper.

Open-Access: This article is an open-access article which was selected by an in-house editor and fully peer-reviewed by external reviewers. It is distributed in accordance with the Creative Commons Attribution Non Commercial (CC BY-NC 4.0) license, which permits others to distribute, remix, adapt, build upon this work non-commercially, and license their derivative works on different terms, provided the original work is properly cited and the use is non-commercial. See: <http://creativecommons.org/licenses/by-nc/4.0/>

Correspondence to: Alessandro Nilo Fulvi, Calle 24 s/n x 7 y 7A Santa Gertrudis, Copó, 97115 Mérida, Yucatán. Postal Code. 97124.
Email: a.nilofulvi@gmail.com
Telephone: + (52) 8180208672

Received: September 3, 2020

Revised: November 7, 2020

Accepted: November 10 2020

Published online: December 28, 2020

ABSTRACT

PURPOSE: To determine clinical and radiological outcomes of patients with acute bony Bankart lesions treated via the arthroscopic approach and evaluate the hypothesis that instability recurrence is associated with fragment reduction quality and/or glenoid defect.

MATERIAL AND METHODS: Between 2008 to 2013, 27 patients (mean age 24.3 years) were examined before, and (on average) 29 months after, arthroscopic repair. Inclusion criteria were acute bony Bankart lesions, glenoid osseous defects of less than 20%, and postoperative follow-up period of at least 24 months. Functional recovery was assessed using the Rowe, Western Ontario Shoulder Instability Index (WOSI), and UCLA shoulder rating scales. Computed tomography scans were used to evaluate reduction

and healing of bony fragments. Cases of instability recurrence were documented.

RESULTS: Postoperative mean Rowe score was 90.4 points (range, 35 to 100 points), the mean WOSI was 282.0 (range, 25-1100 points), and the mean UCLA was 28.5 points (range, 15 to 35 points). The recurrence rate of shoulder instability was 7.4% (2/27), which only occurred in cases of fragment malposition. The average loss of external rotation was 5° at 0° of abduction, and 7° at 90° of abduction. Twenty three patients (85.19%) returned to preinjury sport level. Radiological assessment revealed complete union of the bony fragment in all cases.

CONCLUSION: Arthroscopic reduction and suture anchor fixation of acute bony Bankart lesions yield excellent outcomes providing a low recurrence instability and high bone union rates. In addition, non-anatomical reduction of the bony fragment is a reliable risk factor for instability recurrence in acute cases.

Key words: Arthroscopic bony Bankart; Joint instability; Shoulder dislocation; Suture anchors

© 2020 The Author(s). Published by ACT Publishing Group Ltd. All rights reserved.

Muiño JMS, Fulvi AN. Arthroscopic Repair of Acute Bony Bankart Lesions: An Analysis of Risk Factors for Instability Recurrence. *International Journal of Orthopaedics* 2020; 7(6): 1382-1389 Available from: URL: <http://www.ghrnet.org/index.php/ijo/article/view/2988>

INTRODUCTION

Bony Bankart lesions follow anterior glenohumeral dislocations ranging from 5.4% to 70%^[1-4]. Such lesions have historically been treated by open reduction and fixation^[1,5]. However, there have been many encouraging reports more recently of excellent results following treatment through arthroscopic reduction and fixation^[2,3,6-10]. The outcome following repair of bony Bankart lesions is affected by many factors such as: chronicity of the lesion, glenoid defect or bony fragment size, bone union, and reduction quality^[6,7,9,11-14]. Moreover, despite the consensus in the literature advocating for early stabilization of bony Bankart lesions^[9,13,14], this recommendation is based on only a few clinical trials of cases with acute lesions^[3,9]. Thus, the present study sought to clarify which risk factors are associated with

positive or negative outcomes following arthroscopic stabilization among patients with acute bony Bankart lesions.

Here, we report clinical and radiological outcomes of 27 patients with acute bony Bankart lesions treated through arthroscopic reduction and fixation with single row suture anchors and analysed a variety of risk factors potentially linked to failure in acute lesion cases. We hypothesized that arthroscopic fixation with suture anchors would yield satisfactory outcomes, and that fragment reduction quality and glenoid defect would be associated with instability recurrence in acute bony Bankart lesions.

MATERIALS AND METHODS

Subjects and study design

A prospective clinical study of arthroscopic repair of bony Bankart injuries from January 2008 to July 2013 was performed at our institution. During this period, 182 patients were treated for arthroscopic repair after an anterior shoulder dislocation. Our inclusion criteria for this study were: patients with an acute bony Bankart lesion with less than 3 months from initial injury to time of surgery, glenoid osseous defects of less than 20%, and posterior follow up period of at least 24 months.

Patients with chronic injuries (more than 3 months), rotator cuff lesions or full-thickness tears, or those who required additional treatment for posterior, superior labral lesions and/or multidirectional instability, voluntary shoulder instability, or had previously undergone surgery in the affected shoulder, or who suffered from neurologic disorders involving the shoulder girdle, were excluded. Inability to participate in our postoperative rehabilitation protocol was also considered an exclusion criterion.

The 27 patients who passed the exclusion criteria underwent arthroscopic repair of acute bony Bankart lesions after prior approval of the institutional research ethics committee and informed written consent of all study participants had been obtained.

Preoperative evaluation

All patients were physically examined prior to surgery. Pain during range of motion examination and positive antero-inferior instability tests were observed in all cases (apprehension, re-colocation, and anterior drawer). Preoperative radiological assessment was performed in consensus between an experienced musculoskeletal radiologist (ARO) and orthopaedic surgeon (JS). Anteroposterior (AP) and axillary radiographic views were obtained (Figure 1), and computer tomography (CT) scan was performed. The use of axial, coronal and sagittal planes allowed generation of a 3D CT reconstruction for quantification of glenoid bone defects using the method described by Sugaya *et al*^[5]. Patients were classified according the glenoid defect surface as small defect group (> 10% of glenoid surface) and medium defect group (between 10 to 20% of glenoid surface). Capsulolabral and chondral defects were also assessed by MRI.

Surgical technique

All patients underwent general and regional anaesthesia in the lateral decubitus position, with the arm suspended in abduction of 30 degrees with the assistance of a 4-5 kg traction device. Previous examination assessing glenohumeral translation was performed before starting diagnostic arthroscopy. Standard posterior, antero-inferior, and antero-supero-lateral portals were created. The fracture site and the bone fragment were dissected free of scar tissue preserving the labrum and inferior glenohumeral ligament complex to the bony fragment (Figure 2).

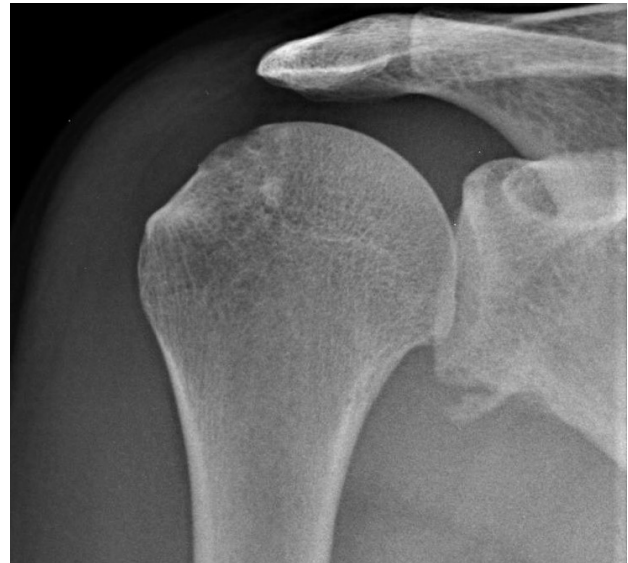

Figure 1 Anteroposterior projection. Evidence of a bony Bankart lesion at the inferior glenoid rim.

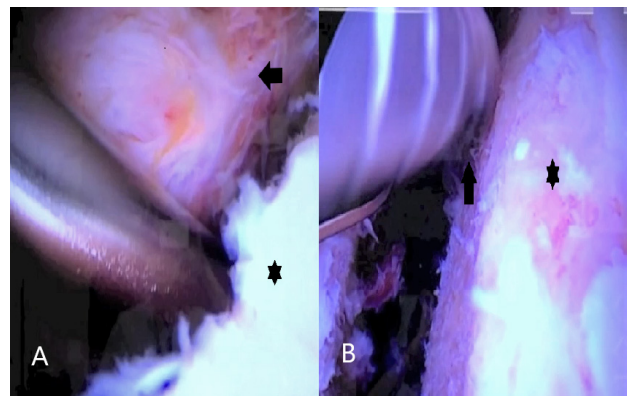


Figure 2 Arthroscopic superior view of the fracture site from the antero-supero-lateral portal. (A) The asterisk indicates the native glenoid and the black arrow indicates the bony Bankart fragment. (B). Preparation of the glenoid rim and neck (asterisk) with a high-speed burr (black arrow) prior to anchor placement.

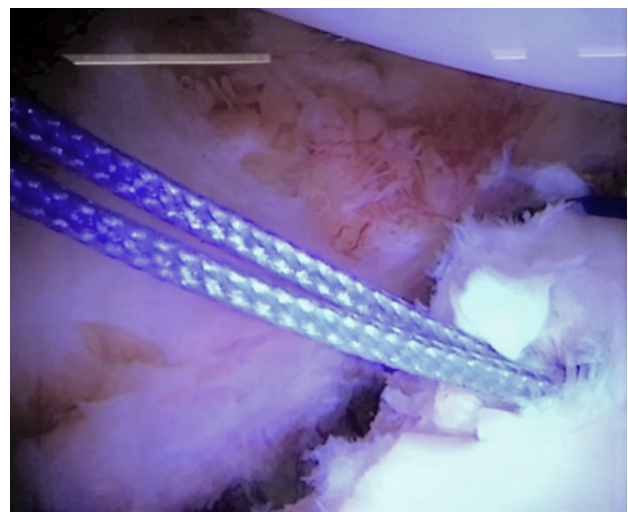


Figure 3 Arthroscopic superior view of the fracture site from the antero-supero-lateral portal. First Anchor placement at the 5:00 o'clock position (right shoulder). The exact placement of the first anchor was determined by the size of the bony fragment, aiming to place this anchor adjacent at the middle portion of the bony fragment.

All suture anchors were inserted along healthy glenoid rim cartilage. Although the number of suture anchors depended on the size of the bony fragment, generally 3 or 4 anchors were used. The first anchor (1.4 mm simple loaded all-suture anchor) was positioned in the inferior aspect of the native glenoid (5:00 or 5:30 o'clock position for right shoulder) through the antero-inferior portal (Figure 3). Then the sutures were passed through the inferior capsule to reduce the extent of inferior capsular recess and stabilize the bone fragment. These sutures were left untied, permitting adequate mobilization of the osseous fragment.

The second suture anchor was then inserted either through the antero-inferior portal or via percutaneous trans-subscapularis portal. Care was taken to place this anchor above the glenoid articular margin, and during this step one or two anchors were placed depending of the bony fragment size. Then, a 1.6 mm drill guide was subsequently brought through the posterior portal, while also taking control of the fragment through the antero-inferior portal with a grasper device. Single or double holes were then drilled into the bony fragment (Figure 4).

Once drilling was complete, a long spinal needle was placed into the drilled hole(s) through the posterior portal, and a number 1 PDS suture was passed through the spinal needle and retrieved trough the antero-inferior portal. Fixation was done from inferior to superior, and configuration was done in relation with the fragment size. Single vertical suture configuration was used for small fragments, whereas two vertical suture or horizontal mattress configuration was employed for medium fragments. Both suture configurations permitted and adequate position of the bony fragment into the glenoid defect area (Figure 5).

Finally, further anchors were placed superiorly in the same manner to ensure an adequate capsule-labral reconstruction.

Postoperative rehabilitation protocol

All patients underwent the same postoperative protocol used for conventional Bankart repair. Immobilization in a simple shoulder sling was indicated for 6 weeks, and pendulum exercises were allowed for several times a day beginning day after surgery. After the third week, patients began passive-assisted mobilization while avoiding external rotation. Active motion and passive external rotation were started after 6 weeks. Patients were permitted to practice noncontact sports at 16 weeks, and to return to contact sports after 8 months.

Postoperative evaluation

Clinical evaluations were performed at 6 weeks, 3 months, 6 months, 1 year, and then annually after the surgical procedure. Functional outcomes were evaluated by an independent observer (ANF), and rated by the ROWE, WOSI and UCLA Scores^[4,16,17]. Additionally, the patient's overall satisfaction with the surgical outcome was obtained using a Likert-style question (very satisfied, satisfied, partly satisfied). Radiological postoperative follow up assessments were performed at 3 and 6 months. 3D and multiplanar reconstruction CT scan images were assessed for adequate position of the fragment and bone union. Continuity of the bone fragment with the glenoid in multiplanar slices was considered to indicate union. Quantification of the articular step between the bony fragment and glenoid articular margin in the axial and coronal planes was assessed to determine the bony fragment position. Patients were classified depending on the quality of the fragment reduction into anatomic or non-anatomic reduction. An articular step of 2 mm or less was consider as an anatomic, while a step of over 2 mm was considered non-anatomic.

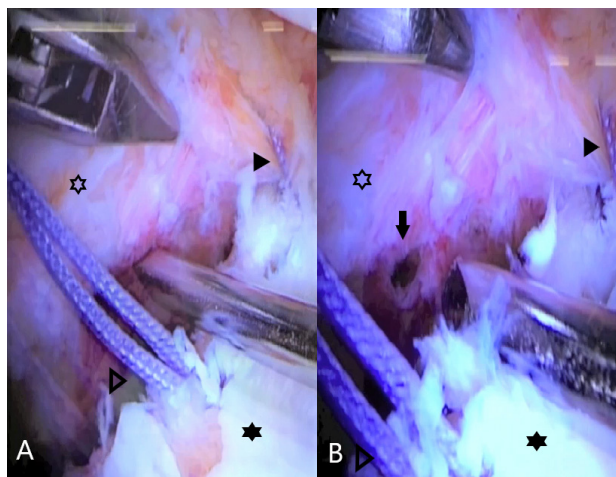


Figure 4 Arthroscopic view from the antero-supero-lateral portal. A hole at the middle segment of the bony fragment is performed with a 1.6 mm drill guide through the posterior portal while taking control of the fragment through the antero-inferior portal with a grasper device. (A) Native glenoid (black asterisk), anchor for trans-osseous suture configuration (open triangle), bony fragment (open asterisk) and lowest not trans-osseous suture stitch (black triangle). (B) Bony fragment drilled hole at the middle segment (black arrow).

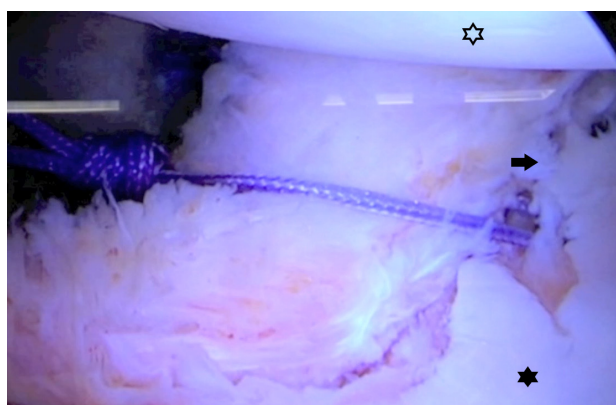

Figure 5 Final repair with trans-osseous configuration at the middle portion of the bony fragment through arthroscopic view from the antero-supero-lateral portal. Humeral head (open asterisk), native glenoid (black asterisk), and reduction and position of the bony fragment (black arrow).

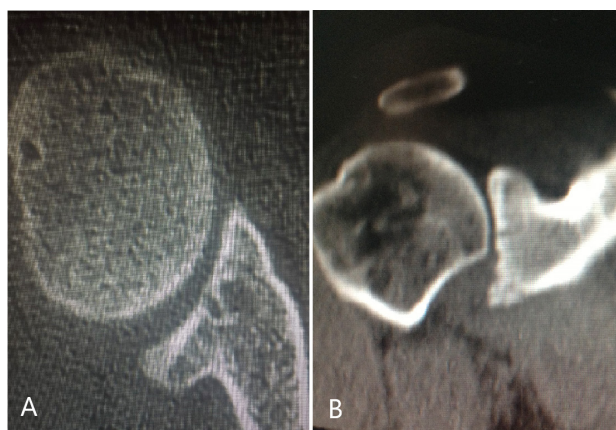

Figure 6 6-month follow-up CT scan showing complete union of the bony fragment en axial and coronal planes.

Statistical analysis

Descriptive statistics (mean, SE, minimum, median, maximum) were calculated (using R^[18]) for age, time between dislocation to surgery, and postoperative WOSI, Rowe, and UCLA clinical indices were examined for the overall sample, and also for each sex (female,

male) and glenoid defect group (< 10%, 10-20%). This descriptive summary was combined with 2 x 2 (sex x glenoid defect group) factorial ANOVAs (using the car^[19] package in R) to evaluate the extent to which functional outcomes varied as a result of glenoid defect or between the sexes (to determine whether outcomes were sex-dependent). Measures found to be non-normally distributed using the Shapiro-Wilk test were examined instead using an equivalently specified factorial permutation ANOVA with 100,000 iterations^[20-22].

Associations between the primary outcome of interest, recurrent instability, with reduction type and glenoid defect (the primary predictors of interest) were examined using separate Fisher's exact tests^[23] implemented in R (stats^[18] package). Other potential proxy indicators of recurrent instability (postoperative WOSI, Rowe, and UCLA scores) or risk factors (age, sex, dominance of the lesioned shoulder) were also examined using Fisher's exact test or exact logistic regressions (with 10,000 iterations using the elrm^[24] package in R), depending on whether the predictor variable was categorical (Fisher's exact test) or numerical (exact logistic regression).

RESULTS

Participant characteristics

The demographic characteristics of all participants are provided in Table 1. Of the 27 participants included in this study, 19 were men and 8 were female, with a mean age of 24.3 years at time of the surgery (range, 18 to 39; Table 2). The dominant shoulder was affected in

81.4% of the cases, and the average time between the initial dislocation and surgery was 24.6 days (range, 9 to 58; Table 2). All patients were played sports on a non-professional basis and the average follow up period was 29 months. Neither age (2 × 2 ANOVA) nor time from dislocation to surgery (2 × 2 permutation ANOVA) were found to differ between men and women or glenoid defect groups (all main effect and interaction p-values > 0.05; Table 3).

Outcome assessment

At the 6-month follow-up examination, postoperative functional instability was evaluated using the clinical Rowe, WOSI, and UCLA scales. The mean postoperative Rowe score was 90.37 points (SE = 14.2), the mean WOSI was 283.51 (SE = 46.5), and the mean UCLA was 28.48 points (SE = 0.7; Table II). As observed for the above demographic comparisons, factorial permutation ANOVAs for each of the 3 clinical scales by sex and glenoid defect did not reveal any significant main effects or interactions (all p-values ≥ 0.05; Table III), indicating that the neither affected these outcome metrics. Satisfaction with surgical outcome was reported as very satisfied by 88.9% (23/27), satisfied by 7.4% (2/27), and partially satisfied by 7.4% (2/27) of patients. There were no postoperative neurovascular or infection complications, and none of the patients required surgical intervention for shoulder stiffness.

Stability

The recurrence rate of shoulder instability in our population studied

Table 1 Patient demographics and postoperative outcome scores.

patient	age	sex	dominant shoulder	time from dislocation to surgery (days)	glenoid defect	postoperative Rowe score	postoperative WOSI score	postoperative UCLA index	recurrence instability
1	21	M	Yes	14	<10%	95	205	35	no
2	24	F	Yes	21	<10%	90	220	30	no
3	31	M	Yes	18	10-20%	70	440	29	no
4	39	M	No	40	10-20%	95	375	28	no
5	22	F	Yes	57	10-20%	90	455	30	no
6	26	M	Yes	11	<10%	100	410	26	no
7	21	F	Yes	9	<10%	90	105	26	no
8	20	M	Yes	27	10-20%	100	215	28	no
9	23	M	Yes	21	10-20%	70	210	27	no
10	22	M	Yes	29	<10%	100	130	25	no
11	21	F	Yes	20	10-20%	100	120	28	no
12	18	M	Yes	16	10-20%	95	320	25	no
13	26	F	Yes	14	<10%	95	375	30	yes/re-dislocation
14	33	M	Yes	22	10-20%	70	770	29	no
15	31	F	Yes	35	<10%	90	430	27	no
16	24	M	No	40	<10%	35	1100	15	yes/subluxation episodes
17	24	M	Yes	42	10-20%	95	510	27	no
18	19	F	Yes	58	10-20%	90	30	28	no
19	22	M	Yes	16	<10%	100	50	29	no
20	30	F	No	18	10-20%	95	120	30	no
21	25	M	Yes	23	<10%	100	205	28	no
22	20	M	Yes	24	<10%	100	340	28	no
23	21	F	Yes	26	<10%	95	235	30	no
24	23	F	Yes	15	10-20%	90	75	35	no
25	24	F	Yes	17	<10%	95	25	33	no
26	26	F	No	16	10-20%	100	50	31	no
27	20	M	Yes	14	10-20%	95	105	32	no

Bone Glenoid Defect: 1^o Group: >10% of glenoid surface. 2^o Group: 10-20%. Rowe Score. WOSI: The Western Ontario Shoulder Instability Index. UCLA: Shoulder rating scale.

was 7.4 % (2/27). Of the two patients exhibiting instability, one reported a non-traumatic re-dislocation at 11 months after surgery requiring revision repair with bone grafting procedure (open Latarjet-Patte), while the other experienced recurrent subluxations during sport activities but refused to undergo surgical revision repair. To evaluate associations between recurrent instability, demographic characteristics, and postoperative outcomes, Fisher’s exact test or exact logistic regression were used according to whether the predictor was categorical or numeric (see Methods). These tests revealed that recurrent instability was not found to differ due to glenoid defect (< 10% vs. 10-20%; OR = 0 [95% CI: 0-4.868], *p* = 0.222), sex (OR = 0.792 [95% CI: 0.009-67.185], *p* = 1.000), the affected shoulder (dominant vs. non-dominant; OR = 0.154 [95% CI: 0.002-14.247], *p* = 0.279), age (OR: 1.087 [95% CI: 0.676-1.755], *p* = 0.593), time

between dislocation and surgery (OR = 1.004 [95% CI: 0.873-1.143], *p* = 0.477), postoperative Rose score (OR = 0.957 [95% CI: 0 - 1.031], *p* = 0.245), or postoperative WOSI index (OR = 1.005 [95% CI: 1-∞], *p* = 0.304; Table IV). However, there was a trend towards a negative association between instability recurrence and postoperative UCLA score (OR = 0.695 [95% CI: 0.257-1.055], *p* = 0.087; Table 4).

Shoulder function

When compared with unaffected contralateral shoulder, anterior elevation was fully achieved in all cases, and postoperative external rotation at 0° and 90° of abduction was 75° and 83°, respectively. The average loss of external rotation was 5° at 0° of abduction, and 7° at 90° of abduction.

Table 2 Demographic and postoperative outcome summary by glenoid defect group, sex, and overall.

glenoid defect	sex	measure	n	mean	se	min.	median	max.
<10%	F	age	6	24.5	1.5	21	24	31
<10%	M	age	7	22.9	0.8	20	22	26
10-20%	F	age	6	23.5	1.6	19	23	30
10-20%	M	age	8	26.0	2.6	18	24	39
total		age	27	24.3	0.9	18	23	39
<10%	F	time from dislocation to surgery (days)	6	20.3	3.8	9	19	35
<10%	M	time from dislocation to surgery (days)	7	22.4	3.8	11	23	40
10-20%	F	time from dislocation to surgery (days)	6	30.7	8.5	15	19	58
10-20%	M	time from dislocation to surgery (days)	8	25.0	3.8	14	22	42
total		time from dislocation to surgery (days)	27	24.6	2.5	9	21	58
<10%	F	postoperative ROWE score	6	92.5	1.1	90	93	95
<10%	M	postoperative ROWE score	7	90.0	9.2	35	100	100
10-20%	F	postoperative ROWE Score	6	94.2	2.0	90	93	100
10-20%	M	postoperative ROWE Score	8	86.3	4.8	70	95	100
total		postoperative ROWE Score	27	90.4	14.2	35	95	100
<10%	F	postoperative UCLA score	6	29.3	1.0	26	30	33
<10%	M	postoperative UCLA score	7	26.6	2.3	15	28	35
10-20%	F	postoperative UCLA score	6	30.3	1.1	28	30	35
10-20%	M	postoperative UCLA score	8	28.1	0.7	25	28	32
total		postoperative UCLA score	27	28.5	0.7	15	28	35
<10%	F	postoperative WOSI index	6	231.7	62.9	25	228	430
<10%	M	postoperative WOSI index	7	348.6	133.3	50	205	1100
10-20%	F	postoperative WOSI index	6	141.7	64.4	30	98	455
10-20%	M	postoperative WOSI index	8	368.1	74.0	105	348	770
total		postoperative WOSI index	27	282.0	46.5	25	215	1100

Bone Glenoid Defect: 1° Group: >10% of glenoid surface. 2° Group: 10-20%. Rowe Score. WOSI: The Western Ontario Shoulder Instability Index. UCLA: Shoulder rating scale.

Table 3 Demographic and postoperative assessment analysis by glenoid defect and sex.

model = measure ~ glenoid defect*sex	diagnostics		inferential test	results	
	Levene's test (homoscedasticity)	Shapiro-Wilk test (model residuals)		main effects	interaction
age	F(3, 23) = 2.088, p = 0.130	W = 0.951, p = 0.229	ANOVA	glenoid defect: F(1, 23) = 0.309, p = 0.583, sex: F(1, 23) = 0.049, p = 0.826	F(1, 23) = 1.156, p = 0.293
time from dislocation to surgery (days)	F(3, 23) = 0.680, p = 0.573	W = 0.905, p = 0.017	permutation ANOVA	glenoid defect: F(1, 23) = 1.595 p = 0.220, sex: F(1, 23) = 0.122, p = 0.729	F(1, 23) = 0.577, p = 0.454
postoperative Rowe score	F(3, 23) = 0.499, p = 0.687	W = 0.726, p < 0.001	permutation ANOVA	glenoid defect: F(1, 23) = 0.033 p = 0.886, sex: F(1, 23) = 0.831, p = 0.430	F(1, 23) = 0.225, p = 0.692
postoperative WOSI score	F(3, 23) = 0.494, p = 0.690	W = 0.869, p = 0.003	permutation ANOVA	glenoid defect: F(1, 23) = 0.146 p = 0.721, sex: F(1, 23) = 3.478, p = 0.069	F(1, 23) = 0.354, p = 0.571
postoperative UCLA index	F(3, 23) = 1.029, p = 0.398	W = 0.889, p = 0.008	permutation ANOVA	glenoid defect: F(1, 23) = 0.801 p = 0.405, sex: F(1, 23) = 3.036, p = 0.092	F(1, 23) = 0.038, p = 0.856

Bone Glenoid Defect: 1° Group: >10% of glenoid surface. 2° Group: 10-20%. Rowe Score. WOSI: The Western Ontario Shoulder Instability Index. UCLA: Shoulder rating scale.

Table 4 Recurrent instability analysis results.

model = recurrent instability ~ measure	predictor class	inferential test	estimate	odds ratio	odds ratio 95% CI	p-value
age	numeric	exact logistic regression1	$\beta = 0.083$	1.087	0.676 - 1.755	0.593
time from dislocation to surgery (days)	numeric	exact logistic regression1	$\beta = 0.004$	1.004	0.873 - 1.143	0.477
postoperative Rowe score	numeric	exact logistic regression1	$\beta = -\infty$	0.957	0 - 1.031	0.245
postoperative WOSI score	numeric	exact logistic regression1	$\beta = 0.005$	1.005	1 - ∞	0.304
postoperative UCLA index	numeric	exact logistic regression1	$\beta = -0.364$	0.695	0.257 - 1.055	0.087
reduction amount (< 2 mm vs. > 2mm)	categorical	Fisher's exact test2	-	∞^3	3.488 - ∞	0.003
glenoid defect (< 10% vs. 10-20%)	categorical	Fisher's exact test2	-	0	0 - 4.868	0.222
sex (M vs. F)	categorical	Fisher's exact test2	-	0.793	0.009 - 67.185	1.000
dominant shoulder	categorical	Fisher's exact test2	-	0.154	0.002 - 14.247	0.279

1Zamar *et al.*, 2007; 2Agresti, 2007; 3non-anatomical reduction was observed in both cases of recurrent instability.

Return to sports

Among the 27 patients who actively participated in sports preoperatively, 23 of them (85.19%) returned to sporting or recreational activities after surgery at the preinjury level, two patients (7.4%) presented minimal restriction during sporting activities, and the other two patients with instability recurrence were able to return to a lower sport preinjury level, once subsequent treatment was given.

Radiological findings

Before surgery, the average glenoid surface defect was $13.9 \pm 7.8\%$, of which 13 patients (48.1%) presented a small size defect (< 10% of glenoid surface) and 14 patients (51.8%) had a medium size defect (between 10 to 20% of glenoid surface) (Table 4). Postoperatively, a 6-month follow-up CT scan revealed complete union of the bony fragment in all cases and the position of the bony fragment showed an anatomical reduction (flush reduction) in 25 cases (92.60 %) (Figure 6), and non-anatomical reduction in 2 patients (7.40%). Regarding instability recurrence and type of reduction, non-anatomical reduction was only observed in patients also exhibiting instability, a perfect positive correspondence (Fisher's exact test, OR = ∞ [95% CI: 3.488- ∞], $p = 0.003$; Table IV). Among the 2 cases of non-anatomic reduction, one patient showed a 3 mm medial position of the fragment, and the other showed 4.5 mm medial position fragment, while reductions of ≤ 2 mm were observed in the other 25 patients. Radiographic images were also obtained for all patients, and glenohumeral osteoarthritis was not observed in any cases at the time.

DISCUSSION

Our results have shown that arthroscopic reduction and fixation with suture anchors of acute bony Bankart lesions yield satisfactory clinical outcomes, and that non-anatomic reduction of the fragment was consistently found in cases of instability recurrence.

After Porcellini *et al.* published their case series³ on managing acute bony Bankart lesions through arthroscopic approach, many authors have demonstrated satisfactory outcomes with arthroscopic surgical reduction and fixation of glenoid defects^[3,6,9-12,14]. In our study, the average postoperative Rowe score (90.4 points) was very similar to that reported by Kim *et al.*^[7] (92 points) and Jiang *et al.*^[6] (91.1 points). Furthermore, several authors have reported significant improvement in Rowe, WOSI and UCLA postoperative scores after arthroscopic repair of bony Bankart lesions^[6-12,14].

Regarding shoulder function, some loss of external rotation is expected following arthroscopic approach of bony Bankart lesions. In comparing acute versus chronic lesions, Porcellini *et al.*^[9] found a

mean loss of external rotation of 5° at 0° of abduction, and 6° at 90° of abduction in the acute group, a mean loss of external rotation of 20° at 0° and 90° of abduction in the chronic group. In our study, which only include acute lesions, the mean loss of external rotation at 0° and 90° of abduction (5° and 7° respectively) were similar with the degree of loss reported by Sugaya *et al.*^[10] and Mologne *et al.*^[12] We believe that the loss of external rotation after this approach could be related to the degree of preoperative external rotation, as well as the repair of capsulolabral structures during restoration of the antero-inferior defect.

Bone union rate after this approach has been reported to vary between 60% to 100%^[3,6,9-11,13], although viability of the bony Bankart fragment in chronic lesions has been histological studied, suggesting that bony Bankart lesions seemed to be viable and could be used to treat fracture glenoid defects^[25], clinical studies have shown that lesion chronicity is related to the bone union rate^[3,9,10,13,14]. In 2002, Porcellini *et al.*^[3] reported a bone union rate of 92% in patients with acute bony Bankart lesions after employing conventional radiographic assessment. In 2007, they also reported a bone union rate of 100% in acute cases with radiographic and tomographic assessment, compared to 91.7% in chronic cases^[9]. Furthermore, a significant difference in bone union rate between acute and chronic cases was also demonstrated by Porcellini *et al.*^[9]. (95% in acute lesions versus 60% in chronic cases). In our study, we found 100% of bone union rate at 6 months confirmed by computed tomography, supporting the high rate of bone union after arthroscopic repair of bony Bankart lesions in acute phases.

Recurrence of instability after arthroscopic treatment of bony Bankart lesions has been studied, and different related factors had already been largely described. The recurrence rate of instability reported in the literature after arthroscopic approach of bony Bankart lesions ranges from 2.1% to 12.38%^[3,6-14]. The rate of instability in this study was 7.4% (2/27 cases): one case of re-dislocation and one case of repetitive subluxation episodes. Although instability following shoulder dislocation after conservative treatment has been found in younger age patients^[26], an association between recurrence and youth after arthroscopically treatment of bony Bankart lesions has not consistently been demonstrated. Kim *et al.*^[7] found no correlation of recurrence between age at time of surgery and age at the time of first dislocation. In contrast, Porcellini *et al.*^[9] found that patients who present recurrent dislocations were significantly younger at initial dislocation and time of surgery. Nevertheless, in our study the patient who presented a new episode of atraumatic dislocation was 24 years old. Comparing our series with the population studied by Porcellini (mean age 41.2 years), patients in our study were 16.9 years younger (mean age 24.3).

Nakagawa *et al.*^[13] investigated bone fragment union after arthroscopic bony Bankart repair and its influence on postoperative

recurrence, demonstrating that shoulders with complete bone union had a significant lower rate of recurrence (6.1%) than shoulders with partial union, non-union, non-fragment at operation, and absorption (50%). Additionally, their bone union rate was 60% and they showed that most of those complete unions were achieved at 7 months. However, only 9 of 81 patients included in their study had acute lesions. Furthermore, another study by Kitayama *et al*^[11] found that arthroscopic osseous Bankart repair for shoulders with significant glenoid bone loss results in successful outcomes without recurrence after bony union had been obtained. In our study with only acute cases, the dislocation recurrence rate was 3.7% despite finding bone union in all cases at 6 months following treatment. It is highly probable that both the recurrence rate of instability and bone union rate were low in our study due to an increased union rate in acute cases, accompanied by a lower rate of recurrence in complete union cases.

Glenoid defect, bony fragment size, and reduction of the bony fragment have also been recognized as risk factors for recurrence of instability. Burkhart and De Beer^[27] recommended bone grafting when inverted pear configuration of the glenoid is present. Lo *et al*^[28] determined that glenoid bone loss of at least 25% to 27% is necessary to produce an inverted pear glenoid. They also recommended that large osseous defects producing an inverted pear glenoid are not candidates for arthroscopic stabilization, due the high failure rate in those patients.

Arthroscopic stabilization of large glenoid defects has been published more recently. In the present study, we only included patients with small and medium glenoid defects, excluding patients with glenoid defects over 20%. Although no significant correspondence between glenoid defect and instability recurrence was observed, we found that our patient with recurrent dislocation belonged to the medium glenoid defect group, whereas the patient with repetitive subluxation episodes belonged to the small glenoid defect group. Another study by Jiang *et al*^[6] found a residual glenoid after reconstruction of less than 80% in the three patients which had re-dislocation episodes, concluding a higher risk of recurrence with residual glenoid of less than 80%. In contrast, Mologne *et al*^[2] reported satisfactory clinical outcomes after arthroscopic treatment even in presence of an inverted pear glenoid, when bony fragment is incorporated to the capsulolabral structures repair.

After division of bony fragments into small (< 12.5%) and medium sized (12.5%-25%), Kim *et al*^[7] recommended focusing in an adequate soft-tissue repair alone in small defect cases, and anatomic reduction for medium sized fragment cases. Despite the lack of a significant association between reduction and recurrence rate, they did find non-anatomical reduction to be related to improvements in VAS and Rowe scores in cases of medium sized fragments. Furthermore, one of the two patients that had a recurrent traumatic dislocation in their study, had a non-anatomical reduction.

Our study detected a perfect association between non-anatomic reduction and recurrence of instability. The patient which sustained a new atraumatic dislocation episode (medium glenoid defect group) and the patient with repetitive subluxations episodes (small glenoid defect group) both showed fragment medial mal-positioned of 4.5 mm and 3 mm, respectively. According these findings, we suggest that anatomic reduction of the anterior bony fragment and achieving an adequate capsulo-labral tension repair are crucial to decrease the rate of instability during arthroscopic surgical repair among acute bony Bankart lesions.

The main strength of this study is that we only included acute bony Bankart lesions with small and medium glenoid bone defects,

excluding other factors that could influence and be related to instability recurrence. Notably, most patients exhibited anatomic reduction and stable functional recovery, returning to pre-injury sport engagement levels. Unexpectedly, postoperative UCLA scores were found to be more relevant to the odds of recurrent stability after arthroscopic bony Bankart repair than the WOSI or Rowe instability indices, where the odds of instability were found to decrease by 30.5% per unit increase on the UCLA index. However, the wide range of the 95% CI for the odds ratio (0.257 - 1.055) indicates a need for further examination on a larger scale to determine the reliability of this result. In addition to the small sample size (n = 27), this study was limited by a relatively short follow-up period and few radiological assessments. Preoperative clinical scores were not recorded. We also did not consider any further radiological evaluation after obtaining bone union and recommend that future studies also radiologically assess osteoarthritis changes after bony Bankart repair. Finally, we only considered the glenoid bone defect, omitting measurement of the bony fragment. Further follow-up assessments and larger series including only acute bony Bankart lesions, as well comparative studies between acute and chronic lesions are necessary to identify potential risks and factors predictive of instability recurrence.

CONCLUSION

Arthroscopic reduction and suture anchor fixation of acute bony Bankart lesions yields excellent outcomes in association with low recurrence of instability and high bone union rates. We have also identified non-anatomical reduction of the bony fragment as a risk factor for instability recurrence in acute cases. We strongly suggest identification of these lesions in acute phases in order to decrease other risk factors associated with instability recurrence in non-acute lesions.

ACKNOWLEDGEMENT

We would like to thank Dr. Craig Hutton for his assistance with the analysis of the data and editing of the manuscript.

REFERENCES

1. Agresti, A. An introduction to categorical data analysis, 2nd ed. John Wiley & Sons; 2007. ISBN: 978-0-471-22618-5.
2. Anderson, M, & ter Braak, C. Permutation tests for multi-factorial analysis of variance. *J Stat Comput Simul* 2003; **73**(2): 85-113. [DOI: 10.1080/00949650215733]
3. Amstutz HC, Sew HA, Clarke IC. UCLA anatomic total shoulder arthroplasty. *Clin Orthop Relat Res* 1980; **155**: 7-20.
4. Bigliani LU, Newton PM, Steinmann SP, Connor PM, McIlveen SJ. Glenoid rim lesions associated with recurrent anterior dislocation of the shoulder. *Am J Sports Med* 1998; **26**: 41-45.
5. Burkhart SS, De Beer JF. Traumatic glenohumeral bone defects and their relationship to failure of arthroscopic Bankart repairs: significance of the inverted-pear glenoid and the humeral engaging Hill-Sachs lesion. *Arthroscopy* 2000; **16**: 677-694. [DOI: 10.1053/jars.2000.17715]
6. De Palma AF. Fracture and fracture-dislocation of the shoulder girdle. In: Jacob RP, Kristiansen T, Mayo K, *et al.*, eds. *Surgery of the shoulder*. 3rd ed. Philadelphia: JB Lippincott, 1983; 366-367.
7. Fox J, Weisberg S. An {R} companion to applied regression, 2nd ed. Thousand Oaks CA: Sage; 2011. ISBN: 978-1412975148.
8. Frossard J, Renaud O. permuco: permutation tests for regression, (repeated measures) ANOVA/ANCOVA and comparison of signals. 2019. Available from: <https://CRAN.R-project.org/>

- package=permuco
9. Fujii Y, Yoneda M, Wakitani S, Hayashida K. Histologic analysis of bony Bankart lesions in recurrent anterior instability of the shoulder. *J Shoulder Elbow Surg* 2006; **15**: 218-223. [DOI: 10.1016/j.jse.2005.06.006]
 10. Jiang CY, Zhu YM, Liu X, Li FL, Lu Y, Wu G. Do reduction and healing of the bony fragment really matter in arthroscopic bony Bankart reconstruction?: A prospective study with clinical and computed tomography evaluations. *Am J Sports Med* 2013; **41**: 2617-2623. [DOI: 10.1177/0363546513499304]
 11. Kherad-Pajouh S, Renaud O. An exact permutation method for testing any effect in balanced and unbalanced fixed effect ANOVA. *Comput Stat Data Anal* 2010; **54**: 7; 1881-1893. [DOI: 10.1016/j.csda.2010.02.015]
 12. Kim Y-K, Cho S-H, Son W-S, Moon S-H. Arthroscopic repair of small and medium-sized bony Bankart lesions. *Am J Sports Med* 2014; **42**: 86-94. [DOI: 10.1177/0363546513509062]
 13. Kirkley A, Griffin S, McLintock H, Ng L. The development and evaluation of a disease-specific quality of life measurement tool for shoulder instability: the western Ontario shoulder instability index (WOSI). *Am J Sports Med* 1998; **26**: 764-672. [DOI: 10.1177/03635465980260060501]
 14. Kitayama S, Sugaya H, Takahashi N, Kawai N, Tanaka M, Tokai M, et al. Glenoid morphology after arthroscopic osseous Bankart repair for recurrent anterior glenohumeral instability: a 5- to 8-year follow-up. *Arthroscopy* 2013; **29**: e150-e151. Available from: [DOI: 10.1016/j.arthro.2013.07.197]
 15. Lo IK, Parten PM, Burkhart SS. The inverted pear glenoid: an indicator of significant glenoid bone loss. *Arthroscopy* 2004; **20**: 169-174. [DOI: 10.1016/j.arthro.2003.11.036]
 16. Millett PJ, Horan MP, Martetschläger F. The “bony Bankart bridge” technique for restoration of anterior shoulder stability. *Am J Sports Med* 2013; **41**: 608-614. [DOI: 10.1177/0363546512472880]
 17. Mologne TS, Provencher MT, Menzel KA, Vachon TA, Dewing CB. Arthroscopic stabilization in patients with an inverted pear glenoid: Results in patients with bone loss of the anterior glenoid. *Am J Sports Med* 2007; **35**: 1276-1283. [DOI: 10.1177/0363546507300262]
 18. Nakagawa, S., Ozaki, R., Take, Y., Mae, T., & Hayashida, K. Bone Fragment Union and Remodeling After Arthroscopic Bony Bankart Repair for Traumatic Anterior Shoulder Instability with a Glenoid Defect: Influence on Postoperative Recurrence of Instability. *Am J Sports Med* 2015; **43**: 1438-1447. [DOI: 10.1177/0363546515571555]
 19. Park JY, Lee SJ, Lhee SH, Lee SH. Follow-up computed tomography arthrographic evaluation of bony Bankart lesions after arthroscopic repair. *Arthroscopy* 2012; **28**: 465-473. [DOI: 10.1016/j.arthro.2011.09.008]
 20. Plath JE, Feucht MJ, Bangor R, et al. Arthroscopic suture anchor fixation of bony Bankart lesions: Clinical outcome, magnetic resonance imaging results, and return to sports. *Arthroscopy* 2015; **31**: 1472-1481. [DOI: 10.1016/j.arthro.2015.03.005]
 21. Porcellini G, Campi F, Paladini P. Arthroscopic approach to acute bony Bankart lesion. *Arthroscopy* 2002; **18**: 764-769. [DOI: 10.1177/0363546507305011]
 22. Porcellini G, Paladini P, Campi F, Paganelli M. Long-term outcome of acute versus chronic bony Bankart lesions managed arthroscopically. *Am J Sports Med* 2007; **35**: 2067-2072. [DOI: 10.1177/0363546507305011]
 23. R Core Team. R: a language and environment for statistical computing. R foundation for statistical computing. Vienna, Austria; 2018. Available from: <https://www.R-project.org/>
 24. Rowe CR, Patel D, Southmayd WW. The Bankart procedure: A long-term end-result study. *J Bone Joint Surg Am* 1978; **60**: 1-16.
 25. Sugaya H, Moriishi J, Dohi M, Kon Y, Tsuchiya A. Glenoid rim morphology in recurrent anterior glenohumeral instability. *J Bone Joint Surg Am* 2003; **85**: 878-884. [DOI: 10.2106/00004623-200305000-00016]
 26. Sugaya H, Moriishi J, Kanisawa I, Tsuchiya A. Arthroscopic osseous Bankart repair for chronic recurrent traumatic anterior glenohumeral instability. *J Bone Joint Surg Am* 2005; **87**: 1752-1760. [DOI: 10.2106/JBJS.D.02204]
 27. Wasserstein DN, Sheth U, Colbenson K, Henry PD, Chahal J, Dwyer T, Kuhn JE. The true recurrence rate and factors predicting recurrent instability after nonsurgical management of traumatic primary anterior shoulder dislocation: a systematic review. *Arthroscopy* 2016; **32**: 2616-2625. [DOI: 10.1016/j.arthro.2016.05.039]
 28. Zamar D, McNeney B, Graham J. elrm: Software implementing exact-like inference for logistic regression models. *J Stat Softw* 2007; **21(3)**: 1-8. [DOI: 10.18637/jss.v021.i03]