

The Trend in the Management of Traumatic Hip Dislocation in Qatar: A Retrospective Observational Study

Waleed Assad¹ M.D; Abduljabbar Alhammoud¹ M.D; Manaf H Younis¹ M.D MRCS, MPH; Mohammed Al Ateeq Al Dosari¹ FRCSC; Ghalib Ahmed Alhaneedi¹ FRCs

¹ Orthopedics Department, Hamad General Hospital, Hamad Medical Corporation, PO Box 3050, Doha, Qatar.

Conflict-of-interest statement: The author(s) declare(s) that there is no conflict of interest regarding the publication of this paper.

Open-Access: This article is an open-access article which was selected by an in-house editor and fully peer-reviewed by external reviewers. It is distributed in accordance with the Creative Commons Attribution Non Commercial (CC BY-NC 4.0) license, which permits others to distribute, remix, adapt, build upon this work non-commercially, and license their derivative works on different terms, provided the original work is properly cited and the use is non-commercial. See: <http://creativecommons.org/licenses/by-nc/4.0/>

Correspondence to: Dr. Ghalib Ahmed Alhaneedi, MBChB, FRCs (Tr. &Orth.), Senior Consultant Orthopedic Surgeon, Director of Orthopedic Residency Training Program, Ass. Professor Weil Cornell Medical College, Hamad Medical Corporation, Qatar.
Email: ghaliboudah@yahoo.com, gahmed@hamad.qa
Telephone: +0097455975125

Received: October 13, 2020

Revised: November 17, 2020

Accepted: November 18 2020

Published online: December 28, 2020

ABSTRACT

BACKGROUND: Traumatic hip dislocation is a severe orthopedic injury that demands urgent reduction to decrease the long-term complications. This study aimed to assess the outcomes and describe the epidemiological profile of adult's traumatic hip dislocation in Qatar.

METHODS: A retrospective analysis was conducted for 56 patients who were treated in a level I trauma center from January 2010 to December 2013. Charts and radiographs were reviewed to analyze the demographic data of patients, type of dislocation, associated injuries, timing, modality of treatment, and early and late outcomes.

RESULTS: The mean age of patients was 33.5 years old and 98.2% were males. The most common cause of injury was motor vehicle collisions (MVCs) (76.8%). The posterior dislocation of the hip was

the most common injury (85.7%). Associated injuries occurred in 82% of patients, hip fractures being the most frequent. The time span between injury and reduction of dislocation was ranging from 1 to 14.5 hours. less than 6 hours in 85% of patients, 6-12 hours in 10% and more than 12 hours in 5%. 98.2% of patients underwent closed reduction. 10.6% of patients developed osteoarthritic changes, 1.8% had sciatic nerve palsy, and there were no reported cases of avascular necrosis (AVN) of the hip.

CONCLUSIONS: This study demonstrated that the traumatic hip dislocation affected mostly young adult males, with MVC being the most common cause of injury. The posterior dislocation of the hip was the most frequent type with high prevalence of associated injuries. Closed reduction was performed and the timing of reduction was less than 12 hours in the vast majority of patients. At an average of 2 years follow-up, no cases of avascular necrosis of the hip were encountered, however, long-term follow-up are required to assess the late outcome of dislocation.

Key words: Hip; Traumatic; Dislocation; Avascular necrosis

© 2020 The Author(s). Published by ACT Publishing Group Ltd. All rights reserved.

Assad W, Alhammoud A, Younis MH, Al Dosari MAA, Alhaneedi GA. The Trend in the Management of Traumatic Hip Dislocation in Qatar: A Retrospective Observational Study. *International Journal of Orthopaedics* 2020; 7(6): 1402-1406 Available from: URL: <http://www.ghrnet.org/index.php/ijo/article/view/3010>

INTRODUCTION

Traumatic hip dislocation is one of the most severe injuries in orthopedics that can end up with grave sequelae. It is usually a result of high energy trauma, mostly associated with MVCs, and the situation is complicated more if it was associated with acetabular or femoral head fractures^[1,2]. These types of dislocation are considered an orthopedic emergency because of the soft tissue injury, damage to vascular supply to the femoral head and the associated high risk of femoral head avascular necrosis (AVN)^[3-6].

It most commonly involves unrestrained passenger or pedestrian in MVC, falls from heights and sport-related injuries. Characteristically it causes greater soft tissue injury and disruption of blood supply of

femoral head that leaves the femoral head more susceptible to AVN^[7-9].

The most common type of hip dislocation is posterior, and it's usually caused by dashboard injury resulting in a direct impact on the flexed hip in sitting position. Patients usually present with shortened, adducted and internally rotated injured limb^[10].

The major concern of orthopedic surgeons at presentation is to avoid early complications such as femoral head osteonecrosis and articular cartilage injury, however, late outcomes of hip dislocation are still worrisome, with a high incidence of hip osteoarthritis in up to 50% in some series^[11,12]. The timing of reduction was reported by some authors as a determinant factor of outcome. The longer the interval between the time of dislocation and the time to reduction, the worse the results^[13-14].

As the only level one trauma center at Qatar, Hamad Medical Corporation (HMC) serve a high quality of patient care and research production for a population of around two million with an average of 3000 musculoskeletal injuries per year^[15].

This study aims to assess the outcomes and the epidemiological profile of patients with traumatic hip dislocation treated at Hamad General Hospital in Qatar.

METHODS

A retrospective review of all patients with traumatic hip dislocation treated at Hamad General Hospital, between January 2010 and December 2013.

Inclusion criteria for the study were patients 18 years and older with traumatic dislocation of the hip. Patients were excluded if (1) age less than 18 years old; (2) dislocations of hip arthroplasty; (3) hip dislocation of atraumatic causes; (3) open fracture-dislocations of the hip joint.

Patient Data were collected including general demographic characteristics (age, sex, weight), comorbidities (smoking, diabetic Mellitus, alcohol consumption, medication/steroid), the mechanism of injury (MVCs, falls from heights, fall of heavy objects, pedestrians hit by car), injury characteristics (Direction of the hip dislocation, laterality, femoral head fractures, acetabulum fractures, other injuries) management related parameters (closed/open reduction, time to reduction, post reduction traction, weight bearing, hospital stay) and follow up-related parameters (follow up period, development of AVN of the femoral head, development of osteoarthritis or Heterotopic ossifications, sciatic nerve palsy and recurrent instability) (Table 1).

Hip dislocations were divided into anterior and posterior. Anterior dislocations were classified according to Epstein and Harvey^[16], whereas posterior ones according to Thompson and Epstein^[17].

A standard treatment protocol was used in all cases, starting with ATLS protocol for all trauma cases, stabilization of the patient, and management of non-orthopedics injuries by the trauma team. Afterward, a trial of closed reduction of the dislocated hip joint is attempted in the trauma room in the emergency department (ED) under conscious sedation. In case of a failed reduction in the ED, open or closed reduction in operation room is pursued. Follow up was performed by post reduction CT scan, to ensure concentric congruent hip joint reduction, and assessing any femoral head or acetabular fracture, or intra-articular loose bodies. The stability of the hip joint reduction is evaluated, and skin traction is usually applied. Ambulation and weight bearing after the reduction depends on several factors according to patient's general condition, associated injuries, in addition to the surgeon's preference. Patients are followed up in the clinic with serial radiographs to detect re-dislocation, subluxation, develop-

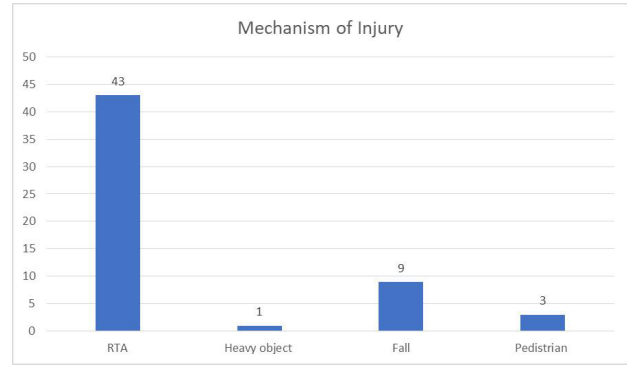


Figure 1 Mechanism of injury.

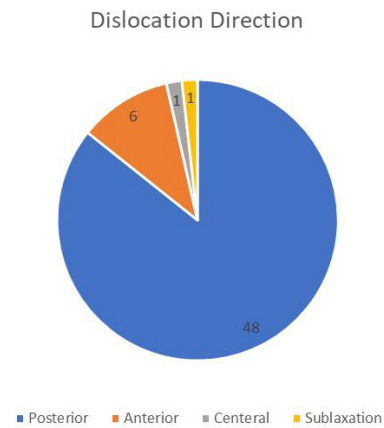


Figure 2 Direction of dislocation.

Table 1 Baseline patients' demographics.

Total Number of Patients	56
Age mean (range) (years)	33.5 (17-79)
Gender	
Male	55 (98.2%)
Female	1 (1.8%)
Weight mean (Kg)	75.4
Laterality	
Right	34 (60.7%)
Left	22 (39.3%)
Head Fractures	
Yes	10 (17.9%)
No	46 (82.1%)
Acetabulum Fracture	
Yes	25 (44.6%)
No	31 (55.4%)
Non-Orthopedics Injuries	
Yes	6 (10.7%)
No	50 (89.3%)
Hospital Stay mean (range) (days)	17.5
Follow up mean (range) (months)	24 (12-38)

ment of AVN of the femoral head, and osteoarthritic changes.

Statistical analysis

SPSS 22.0 (SPSS Inc. Chicago, IL) and Epi Info TM 2000 (Centers for Disease Control and Prevention, Atlanta, GA) was used for statistical analysis as percentage, mean and range were used for the categorical and continuous data.

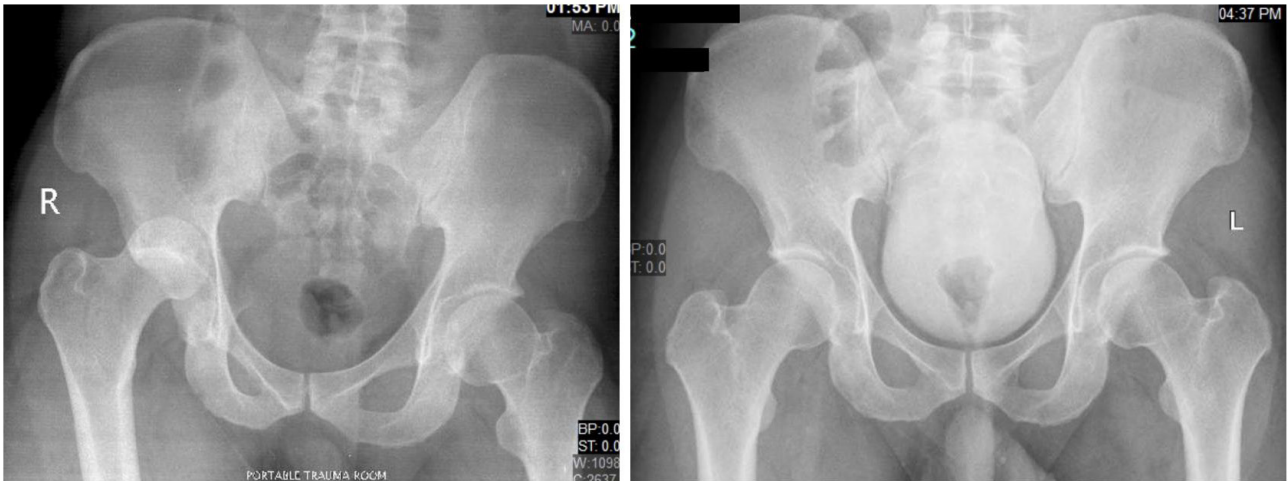


Figure 3 Isolated hip dislocation (Pre-reduction and post reduction).

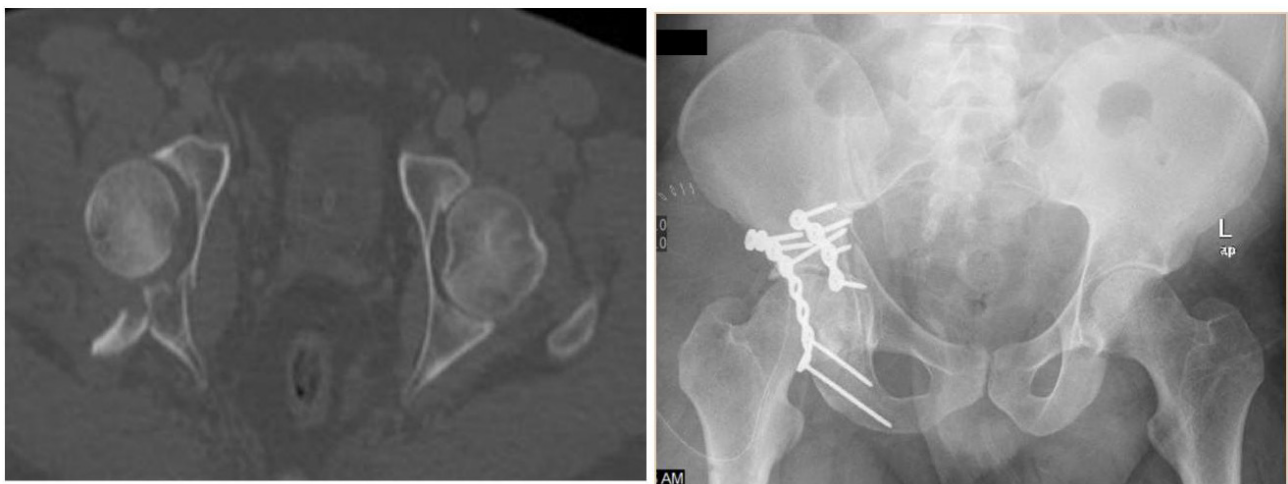
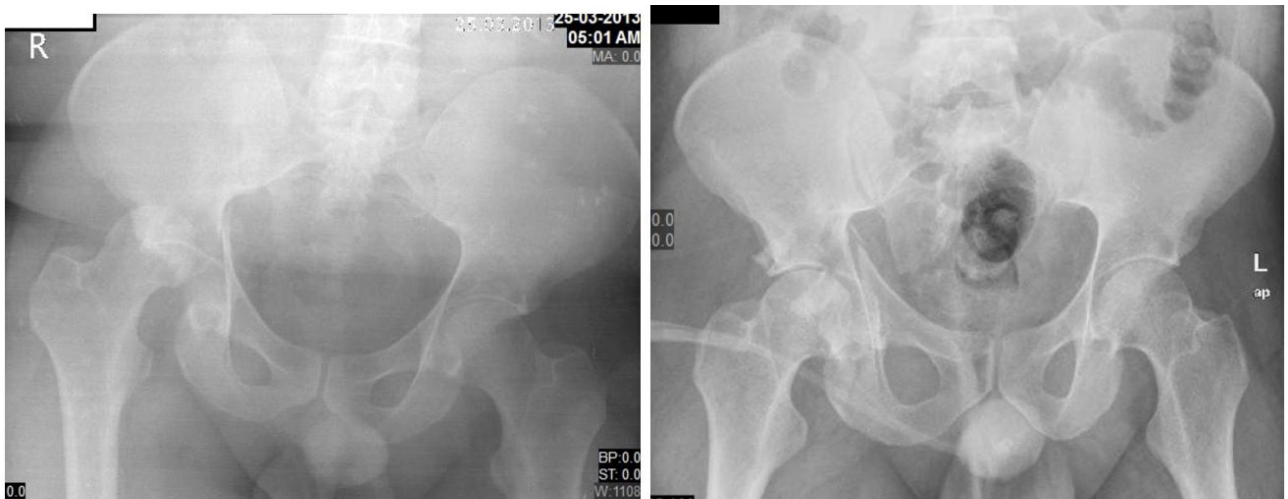

Figure 4 Hip dislocation with acetabular fracture (Pre-reduction, post reduction and post acetabular fixation).

RESULTS

Incidence: Fifty-six patients with traumatic hip dislocations managed in the orthopedics department at Hamad General Hospital over four years (From January 2010 to December 2013)

Demographics: The average age of patients sustaining a traumatic hip dislocation between was 33.5 years (17-79 years). (98.2%) were males and (1.8%) females. Average weight was 75.4 Kgs. (28.5%)

were smokers, (28.5%) used alcohol and only (1.8%) were on steroids. Table 1 demonstrated patient demographics.

Mechanism of injury: The most common cause of injury was MVCs in 43 cases (76.8%) followed by falls from heights in 9 patients (16.1%), 3 of them were pedestrians struck by vehicles (5.4%), and fall of heavy objects in one case (1.8%) (Figure 1).

Types of dislocation: There were 48 (85.7%) posterior dislocation,

6 (10.7%) anterior dislocation, one (1.8%) central dislocation and one (1.8%) subluxation (Figure 2).

According to Thompson and Epstein classification there were (46.4%) type I, (12.5%) type II and type III, (10.7%) TYPE IV and (12.5%) type V. All femoral head fractures were type I according to Pipkins classification.

Other associated injuries: Over the 4-year period, associated orthopedics injuries occurred in (71.4%); acetabulum fractures in 25 (44.6%), a femoral head fracture in 10 (17.9%) and 17 (30.4%) with other injuries like femoral shaft fractures and patella fractures. Other non-orthopedics injuries (e.g. maxillofacial fractures, chest and abdominal injuries) occurred in (10.7%) of patients.

Treatment options: Fifty-five patients (98.2%) underwent closed reduction whereas one case (1.8%) underwent open reduction. The average time between the injury and reduction was 3.8 hours (1-14.5). Fifty-five patients (98.2%) had post reduction skin traction for an average of 10.7 days, and the average hospital stay was 17.5. Nine cases required open reduction and internal fixation (ORIF) of the acetabulum, two required removal of intraarticular loose bodies, and three cases required ORIF of the femoral head.

Other outcomes: The average follow-up time was 24 months ranging from 12 month in isolated uncomplicated hip dislocation to 48 months, 14 patients (25%) lost follow up after discharge from hospital, 25 (44.6%) follow up for less than 24 months and 17 (30.4%) follow up for more than 24 months and up to 48 months. During the follow-up and in serial radiographs, no AVN was detected in any case even for the case which followed up till 48 months, whereas only one case develops dysplastic changes in acetabulum with heterotopic ossification. One case (1.8%) had sciatic nerve palsy, and there were no cases of recurrent instability. There were 6 cases (10.6%) who developed osteoarthritic changes and the only factor that was statistically significant is the direction of the dislocation $P=0.030$.

Figure 3 demonstrates a case of isolated hip dislocation pre-and post-reduction, whereas Figure 4 is an example of hip dislocation with acetabular fracture pre-reduction, post-reduction, and post-fixation.

DISCUSSION

Traumatic hip dislocations are considered orthopedic emergencies that are traditionally treated with reduction and touch weight bearing ambulation. Epidemiological studies have shown that traumatic hip dislocation occurred at a rate of 5.2% of all traumatic joint dislocation and the most common type is posterior dislocation in about 90%^[18].

We evaluated 56 patients over a period of four years, following them up for an average of two year. Our study demonstrated that traumatic hip dislocation is quite common in young patients, with the mean age of affected patients was 33.5 years old, affecting mainly males (98.2%). The most common type was posterior dislocation in 85.7%, while 10.7% were anterior dislocation, and only one patient had central hip dislocation (1.8%). Femoral head fractures occurred in 11 of the dislocations, and 27 of them sustained acetabular fractures as well. Similar findings were reported by Onyemaechi *et al.* and Lima *et al.*^[19,20]. In our series, MVC was the mechanism of injury responsible for 76.8% of dislocations, which is consistent with the literature^[10,14,19].

The prevalence of AVN following reduction of dislocation is approximately 1- 50% in traumatic hip dislocation^[13,14]. Femoral head AVN cause significant morbidity and place a cost burden on total

health care expenditures.

The prognosis of hip dislocation depends on several factors, including the timing of reduction. The initial reduction of hip dislocation is usually performed within six hours from the time of injury to reduce the risk of AVN. There is controversy in the literature regarding the appropriate timing to reduction. Among our patients, the time between the injury and dislocation reduction was less than six hours in 85% of patients. Although hip dislocation is an orthopedic emergency, few patients in our study underwent reduction after 6 hours from trauma. This delay in the treatment was caused by delay in transfer of patients, or due to associated injuries that take more priority in trauma emergency care. In our cases only 3 cases were reduced after 12 hours, two of them were due to delay in presentation, and in one case, a trial of closed reduction failed and the patient underwent open reduction which was carried 14.5 hours after the injury.

In this study, no AVN was detected even for the case which was followed up till 48 months. This might be attributed to the early reduction of dislocation within six hours in the majority of cases.

Several authors have shown a positive correlation between duration of dislocation and rate of AVN^[3,12,13]. Hougaard and Thomsen in 1986 have found avascular necrosis occurred most frequently (58.8%) in hips that underwent reduction after a delay of more than six hours versus 4.8% AVN rate in patients who were reduced in less than 6 hours from injury^[13].

Dreinhöfer and his colleagues in 1994 reported that isolated hip dislocation reduced within six hours gives an excellent outcome^[12]. Sahin *et al.* demonstrated better prognosis in hip dislocations and fracture-dislocations reduced within 12 hours^[3].

Several studies have reported that the timing of reduction of hip dislocation may not play such a critical role in the prevention of AVN^[2,6,7].

Dwyer *et al.* reviewed 35 cases of hip dislocation and concluded that “the single most important factor in predicting the AVN was the type and mechanism of dislocation. In this study, patients who were sustained the injury due to high energy trauma and more severe type (III & IV) had an AVN rate of 47% compared to 7.5% in those whom mechanism of injury due to low energy trauma and less severe type (I & II) even when reduction was achieved in less than 12 hours and may reflect the severity of initial injury^[7]. On the other hand, Marchetti *et al.* found no statistically significant difference in outcomes in posterior fracture-dislocations when reduced greater or less than 6 hours from time of injury^[21].

In our study, 98.2% of our patients underwent closed reduction which is the gold standard in the treatment of hip dislocation, unless there is an otherwise indication to perform an open reduction. Open reduction is indicated in cases when the hip is irreducible, delayed presentation, there is an obstacle to closed reduction (such as an intra-articular incarcerated bony fragment, or soft tissue interposition), or a proximal femoral fracture and other associated injury making it inappropriate to manipulate the lower limb to perform the reduction.

Our study has several limitations. It is a retrospective study with purposeful patient selection; therefore, it is susceptible selection bias. However, we tried to overcome this bias by enrolling all patients that met the inclusion criteria. Secondly, the lack of comparative design and long-term follow up has limited our conclusions and the ability to detect long-term complications such as AVN and osteoarthritis.

All authors have no conflict of interest.

CONCLUSION

Traumatic hip dislocation affected mostly young adult males,

with MVC being the most common cause of injury. The posterior dislocation of the hip was the most frequent type with high prevalence of associated injuries. Closed reduction was performed and the timing of reduction was less than 12 hours in the vast majority of patients. At an average of 2 years follow-up, no cases of avascular necrosis of the hip were detected, however, long-term follow-up studies are required to accurately detect potential complications of traumatic hip dislocation.

It is pertinent to improve the initial and definitive care of this kind of injury by implementing proper protocols aiming to reduce the time between the accident and reduction of dislocations to achieve reasonable prognosis.

Availability of data and materials

The datasets used and/or analyzed during the current study are available from the corresponding author on reasonable request.

Abbreviations

ATLS: Advance Trauma Life Support
AVN: Avascular Necrosis
ED: Emergency Department
MVC: Motor Vehicle Collision

ACKNOWLEDGEMENTS

The institutional medical research center for their support in this study.

Funding: The authors report no external funding source for this study.

Ethics declarations

Ethics approval and consent to participate: The study was approved by the institutional review board at Hamad Medical Research Centre. The consent was waved by IRB.

Consent for publication: Not applicable.

Competing interests: The authors declare that they have no competing interests.

Authors' contributions: WA, AA, MY drafted the initial manuscript, worked on the data acquisition, interpreted the data and edited the manuscript. MA assisted with data interpretation and reviewed and revised the manuscript. GA developed the project, analyzed and interpreted the data, supervised all of the work, wrote and edited the manuscript. All authors read and approved the submitted version of the manuscript to be published.

REFERENCES

- Giza E, Mithofer K, Matthews H, Vrahas M. Hip fracture-dislocation in football: a report of two cases and review of the literature. *Br J Sports Med.* 2004; **38**(4): e17. [PMID: 15273210]; [DOI: 10.1136/bjism.2003.005736]
- Sah AP, Marsh E. Traumatic simultaneous asymmetric hip dislocations and motor vehicle accidents. *Orthopedics.* 2008; **31**(6): 613. [PMID: 19292332]
- Sahin V, Karakaş ES, Aksu S, Atlıhan D, Turk CY, Halici M. Traumatic dislocation and fracture-dislocation of the hip: a long-term follow-up study. *J Trauma.* 2003; **54**(3): 520-9. [PMID: 12634533]; [DOI: 10.1097/01.TA.0000020394.32496.52]
- Epstein HC Traumatic dislocations of the hip. *Clin Orthop Relat Res.* 1973; **(92)**: 116-42. [PMID: 4710828]; [DOI: 10.1097/00003086-197305000-00011]
- Rodríguez-Merchán EC, Goddard NJ. Traumatic dislocation of the hip. *Clin Orthop Relat Res.* 2000; **(377)**: 2-3. [PMID: 10943177]
- Hougaard K, Thomsen PB (1987) Coxarthrosis following traumatic posterior dislocation of the hip. *J Bone Joint Surg Am.* 1987; **69**(5): 679-83. [PMID: 3597467]
- Dwyer AJ, John B, Singh S, and Mam MK. Complications after posterior dislocation of the hip. *Int Orthop.* 2006; **30**(4): 224-227. [PMID: 16521016]; [DOI: 10.1007/s00264-005-0056-9]
- Thompson VP, Epstein HC. Traumatic dislocation of the hip; a survey of 204 cases covering a period of twenty-one years. *J Bone Joint Surg Am.* 1951; **33-A** (3): 746-78. [PMID: 14850515]
- Pipkin G. Treatment of grade IV fracture-dislocation of the hip. *J Bone Joint Surg Am.* 1957; **39-A** (5): 1027-42. [PMID: 13475403]
- Deakin DE, Porter K (2009) Traumatic hip dislocation in adults. *Trauma.* 2009; **11**(3): 189-97. [DOI: 10.1177/1460408609340829]
- Yang RS, Tsuang YH, Yang YS, Liu TK. Traumatic dislocation of the hip. *Clin Orthop Relat Res.* 1991; **(265)**: 218-28. [PMID: 2009661]
- Dreinhofer KE, Schwarzkopf SR, Haas NP, Tscherne H. Isolated traumatic dislocation of the hip. Long-term results in 50 patients. *J Bone Joint Surg Br.* 1994; **76**(1): 6-12. [PMID: 8300683]
- Hougaard K, Thomsen PB. Traumatic posterior dislocation of the hip: prognostic factors influencing the incidence of avascular necrosis of the femoral head. *Arch Orthop Trauma Surg.* 1986; **106**(1): 32-5. [PMID: 3566493]; [DOI: 10.1007/BF00435649]
- R. W. Buchholz, J. D. Heckman, C. M. Court-Brown, and P. Tornetta III. Rockwood and Green's fractures in adults, Lippincott Williams & Wilkins, 6th edition, 2006.
- Al-Thani H, El-Menyar A, Consunji R, Mekkodathil A, Peralta R, Allen KA, Hyder A. Epidemiology of occupational injuries by nationality in Qatar: Evidence for focused occupational safety programmes. *Injury.* 46: p.1806-1813.
- Epstein HC, Harvey JP. Traumatic anterior dislocation of the hip: Management and results. *J Bone Joint Surg Am.* 1972; **54**: 1561-70. [DOI: 10.1590/1413-78522014220300883]
- Thompson VP, Epstein HC. Traumatic dislocation of the hip; a survey of two hundred and four cases covering a period of twenty-one years. *J Bone Joint Surg Am.* 1951; **33**(3): 746-78. [PMID: 14850515]
- Anjan P Kaushik, Anusuya Das and Quanjun Cui. Osteonecrosis of the femoral head: An update in the year 2012. *World J Orthop.* 2012 May 18; **3**(5): 49-57. [PMID: 22655222]; [DOI: 10.5312/wjo.v3.i5.49]
- Onyemaechi NO, Eyichukwu GO. Traumatic hip dislocation at a regional trauma center in Nigeria. *Niger J Med.* 2011; **20**(1): 124-30. [PMID: 21970274]
- Lima LC, do Nascimento RA, de Almeida VMT, Façanha FAM. Epidemiology of traumatic hip dislocation in patients treated in Ceará, Brazil. *Acta Ortopedica Brasileira.* 2014; **22**(3), 151-154. [PMID: 25061422]; [DOI: 10.1590/1413-78522014220300883]
- Marchetti, Steinberg, and Coumas. Intermediate-term experience of Pipkin fracture-dislocations of the hip. *J Orthop Trauma.* 1996; **10**(7): 455-61. [PMID: 8892144]; [DOI: 10.1097/00005131-199610000-00002]