

Distal Semitendinosus Rupture in a Rugby Union Player: an Algorithmic Approach to Assist Treatment Decision

Bikram Karmakar¹

1 Sports Medicine Institute, Department of Sports Medicine, Miranda, NSW, Australia.

Conflict-of-interest statement: The author(s) declare(s) that there is no conflict of interest regarding the publication of this paper.

Open-Access: This article is an open-access article which was selected by an in-house editor and fully peer-reviewed by external reviewers. It is distributed in accordance with the Creative Commons Attribution Non Commercial (CC BY-NC 4.0) license, which permits others to distribute, remix, adapt, build upon this work non-commercially, and license their derivative works on different terms, provided the original work is properly cited and the use is non-commercial. See: <http://creativecommons.org/licenses/by-nc/4.0/>

Correspondence to: Bikram Karmakar, Sports Medicine Institute, Miranda NSW, 2228, Australia.

Email: bikram.karmakar@outlook.com

Received: October 20, 2020

Revised: November 6, 2020

Accepted: November 10 2020

Published online: December 28, 2020

ABSTRACT

Literature regarding the management of distal semitendinosus rupture is limited. Though uncommon, distal semitendinosus rupture does occur, particularly in athletes. Clinicians are presented with a treatment dilemma in choosing between non-operative and operative methods without a consensus in the management approach. This is particularly challenging when managing patients who demand optimum function after recovery from injury. This was also the situation in the case that is reported in this paper. Using available literature, a treatment algorithm has been formulated in the form of a flowchart to simplify the decision-making process. The treatment flowchart guides the clinician in the initial treatment decision and specific patient measures that can determine treatment success. This approach was used successfully in the management of the case presented. The patient outcome focussed algorithm ensures that their functional goals are prioritised and any complications that occur in the treatment process can be addressed in a timely manner. The overall goal of whichever treatment process is chosen is for the

patient to return to an optimal level of function.

Key words: Athletic injuries; Hamstring; Rehabilitation

© 2020 The Author(s). Published by ACT Publishing Group Ltd. All rights reserved.

Karmakar B. Distal Semitendinosus Rupture in a Rugby Union Player: an Algorithmic Approach to Assist Treatment Decision. *International Journal of Orthopaedics* 2020; 7(6): 1413-1417 Available from: URL: <http://www.ghrnet.org/index.php/ijo/article/view/3017>

INTRODUCTION

Injuries to the hamstring muscle and tendon complex are common in athletes across many sports^[1-4]. Distal hamstring injuries most frequently involve the biceps femoris component of the muscle complex^[5,6]. This occurs within the muscle belly or musculotendinous junction more often than complete rupture or avulsion of the tendon. Distal semitendinosus injury likely accounts for a minority of overall distal hamstring injuries^[7]. The published literature on management of distal semitendinosus rupture is limited to case reports and case series. Treatment approaches and recommendations vary between studies. Interestingly, the published cases are often elite athletes in whom peak performance of lower limb function is critical. Time to return may be a critical factor in managing athletes. This may not be as critical in non-athletes if outcomes are similar between treatments. Semitendinosus graft is often used for anterior cruciate ligament reconstruction. Functional outcomes following this procedure can provide a patient with guidance of expectations following injury to the tendon. This paper aims to provide clarity on current evidence and provide the clinician an algorithmic approach to guide them when managing a patient with distal semitendinosus rupture.

CASE REPORT

A 21-year-old male semi-professional rugby union player presented 4 days following an injury in a match. During the game he broke free from a tackle but while reaching to stretch for the try line he felt a pop in the medial right knee region. He played on for another 5 minutes but was limited by pain and inability to push off and accelerate. Examination revealed tenderness in the pes anserine region. A sulcus was notable in the distal medial hamstring which was accentuated by

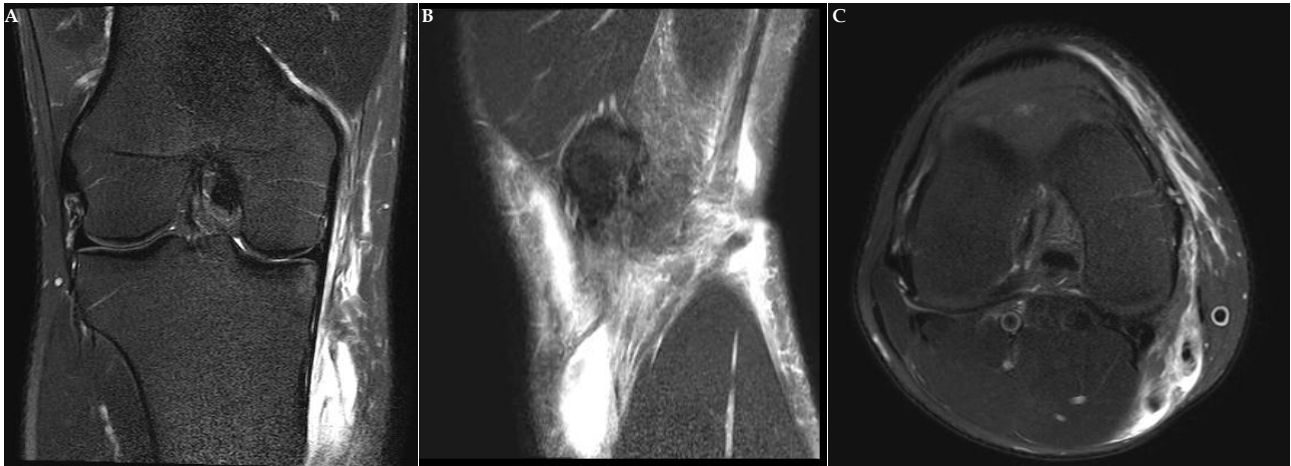

Figure 1A, 1B, 1C: Coronal, Sagittal and Axial views demonstrating discontinuity of the semitendinosus tendon and extensive oedema in the pes anserine region.

knee flexion. There was reduced tension in the palpable part of the semitendinosus. Knee flexion power was reduced compared to the contralateral side. MRI of the right knee confirmed complete rupture of the semitendinosus and gracilis components at the pes anserine but intact sartorius attachment. The semimembranosus was also intact (Figure 1A, 1B, 1C).

A patient centred algorithmic treatment approach ensued. Primary care was provided by the Sports medical practitioner with orthopaedic surgeon consultation. Rehabilitation was facilitated by a physiotherapist with regular guidance from the Sports medical practitioner. Both non-operative and operative options were discussed with the patient. In particular, the likely longer rehabilitation process of non-operative management was also discussed. From the available literature, a flowchart describing a treatment algorithm was formulated (Figure 2). This approach was used to assist both the patient and the clinician in formulating a collective decision at each step of the management regimen. The patient was agreeable to a longer rehabilitation process. The injury occurred with the season already underway. The patient reasoned that were likely to miss the remainder of the season with or without operative treatment. The patient was aware that should they require surgery for failure of non-operative treatment this would likely involve debridement rather than a primary repair of the tendon.

The patient underwent an extensive rehabilitation process with regular interval follow up. At 4 weeks they had achieved a range of motion of 0 to 130 degrees in the affected knee. They had progressed to 20kg goblet squats. By 2 months the patient was squatting 120 kg for 8 reps which was 20 kg less than their personal best. He commenced light running at 2 months and returned to early contact training at 3 months. The player returned to playing off the bench 4 months post injury for the last 3 games of the season for a cumulative total of 25 minutes. At 10 months following injury the patient had no pain and had returned to their normal squat and deadlift weight regime. They returned to playing a full 80-minute game at 11 months post injury without any clinical concerns.

DISCUSSION

Review of the literature revealed 2 case reports and 2 case series outlining patients with rupture of the distal semitendinosus. Cooper and Conway performed a retrospective case series spanning 14 years of distal semitendinosus ruptures in elite athletes. Patients either underwent acute non-operative treatment or surgical resection of the tendon. Patients were considered recovered when they had > 80%

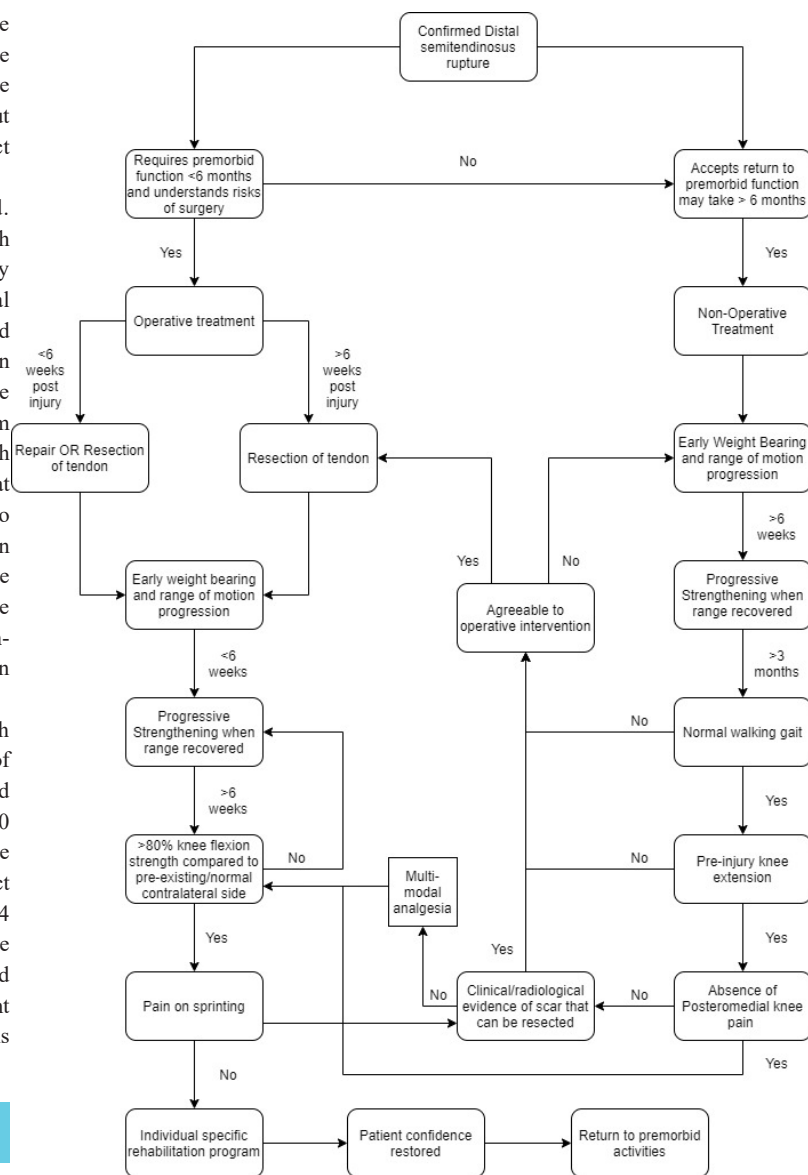


Figure 2 Treatment Flowchart used to guide management of distal semitendinosus rupture.

requirements of their usual activities or sport. This would be consistent with general rehabilitation guidelines for musculoskeletal injuries. Regular follow up through the process is encouraged

Table 1 Summary of findings in published case reports and case series on patients with distal semitendinosus rupture

Study	Patients	Level of evidence	Sport(s)	Management	Comment
Adejuwon et al[1].	2	Case report (IV)	Sprinting	Non-operative: Initial rest followed by focused rehabilitation	Both cases had MRI confirmed complete rupture of the Semitendinosus tendon. Season best time for 100m achieved at 10 months and 12 months
Cooper et al [6].	25	Case series (IV)	8 Baseball (MLB), 8 American football (NFL), 1 Hockey (NHL)	Non-operative: rehabilitation, Operative: Resection of tendon	Cases spanning 14 years. Diagnosis confirmed on MRI of complete semitendinosus rupture. 17 patients followed up. 5/12 players managed non-operatively later required surgery. Remaining 7 returned to play successfully. 5 players had surgery all returned to play. Symptoms persisted for 18 months in one surgical patient. Recovery time with acute surgery à 6.8 weeks Non-operative à 18.4 weeks
Kelly et al[11]	1	Case report (IV)	Australian rules football (AFL)	Operative: Repair with reattachment of semitendinosus direct to attachment	MRI confirmed Semitendinosus complete avulsion. Return to competition at 9 weeks post-operative with no symptoms. No long term sequelae of injury at 2 years
Schilders et al[18]	4	Case series (IV)	3 Soccer players, 1 Rugby player	Operative: tenotomy	All patients had original diagnosis of partial rupture of distal semitendinosus rupture confirmed on MRI. 1 player had previous undescribed surgery previously. All players had >4 months of conservative treatment but with persistent symptoms of pain and local tenderness. All players returned to usual sport although timing was unknown
Sekhon & Anderson [19]	2	Case Report (IV)	1 American Football (NFL), 1 Baseball (MLB)	Non-operative: early rehabilitation	Both cases were distal semitendinosus avulsion. One was confirmed on MRI the other on Ultrasound. 1st case returned to NFL level competition in 2 weeks and played the whole season without complication. 2nd player returned to major league baseball after 4 weeks with no further complication.

strength to the contralateral side, could sprint without pain, completed a sports specific rehabilitation and could play at a competitive level. The average recovery time for the acute surgery group was 6.8 weeks and for non-operative was 18.4 weeks. The total recovery time was measured from the date of injury and the length may not accurately represent their initial treatment choice. Furthermore, one player in the acute surgical group although considered to have recovered in 3 weeks still had symptoms for 18 months. There was no long-term difference in hamstring flexibility or function^[8].

Kelly et al reported on the case of a professional Australian rule football player. The player underwent an acute surgical repair of the distal semitendinosus tendon with a longitudinal incision overlying the pes anserine region. The surgical technique and the approach used had not been previously described in the literature for management of this condition. The patient returned to competition at 9 weeks post-operative with no complication. The authors determined that repair of the tendon was possible and associated with an expeditious return to play^[9]. Schilders reported the case of 4 athletes with partial semitendinosus rupture. 3 of the 4 patients had 4 months of conservative treatment while one patient had an undisclosed surgery previously. The patients reported ongoing pain or loss of explosive movement. They underwent a tenotomy procedure and reported no symptoms at 6 weeks follow up^[10].

Another study reported two cases of distal semitendinosus rupture in sprinters. The patients underwent a focused rehabilitation program. At 12 months one patient had achieved season best times in 100m and 200m and the other patient achieved a season best time at 10 months over a 100m. The authors thus advocated for non-operative treatment as full recovery could be achieved^[11]. Sekhon and Anderson also reported 2 cases of distal semitendinosus avulsion which were non-operatively managed. One patient had an ultrasound demonstrating 4cm retraction of the distal semitendinosus tendon but did not have an MRI. With aggressive rehabilitation the player returned to major league level competition in 4 weeks. The other was also treated non-operatively. The player returned to the NFL competition after 2 weeks but required local anaesthetic injection for the first games after return^[12]. The findings of the studies are summarised in Table 1.

Patient outcome in published case reports and series of distal

semitendinosus rupture are largely based upon observational functional measures rather than imaging findings. Outcomes based upon hamstring graft for anterior cruciate ligament reconstruction can assist in understanding regeneration potential of the distal semitendinosus. In a systematic review evaluating hamstring tendon regeneration after harvesting the pooled regeneration rate for the semitendinosus tendon was 91% inside one year and 79% when including results over a year post harvesting. In the same review, no statistical correlation was seen to indicate determinants for tendon regeneration including patient sex or duration of immobilisation^[13]. Eriksson et al. demonstrated regeneration of the semitendinosus tendon in 75% of cases at median 7 months with no evidence of muscle belly retraction^[14]. Nakamae et al used 3D CT reconstruction which demonstrated that at 12 months there was regeneration of some capacity in all patient's semitendinosus tendon. There was on average 7.3+/-2.0 cm proximal retraction of the muscle-tendon junction but not affect the peak torque ration at 12 months^[15]. Based on patients with a semitendinosus tendon harvesting, patients can take reassurance knowing there is capacity for the semitendinosus tendon to regenerate in most cases.

An algorithmic approach assists the clinician in making treatment decisions for conditions in which best practice has not been conclusively determined. Applying learning points from previous studies can be used to formulate a treatment flowchart (Figure 1). This can be by clinicians as a guide to managing distal semitendinosus rupture cases. Both non-operative and operative measures provided good long-term outcomes with consistent return to sport. Although it is possible to return to competition prior to 6 months with non-operative treatment, the early recovery with surgery appears more predictable. For this reason, it is used as an initial differentiator in the flowchart so that the patient is aware of a potentially long rehabilitation process. If the patient still experiences issues following initial treatment their options include debridement (either primary debridement or secondary debridement of any scar tissue) or analgesia or both. There is no information provided on the specific rehabilitation protocols in the published cases. For this reason, the flowchart mentions an individual specific rehabilitation process that would incorporate parameters specific to individual

Karmakar B. Approach to distal semitendinosus rupture

so that the management can be appropriately altered should any complication arise. Providing the clinician with specific measures that have been used in the cases discussed to assess non-operatively managed patients provides consistency in managing patients with the same injury. Most significantly it ensures recognition of issues that can be addressed with delayed surgical treatment as evidenced in previous case studies.

There are several limitations in making recommendations based on case reports and case series. The total number of cases published are low. Individual differences both at an individual level as well as in the rehabilitation process cannot be accounted for. Notably the studies all documented elite level athletes where rehabilitation goals are more likely to be enforced. Clinicians are forced to decide treatment approach based upon limited literature. It can be confusing to determine which case report suits their patient's situations best and then based their treatment decision with only limited evidence. The paper synthesises available literature relevant to the topic. It serves to provide guidance rather than strict recommendations in the management of distal semitendinosus rupture.

The flowchart provides outcome measures that can be used to assess the effectiveness of the treatment choice and guide the clinician through the rehabilitation process. Patients in previous cases have demonstrated improved function following a tendon resection after initial non-operative treatment^[8]. This suggests the limiting factor to performance is likely to be pain or scar tissue formation. This is evidenced in the flowchart where analgesia might be considered first if there is no definitive scar identifiable. Furthermore, factors such as sprinting and those specific to an individual's usual activity or sport are regularly part of most sports injury rehabilitation protocols and used to determine timing of return to activity. They are only broadly mentioned in the case reports on this topic and have been included in the algorithm without providing specific details of the outcome measures.

In this paper operative treatment is broadly described as repair or resection. There are other considerations that need to be made when deciding on operative treatment. Differences exist in not only the operative technique but also approach across the cases published. Schilders et al described a posterior approach for their tenotomy^[10]. Cooper and Conway described a posteromedial approach over the semitendinosus tendon for resection^[8]. Kelly was the only study that described a primary repair, and this occurred with an anteromedial approach overlying the pes anserine region^[9]. The surgical approach is surgeon dependent and may also be determined by the anatomical location of the proximal tendon. All approaches have the potential to endanger neurological structures^[16]. The approach used to harvest the semitendinosus tendon for anterior cruciate ligament reconstruction has also been demonstrated to impact functional recovery. Patients who had a posterior approach to the semitendinosus tendon exhibited less strength deficit in quadriceps isokinetic testing at 3 months but no significant difference in hamstring function. The strength outcomes were the same at 6 months for both quadriceps and hamstring. The author's hypothesised that this was due to preservation of the sartorius and less subsequent inhibition of quadriceps function^[17]. Both posterior and anterior approach have been used for resection of semitendinosus resection in the cases highlighted. The approach used may worth considering in situations where earlier functional return is desired and operative intervention is chosen for semitendinosus rupture.

Autologous semitendinosus graft is regularly harvested for anterior cruciate ligament reconstruction. Imaging studies have demonstrated regrowth of the semitendinosus tendon following grafting in most

cases^[18,19]. Ultrasound using continuous shear wave elastography technique has demonstrated regrowth of the semitendinosus tendon post graft harvest, but reduction may occur in shear and viscosity moduli. Both these mechanical properties improve over time with 80.6% recovery in shear modulus and 78.7% recovery of viscosity modulus by 24 months and 39.9% and 46% by 12 months respectively when compared to the contralateral side^[19]. The regrowth potential and functional recovery over this time period are important to note having chosen either resection or non-operative treatment for semitendinosus rupture. The delayed time period may occur as the initial recovered tendon is composed mainly of type III collagen which is disorganised and has decreased mechanical strength. With progressive rehabilitation the tendon is remodelled to contain more type I collagen as is normally most prevalent in tendon structures^[20]. This would indicate that there is still potential for functional recovery beyond 12 months in semitendinosus rupture treated non-operatively or with resection. This is particularly relevant in non-athletes who should continue to partake in active rehabilitation until they achieve their functional goals. The suggested algorithmic approach provided in this paper is restricted to management of distal semitendinosus injury.

Distal semimembranosus and distal biceps femoris rupture has also been reported but anatomical differences may confer alternative management. The long tendinous component of the semitendinosus tendon can be separated more easily from scar tissue using a tendon stripper thus making resection a more viable option^[21]. This contrasts with the large distal component of the semimembranosus with multiple tendinous components making resection more difficult and more likely to be incomplete^[22]. Furthermore, distal hamstring injury may also be part of a wider injury involving other distal hamstring components as well as ligamentous, capsular or bone structures in the region^[23-25]. All these factors may subsequently alter the required management or rehabilitation protocol.

CONCLUSION

The evidence for the management of distal semitendinosus rupture is limited to case reports and case series. Evidently despite recommendations provided by the authors of these studies there exists no consensus on best practice. Both non-operative and operative options have proved successful in the cases published. Given so it is best to follow a methodical approach that is patient centred throughout the treatment process. An algorithmic approach provides a simplified guide to the decision-making process. The main difference in outcome between treatments is the more predictable time to recovery with operative treatment. With an effective rehabilitation process non-operative treatment provides patients with a long-term outcome comparable to operative treatment that also allows the patient to return successfully to high demanding sports. If a patient is evaluated methodically and in a timely manner, then surgical intervention can still occur if outcome is not as desired with initial non-operative treatment.

REFERENCE

1. Eirale C, Farooq A, Smikey FA, Tol JL, Chalabi H. Epidemiology of football injuries in Asia: A prospective study in Qatar. *Journal of Science and Medicine in Sport*. 2013; **16**(2): 113-117. [PMID: 22858346]; [DOI: 10.1016/j.jsams.2012.07.001]
2. Liu H, Garrett WE, Moorman CT, Y. Injury rate, mechanism, and risk factors of hamstring strain injuries in sports: A review of the literature. *Journal of Sport and Health Science*. 2012; **1**: 92-101.

- [DOI: 10.1016/j.jshs.2012.07.003]
3. Verall G, Slavotinek J, Barnes P, Fon G, Spriggins A. Clinical risk factors for hamstring muscle strain injury: a prospective study with correlation of injury by magnetic resonance imaging. *British Journal of Sports Medicine*. 2001; **35**(6): 435-439. [PMID: 11726483]; [DOI: 10.1136/bjism.35.6.435]
 4. Orchard JW, Seward H, Orchard JJ. Results of 2 decades of injury surveillance and public release of data in the Australian Football League. *American Journal of Sports Medicine*. 2013; **41**(4): 734-741. [PMID: 23460329]; [DOI: 10.1177/0363546513476270]
 5. Koulouris G, Connell D. Evaluation of the hamstring muscle complex following acute injury. *Skeletal Radiology*. 2003; **32**(10): 582-589. [PMID: 12942206]; [DOI: 10.1007/s00256-003-0674-5]
 6. De Smet AA, Best TM. MR Imaging of the Distribution and Location of Acute Hamstring Injuries in Athletes. *American Journal of Roentgenology*. 2000; **174**(2): 393-399. [PMID: 10658712]; [DOI: 10.2214/ajr.174.2.1740393]
 7. Lempainen L, Sarimo J, Mattila K, Heikkila J, Orava S. Distal tears of the hamstring muscles: review of the literature and our results of surgical treatment. *British Journal of Sports Medicine*. 2007; **41**(2): 80-83. [PMID: 17138628]; [DOI: 10.1136/bjism.2006.031211]
 8. Cooper DE, Conway JE. Distal Semitendinosus Ruptures in Elite-Level Athletes Low Success Rates of Nonoperative Treatment. *The American Journal of Sports Medicine*. 2010; **38**(6): 1174-1178. [PMID: 20351198]; [DOI: 10.1177/0363546509361016]
 9. Kelly T, Gultekin S, Cross T. Distal Avulsion of the Semitendinosus Tendon A Case Report. *The Orthopaedic Journal of Sports Medicine*. 2019; **7**(9): 1-5. [DOI: 10.1177/2325967119873843]
 10. Schilders E, Bismil Q, Sidhom S, Robinson P, Barwick T, Talbot C. Partial rupture of the distal semitendinosus tendon treated by tenotomy—a previously undescribed entity. *Knee*. 2006. **13**(1): 45-47. [PMID: 16125940]; [DOI: 10.1016/j.knee.2005.05.004]
 11. Adejuwon A, McCourt P, Hamilton B, Haddad F. Distal Semitendinosus Tendon Rupture: Is There Any Benefit of Surgical Intervention? *Clinical Journal of Sports Medicine*. 2009; **19**(6): 502-504. [PMID: 19898080]; [DOI: 10.1097/JSM.0b013e3181bd09c7]
 12. Sekhon J, Anderson K. Rupture of the Distal Semitendinosus Tendon - A Report of Two Cases in Professional Athletes. *The Journal of Knee Surgery*. 2010; **20**(2): 147-150. [PMID: 17486907]; [DOI: 10.1055/s-0030-1248034]
 13. Suijkerbuijk, MAM, Reijman M, Lodewijks SJM, Punt J, Meuffels DE. Hamstring Tendon Regeneration After Harvesting: A Systematic Review. *The American Journal of Sports Medicine*. 2014; **43**(10): 2591-2598. [PMID: 17486907]; [DOI: 10.1055/s-0030-1248034]
 14. Eriksson K, Hamberg P, Jansson E, Larsson H, Shalabi A, Wredmark T. Semitendinosus Muscle in Anterior Cruciate Ligament Surgery: Morphology and Function. *The Journal of Arthroscopic & Related Surgery*. 2001; **17**(8): 808-17. [PMID: 11600977]; [DOI: 10.1016/s0749-8063(01)90003-9]
 15. Nakamae A, Deie M, Yasumoto M, Adachi N, Kobayashi K, Yasunaga Y, Ochi M. Three-Dimensional Computed Tomography Imaging Evidence of Regeneration of the Semitendinosus Tendon Harvested for Anterior Cruciate Ligament Reconstruction A Comparison With Hamstring Muscle Strength. *Journal of Computer Assisted Tomography*. 2005; **29**(2): 241-5. [PMID: 15772546]; [DOI: 10.1097/01.rct.0000153779.86663.92]
 16. Stanton JES, Gupte C, Mahadevan V. Surgical approaches to the knee joint. *Orthopaedics and Trauma*. 2010; **24**(2): 92-99. [DOI: 10.1016/j.morth.2010.03.002]
 17. Dujardin D, Fontanin N, Geffrier A, Morel N, Mensa C, Ohl X. Muscle recovery after ACL reconstruction with 4-strand semitendinosus graft harvested through either a posterior or anterior incision: A preliminary study. *Orthopaedics & Traumatology: Surgery & Research*. 2015; **101**(5): 539-42. [PMID: 26047753]; [DOI: 10.1016/j.otsr.2015.03.017]
 18. Choi JY, Ha JK, Kim YW, Shim JC, Yang SJ, Kim JG. Relationships Among Tendon Regeneration on MRI, Flexor Strength, and Functional Performance After Anterior Cruciate Ligament Reconstruction With Hamstring Autograft. *American Journal of Sports Medicine*. 2012; **40**(1): 152-62. [PMID: 21993976]; [DOI: 10.1177/0363546511424134]
 19. Suydam SM, Cortes DH, Axe MJ, Snyder-Mackler L, Buchanan TS. Semitendinosus Tendon for ACL Reconstruction: Regrowth and Mechanical Property Recovery. *The Orthopaedic Journal of Sports Medicine*. 2017; **5**(6): 1-7. [PMID: 28680900]; [DOI: 10.1177/2325967117712944]
 20. Wang JH-C. Mechanobiology of tendon. *Journal of Biomechanics*. 2006; **39**(9): 1563-82. [PMID: 16000201]; [DOI: 10.1016/j.jbiomech.2005.05.011]
 21. Sonnery-Cottet B, Daggett M, Gardon R, Pupim B, Clechet J, Thauat M. Surgical Management of Recurrent Musculotendinous Hamstring Injury in Professional Athletes. *Orthopaedic Journal of Sports Medicine*. 2015; **3**(10): 1-7. [PMID: 26535376]; [DOI: 10.1177/2325967115606393]
 22. Blakeney WG, Thauat M, Ouanezar H, Constantino de Campos G, Castro de Padua VB, Sonnery-Cottet B. Distal Semimembranosus Tendon Avulsions Acute Surgical Repair in a Professional Rugby Player. *The Orthopaedic Journal of Sports Medicine*. 2017; **5**(10). [PMID: 29051904]; [DOI: 10.1177/2325967117731102]
 23. Aldebeyan S, Boily M, Martineau PA. Complete tear of the distal hamstring tendons in a professional football player: a case report and review of the literature. *Skeletal Radiology*. 2016; **45**(3): 427-430. [PMID: 26668066]; [DOI: 10.1007/s00256-015-2306-2]
 24. Alioto RJ, Browne JE, Barnhouse CD, Scott AR. Complete rupture of the distal semimembranosus complex in a professional athlete. *Clinical Orthopaedic Related Research*. 1997; **336**: 162-165. [PMID: 9060501]; [DOI: 10.1097/00003086-199703000-00023]
 25. Khoshnoodi P, Tehranzadeh AD, Dunn JM, Tehranzadeh J. Semimembranosus tendon avulsion fracture of the posteromedial tibial plateau associated with posterior cruciate ligament tear and capsular rupture. *Skeletal Radiology*. 2014; **43**(2): 239-242. [PMID: 24026070]; [DOI: 10.1007/s00256-013-1719-z]