

Pronator Teres Tear at the Myotendinous Junction in the Recreational Golfer: A Case Report

Alvarho J. Guzman¹, BA; Stewart A. Bryant¹, MD; Shane M. Rayos Del Sol¹, BS, MS; Brandon Gardner¹, MD, PhD; Moyukh O. Chakrabarti¹, MBBS; Patrick J. McGahan¹, MD; James L. Chen¹, MD

¹ Department of Orthopedic Surgery, Advanced Orthopedics & Sports Medicine, San Francisco, CA, the United States.

Conflict-of-interest statement: The author(s) declare(s) that there is no conflict of interest regarding the publication of this paper.

Open-Access: This article is an open-access article which was selected by an in-house editor and fully peer-reviewed by external reviewers. It is distributed in accordance with the Creative Commons Attribution Non Commercial (CC BY-NC 4.0) license, which permits others to distribute, remix, adapt, build upon this work non-commercially, and license their derivative works on different terms, provided the original work is properly cited and the use is non-commercial. See: <http://creativecommons.org/licenses/by-nc/4.0/>

Correspondence to: Alvarho J. Guzman, Department of Orthopedic Surgery, Advanced Orthopedics & Sports Medicine, San Francisco, CA, the United States.

Email: alvarho@aosportsmed.com
Telephone: +1-415-900-3000

Received: December 16, 2020

Revised: January 23, 2021

Accepted: January 26, 2021

Published online: April 28, 2021

ABSTRACT

Pronator teres muscle tear is a rare athletic injury that reportedly occurs in swinging sports such as golf and cricket. The main mechanism of injury appears to be caused by a forceful golf or racket swing striking the ground during resisted elbow flexion and supination. We report the case of a 50 year old right hand dominant male who presented with right elbow pain and volar sided ecchymosis of the right bicep, elbow, and forearm for two weeks following his injury while golfing. Initially after one episode of golfing, the patient reported experiencing right elbow pain with no ecchymosis. The following week while golfing, the patient developed pain over the anterior forearm and was forced to stop golfing. The next day he noted extensive ecchymosis of the right distal arm region that extended to the distal wrist. MRI confirmed an acute right pronator teres tear at the myotendinous junction. The patient

was expected to make a complete return to pre-injury level athletic activity with conservative management. With this article, we consider biceps rupture on the differential diagnoses associated with pronator teres musculotendinous injuries, emphasize the significance of club type in relation to golfing injuries, and propose a potential pronator teres rupture non-operative rehabilitation protocol.

Key words: Pronator teres; Golf; Biceps; Ecchymosis; Rehabilitation protocol

© 2021 The Author(s). Published by ACT Publishing Group Ltd. All rights reserved.

Guzman AJ, Bryant SA, Del Sol SMR, Gardner B, Chakrabarti MO, McGahan PJ, Chen JL. Pronator Teres Tear at the Myotendinous Junction in the Recreational Golfer: A Case Report. *International Journal of Orthopaedics* 2021; 8(2): 1457-1462 Available from: URL: <http://www.ghrnet.org/index.php/ijo/article/view/3055>

INTRODUCTION

The pronator teres (PT) is a fusiform muscle that belongs to the superficial group of muscles in the anterior compartment of the forearm. It consists of 2 heads that originate from the medial epicondyle of the distal humerus and coronoid process of the ulna, and it inserts along the lateral surface of the mid shaft of the radius just distal to the supinator. Pronation of the forearm at the proximal radioulnar joint and flexion of the forearm are the primary actions of the PT muscle. Pronator teres muscle tears (PTT) are rare athletic injuries reported to occur in swinging sports such as golf and cricket when a sudden eccentric force is applied to the elbow during resisted pronation and flexion^[18,11]. The injury reportedly occurs when a forceful swing of a club or racket makes contact with the ground, resulting in excess loading and contraction of the PT muscle past its threshold^[18,10,17].

Overuse injuries in golf can result in chronic, serious musculoskeletal problems^[13]. An epidemiological study of 703 golfers, professional and amateur, found that 82% of injuries stemmed from overuse and 17% from isolated trauma events^[13]. Professional golfers were more likely to be injured in the wrist, shoulder, and back, while amateur golfers reported elbow, back, and shoulder injuries more frequently^[13]. A study of golfers noted

that one out of six amateur golfers sustained an injury over a single year, 17% of the injuries affected the elbow and forearm, the second most commonly injured area behind the lower back^[15]. An electromyographic analysis revealed that compared to professional golfers, amateur golfers showed more muscle activity in the PT of the trailing arm (right arm in right-handed golfers) during the forward swing phase and a trend towards increased activity in the acceleration phase^[9]. This raises the concern for potential PTT in individuals with a less consistent form when swinging.

The PT provides dynamic stability by supporting the medial elbow during throwing, and can also be a cause for fatigue and stress based injury in the elite and recreational athlete^[19]. PT injuries have been associated with medial elbow tendinopathy, medial epicondylitis, and ulnar collateral ligament ruptures^[3,8]. To our knowledge, there are 5 case reports/reviews describing PTT: 3 case reports in golfing,^[18,10,12] one report in a cricket player,^[17] and another review briefly describing the injury in a rugby player^[6]. In this article, we report the case of a recreational golfer with a PTT at the distal myotendinous junction associated with elbow pain and significant volar sided ecchymosis of the distal arm that extended to the distal wrist. In this report, the literature on PTT injuries is reviewed, physical examination and imaging findings are discussed, and a rehabilitation protocol is proposed.

CASE REPORT

The authors obtained the patient's informed consent for print and electronic publication of the case report before submission. Institutional review board approval is not required for case reports at our institution.

A 50 year old right hand dominant male presented with right elbow pain and volar sided ecchymosis of the right elbow and forearm for two weeks after two episodes of golfing one week apart. The patient described using a new oversized 520cc driver for golfing at the time in comparison to his regular 450cc driver. After the first episode of golfing, the patient began to experience right elbow pain without ecchymosis. Before the next episode of golfing a week later, the patient reported taking 6-8 tablets of ibuprofen. During a driver swing that made contact with the ground, the patient reported intense throbbing elbow pain and was forced to stop golfing. The next day the patient noted progressive medial sided ecchymosis over the right distal arm region extending to the right distal wrist which increased over several days (Figures 1A-C). Upon initial consultation with the orthopedic surgeon, the patient reported tightness in the right forearm, pain in the lateral right elbow, and mild pain of the right bicep.

On physical examination, the patient exhibited tenderness along the right proximal forearm and both the medial and lateral condyles. Some swelling throughout the elbow and arm were noted. Exquisite tenderness of the medial condyle was appreciated during examination. He showed pain and difficulty with right elbow range of motion, specifically with supination and pronation. Full flexion and extension of the right elbow was noted, although he experienced pain with full extension. No crepitus, laxity, subluxations, masses, or joint effusion were appreciated. Good muscle tone was noted for both the right elbow and bicep. X-ray imaging of the right elbow was taken prior to the consultation indicating no evidence of fracture. Due to extensive volar sided ecchymosis from the right distal biceps extending down to the right distal forearm, an MRI without contrast of the right elbow and forearm were ordered to evaluate for a possible tendon, ligament, or muscle tear.

Upon follow up at two weeks, the ecchymosis had improved but

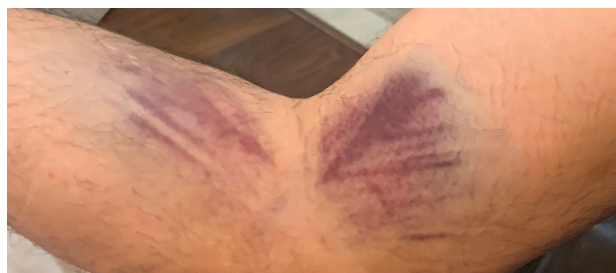

Figure 1A A few days after injury. Anterior sided ecchymosis along the proximal forearm over course of pronator teres muscle and the distal bicep is appreciated.

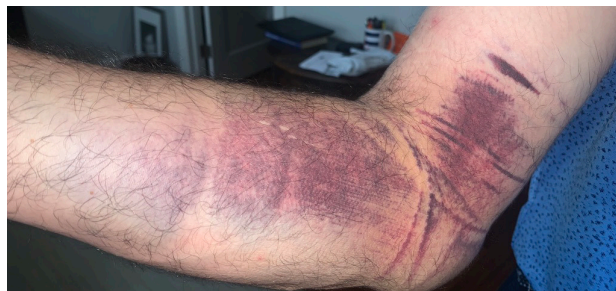

Figure 1B One week after the injury. Ecchymosis spreads further down the anterior forearm over the medial elbow.

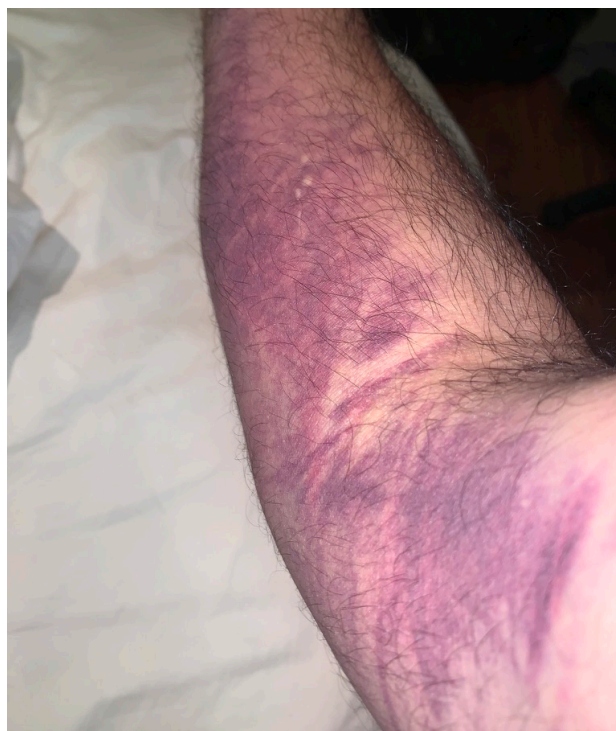

Figure 1C Nearly two weeks following the injury. This picture is taken prior to initial consultation with the orthopedic surgeon. Ecchymosis has clearly spread from the distal forearm over the distribution into the arm at mid bicep.

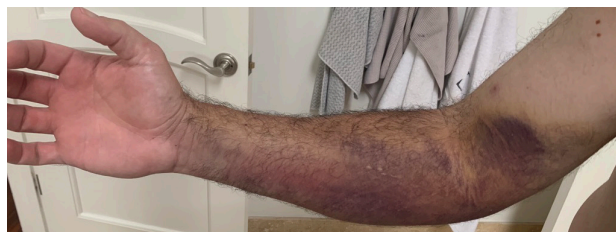

Figure 1D This picture is taken after initial consultation with the orthopedic surgeon, just over two weeks after injury. Ecchymosis is still prominent with increased discoloration.

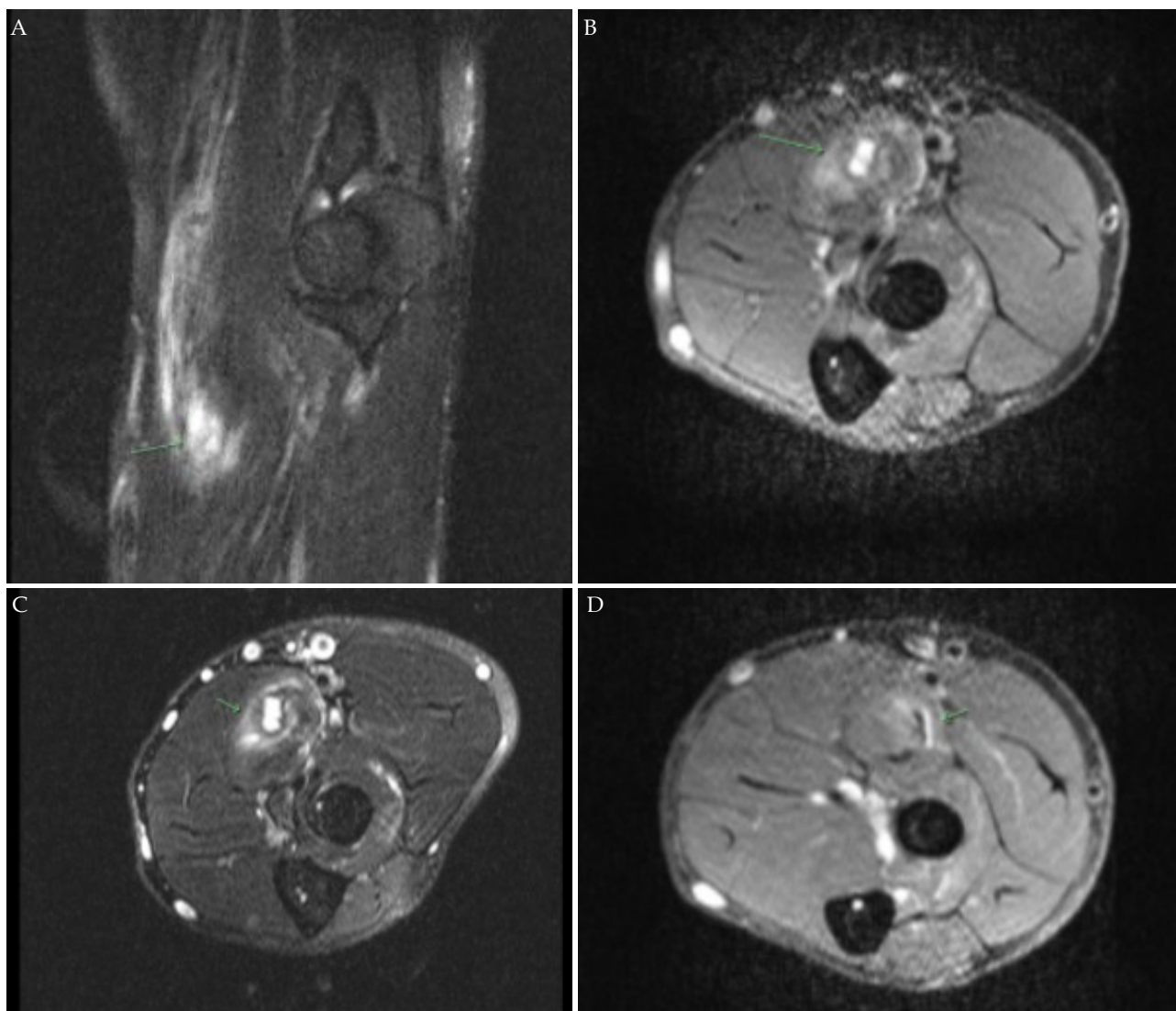


Figure 2A-2D: MRI imaging of pronator teres tear highlighted as increased intensity on sagittal and axial images.

the patient still experienced some pain with elbow ROM. The MRI of the right elbow and right forearm revealed an acute partial thickness tear of the distal myotendinous junction of the PT muscle (Figures 2A-2C). Following MRI review, the patient was instructed to rest the elbow from golfing activity and repetitive swinging motions for two months. The patient was advised to perform two months of physical therapy during this resting period in order to strengthen surrounding muscles of the forearm, bicep, and elbow and maintain ROM (Table 1). The patient was counseled he may experience residual pain of the elbow with pronation, although this should alleviate over time with physical therapy, rest, and activity modification. The patient was advised to avoid nonsteroidal anti-inflammatory drugs for the time being due to extensive ecchymosis. Surgical treatment was not recommended since conservative management produces good healing in partial thickness myotendinous tears^[18,10,17,12]. At 2 month follow up, the patient was doing well and reported success with swinging the golf club. He was given precautions and subsequently returned to golfing after practice.

DISCUSSION

PTTs are rare athletic injuries reported to occur in sports that require repetitive, dynamic swings such as golf and cricket^[18,11]. A

2013 study of the 2012 Olympics by Bethapudi *et al.* described 6 injuries of the PT during the games^[11]. A case report published by Qayyum *et al.* describes the mechanism of injury resulting from a forceful swing striking the ground during resisted pronation and supination of the elbow, resulting in sudden loading of the elbow and an overwhelming eccentric force on the PT muscle^[18]. However, other case reports have been published where PT injuries result from altering swing mechanics and indirect trauma through muscle fatigue^[10,17]. This report notes that elbow and biceps pathology are similarly associated with medial elbow pain commonly reported in PT muscular injuries^[11,3]. To our knowledge, no prior reports of published PTT have identified a biceps rupture for differential diagnosis, stressed golf club type as a considerable factor in injury mechanism, nor implemented a specific nonoperative rehabilitation protocol.

Differential diagnosis for medial elbow pathology known to occur in the throwing and swinging athlete include medial epicondylitis, medial elbow tendinopathy, ulnar collateral ligament rupture, posteromedial impingement, PT syndrome, and elbow fracture^[19,3,8,7]. With this case report, we include a biceps rupture to potential injuries associated with medial elbow pathology in throwing and swinging sports. Our patient experienced a PTT at the myotendinous junction, which represents a primary force transmission site particularly

Table 1 Non-Operative Rehabilitation Protocol for Isolated Pronator Teres Rupture.

Phase	Time	Exercises/Activities/Restrictions	Goals
Phase I: Rest	~ 0-1 weeks	(1) No loading (2) Complete rest (3) Avoid swinging, repetitive pronation (4) Rest, ice, compression, elevation (5) Partial weight bearing (6) Immobilization not necessary	(1) Increase ROM (2) Promote healing of pronator teres tear (3) Decrease pain and inflammation
Phase II: Passive/ Active ROM	~ 2-3 weeks	(1) Isometric wrist and elbow exercises (2) Eccentric lowering (<5 lbs) (3) Isotonic exercises: wrist curls, wrist extension, bicep/triceps, pronation/supination (4) Weight bearing as tolerated	(1) Progress to AROM; (2) Promote stability (3) Light isometric/sotonic strengthening (4) Promote healing of repairing tissue
Phase III: Strengthening	~ 3-6 weeks	(1) Weighted resisted pronation/ supination with dumbbells/resistance bands (>5 lbs) (2) Increase resistance of isotonic exercises from phase II (3) Gentle swings with golf club: emphasis on reducing hyper-pronation (4) Full weight bearing	(1) Increase endurance/ strengthening (2) Isotonic exercises of the wrist, bicep, tricep (3) Maintain full elbow ROM (4) Gradually initiate sport specific activities (5) Prepare athlete for return to swinging
Phase IV: Return to Sport	~ 6-8 weeks	(1) Initiate interval golf program (2) Continue exercises in phase III (3) Emphasize elbow, forearm, bicep, and wrist strengthening/flexibility exercises (4) Continue with strengthening program	(1) Progress endurance/ strengthening (2) Implement sport (3) specific movements (4) Pain free ROM (5) Full return to sporting function

susceptible to injury^[18,17,2]. Similar to previous reports, our patient reported golfing and striking the ground with his club which produces a sudden eccentric force upon the elbow^[18,10]. It is unclear whether the PTT occurred partially during the first golfing episode given their arm pain and was fully injured on their second golfing episode. Given the literature on prior case reports of PTT known to occur from differing mechanisms, it is reasonable to infer forceful contraction, sudden eccentric loading, and repetitive forearm pronation are considerable risk factors to this injury^[10,17].

Advanced imaging is imperative in proper diagnosis of PTT and allows for evaluation of differential diagnoses indicated from clinical presentation. Following activities that require substantial valgus stress and force, medial elbow pain and swelling can be mistaken for ulnar collateral ligament damage or medial epicondylitis^[18,3,8]. The clinical presentation of PTT can also resemble injuries of the elbow such as proximal ulnar fracture or common flexor tendon injury^[18,10,17]. Ultimately, MRI revealed a full-thickness tear of the PT at the myotendinous junction consistent with all reported cases of PTT induced by strenuous swinging motions^[18,10,17,12]. All previous reported cases described each patient exhibiting tenderness over the medial elbow over the flexor-pronator mass^[18,10,17,12]. Our patient case raises the concern for biceps rupture given the extensive ecchymosis and tenderness over a similar extending up the arm.

Tenderness along the right distal biceps tendon attachment in addition to the extensive ecchymosis over our patient's bicep were initially concerning for a biceps injury. In our patient, these clinical findings coupled with tenderness over the proximal forearm and distal bicep were concerning for a partial biceps rupture. Given the biceps brachii insertion is adjacent to the origin of the PT, and upon examination the patient showed discomfort with pronation and supination, a suspicion for a biceps injury was higher than a PTT due to identical location and reciprocal functions (Figure 3). Swelling and bruising of the distal arm extending from mid bicep to wrist may indicate distal humerus or elbow fractures^[10]. Normal radiographs reported no evidence of fracture, similar to prior case reports of PTT^[18,10,17]. However, in contrast to previous reports of PTT, our patient additionally experienced lateral elbow pain from golfing before exhibiting symptoms consistent with reported PTT. Lateral epicondylitis is common in athletes of all ages and skill levels, especially in sports such as tennis and golf^[11]. This patient possessed a history of lateral epicondylitis, potentially making his injury less

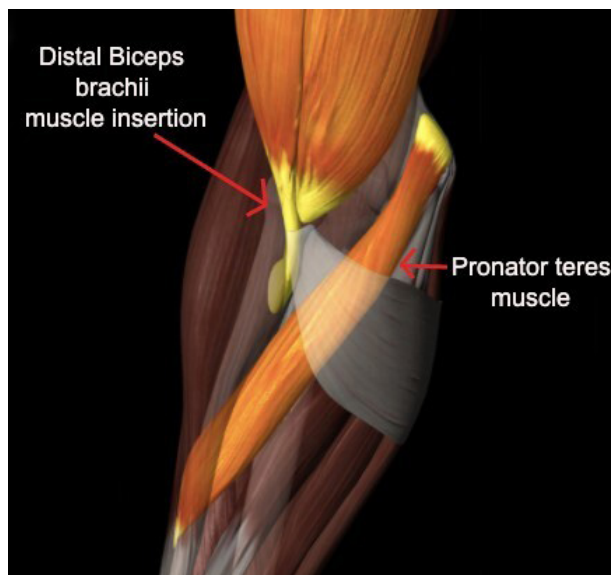


Figure 3 Diagram demonstrating the relationship between the Pronator Teres muscle and Distal Biceps brachii muscle insertion. The juxtosition of the two muscles can confound the diagnosis made using physical exam.

clear on presentation.

It is important to consider our patient's use of a new golf club when swinging. He reported using a different larger driver when his injury occurred. Given the inherent differences in size, weight, length, and grip with different golf clubs, the potential for alteration of swing biomechanics, club angle, and wrist control in the amateur golfer could predispose the PT to injury. Comparable to the patient in Ficke et al. that switched to a longer club while golfing, our patient utilized a different club type over the course of golfing that altered his swing biomechanics, forearm positioning, and grip mechanics^[10]. Ghisa et al. report a patient case where an acute full-thickness PTT of the right forearm was reported in the case of a left hand dominant male who golfed right-handed^[12]. This finding suggests hand use, not hand dominance, may be a more substantial risk factor in PTTs. The body of evidence suggests there may be a trend in increased risk of injury with changes in golf clubs.

In a study comparing the smoothness of swinging motions between golfers, it was found that the normalized jerk of the clubhead of skilled golfers was lower than that of unskilled golfers in every plane

and component of the downward swinging motion^[4]. Modification to forearm position can significantly affect both club head velocity and energy transfer efficiency with exceeding maximum swing torque^[16]. Ball positioning can also significantly alter hand positioning and arm angle relative to the body which further alters swing biomechanics^[14]. As reported in prior case studies, adjustments in golf swing can cause the over-pronation of the hand during contact and follow through, subjecting the golfer to substantial eccentric forces induced by muscular fatigue^[18,10]. A combination of forearm and ball positioning, swing biomechanics, and golf club type are all considerable risk factors in explaining the patient's PTT.

Similar to prior case reports, our patient experienced medial elbow ecchymosis over the course of the PT muscle that progressively developed with repetitive golfing^[18,10,17]. Ecchymosis of the anterior distal arm extending to the volar wrist then developed following the injury. Ficke *et al.* described similar findings of severe volar sided ecchymosis from mid-biceps to wrist due to strenuous golfing^[10]. They also described their patient's use of aspirin for heart disease and NSAIDs for the injury which were held briefly due to the ecchymosis. Their report and our similar findings raise the concern that the use of NSAIDs contributed to the development of ecchymosis. There is literature noting that tendon healing is compromised by the use of NSAIDs but this may not extend to all tendon tears^[5]. Although ecchymosis was initially present upon clinical examination, swelling and bruising were both completely alleviated following conservative measures of rest, ice, compression, and physical therapy^[18,10]. Four weeks following injury, ecchymosis throughout our patient's arm had disappeared.

Non-operative treatment is generally recommended for tears of the PT at the myotendinous junction. All reported case studies of PTT had good outcomes with conservative management consisting of rest, ice, activity modification, and physical therapy^[18,10,17,12]. It is vital to obtain advanced imaging such as MRI and sonography following clinical examination in order to differentiate between other elbow pathology^[6]. Our patient is expected to make a complete return to pre-injury level sporting function without deficit through a conservative pathway. We propose a non-operative rehabilitation protocol for an isolated PTT with the goal of restoring full function, strength, and ROM to pre-injury athletic ability (Table 1). Our protocol and expected timeline are based on all prior published case reports of PTTs in which every patient has made a complete return to activity with nonoperative treatment^[18,10,17,12].

CONCLUSION

PTTs are rare sporting injuries only reported to occur in swinging sports such as golf and cricket. Alteration of swing biomechanics, club type, and arm positioning may predispose the amateur golfer to sudden eccentric forces upon striking the ground, placing significant stress on the PT that may lead to injury. However, it is still unclear whether muscle fatigue, sudden loading, or forceful contraction are primarily responsible for this injury. Physical examination and advanced imaging are pivotal to identify isolated rupture of the PT and discern between differential diagnoses of the elbow, bicep, and forearm. To the available literature of isolated PTT, we add a biceps rupture to the list of possible differential diagnoses, highlight the relevance of club type to golfing injuries, and propose a practical, non-operative rehabilitation protocol for complete return to play.

REFERENCES

1. Bethapudi S, Budgett R, Engebretsen L, O'Connor P. Imaging at

- London 2012 summer Olympic Games: analysis of demand and distribution of workload. *Br J Sports Med.* 2013 Sep; **47(13)**: 850-6. [DOI: 10.1136/bjsports-2013-092345]. Epub 2013 Jul 23. [PMID: 23881896].
2. Charvet B, Ruggiero F, Le Guellec D. The development of the myotendinous junction. A review. *Muscles Ligaments Tendons J.* 2012 Sep 10; **2(2)**: 53-63. [PMID: 23738275]; [PMCID: PMC3666507].
3. Chen FS, Rokito AS, Jobe FW. Medial elbow problems in the overhead-throwing athlete. *J Am Acad Orthop Surg.* 2001 Mar-Apr; **9(2)**: 99-113. [DOI: 10.5435/00124635-200103000-00004]; [PMID: 11281634].
4. Choi A, Joo SB, Oh E, Mun JH. Kinematic evaluation of movement smoothness in golf: relationship between the normalized jerk cost of body joints and the clubhead. *Biomed Eng Online.* 2014 Feb 26; **13(1)**: 20. [DOI: 10.1186/1475-925X-13-20]; [PMID: 24571569]; [PMCID: PMC3941698].
5. Connizzo, Brianne K., Sarah M. Yannascoli, Jennica J. Tucker, Adam C. Caro, Corinne N. Riggan, Robert L. Mauck, Louis J. Soslowsky, David R. Steinberg, and Joseph Bernstein. The detrimental effects of systemic Ibuprofen delivery on tendon healing are time-dependent. *Clinical Orthopaedics and Related Research* 472, no. 8 (2014): 2433-2439.
6. Créteur V, Madani A, Sattari A, Bianchi S. Sonography of the Pronator Teres: Normal and Pathologic Appearances. *J Ultrasound Med.* 2017 Dec; **36(12)**: 2585-2597. [DOI: 10.1002/jum.14306]. Epub 2017 Jul 3. [PMID: 28670713].
7. Dididze M, Tafti D, Sherman AL. Pronator Teres Syndrome. 2020 Jul 8. In: StatPearls [Internet]. *Treasure Island (FL): StatPearls Publishing*; 2020 Jan-. [PMID: 30252346].
8. Donaldson O, Vannet N, Gosens T, Kulkarni R. Tendinopathies Around the Elbow Part 2: Medial Elbow, Distal Biceps and Triceps Tendinopathies. *Shoulder Elbow.* 2014 Jan; **6(1)**: 47-56. [DOI: 10.1111/sae.12022]. Epub 2013 Jun 10. [PMID: 27582910]; [PMCID: PMC4986646].
9. Farber AJ, Smith JS, Kvitne RS, Mohr KJ, Shin SS. Electromyographic analysis of forearm muscles in professional and amateur golfers. *Am J Sports Med.* 2009 Feb; **37(2)**: 396-401. [DOI: 10.1177/0363546508325154]. Epub 2008 Nov 20. [PMID: 19022991].
10. Ficke BW, Larrison MC, Ponce BA. Isolated Rupture of the Pronator Teres in an Amateur Golfer: A Case Report. *International Journal of Orthopaedics.* 2015Dec23; **2(6)**: 481-483. [DOI: 10.17554/j.issn.2311-5106.2015.02.130]
11. Field LD, Savoie FH. Common elbow injuries in sport. *Sports Med.* 1998 Sep; **26(3)**: 193-205. [DOI: 10.2165/00007256-199826030-00005]; [PMID: 9802175].
12. Ghisa C, Peck E. Comparative Sonographic and Magnetic Resonance Images of an Acute Pronator Teres Full-Thickness Tear. *PM R.* 2018 Sep; **10(9)**: 984-987. [DOI: 10.1016/j.pmrj.2018.03.020]. Epub 2018 Apr 5. [PMID: 29626615].
13. Gosheger G, Liem D, Ludwig K, Greshake O, Winkelmann W. Injuries and overuse syndromes in golf. *Am J Sports Med.* 2003 May-Jun; **31(3)**: 438-443. [DOI: 10.1177/03635465030310031901]; [PMID: 12750140].
14. Kim SE, Koh YC, Cho JH, Lee SY, Lee HD, Lee SC. Biomechanical Effects of Ball Position on Address Position Variables of Elite Golfers. *J Sports Sci Med.* 2018 Nov 20; **17(4)**: 589-598. [PMID: 30479527]; [PMCID: PMC6243633].
15. McHardy A, Pollard H, Luo K. One-year follow-up study on golf injuries in Australian amateur golfers. *Am J Sports Med.* 2007 Aug; **35(8)**: 1354-60. [DOI: 10.1177/0363546507300188]. Epub 2007 Mar 26. [PMID: 17387218].
16. Nesbit SM, McGinnis RS. Kinetic constrained optimization of the golf swing hub path. *J Sports Sci Med.* 2014 Dec 1; **13(4)**: 859-73. [PMID: 25435779]; [PMCID: PMC4234956].
17. Niebuiski HZ, Richardson ML. High-grade pronator teres tear

Guzman AJ *et al.* Pronator Teres Tear Case Report

- in a cricket batsman. *Radiol Case Rep.* 2015 Nov 6; **6(3)**: 540. [DOI: 10.2484/rcr.v6i3.540]; [PMID: 27307919]; [PMCID: PMC4900047].
18. Qayyum U, Villacis D, Jobin CM. Pronator Teres Myotendinous Tear. *Am J Orthop (Belle Mead NJ)*. 2017 Mar/Apr; **46(2)**: E105-E107. [PMID: 28437501].
19. Willemot L, Hendrikx FR, Byrne AM, van Riet RP. Valgus instability of the elbow: acute and chronic form. *Obere Extrem.* 2018; **13(3)**: 173-179. [DOI: 10.1007/s11678-018-0465-1]. Epub 2018 May 30. [PMID: 30220920]; [PMCID: PMC6132395].