

## Recurrent Intraosseous Spindle Myoepithelioma of the Distal Fibula: A Clinical and Radiological Challenge

Andrei Tuluca<sup>1\*</sup>, Sai S. Kilaru<sup>1\*</sup>, Gopi K. Nallani<sup>2</sup>

1 Central Michigan University College of Medicine; the United States;

2 Advanced Diagnostic Imaging, Department of Radiology-Covenant Healthcare; the United States.

\*these co-first authors contributed equally to the work

**Conflict-of-interest statement:** The author(s) declare(s) that there is no conflict of interest regarding the publication of this paper.

**Open-Access:** This article is an open-access article which was selected by an in-house editor and fully peer-reviewed by external reviewers. It is distributed in accordance with the Creative Commons Attribution Non Commercial (CC BY-NC 4.0) license, which permits others to distribute, remix, adapt, build upon this work non-commercially, and license their derivative works on different terms, provided the original work is properly cited and the use is non-commercial. See: <http://creativecommons.org/licenses/by-nc/4.0/>

**Correspondence to:** Andrei Tuluca, Central Michigan University College of Medicine; the United States.

Email: [tuluclam@cmich.edu](mailto:tuluclam@cmich.edu)

Telephone: +1-(973)-294-0011

Received: March 10, 2021

Revised: March 20, 2021

Accepted: March 23 2021

Published online: April 28, 2021

### ABSTRACT

A 42-year-old man with a past history of lipomas, presented with right ankle pain radiating to the hip and limited range of motion of the ankle. An initial x-ray was performed revealing an expansile lytic lesion in the right distal fibula. Next, an MRI was performed to confirm this expansile lytic lesion. Initial presumptive differential diagnoses included chondromyxoid fibroma, osteoblastoma, intraosseous ganglion cyst and Brodie's abscess. However, upon bone biopsy the pathology report revealed that the lesion was smooth muscle actin (SMA) positive and an ultimate diagnosis of intraosseous spindle myoepithelioma (ISM) was made. Curettage was then performed on the initial lesion to excise the tumor. The patient since has had multiple recurrences of this lesion. The diagnosis of ISM is rare and can present with many challenges in

diagnosis radiologically and clinically as this tumor can mimic many common diagnoses. Due to the paucity of literature on this topic, documentation of this case will help enhance the understanding of this rare lesion, its behavior, and possible genetic associations.

**Key words:** Intraosseous myoepithelioma; Fibula; Recurrent myoepithelioma; Spindle myoepithelioma; Smooth muscle actin; Orthopedic oncology

© 2021 The Author(s). Published by ACT Publishing Group Ltd. All rights reserved.

Tuluca A, Kilaru SS, Nallani GK. Recurrent Intraosseous Spindle Myoepithelioma of the Distal Fibula: A Clinical and Radiological Challenge. *International Journal of Orthopaedics* 2021; 8(2): 1463-1466 Available from: URL: <http://www.ghrnet.org/index.php/ijo/article/view/3112>

### INTRODUCTION

Intraosseous spindle myoepithelioma (ISM) are rare tumors that present with mixed pathology within the classification of myoepithelial tumors. Historically, myoepithelial tumors (MET) that occur in the soft tissue or the bone bear resemblance to those METs in the salivary glands<sup>[1]</sup>. The diagnosis of ISM has become more common within the recent years due to the increased use of diagnostic criteria such as immunohistochemical (IHC) markers to identify these tumors<sup>[2]</sup>. While IHC has increased the incidence of diagnosis, much remains unknown regarding these tumors including their associations, clinical course, and definitive treatment.

Review of previous literature has demonstrated a propensity of these tumors to occur in the mandible or typically an extra salivary gland location<sup>[2]</sup>. These locations are expected given the nature of myoepithelial cells which are commonly seen in glandular tissues. Myoepithelial tumors in non-traditional bony locations often are found to have gland formation that demonstrates a biphasic morphology<sup>[1]</sup>. Previous literature has also elucidated varying METs within these non-traditional bony locations like the ribs and the tibia<sup>[3,4]</sup>.

In addition, myoepithelial carcinomas at a histological level are usually not correlated to their behavior. In fact, tumors with low histological grades can commonly behave in aggressive manners with distant metastasis to the liver, bone, lungs, kidneys and many more locations<sup>[3,4]</sup>. Interestingly, these locations are more common

than regional lymph node metastasis<sup>[3,4]</sup>. This difficulty in diagnosing and predicting the clinical course of MET has made characterizing and understanding tumor behavior very elusive<sup>[2]</sup>.

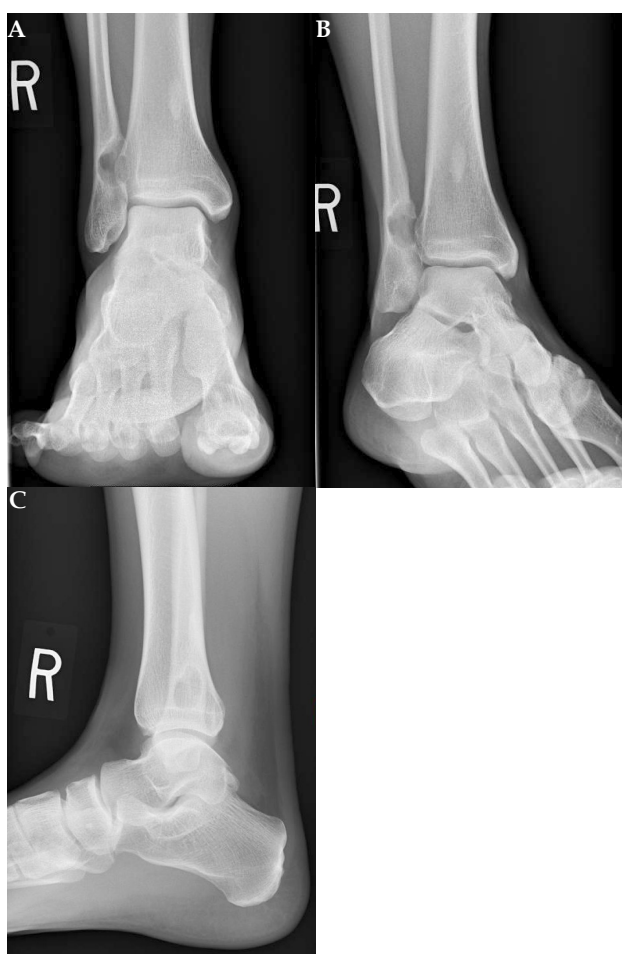Recent advances in cytogenetics have brought to light another perspective in the diagnosis of METs, distinct molecular changes. Approximately 70% of the documented cases of intraosseous METs have been associated with *Ewing sarcoma breakpoint region 1 (EWSR1)* gene rearrangements<sup>[5,6]</sup>. Cytogenetic analysis of various cases of intraosseous spindle myoepithelioma have revealed the wide variety of fusions possible between *EWSR1* and other genes such as *PBX1*, *PBX3*, *ZNF444*, and *POU5F1*<sup>[7]</sup>. Despite the increased knowledge in the diagnostic criteria of intraosseous METs, which is rapidly evolving to become more specific and precise, much remains unknown on a case to case basis when involving intraosseous METs in rare locations.

## CASE REPORT

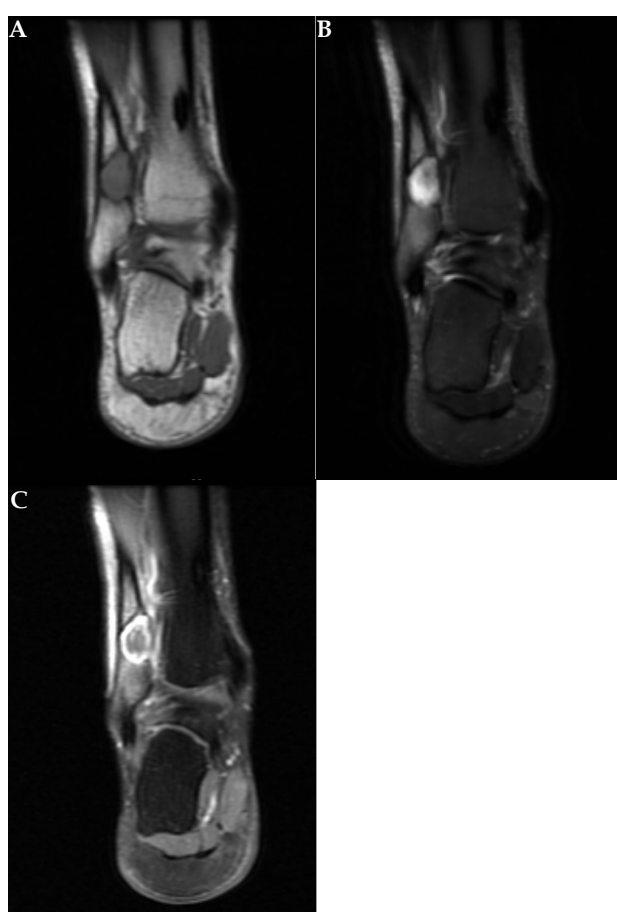
A 42-year-old man with a past history of lipomas presented with right ankle pain radiating to the hip and limited range of dorsiflexion of the right ankle. Radiographs revealed an expansile lytic lesion with narrow zone of transition and sclerotic margin involving the distal one third shaft of the fibula at the level of inferior tibiofibular joint (Figure 1). Next, an MRI was performed and confirmed the lesion as seen on the radiograph. In addition, the T1 imaging revealed a sclerotic margin and mild marrow edema surrounding the bone marrow (Figure 2A). The post-contrast image showed

intense peripheral enhancement in the right ankle (Figure 2C). Initial presumptive differential diagnoses after the MRI included chondromyxoid fibroma, osteoblastoma, intraosseous ganglion cyst, and Brodie's abscess. However, upon bone biopsy the pathology report revealed multiple fragments of bone and soft tissue that were involved by a low grade spindle cell neoplasm in a myxoid background. No necrosis or mitosis were seen. The biopsy sample was smooth muscle actin (SMA) positive and negative for other immunohistochemical markers including S100, AE1/3, CD31, CD34, desmin, EMA, P63, and SOX10. An ultimate diagnosis of intraosseous spindle myoepithelioma (ISM) was made. The patient was then treated with curettage to excise the tumor and an argon beam was used to coagulate the bone defect. The bone was also filled with allograft croutons during surgery.

Two years after the initial surgical encounter the patient returned again with right ankle pain. Again, a lesion was seen on MRI with a biopsy that was positive for smooth muscle actin and polytypic cytokeratin. The patient was then treated similarly to the first time in respect to the right fibular lesion, however, during this procedure one angioliipoma and two lipomas from the right arm as well as one angioliipoma and one lipoma from the left arm were removed. One year later the patient for the third time presented with ankle pain and another recurrence of myoepithelioma confirmed by X-ray and MRI and was treated with curettage. The final known recurrence happened another year after the second recurrence and was confirmed by biopsy. This time the patient presented with an enlarging lump on the ankle with pain and sought a more definitive treatment. Therefore, the



**Figure 1** (a) Anteroposterior view, (b) sagittal view, (c) oblique view of the right fibula lesion showing intense peripheral enhancement.



**Figure 2** (a) shows a T1 image with sclerotic margin and mild marrow edema in the surrounding bone marrow, (b) shows a T2 image again showing a sclerotic margin, (c) is a post contrast image showing intense peripheral enhancement.

right distal fibula was removed in its entirety and a 3D reconstructed distal fibula was placed.

## DISCUSSION

Myoepithelial tumors vary in terms of immunohistological markers making the tumors hard to characterize clinically<sup>[8]</sup>. While it has become widely accepted that the presence of S100 and smooth muscle actin (SMA) are generally consistent with the presence of METs, not all METs display this pattern including our patient who was S100 negative. In fact, there are other cases reported in which myoepithelial tumors are not S100 positive<sup>[9,10,11]</sup>. This is especially true in rare locations like the fibula<sup>[11]</sup>. A previously reported myoepithelioma in the distal femur was S100 negative just like our patient<sup>[11]</sup>. This adds an additional diagnostic challenge to correctly identify S100 or SMA negative tumors. In addition to S100 and SMA, myoepitheliomas can be positive for many other markers including cytokeratins, GFAP, EMA, and AE3<sup>[8]</sup>.

Over the last decade there have been numerous studies suggesting that there is a connection between myoepithelial tumors and the *EWSR1* gene rearrangement<sup>[1,4,5]</sup>. *EWSR1* gene rearrangement and fusion has been implicated in almost 70% of intraosseous myoepitheliomas<sup>[5]</sup>. Literature has elucidated a subset of METs with known cytogenetic rearrangements between *EWSR1* and multiple other genes. The importance behind delineating these rearrangements lies within the ability to accurately diagnose such tumors at novel locations cytogenetically. Such novel locations for reported intraosseous myoepitheliomas have been in the posterior mediastinum, metatarsal bone, ankle, and soft tissue of the index finger<sup>[1,6,12]</sup>. Of these cases, all reported some fusion between *EWSR1* and a complementary gene. Furthermore, previous literature has reported that *EWSR1* negative myoepithelioma tumors are more likely to be located superficially in the skin or subcutaneous tissue, thus making diagnosis of intraosseous myoepithelioma less likely for *EWSR1* negative tumors<sup>[1]</sup>. Recently, however, *EWSR1-PBX3* has gained traction in recent reports given its newly formed association between superficial myoepithelioma and *EWSR1* positive tumors<sup>[13]</sup>.

Presently, our case demonstrated a patient who possessed both multiple lipomas, angiolipomas, and recurrent intraosseous spindle myoepithelioma. Prior research has loosely associated *EWSR1* positivity with strictly deep tissue or bone myoepithelioma with no superficial tumors. With the unique finding of a cutaneous syncytial myoepithelioma (CSM) in research literature bearing the *EWSR1-PBX3* fusion, there is a possibility to draw an association between the recurrence of ISM and lipomas present in our patient presenting with both deep bony tumors and superficial soft tissue tumors<sup>[13]</sup>.

In addition to the findings present above, *EWSR1-PBX3* has been reported as a “Single Case” fusion for myoepithelioma/mixed tumors indicating that recurrence events are extremely unlikely<sup>[14]</sup>. Presently, our patient presents with multiple recurrences over the course of a five year clinical period possibly indicating, although unconfirmed, the first report of a *EWSR1-PBX3* fusion presenting with multiple recurrences of both superficial soft tissue and deep bony tumors. In addition, consistent with our histology report, two previous cases of *EWSR1-PBX3* gene fusion described the histology of biopsy specimens as partially myoxid to collagenous matrix with nests or sheets of epithelioid to spindled cells<sup>[1,4,5]</sup>.

Current treatment includes curettage or resection of the tumor despite the possibility of local recurrence<sup>[2]</sup>. Although recurrence of this rare tumor has not been extensively studied due to both rarity of these tumors and short-term follow ups of other cases, our

patient is an example of a case with multiple recurrences over a five-year period with an ultimate treatment of a reconstructed fibula. In conclusion, there is still much to be understood regarding the diagnosis and prognosis of primary intraosseous myoepitheliomas as well as their associations with other benign tumors like lipomas. Our future work with the approval of the patient and IRB will hope to explore the potential connection between intraosseous myoepitheliomas and lipomas through the use of genetic sequencing to check for potential fusion genes.

## ACKNOWLEDGEMENTS

The authors would like to thank Brenda Johnroe for helping us acquire all necessary approvals and Dr. Rajiv M. Patel for his guidance.

## REFERENCES

1. Agaram NP, Chen HW, Zhang L, Sung YS, Panicek D, Healey JH, Nielsen GP, Fletcher CD, Antonescu CR. *EWSR1-PBX3*: a novel gene fusion in myoepithelial tumors. *Genes Chromosomes Cancer*. 2015 Feb; **54**(2): 63-71. [DOI: 10.1002/gcc.22216]. Epub 2014 Sep 18. [PMID: 25231231]; [PMCID: PMC4268355].
2. Kannadasan K, K VS, Kengagsubbiah S, Kumar S, V S. Intraosseous myoepithelial carcinoma of mandible- a case report with clinical, radiological, histopathologic and immunohistochemical features. *J Clin Diagn Res*. 2014; **8**(8): ZD46-ZD48. [DOI: 10.7860/JCDR/2014/10174.4762]
3. Tsujimura R, Izu A, Ohni S, Yoshida Y, Sugitani M. C-kit positive intraosseous myoepithelioma arising in rib: a case report. *Int J Clin Exp Pathol*. 2017 Aug 1; **10**(8): 8925-8927. [PMID: 31966761]; [PMCID: PMC6965425].
4. Brandal P, Panagopoulos I, Bjerkehagen B, Gorunova L, Skjeldal S, Micci F, Heim S. Detection of a t(1; 22)(q23; q12) translocation leading to an *EWSR1-PBX1* fusion gene in a myoepithelioma. *Genes Chromosomes Cancer*. 2008 Jul; **47**(7): 558-64. [DOI: 10.1002/gcc.20559]; [PMID: 18383210].
5. Pairet G, Tilman G, Sciort R, Schubert T, Perlepe V, Poirel HA, Galant C. Case Reports in Oncological Medicine Myoepithelioma: A New Rearrangement Involving the *LPP* Locus in a Case of Multiple Bone and Soft Tissue Lesions. *Case Rep Oncol Med*. 2018 Feb 27; **2018**: 3512847. [DOI: 10.1155/2018/3512847]; [PMID: 29992069]; [PMCID: PMC5848058].
6. Yun S, Kim SH, Cho HS, Choe G, Lee KS. *EWSR1-PBX3* fused myoepithelioma arising in metatarsal bone: Case report and review of the literature. *Pathol Int*. 2019 Jan; **69**(1): 42-7. [DOI: 10.1111/pin.12746]. Epub 2019 Jan 3. [PMID: 30605259].
7. Antonescu CR, Zhang L, Shao SY, Mosquera JM, Weinreb I, Katabi N, Fletcher CD. Frequent *PLAG1* gene rearrangements in skin and soft tissue myoepithelioma with ductal differentiation. *Genes Chromosomes Cancer*. 2013 Jul; **52**(7): 675-82. [DOI: 10.1002/gcc.22063]. Epub 2013 Apr 30. [PMID: 23630011]; [PMCID: PMC4041540].
8. Rekihi B, Amare P, Gulia A, Baisane C, Patil A, Agarwal S, Puri A, Jambhekar NA. Primary intraosseous myoepithelioma arising in the iliac bone and displaying trisomies of 11, 15, 17 with del (16q) and del (22q11)--A rare case report with review of literature. *Pathol Res Pract*. 2011 Dec 15; **207**(12): 780-5. [DOI: 10.1016/j.prp.2011.09.004]. Epub 2011 Nov 3. [PMID: 22054860].
9. Nambirajan A, Mridha AR, Sharma MC, Panda A, Palaniswamy A. Primary intra-osseous myoepithelioma of phalanx mimicking an enchondroma. *Skeletal Radiology*. 2016 Oct; **45**(10): 1453-1458. [DOI: 10.1007/s00256-016-2452-1]
10. Lai MC, Tan MH. Soft tissue myoepithelial cell carcinoma. *Singapore Med J*. 2016 Mar; **57**(3): 166-7. [DOI: 10.11622/smedj.2016058]; [PMID: 26997168]; [PMCID: PMC4800729].

11. Alberghini M, Pasquinelli G, Zanella L, Pignatti G, Benini S, Bacchini P, Bertoni F. Primary malignant myoepithelioma of the distal femur. *APMIS: Acta Pathologica, Microbiologica, et Immunologica Scandinavica*. 2007 Apr; **115(4)**: 376-380. [DOI: 10.1111/j.1600-0463.2007.apm\_569.x].
12. Habu T, Soh J, Toji T, Shien K, Niman E, Namba K, Sato H, Yamamoto H, Sugimoto S, Yamane M, Toyooka S. Myoepithelioma occurring in the posterior mediastinum harboring EWSR1 rearrangement: a case report. *Jpn J Clin Oncol*. 2018 Sep 1; **48(9)**: 851-854. [DOI: 10.1093/jjco/hyy100]; [PMID: 30053180].
13. Jo VY, Antonescu CR, Dickson BC, Swanson D, Zhang L, Fletcher CDM, Demicco EG. Cutaneous Syncytial Myoepithelioma Is Characterized by Recurrent EWSR1-PBX3 Fusions. *Am J Surg Pathol*. 2019 Oct; **43(10)**: 1349-1354. [DOI: 10.1097/PAS.0000000000001286]; [PMID: 31135487]; [PMCID: PMC6742566]
14. Mertens F, Antonescu CR, Mitelman F. Gene fusions in soft tissue tumors: Recurrent and overlapping pathogenetic themes. *Genes Chromosomes Cancer*. 2016 Apr; **55(4)**: 291-310. [DOI: 10.1002/gcc.22335]. Epub 2015 Dec 18. [PMID: 26684580]; [PMCID: PMC5012284]