

The Use of VEPTR in Congenital Scoliosis

Stefan Gavrilu^{1,2}, Ecaterina Maria Sora¹

1 “Maria Sklodowska Curie” Hospital, Bucharest, Romania;

2 “Carol Davila” University of Medicine and Pharmacology, Bucharest, Romania.

Conflict-of-interest statement: The author(s) declare(s) that there is no conflict of interest regarding the publication of this paper.

Open-Access: This article is an open-access article which was selected by an in-house editor and fully peer-reviewed by external reviewers. It is distributed in accordance with the Creative Commons Attribution Non Commercial (CC BY-NC 4.0) license, which permits others to distribute, remix, adapt, build upon this work non-commercially, and license their derivative works on different terms, provided the original work is properly cited and the use is non-commercial. See: <http://creativecommons.org/licenses/by-nc/4.0/>

Correspondence to: Stefan Gavrilu, “Maria Sklodowska Curie” Hospital, Bucharest, Romania.

Email: banteo@gmail.com

Telephone: +40722515011

Received: February 23, 2021

Revised: March 15, 2021

Accepted: March 18 2021

Published online: April 28, 2021

ABSTRACT

BACKGROUND: Congenital scoliosis is nowadays addressed by many surgical solutions. There are rare cases presenting with mixed vertebral defects associated with Thoracic Insufficiency Syndrome (TIS). The presence of mixed vertebral defects may present with a very high progressive potential, inducing a severe scoliotic curve which impairs the development of the thoracic cage. Additionally, these cases may associate rib fusions which will further impair the development of the lung in these patients. The unique surgical solution in these cases is represented by VEPTR (Vertical Expandable Prosthesis Titanium Rib) devices able to expand the thorax and to control the scoliotic curve.

MATERIAL AND METHODS: The surgical technique of the VEPTR device in a rib-to-spine construct consists in a distraction based device able to expand the thorax on the concave side of the scoliosis by consecutive distractions and, secondary, to control de scoliotic curve. The upper module of the device is placed on the

first, second and/or third rib and the lower module is fixed to the upper lumbar spine. The construct is completed with the expansion module which allows distractions (1/2 or 1 cm for each distraction). The patients undergo every 4-6 months consecutive distractions until skeletal maturity when definitive spinal fusion is performed.

RESULTS: The VEPTR device in standard constructs with placement as recommended by the developer proved to be efficient in controlling congenital scoliotic curves and thoracic expansion. Unusual placements of the device complicated the evolution of patients with congenital scoliosis and required additional surgical procedures to correct the deformities and to try to ensure remnant spinal growth.

CONCLUSIONS: The VEPTR device has strict indications, congenital scoliosis with TIS being one of them. Proper indication and surgical procedure will aid the patients all along spinal and thoracic growth, in order to obtain a lung and spinal development as close to normal as possible in order to avoid premature death due to TIS.

Key words: VEPTR; Congenital scoliosis; Mixed vertebral defect; Thoracic Insufficiency Syndrome

© 2021 The Author(s). Published by ACT Publishing Group Ltd. All rights reserved.

Gavrilu S, Sora EM. The Use of VEPTR in Congenital Scoliosis. *International Journal of Orthopaedics* 2021; 8(2): 1452-1456 Available from: URL: <http://www.ghrnet.org/index.php/ijo/article/view/3137>

INTRODUCTION

The VEPTR (Vertical Expandable Prosthesis Titanium Rib) represents a surgical solution in the treatment of congenital scoliosis, especially those with mixed vertebral defects (formation and segmentation defects in the same case). This device is indicated especially for the deformities affecting the thorax (depletion of the thoracic volume), with consecutive Thoracic Insufficiency Syndrome (TIS)^[1]. The main goal in the treatment of these patines is thoracic expansion, in order to ensure enough space for the lung to develop during growth. The secondary goal is to control the scoliotic curve induced by the congenital vertebral deformity which presents a high progression rate in these cases^[2]. Mixed vertebral defects with hemivertebra/hemivertebrae on one side and a longitudinal

bony bar on the opposite side present with a 5-7 Cobb degrees/year progression rate, inducing a severe scoliotic curve during a relatively short period^[3]. The distractions of the device, performed every 4-6 months until the age of 10 years, will expand the thorax and will control the scoliotic curve, avoiding the appearance of TIS. This device is a growth friendly device^[4] and it may be used starting with the age of 1.5 years. It works efficiently up to the age of 10 years when it has to be converted into a definitive spinal fusion.

The main goal of this expandable device is the avoidance and the treatment of TIS in skeletally immature patients. Pulmonary alveoles multiply in an accelerated mode during the first 4-5 years of life and continue to grow in volume up to the first 8 years of life^[5,6]. This is the age range where VEPTR is efficient in the treatment of patients with congenital scoliosis due to mixed vertebral defects and high progression rate of the scoliotic curve, associating TIS^[7]. In these patients the addition of a rib-to-rib construct on concave side may be useful in the expansion of the small and distorted hemithorax.

MATERIAL AND METHODS

The surgical technique in a rib-to-spine construct consists in 2 approaches, one in a J letter shape thoracotomy placed next to the internal rim of the scapula, exposing the upper ribs, and a 4- cm paraspinal incision just above the lumbar vertebra to be instrumented (usually L2). The upper module fixed on the ribs and the lower module fixed on the vertebra (laminar hook or transpedicular screw) are connected by the distraction module. If rib fusions are present, a thoracotomy is required to split the fusion in order the thoracic expansion to be effective (Figure 1). A 1-cm intraoperative distraction is next performed.

The distraction process has to be repeated every 4-6 months, up to the age of +10 years when the device is converted into a definitive spinal fusion. Distractions are minimal surgeries with small (2-3 cm) incisions centered on the distraction module (Figure 2).

RESULTS

The device controls the scoliotic curve and allows expansion of the thorax on the concave side in congenital scoliosis with fused ribs, as an absolute indication. The device proved to be effective in the

treatment of Klippel-Feil syndrome type 3 (associating thoracic congenital deformities), too (Figure 3).

Related to congenital scoliosis, Burnei^[8] reported a new construct option, entitled VEPTR vertebra-to-vertebra, the upper module being fixed on the vertebral lamina, with partially intracanal placement of the resulted ring. The follow-up of the patient after several

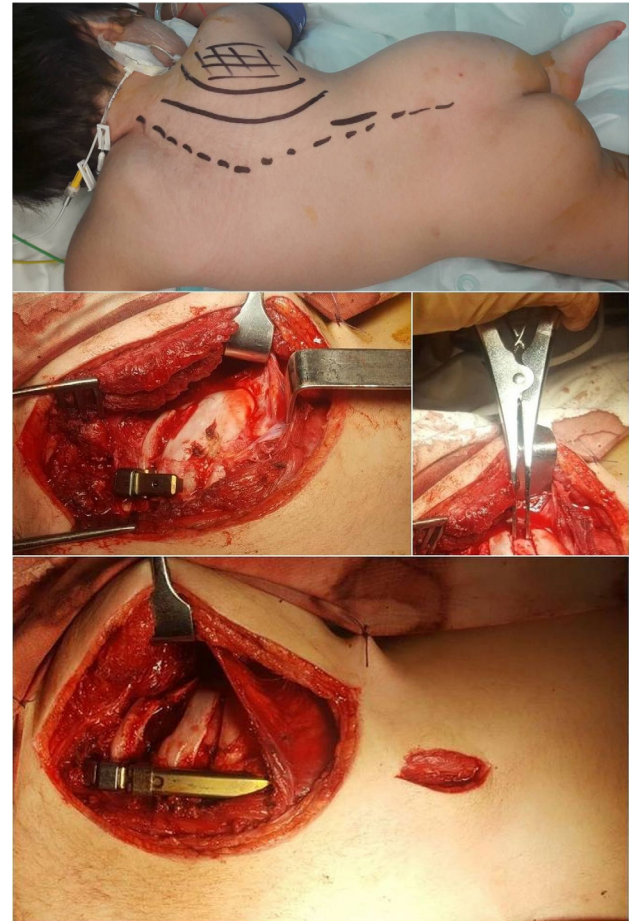


Figure 1 VEPTR surgical technique in rib-to-spine construct. The presence of rib fusions on the concave site requires the resection of the fusion and thoracotomies.

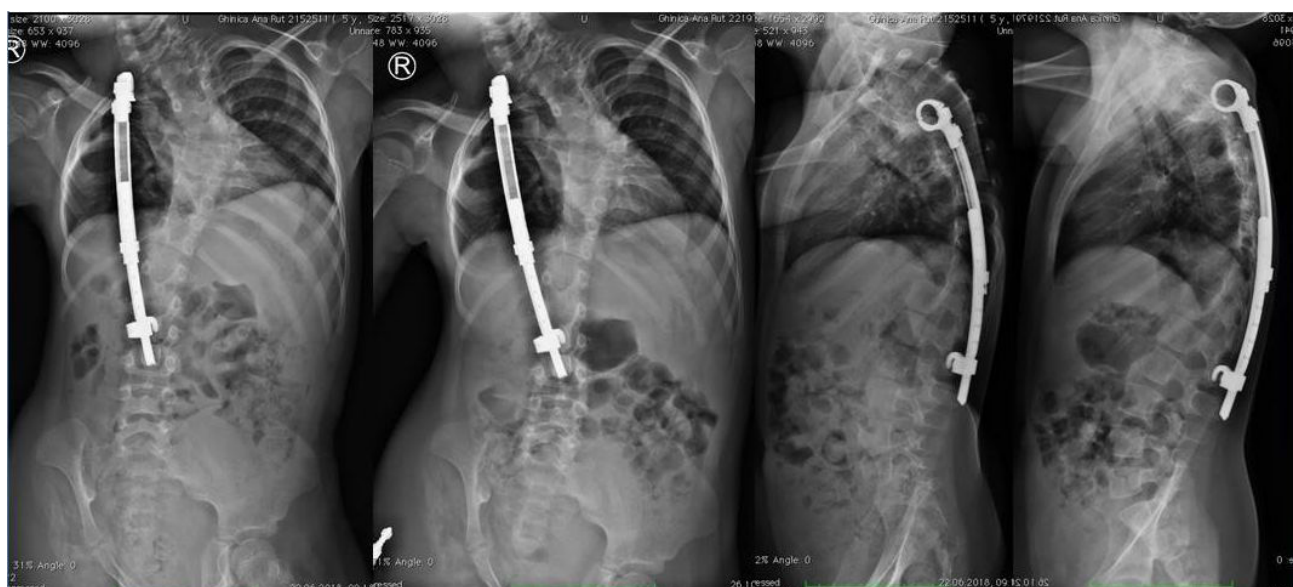


Figure 2 Sequenced distractions of the VEPTR device (every 4-6 months) until skeletal maturity.

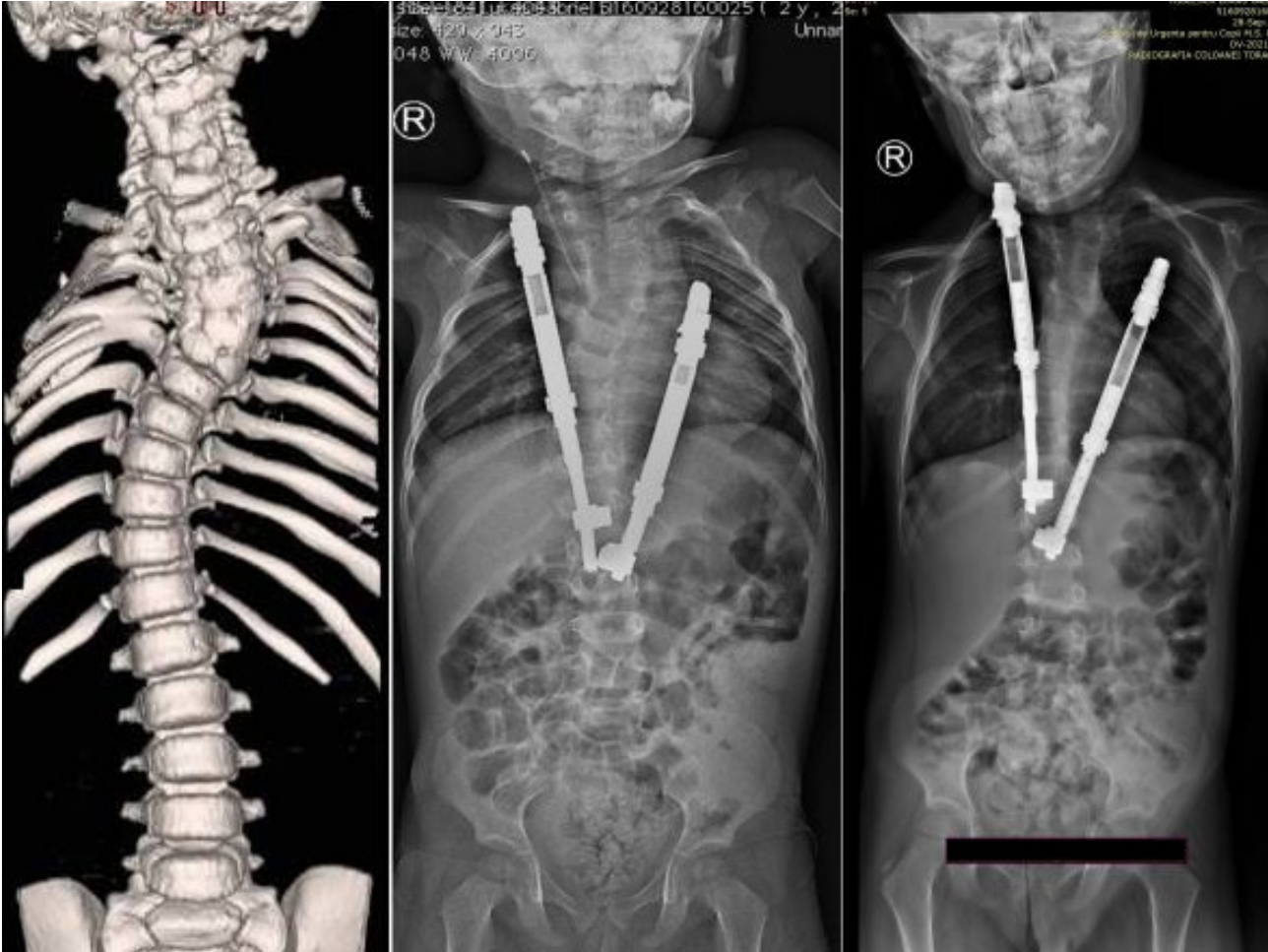

Figure 3 The use of VEPTR in Klippel-Feil type 3 syndrome with rib fusion.

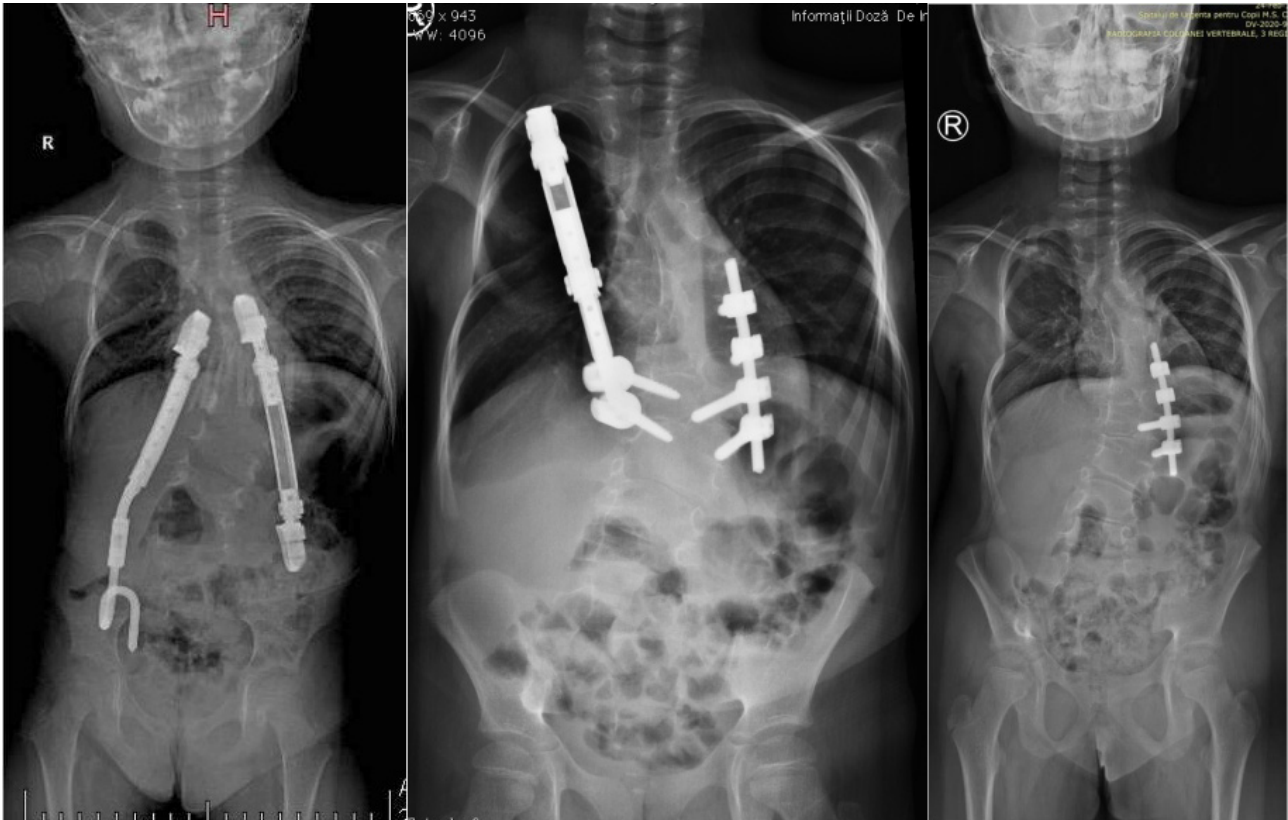

Figure 4 Premature removal had to be performed due to ineffective distraction. Vertebra-to-vertebra VEPTR construct with consecutive deformity and spinal fusion under the device.

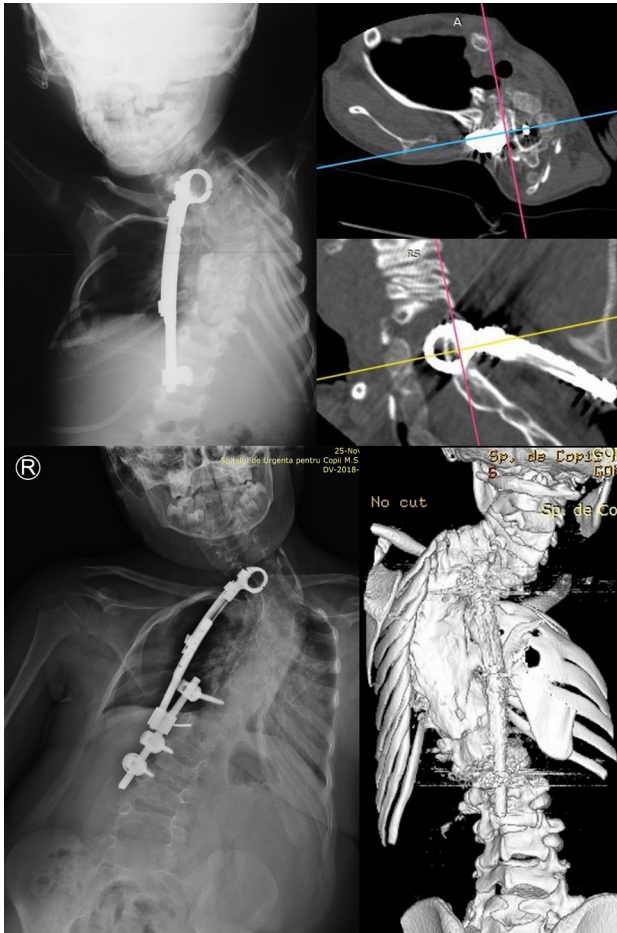


Figure 5 Vertebra-to-vertebra VEPTR construct with consecutive deformity and spinal fusion under the device.

distractions evidenced a poor result with worsening of the scoliotic curve, severe trunk imbalance, lack of thoracic expansion and a fused spine (Figure 4).

Further this unusual type of mounting has been applied to other 2 patients. The follow-up of these 3 patients with this type of using the VEPTR proved totally ineffective, inducing a more severe deformity with spinal fusion under the construct. In these patients the spine did not grow at all, despite several distractions of the VEPTR device. In these patients, other surgical procedures were required, with replacement of the VEPTR device in a standard position (rib-to-vertebra; 2nd or 3rd rib - L1, L2), respecting the producers surgical technique (Figure 5, Figure 6). The VEPTR procedure and principles had to be resumed in the standard construct type and additional procedures had to be performed, like closing wedge spinal osteotomies to correct the fused curve of the spine resulted by the unusual initial placement of the VEPTR device. Further distractions were performed until the age of skeletal maturity or ineffectiveness of the device. The results were satisfactory in one case and poor in the second case (lack of spinal growth and imbalanced sagittal plane). The encountered complication during revision surgery was spinal fusion due to the deviant initial surgical technique applied to these patients.

CONCLUSIONS

The VEPTR device represents the only effective solution in the surgical treatment of TIS. The standard constructs as recommended by the developer have to be applied as described in order for the

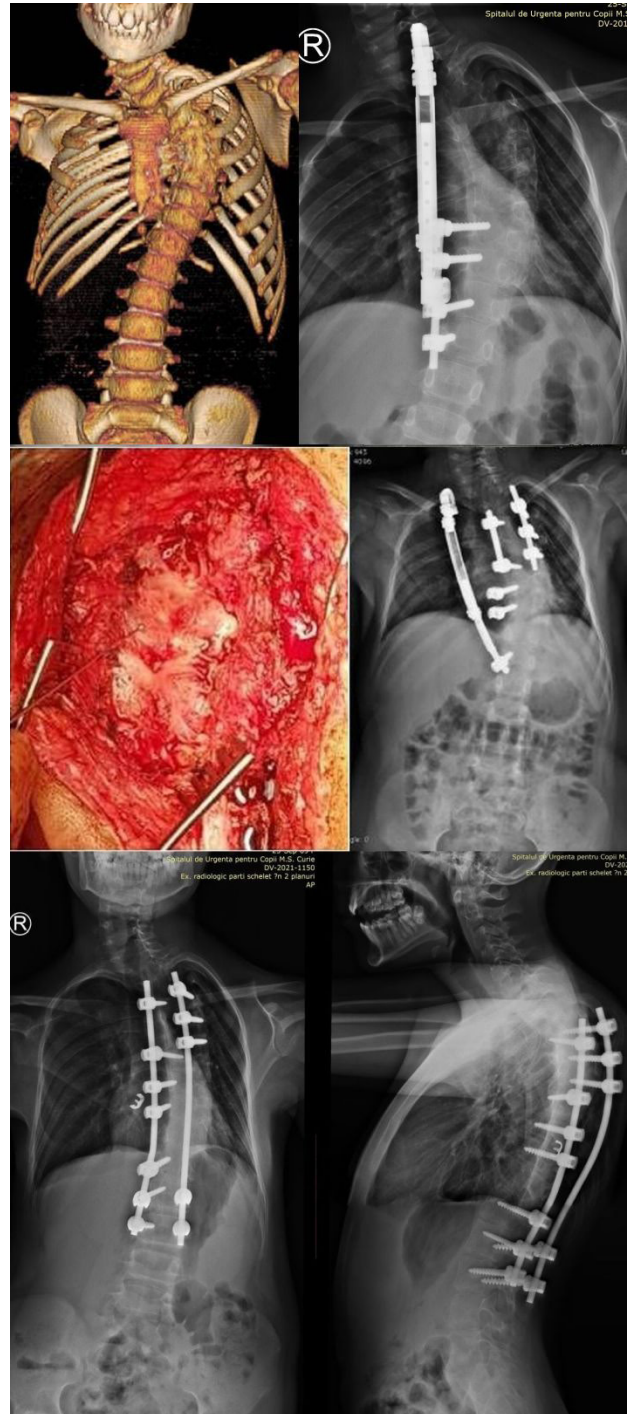


Figure 6 Vertebra-to-vertebra VEPTR construct. The failure to control the scoliotic curve required repositioning of the device and spinal apical wedged osteotomy.

VEPTR to be of use in the patients with congenital scoliosis and to avoid complications and unnecessary additional surgeries. Complications are frequently reported during the treatment of these patients with congenital spinal deformities^[9]. The VEPTR rib-to-vertebra construct has to be placed on the upper ribs (first, 2nd or 3rd) and on the upper lumbar vertebrae (usually L2) due to the preformed shape of the device (it presents a fixed radius which is molded in relationship to the anatomic shape of the trunk induced by the thoracic kyphosis). Latest recommendations by Campbell and Smith are a careful selection of the patients, rib anchors to be placed as cranial as possible, ideally with multiple rib anchors and 2

fixation points on the spine. The kyphosis should be respected, too. Any other placement will induce a disruption of the sagittal spinal balance.

The use of a VEPTR device in order to correct spinal deformities which have been operated before proved to be an ineffective solution, if no additional surgery to “free” the spine had been performed. During the periodical expansions of the device there was a poor improvement of the spinal status (curve correction and sagittal balance).

By any means, any other approach to the spine (midline approach with direct spinal approach on a long segment) should not be applied in order to avoid spinal fusion which will lead to an ineffective expansion device and finally a short spine, presenting the risk of an iatrogenically induced TIS. The recommended age (1.5 up to 10 years of age) and device mounting are mandatory to be respected in order to expect good results.

The placement of the device not respecting the surgical technique as described by the inventor of the VEPTR device induces ineffectiveness of the device and requires additional surgical procedures to correct the consecutive complications.

ACKNOWLEDGEMENTS

All procedures performed in studies involving human participants were in accordance with the ethical standards of the institutional and/or national research committee and with the 1964 Helsinki declaration and its later amendments or comparable ethical standards. Informed consent was obtained from all individual participants included in the study.

REFERENCES

1. Campbell Jr RM. VEPTR: past experience and the future of VEPTR principles. *Eur Spine J.* 2013 Mar; 22 **Suppl 2**: S106-17. [DOI: 10.1007/s00586-013-2671-2]
2. Tis JE, Karlin LI, Akbarnia BA, Blakemore LC, Thompson GH, McCarthy RE, Tello CA, Mendelow MJ, Southern EP. Early Onset Scoliosis: Modern Treatment and Results. *J Pediatr Orthop.* Oct-Nov 2012; **32(7)**: 647-57. [DOI: 10.1097/BPO.0b013e3182694f18]
3. Winter RB, Moe JH, Eilers VE. Congenital Scoliosis A Study of 234 Patients Treated and Untreated PART I: NATURAL HISTORY. *J Bone Joint Surg Am.* 1968 Jan 01; **50(1)**:1-15.
4. Skaggs DL, Akbarnia BA, Flynn JM, Myung KS, Paul D, Sponseller PD, Vitale MG. A Classification of Growth Friendly Spine Implants. *J Pediatr Orthop.* 2014; **34**: 260-274.
5. Davies G, Reid L. Effect of scoliosis on growth of alveoli and pulmonary arteries and on right ventricle. *Arch Dis Child.* 1971 Oct; **46(249)**: 623-632.
6. Davies G, Reid L. Growth of the alveoli and pulmonary arteries in childhood. *Thorax (1970)* **25**. 669-681.
7. Gregory Redding, Kit Song, Steve Inscore, Eric Effmann, Robert Campbell. Jul-Aug 2008; **8(4)**: 639-44. doi: 10.1016/j.spinee.2007.04.020. Epub 2007 Jun 21.
8. Burnei G, Gavriliu TS, Ileana Georgescu I, Costel Vlad C, Cristian Burnei C. An unusual case of congenital scoliosis associated with rib agenesis in the upper part of the concavity treated by VEPTR vertebra to vertebra. *The Spine Journal* 2013; **13**: e49-e53.
9. Waldhausen JHT, Redding G, White K, Song K. Complications in using the vertical expandable prosthetic titanium rib (VEPTR) in children. *Journal of Pediatric Surgery* **51(11)**: 1747-1750.