

## Technique and Outcomes of Antibiotic Impregnated Polymethylmethacrylate Coated Plates

Devon M. Myers<sup>1</sup>, DO; Hayden B. Schuette<sup>1</sup>, DO; Sean P. McGowan<sup>1</sup>, DO; Braden J. Passias<sup>1</sup>, DO; Robert Patterson<sup>2</sup>, BS; Benjamin C. Taylor<sup>3</sup>, MD

1 Department of Orthopedic Surgery, OhioHealth Grant Medical Center, Columbus, OH, USA;

2 Ohio University Heritage College of Osteopathic Medicine, Athens, OH, USA;

3 Orthopaedic Trauma and Reconstructive Surgeons, Department of Orthopedic Surgery, OhioHealth Grant Medical Center, Columbus, OH, USA.

**Conflict-of-interest statement:** The author(s) declare(s) that there is no conflict of interest regarding the publication of this paper.

**Open-Access:** This article is an open-access article which was selected by an in-house editor and fully peer-reviewed by external reviewers. It is distributed in accordance with the Creative Commons Attribution Non Commercial (CC BY-NC 4.0) license, which permits others to distribute, remix, adapt, build upon this work non-commercially, and license their derivative works on different terms, provided the original work is properly cited and the use is non-commercial. See: <http://creativecommons.org/licenses/by-nc/4.0/>

**Correspondence to:** Devon M. Myers, D.O., 285 East State Street, Suite 500, Columbus, OH, 43215, USA.

**Email:** [devon.myers@ohiohealth.com](mailto:devon.myers@ohiohealth.com)

**Telephone:** +1-314-607-6811

**Fax:** +1-614-566-8098

**Received:** June 5, 2021

**Revised:** July 3, 2021

**Accepted:** July 6 2021

**Published online:** August 28, 2021

### ABSTRACT

**AIM:** The purpose of this article is to describe a technique of coating hardware with antibiotic impregnated polymethylmethacrylate (PMMA) and to report the clinical series results.

**MATERIALS AND METHODS:** Adults were retrospectively identified that underwent surgical stabilization of long-bone fractures with an antibiotic impregnated PMMA coated plate. Exclusion criteria included patients with less than one year follow-up, those with no documentation of radiographic union, and those with

incomplete documentation on the type and amount of antibiotics used in the PMMA. Patient demographics, injury characteristics, as well as perioperative variables were collected from the electronic medical records.

**RESULTS:** Six patients met inclusion and exclusion criteria and were included in this retrospective case series. Five patients were male. Four of the patients were treated for humerus fractures, one for an ulna fracture, and one for a both bone forearm fracture. Three of the patients had a history of an open fracture. Five of the patients went on to have fracture union with no evidence of persistent infection following antibiotic impregnated PMMA coated plating. One patient had persistent infection resulting in a nonunion requiring repeat operation.

**CONCLUSIONS:** Antibiotic impregnated PMMA plating is an effective technique that may prove useful in cases of orthopedic hardware infection requiring further fixation. The use of this technique in a prophylactic setting for patients at high risk of infection and poor outcomes may prove to be of an even greater clinical significance.

**Key words:** Antibiotic plating; Septic nonunion; Polymethylmethacrylate; Prophylactic antibiotic plating

© 2021 The Author(s). Published by ACT Publishing Group Ltd. All rights reserved.

Myers DM, Schuette HB, McGowan SP, Passias BJ, Patterson R, Taylor BC. Technique and Outcomes of Antibiotic Impregnated Polymethylmethacrylate Coated Plates. *International Journal of Orthopaedics* 2021; 8(4): 1512-1517 Available from: URL: <http://www.ghrnet.org/index.php/ijo/article/view/3164>

### INTRODUCTION

Infection following fracture fixation is a devastating orthopedic complication. Published rates of deep infection following internal fixation are around 5%<sup>[1-3]</sup>. Hardware infections can present acutely or in the setting of chronic fracture nonunion with infection noted as the cause of 40% of nonunions<sup>[4]</sup>. Both situations present unique challenges to the treating surgeon and increase the risks of osteomyelitis, implant failure, hospital length of stays, reoperation

and amputation<sup>[1,2,4]</sup>. In addition, treatment may cost upwards of \$15,000 per patient<sup>[1,5]</sup>. Populations at risk for poorer outcomes include age > 50, females, BMI > 30 and those with OTA Type C or open fractures<sup>[3,4,6]</sup>.

Current treatment recommendations for deep hardware infection include removal of implants, debridement, lavage, intravenous antibiotics and possible antibiotic bead placement<sup>[7-9]</sup>. It has been well established that removal of infected hardware and meticulous debridement is paramount in decreasing the biofilm burden that contribute to these infections<sup>[2,7,9,10]</sup>. While some studies have shown these techniques do have acceptable success rates, results are worse specifically with orthopedic plate hardware<sup>[12]</sup>. Also of concern are cases where acute infection may compromise fracture stability with removal of hardware. Qui *et al*<sup>[9]</sup> demonstrated an average time to debridement of only 15 days and Conway *et al*<sup>[8]</sup> reaffirmed concerns that need for early hardware removal may compromise long term fracture stability and increase chances for malunion or nonunion.

The use of antibiotic impregnated polymethylmethacrylate (PMMA) as an antibiotic carrier and delivery vehicle has been previously described<sup>[13-16]</sup>. This technique has been used to fill large, bony defects in the setting of infection and has more recently been utilized in PMMA antibiotic eluting intramedullary nails for long-bone nonunions with high rates of infection eradication and fracture union<sup>[17-22]</sup>. Given the aforementioned challenges with infected plate fixation, a few authors have recently reported success with similarly coated PMMA antibiotic plates. These early reports have been encouraging, with high rates of infection eradication, union and improved clinical outcomes<sup>[8,9,16,17,23]</sup>. This technique may be particularly beneficial in the setting of an acute hardware infection, or in that of an infected nonunion, where PMMA coated plates may stabilize the fracture site until the infection can be eradicated. Furthermore, this technique may be particularly useful in the setting of peri-articular fractures where antibiotic coated intramedullary nails may not be an option<sup>[16]</sup>. Additionally, this technique may be useful as a prophylactic agent against infection in grossly contaminated open fractures. In this review, we describe the technique, and associated outcomes, of the use of an antibiotic impregnated cement coated plate construct utilized in a case series of orthopedic trauma patients.

## METHODS

Following institutional review board approval and informed consent, a retrospective chart review was performed from our level I trauma center's database. There were no relevant conflicts of interest or funding to note before data collection. Patient 18 years of age and older who had undergone antibiotic impregnated PMMA plating for a long bone fracture between January 2015 and January 2020 were included in this study. Exclusion criteria included patients with less than one year follow up, those with no documentation of radiographic union or nonunion, and those with incomplete documentation regarding the type and amount of antibiotics used to mix with the PMMA. Patient demographics, injury characteristics, as well as preoperative, intraoperative, and postoperative variables were collected from the electronic medical records.

### Technique Overview

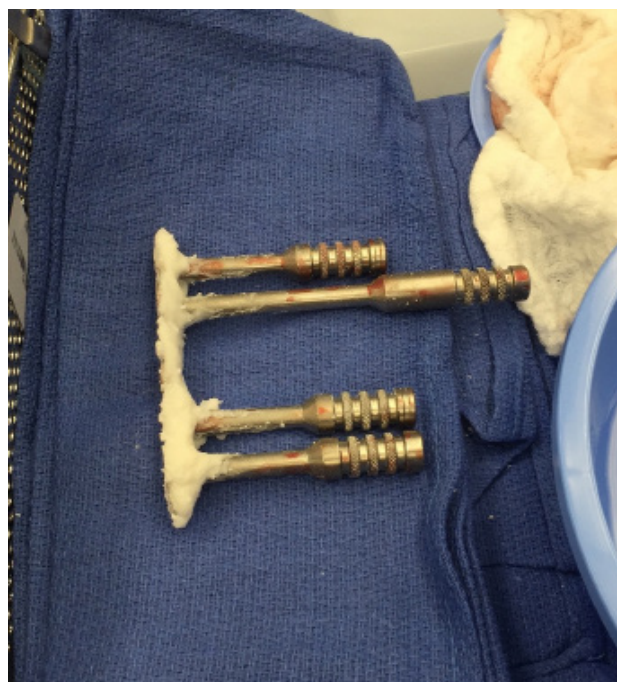All patients were brought to the operating room and prepped and draped in standard fashion. If external fixator was previously placed, it was prepped in and removed in a similar sterile manner. Prior approaches were used if possible, and standard approaches for the humerus and forearm were utilized if necessary. Following sharp

dissection, the fracture site and, in some cases, hardware were identified. If concern for infection existed, culture swabs and tissue cultures were obtained. The site of injury was then thoroughly debrided and irrigated, ensuring a clean wound free of contamination. Attention was then turned to fracture reduction, which was achieved with bony manipulation and provisional stabilization. In some cases, large bony defects were present, necessitating cement spacer insertion or acute limb shortening in order to achieve clean fracture edges.

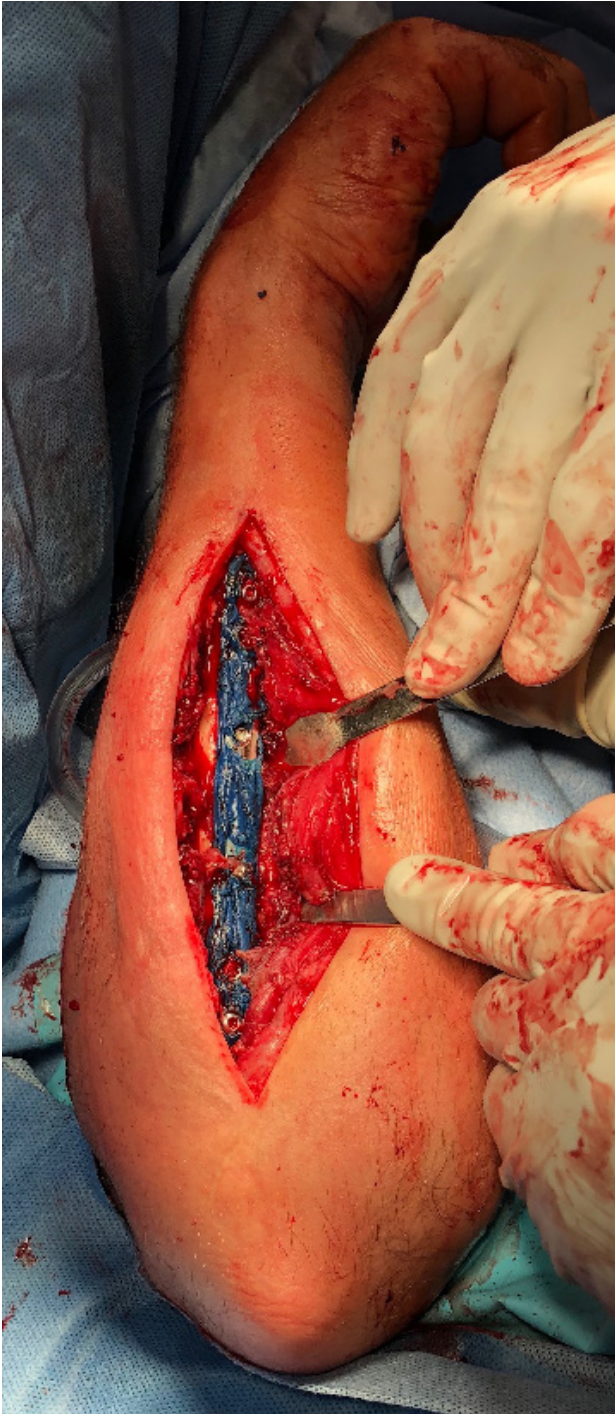Next, the antibiotic impregnated PMMA plate was constructed. One unit of PMMA cement was mixed with two grams of vancomycin powder and 2.4 grams of either tobramycin or gentamicin powder. Based on surgeon preference, three milliliters of methylene blue was added for easier future cement identification. Once the cement mixture had thickened and allowed for adequate handling, it was applied in a thin layer over the surface of the chosen orthopedic plate(s). Locking towers were used to cover screw holes that were going to be used in the eventual construct, so that cement would not prevent screw heads from appropriately contacting the plate (Figure 1). It is important to ensure no cement is retained within the chosen holes using a freer elevator or hemostat. The plate was then positioned and fixated about the fracture site, ensuring maintenance of anatomic reduction (Figure 2). After satisfactory placement was confirmed on fluoroscopy, the wound was irrigated and closed in layered fashion.

## RESULTS

A total of six patients were identified, all of which had humeral or forearm shaft fractures. Three patients were treated for hardware infection or septic nonunion as identified by history, physical examination, radiographs, and laboratory markers. Three other patients were prophylactically treated at the discretion of the surgeon in clinical scenarios deemed at high risk for infection. The majority of participants were male and <50 years old. Complete demographic and surgical information regarding each patient can be found in Table 1.



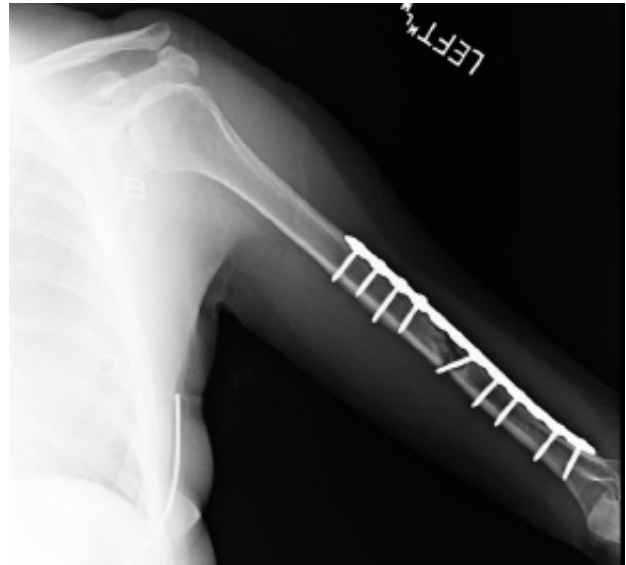
**Figure 1** The plate is coated with antibiotic impregnated PMMA with locking guide towers in place to prevent cement from disrupting screw hole locking mechanism.



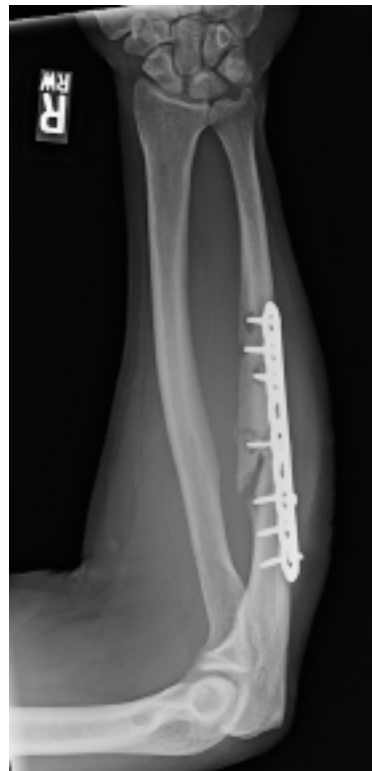**Figure 2** Demonstrates plating of ulnar shaft fracture using antibiotic coated PMMA mixed with methylene blue.

#### Antibiotic PMMA plating for infection

Three patients were identified as having infections involving orthopedic hardware after fracture fixation. The first patient was a 43-year-old male who initially underwent open reduction and internal fixation (ORIF) of a closed humeral shaft fracture and developed a postoperative infection. Intraoperative cultures grew *Yokenella regensburgei*. Although there were signs of immature callus, the fracture was not healed on intraoperative examination. For this reason, an antibiotic impregnated PMMA plate was placed. Six weeks of IV antibiotics were then prescribed post-operatively and no further infections were noted. Unrestricted weight-bearing was allowed at three months and fracture union was noted at five months. A 25-year-



**Figure 3** Anteroposterior radiograph of left humerus demonstrating humeral shaft nonunion after initial open reduction internal fixation.



**Figure 4** Anteroposterior radiograph of right forearm status post ulnar shaft open reduction and internal fixation demonstrating hardware loosening and loss of reduction.

old female also sustained a closed, midshaft humerus fracture which was initially treated with ORIF. Throughout her post-operative period there was concern for nonunion (Figure 3) and revision ORIF was performed approximately eight months after her initial surgery. A 4.5 mm dynamic compression plate was used at that time. Three weeks after her revision ORIF she was noted to have a surgical site infection and she was taken back to the operating room for irrigation and debridement, where cultures grew *Staphylococcus aureus*. Antibiotic impregnated PMMA 4.5mm dynamic compression plate was used to maintain fracture stability at prior nonunion site. She received intravenous cefazolin and rifampin for 60 days after surgery. Fracture

**Table 1** Demographic and Surgical Characteristics.

Patient	Age	Sex	BMI	Smoker?	Fracture Type	Open Fracture? (GA)	Prior Surgery?	Positive culture?	OR time (min)	Fluoroscopy time (sec)	Time to WB (wks)	Union after Abx plate?	Infection?	Return to OR?
1	43	M	38.5	N	Humerus	N	Y	Y	116	6.3	13	Y	N	N
2	25	F	22.1	Y	Humerus	N	Y	Y	43	8	23	Y	N	N
3	18	M	36.6	N	Humerus	Y (2)	N	N	156	92	15	Y	N	N
4	20	M	25.3	N	Humerus	Y (3b)	Y	N	152	8	26	N	N	Y
5	50	M	32.3	N	BBFA	Y (3a)	Y	N	170	17	13	Y	N	N
6	61	M	29.3	Y	Ulna	N	Y	Y	70	6.4	11	Y	N	N

Abx: Antibiotic; BBFA: Both-bone forearm; GA: Gustillo-Anderson open fracture grade; OR: Operating room; WB: Weightbearing.

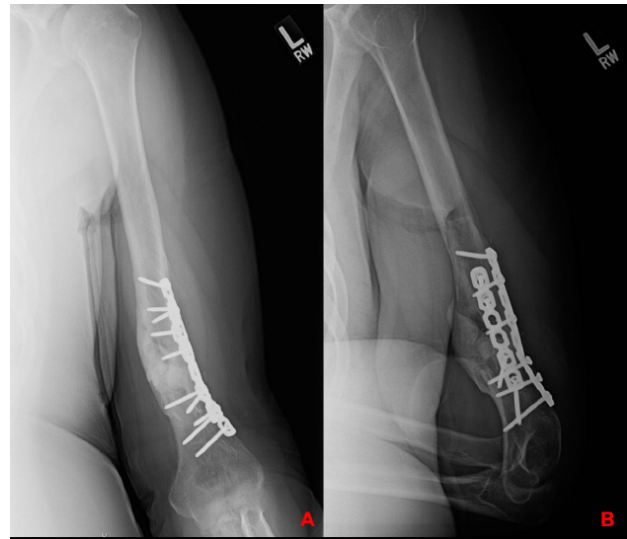
union was noted at 15 weeks post-operatively and full weight-bearing was achieved at 23 weeks with no further infection or complications. Lastly, a 61-year-old male initially sustained a closed ulnar shaft fracture that was treated with ORIF. Approximately eight weeks later, there was concern for hardware infection and septic nonunion and he was taken back to the operating room. Screw loosening and loss of fracture reduction were noted (Figure 4), and cultures obtained intraoperatively grew *Enterobacter cloacae*. At that time a 3.5mm locking compression plate was coated with antibiotic impregnated PMMA cement and applied after adequate reduction of the fracture. Post-operatively, fracture union was achieved, and full weight-bearing was allowed at 11 weeks. No further infections were noted, and no additional surgery was required.

### Prophylactic antibiotic PMMA plating

Three patients sustained open fractures including an 18-year-old male with a Gustillo-Anderson Grade II humeral shaft fracture, a 20-year-old male with a Grade IIIb humeral shaft fracture and a 50-year-old male with a Grade IIIa both-bone forearm fracture. All three open fractures were grossly contaminated at the time of injury. All received cefazolin within one hour of arrival, with both Grade III fractures also receiving gentamicin. Both Grade III fractures underwent emergent irrigation and debridement with external fixation. At initial surgery, the Grade II humerus fracture underwent irrigation and debridement with placement of two small fragment recon plates coated with antibiotic impregnated PMMA cement in order to obtain stability in multiple planes. Both Grade III fractures were converted from external fixation to antibiotic PMMA plates within one week of initial injury. A 9-hole 3.5mm extra-articular distal humerus locking plate covered in antibiotic PMMA cement was used to stabilize the humeral shaft fracture while 3.5mm locking compression plates were coated in antibiotic impregnated PMMA and used on the radius and ulna for the both-bone forearm fracture. No signs of acute infection were identified prior to antibiotic PMMA plating in this population, therefore no cultures were obtained. At an average of 14 months follow-up, there were no superficial or deep infections noted. The 20-year-old male who initially sustained the open Grade IIIb humeral shaft fracture did require revision ORIF to address an atrophic nonunion eight months post-operatively but eventually went on to union. Of note, there was no evidence of superficial or deep infection at time of revision ORIF. Both of the other open fractures treated prophylactically with antibiotic coated PMMA plates went on to union without complication (Figure 5). Full weight-bearing was allowed at an average of five months.

## DISCUSSION

Fracture fixation complicated by infection can present significant challenges to the patient and treating surgeon. Despite advances



**Figure 5** Side-by-side anteroposterior humerus radiographs, both status post antibiotic PMMA plating that show evidence of fracture union with maintenance of hardware.

in technique and implant technology, rates of orthopedic hardware infection still average around 5%<sup>[1-3]</sup>. Standard of care in these cases is removal of hardware combined with local irrigation, debridement and fracture stabilization. The need for repeat operations leads to longer hospital stays, increased healthcare expenses and increases the likelihood of poorer patient outcomes<sup>[1-3,5]</sup>. While it is important to have options available to combat these difficult surgical problems, infection prevention is paramount and the introduction of novel antibiotic PMMA plating techniques may play an important role in both treating septic nonunions, as well as, infection prophylaxis in high risk patients.

PMMA has been historically described as a local delivery vehicle for antibiotics in cases of infection<sup>[13-15,24]</sup>. Traditionally, antibiotic PMMA mixtures were delivered locally with beads or used in situations where large bony defects were present. Results have been quite encouraging in these settings, with eradication rates reaching 100% in some studies<sup>[13]</sup>. While there has been some concern that antibiotic elution is slow when mixed with PMMA, this notion has been downplayed by others<sup>[14,24]</sup>. One other concern with antibiotic PMMA is the risk of local antibiotic resistance<sup>[25]</sup>. While theoretically possible, most local concentrations of antibiotic PMAA appear to be high enough to inhibit return of bacterial growth; more research on this topic is necessary to understand the long-term effects of antibiotic PMAA dosing and concentration on risk for local resistance. Due to the past successes of local antibiotic PMMA as well as antibiotic PMMA eluting intramedullary nails, it has more recently been explored as an adjunct to treating orthopedic hardware infections<sup>[18-22]</sup>. Along these lines, several authors have described

good clinical outcomes with the use of antibiotic PMMA coated orthopedic plates<sup>[8,9,16,23]</sup>.

Antibiotic PMMA plating may be particularly useful in acute hardware infections after fracture fixation, which unfortunately, often occur within the first several months after placement<sup>[3,8,9]</sup>. This presents a significant challenge in that many fractures are incompletely healed at this stage. While initial irrigation and debridement are essential in removing biofilms covering existing hardware, reduction and restoration of length, alignment and rotation of the fracture must remain an important long-term consideration<sup>[8,10,11,16]</sup>. In our series three patients had local infections after fracture fixation and were treated with removal of infected hardware, irrigation and debridement and placement of an antibiotic impregnated PMMA plate. All three patients went on to fracture union, with no evidence of hardware failure and no need for repeat operations. No patient had further issues with superficial or deep infection. All were able to resume full weight-bearing and two patients returned to their previous work duties. All three patients were given adjunctive IV antibiotics after their revision procedure, which prior authors have suggested works synergistically with the local effects of antibiotic PMMA<sup>[13]</sup>.

Furthermore, antibiotic PMMA plating may also be useful in the prevention of infection. It is well documented that open fractures carry higher rates of infection, leading to increased rates of systemic antibiotic use, reoperation and amputation<sup>[2,4]</sup>. Prophylactic fixation using an antibiotic impregnated PMMA plate is a novel technique that offers a sensible way to avoid these risks, particularly in contaminated, high grade open fractures. While there is little comparative data available from other studies, we demonstrated no superficial or deep infections in three patients with Grade II or III open fractures for whom the antibiotic PMMA plate was used prophylactically. One patient did require revision ORIF for an atrophic humeral shaft nonunion, without associated infection. His soft tissue envelope had healed appropriately by this time which allowed a much more controlled revision surgery. While a formal cost analysis was not undertaken, the cost of initial cement and local antibiotic use in high-risk patients seems to have clear financial benefits compared to the cost associated with revision surgery and treatment of septic nonunions. The use of antibiotic impregnated PMMA plating as prophylaxis against infection in the setting of high-grade open fracture may represent a valuable adjunct to achieving improved outcomes and decreasing associated infection and healthcare costs.

In conclusion, antibiotic impregnated PMMA plating is an effective technique that may prove useful in cases of orthopedic hardware infection requiring further fixation. The use of this technique in a prophylactic setting for patients at high risk of infection and poor outcomes may prove to be of an even greater clinical significance. It is with strong recommendation that larger, prospective investigations be conducted to further delineate the clinical utility of this technique.

## REFERENCES

- Shah MQ, Zardad MS, Khan A, Ahmed S, Awan AS, Mohammad T. Surgical Site Infection In Orthopaedic Implants And Its Common Bacteria With Their Sensitivities To Antibiotics, In Open Reduction Internal Fixation. *J Ayub Med Coll Abbottabad*. 2017; **29**(1): 50-3. [PMID: 28712173]
- El-Sayed D, Nouvong A. Infection Protocols for Implants. *Clin Podiatr Med Surg*. 2019; **36**(4): 627-649. [PMID: 31466572]; [DOI: 10.1016/j.cpm.2019.06.007]
- Parkkinen M, Madanat R, Lindahl J, Makinen TJ. Risk Factors for Deep Infection Following Plate Fixation of Proximal Tibial Fractures. *J Bone Joint Surg Am*. 2016; **98**(15): 1292-7. [PMID: 27489320]; [DOI: 10.2106/JBJS.15.00894]
- Simpson AHRW, Tsang STJ. Non-union After Plate Fixation. *Injury*. 2018; **49**(1): S78-82. [PMID: 29929699]; [DOI: 10.1016/S0020-1383(18)30309-7]
- Darouiche RO. Treatment of infections associated with surgical implants. *N Engl J Med*. 2004; **350**: 1422-9. [PMID: 15070792]; [DOI: 10.1056/NEJMra035415]
- Cuerel C, Abrassart S, Billieres J, Andrey D, Suva D, Dubois-Ferriere V, Uckay I. Clinical and Epidemiological Differences Between Implant-Associated and Implant-Free Orthopaedic Infections. *Eur J Orthop Surg Traumatol*. 2017; **27**(2): 229-231. [PMID: 27844159]; [DOI: 10.1007/s00590-016-1879-3]
- Dym H, Zeidan J. Microbiology of Acute and Chronic Osteomyelitis and Antibiotic Treatment. *Dent Clin North Am*. 2017; **61**(2): 271-282. [PMID: 28317566]; [DOI: 10.1016/j.cden.2016.12.001]
- Conway JD, Hlad LM, Bark SE. Antibiotic cement-coated plates for management of infected fractures. *Am J Orthop (Belle Mead NJ)*. 2015; **44**(2): e49-53. [PMID: 25658083]
- Qui XS, Cheng B, Chen YX, Qi X, Sha W, Chen G. Coating the plate with antibiotic cement to treat early infection after fracture fixation with retention of the implants: a technical note. *BMC Musculoskel Disord*. 2018; **19**(1): 360. [PMID: 30301459. [DOI: 10.1186/s12891-018-2285-2]
- Costerton JW. Biofilm Theory Can Guide the Treatment of Device-Related Orthopaedic Infections. *Clin Orthop Relat Res*. 2005; **437**: 7-11. [PMID: 16056019]; [DOI: 10.1097/00003086-200508000-00003]
- Schindler M, Gamulin A, Belaieff W, Francescato M, Bonvin A, Graf V, Hoffmeyer P, Wyssa B, Uckay I. No Need for Broad-Spectrum Empirical Antibiotic Coverage After Surgical Drainage of Orthopaedic Implant Infections. *Int Orthop*. 2013; **37**(10): 2025-30. [PMID: 23744500]; [DOI: 10.1007/s00264-013-1924-3]
- Al-Mayahi M, Betz M, Muller DA, Stern R, Tahintzi P, Bernard L, Hoffmeyer P, Suva D, Uckay I. Remission Rate of Implant-Related Infections Following Revision Surgery After Fractures. *Int Orthop*. 2013; **37**(11): 2253-8. [PMID: 24052163]; [DOI: 10.1007/s00264-013-2092-1]
- Evans RP, Neslon CL. Gentamicin-impregnated polymethylmethacrylate beads compared with systemic antibiotic therapy in the treatment of chronic osteomyelitis. *Clin Orthop Relat Res*. 1993; **295**: 37-42. [PMID: 8403668]
- McConoughey SJ, Howlin RP, Wiseman J, Stoodley P, Calhoun JH. Comparing PMMA and Calcium Sulfate as Carriers for the Local Delivery of Antibiotics to Infected Surgical Sites. *J Biomed Mater Res B Appl Biomater*. 2015; **103**(4): 870-7. [PMID: 25142105]; [DOI: 10.1002/jbm.b.33247]
- Hanssen AD. Local antibiotic delivery vehicles in the treatment of musculoskeletal infection. *Clin Orthop Relat Res*. 2005; **437**: 91-6. [PMID: 16056032]; [DOI: 10.1097/01.blo.0000175713.30506.77]
- Scolaro JA, Mehta S. Stabilization of infected peri-articular nonunions with an antibiotic impregnated cement coated locking plate: Technique and indication. *Injury*. 2016; **47**: 1353-6. [PMID: 26997131]; [DOI: 10.1016/j.injury.2016.03.010]
- Yu X, Wu H, Li J, Xie Z. Antibiotic cement-coated locking plate as a temporary internal fixator for femoral osteomyelitic defects. *Int Orthop*. 2017; **41**(9): 1851-7. [PMID: 27520738]; [DOI: 10.1007/s00264-016-3258-4]
- Oz M, Walter G. Temporary Intramedullary Stabilisation of Infected Non-Union in Long Bones With Local Antibiotic-Impregnated Cement Rods: Case Reports. *Z Orthop Unfall*. 2010; **148**(5): 559-565. [PMID: 20135598]; [DOI: 10.1055/s-0029-1186145]
- Craig J, Fuchs T, Jenks M, Fleetwood K, Franz D, Iff J, Raschke M. Systematic review and meta-analysis of the additional benefit of local prophylactic antibiotic therapy for infection rates in open tibia fractures treated with intramedullary nailing. *Int Orthop*.

- 2014; 38: 1025-30. [PMID: 24531401]; [DOI: 10.1007/s00264-014-2293-2]
20. Cho JW, Kim J, Cho WT, Kent WT, Kim H, Oh J. Antibiotic coated hinged threaded rods in the treatment of infected nonunions and intramedullary long bone infections. *Injury*. 2018; **49(10)**: 1912-1921. [PMID: 30060889]; [DOI: 10.1016/j.injury.2018.07.016]
  21. Pradhan C, Patil A, Puram C, Attarde D, Sancheti P, Shyam A. Can antibiotic impregnated cement nail achieve both infection control and bony union in infected diaphyseal femoral nonunions? *Injury*. 2017; **48 Suppl 2**: S66-S71. [PMID: 28802424]; [DOI: 10.1016/S0020-1383(17)30497-7]
  22. Thonse R, Conway J. Antibiotic cement-coated interlocking nail for the treatment of infected nonunions and segmental bone defects. *J Orthop Trauma*. 2007; **21(4)**: 258-68. [PMID: 17414554]; [DOI: 10.1097/BOT.0b013e31803ea9e6]
  23. Liporace FA, Yoon RS, Frank MA, Gaines RJ, Maurer JP, Polishchuk, Choung EW. Use of an "antibiotic plate" for infected periprosthetic fracture in total hip arthroplasty. *J Orthop Trauma*. 2012; **26(3)**: e18-23. [PMID: 21804411]; [DOI: 10.1097/BOT.0b013e318216dd60]
  24. Neut D, van de Belt H, Stokroos I, van Horn JR, van der Mei HC, Busscher HJ. Biomaterial-associated infection of gentamicin-loaded PMMA beads in orthopaedic revision surgery. *J Antimicrob Chemother*. 2001; **47**: 885-91. [PMID: 11389124]; [DOI: 10.1093/jac/47.6.885]
  25. von Eiff C, Lindner N, Proctor RA, et al. Development of gentamicin-resistant Small Colony Variants of *S. aureus* after implantation of gentamicin chains in osteomyelitis as a possible cause of recurrence. *Z Orthop Ihre Grenzgeb*. 1998; **136**: 268-71. [PMID: 9736990]