

Arthroscopic Findings in Recurrent Shoulder Instability: Gender and Age-Related Differences of Anteroinferior Labrum Injuries

Anestis IOSSIFIDIS¹, Al-achraf KHORIATI¹, Charalambos PETROU¹, Nicholas Iossifidis²

1 Department of Trauma and Orthopaedic Surgery, Shoulder Unit, Croydon University Hospital, London, UK.

2 Goldsmiths University of London.

Conflict-of-interest statement: The author(s) declare(s) that there is no conflict of interest regarding the publication of this paper.

Open-Access: This article is an open-access article which was selected by an in-house editor and fully peer-reviewed by external reviewers. It is distributed in accordance with the Creative Commons Attribution Non Commercial (CC BY-NC 4.0) license, which permits others to distribute, remix, adapt, build upon this work non-commercially, and license their derivative works on different terms, provided the original work is properly cited and the use is non-commercial. See: <http://creativecommons.org/licenses/by-nc/4.0/>

Correspondence to: Anestis Iossifidis, MD, FRCS Ed, FRCS Ed (orth.), Senior Orthopaedic Surgeon, Head of Shoulder & Upper limb Unit, Address: Croydon University Hospital, 530 London Road, Croydon, London, CR7 7YE.

Email: anestis.iossifidis@gmail.com

Telephone: +0044 (0) 7802404708

Received: July 25, 2021

Revised: August 10, 2021

Accepted: August 12 2021

Published online: October 28, 2021

ABSTRACT

AIM: Recurrent shoulder instability results in marked disability and affects mainly a young population. However, the gender and age-related differences in labral injuries have been underreported. The aim of our study is to evaluate the arthroscopic spectrum of anteroinferior labrum pathology in recurrent shoulder instability, and assess the gender and age-related differences.

METHOD: This was a study of 201 consecutive patients who underwent arthroscopic shoulder stabilisation for recurrent shoulder instability. Patients were divided into two age groups. Group 1: under 35 years old, included 152 patients, mean age of 26.3 for both sex, and Group 2: over 35 years old, included 49 patients, mean age 42.2

for male and 47.6 for female patients. The gender and age-related differences of arthroscopic findings between the two age groups and overall gender differences were evaluated.

RESULTS: Female patients had significantly less antero-inferior labrum lesions (85.7% vs 96.2%, $p < 0.011$) and more isolated capsule-ligamentous laxity (11.9% vs 1.8%, $p < 0.003$), than male patients. When analysing the three subtypes of labrum injuries, female patients were found to have significantly less Bankart lesions than male patients (15.4% vs 36.5%, $p < 0.037$). Both male and female patients in Group 2, had significantly more ALPSA lesions (51% vs 31%, $p < 0.0178$), and less combined Bankart & Perthes lesions (40.8% vs 63.8%, $p < 0.008$), than Group 1.

CONCLUSION: This study showed significant gender and age-related differences of anteroinferior capsule-labral complex injuries in chronic shoulder instability. We believe that increased awareness of the different pattern of injuries in female and older patients will be helpful in pre-operative planning and the implementation of the appropriate surgical management.

Key words: Arthroscopic shoulder stabilisation; Recurrent shoulder dislocation; Labrum lesions; Bankart lesion; ALPSA lesion

© 2021 The Author(s). Published by ACT Publishing Group Ltd. All rights reserved.

Iossifidis A, Khoriati A, Petrou C, Iossifidis N. Arthroscopic Findings in Recurrent Shoulder Instability: Gender and Age-Related Differences of Anteroinferior Labrum Injuries. *International Journal of Orthopaedics* 2021; 8(5): 1547-1551 Available from: URL: <http://www.ghrnet.org/index.php/ijo/article/view/3216>

INTRODUCTION

Anterior inferior dislocation is the most common, accounting for up to 97% of all shoulder dislocations with an incidence rate between 0.55 and 1.6 /1,000 person-years and a recurrence rate of 28.7%^[1,2]. The resultant labrum-ligamentous lesions are often complex and difficult to diagnose based on physical examination alone. Magnetic resonance arthrography has been reported as a useful diagnostic tool^[3-9].

Increasingly, three different types of anteroinferior labral injuries

have been recognised and each lesion requires a different surgical management approach. The classic Bankart lesion, the Perthes lesion and the anterior labrum periosteal sleeve avulsion (ALPSA) lesion, are the main three types of antero-inferior labral lesions contributing to shoulder instability^[10-13]. Successful post-operative outcome requires accurate arthroscopic diagnosis of these lesions, and deployment of accordant surgical technique. Although recurrent shoulder instability results in marked disability and affects mainly a young population, the gender and age-related differences in labral injuries have been underreported. The aim of our study was to evaluate the arthroscopic spectrum of labrum pathology in recurrent shoulder instability, and assess the gender and age differences in chronic antero-inferior labrum injuries.

METHODS

This was a retrospective study of 201 consecutive patients who underwent shoulder arthroscopic stabilisation for recurrent shoulder instability. The arthroscopic findings data were retrieved from our hospital digital archive system. The senior author followed an arthroscopic classification of antero-inferior labrum lesions, recognising three main types of labrum lesions, and defined as: Classic Bankart lesion, when the labrum is avulsed and displaced laterally with complete periosteal detachment Figure 1. Perthes lesion when the labrum is avulsed with minimal displacement and intact periosteum (undisplaced labral lesion) Figure 2, and Anterior labrum periosteal sleeve avulsion (ALPSA) when the labrum is avulsed and markedly displaced medially on the anterior aspect of the glenoid neck (medialised labrum injury), with intact periosteum Figure 3.

Associated intra-articular lesions were also reported and included superior labrum anterior-posterior (SLAP) lesions, isolated capsulo-ligamentous laxity, glenoid and posterior-superior humeral head defects (Hill Sachs lesion).

Patients were divided into two age groups. Group 1: under 35 years old, included 152 patients, with a mean age of 26.3 for both male and female patients. Group 2: over 35 years old, included 49 patients, with a mean age 42.2 for male and 47.6 for female patients. The gender and age-related differences of arthroscopic findings between the two age groups and overall gender differences were evaluated. Continuous variables were reported as means and standard deviations and compared using 2-tailed t-tests. Categorical variables were reported as counts and percentages and compared using χ^2 tests. The significance level was set at $p < 0.05$

Our hypothesis was that Group 2 patients and female patients sustain different types of antero-inferior labrum lesions.

RESULTS

Demographics

98.5% of 201 dislocations were antero-inferior, with 79% male and 20.8% female patients. There was a significant difference of the mean age between Group 1 and Group 2 (26.2 vs 43.9 year old, $p < 0.001$) and between male and female patients in Group 2 (42.2 vs 47.6 year old, $p < 0.017$) respectively (Table 1).

Arthroscopic findings

Arthroscopy revealed, 94% of antero-inferior labrum injuries, 4% of isolated antero-inferior capsule-ligamentous laxity and 2% of isolated SLAP type 2 lesions.

Associated injuries included, 4.5% SLAP type 5 lesions, 26% glenoid bone loss (less than 15%) and 71.6% Hill Sachs lesions (Table 2).

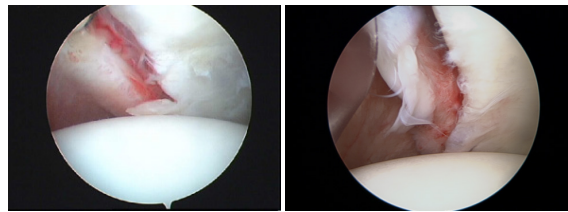


Figure 1 Classic Bankart lesion: Detached labrum with ruptured periosteum (Lateralised labrum lesion).

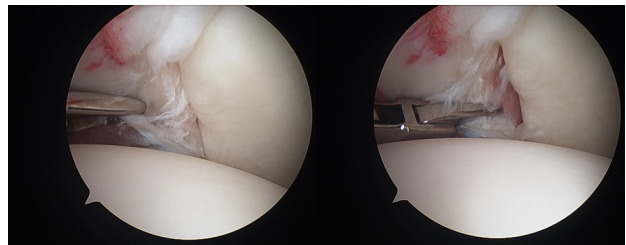


Figure 2 Perthes Lesion: Undisplaced labrum with intact periosteum (Undisplaced labrum lesion).

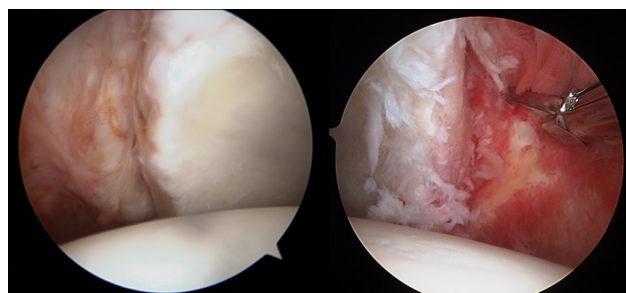


Figure 3 ALPSA lesion: Medially displaced labrum with intact periosteum (Medialised labrum lesion).

There was a significant difference noted in the incidence of large Hill Sachs lesions between ALPSA vs combined Bankart & Perthes lesions, (36% vs 10%, $p < 0.001$). However, no difference was seen between male and female patients (Table 3).

In Group 1, which is the typical young group of recurrent dislocations, the overall incidence of antero-inferior labrum injuries was 94.7%. Three distinct labral lesions were identified: Bankart lesions (33%), Perthes lesions (30.9%), and ALPSA lesions (30.9%) (Table 4).

Age-related differences in antero-inferior Labrum Lesions subtypes

We found a marked difference in the distribution of different subtypes of antero-inferior labrum lesions between the two age groups. Group 2 had significantly less combined Bankart /Perthes lesions (40.8% vs 63.8%, $p < 0.008$) and more ALPSA lesions (51% vs 31%, $p < 0.017$) than Group 1, respectively (Table 5).

Gender-related differences in antero-inferior Labrum and capsular lesions

Overall, female patients had significantly less antero-inferior labrum lesions (85.7% vs 96.2%, $p < 0.011$) and more capsule-ligamentous laxity (11.9% vs 1.8%, $p < 0.003$), than male patients respectively. Similar findings were noted for female patients in Group 1 (Table 6). When analysing the three subtypes of labrum injuries, female patients were found to have significantly less Bankart lesions than male patients (15.4% vs 36.5%, $p < 0.037$) (Table 7).

There were no significant incident rates differences between female and male patients in either large Hill Sachs defects or SLAP lesions.

Table 1 Demographics.

Dislocations	Number	%					
Total number	201						
Antero-inferior	198	98.50%					
Posterior	3	1.50%					
Males	159	79.10%					
Females	42	20.80%					
Age group	Patients	Mean age	Gender	Patients	%	Mean age	SD
Group 1	152	26.3	Male	126	82.90%	26.2	4.28
			Female	26	17.10%	26.5	5.12
Group 2	49	43.9	Male	33	67.30%	42.2	6.36
			Female	16	32.60%	47.6	8.63
P-value		0.0001*				0.0174*	

* significant two tailed p-value <0.05

Table 2 Arthroscopic findings: labrum lesions, capsular lesions and bony defects.

Arthroscopic findings	Patients	%
Total cases	201	
Antero-inferior labrum lesions:	189	94%
Classic Bankart lesion (detached labrum lesion)	60	30%
Perthes lesion (undisplaced labrum lesion)	57	28%
ALPSA lesion (medialised labrum lesion)	72	36%
Superior labrum lesions (SLAP):	13	6.50%
SLAP type 2 (without inferior labrum lesion)	4	2%
SLAP type 5 (with inferior labrum lesion)	9	4.50%
Isolated Capsuloligamentous laxity (without labrum lesion)	8	4%
Associated Bone lesions		
All Hill Sachs lesions	144	71.60%
Large Hill Sachs lesions	38	19%
Glenoid bone loss < 15%	52	25.80%

Table 3 Large Hill Sachs lesions according to Gender and Labrum lesions.

	Bankart & Perthes	ALPSA	Males	Females
	117	72	159	42
Large Hill Sachs	38	12	32	6
%	19%	10%	36%	20%
P-value			0.001*	0.376

Significant chi squared p-value < 0.05.

Table 4 Labrum lesions and subtypes variation (Bankart, Perthes and ALPSA lesions) in each age group.

Age group	Patients	Anterior labrum lesions		Bankart lesion		Perthes lesion		ALPSA lesion	
Group1	152	144	94.70%	50	33%	47	30.90%	47	30.90%
Group2	49	45	91.80%	10	20.40%	10	20.40%	25	51%

Table 5 Age related differences in antero-inferior Labrum Lesions subtypes.

Age group	Patients	Mean age	anterior labrum lesions	%	Bankart & Perthes lesions	%	ALPSA Lesion	%
Group 1	152	26.26	144	94.70%	97	63.80%	47	31%
Group 2	49	43.94	45	91.80%	20	40.80%	25	51%
P-value		0.0001 **		0.459		0.0084*		0.0178*

* significant chi squared p-value <0.05. ** significant two tailed p-value <0.05

Table 6 Gender related differences in the overall antero-inferior Labrum lesions and capsular lesions.

	Gender	Patients	Antero-inferior labrum lesions			Isolated Capsular laxity		
			Patients	%	p-value	Patients	%	p-value
All patients	Male	159	153	96.20%		3	1.88%	
	Female	42	36	85.70%	0.011 *	5	11.90%	0.0032 *
Group 1	Male	126	122	96.80%		3	2.38%	
Mean age 26	Female	26	22	84.60%	0.011 *	3	11.50%	0.0301 *

Significant chi squared p-value <0.05

Table 7 Gender related differences of antero-inferior labrum lesion subtypes.

Group1	Patients	Bankart lesion	%	Perthes lesion	%	ALPSA lesion	%
Male	126	46	36.50%	37	29.36%	39	30.80%
Female	26	4	15.38%	10	38.46%	8	30.70%
p-value			0.0375*		0.362		0.992

* Significant chi squared p-value <0.05.

DISCUSSION

Bankart first described the detachment of the antero-inferior capsule-labrum complex from the glenoid as the “essential lesion” in recurrent shoulder dislocation and reported the surgical technique for an anatomical repair^[14,15]. In his elegant study Bankart was describing the loss of tension of the inferior gleno-humeral ligament^[16]. Over the last two decades, three Bankart subtypes have been recognised as separate lesions, both in clinical studies^[10-13] and in Magnetic resonance arthrographic (MRA) studies^[3,4,9].

In the classic Bankart lesion, the labrum is displaced and detached with rupture of the glenoid periosteum. Perthes lesion is an undisplaced labral tear with an intact periosteum (undisplaced Bankart variant). The labrum is flattened and the small labral tear may be only seen when probed. The ALPSA lesion is a medialised labrum tear (medialised Bankart variant). However, unlike the classic Bankart lesion, the anterior scapular periosteum does not rupture. The labrum and capsule-ligamentous complex, together with the periosteum, are stripped and displaced medially on the glenoid neck in a sleeve-like manner. Neviasser was the first to recognise and report the surgical importance of the ALPSA lesion, insisting on correctly mobilising and reattaching the labro-ligamentous complex on the glenoid. He described both acute ALPSA and chronic ALPSA lesions, which heal medially on the scapular neck^[17].

In Group 1, which is the typical young group of recurrent dislocations, the incidence of antero-inferior labrum lesions was 94.7%, comparable to reported rates of 89.6% to 99%^[11,13,18]. It is noteworthy that the classic Bankart lesion was present in only 33% of the cases. Three different subtypes of antero-inferior labrum lesions were found with an incidence of 63.9% for combined Bankart & Perthes lesions, and 30.9% for ALPSA lesions. These results are comparable to previous reports of 55% to 76% for combined Bankart & Perthes lesions and of 23% to 34.7% for ALPSA lesions^[11,13,19]. There has been a controversy over the pathogenesis of the ALPSA lesion. Some authors have considered that this lesion develops as a result of multiple recurrent dislocations^[20]. However, more recent studies have confirmed the findings of Neviasser *et al.* (1993) and reported the presence of ALPSA lesions in first time dislocations with an incidence of 12% to 30%^[11,12,19,21]. The three subtypes of antero-inferior labrum lesions seen in our study are similar to the type of lesions reported in first time dislocations^[11,12,19,21]. Therefore, we believe that they clearly represent very distinct labral lesions and their occurrence is dictated by the mechanism of injury and degree of force applied to the capsule-ligamentous complex at the time of the initial dislocation. This study has showed that ALPSA lesions were associated with significantly higher incidence of Hill Sachs bone defects of the engaging type than Bankart and Perthes lesions (36% vs 10%, $p < 0.001$), confirming the results of previous studies^[13]. This fact confirms that the ALPSA lesion is the result of a significantly greater initial impact force and could explain the more extensive soft tissue damage that we observe with this lesion. Injury to the superior labrum (SLAP) was found in 13 cases (6.5%). Previous studies have reported rates of 6% to 26%^[12,13,18,21,22].

In the present study, the overall incidence of shoulder dislocation in female patients was 20.8%, comparable to published results^[23]. It is interesting to note that previously reported sport-specific incident rates of shoulder instability between female and male athletes were not significantly different. The mechanism of injury was different. Female athletes were more likely to sustain an instability event as a result of contact with an object, and male athletes from contact with a player^[24].

In this study, we have shown the gender and age-related differences in the pattern of antero-inferior labral injuries. In Group 2, patients with recurrent dislocations presented with less Bankart & Perthes lesions and significantly greater incidence of ALPSA lesions. This denotes a different mechanism of injury with greater forces applied to the joint. In this group the mean age of females was significantly higher than the males (47.6 vs 42.2, $p < 0.017$). Another important finding of this study was the marked gender-related difference of soft tissue injuries observed. Female patients had a very different pattern of capsule-labrum injuries with significantly more isolated capsular injuries and less Bankart lesions than male patients. Comparable findings have been reported in a recent multi-centre study^[23]. Noticeably, there were no significant incident rate differences between female and male patients in either large Hill Sachs defects or SLAP lesions.

CONCLUSION

The study has confirmed our hypothesis and showed significant gender and age -related differences of antero-inferior capsule-labral injuries in chronic shoulder instability. Overall, female patients had significantly less antero-inferior labrum lesions and more capsule-ligamentous laxity than male patients. When analysing the subtypes of labrum injuries, female patients were found to have significantly less Bankart lesions than male patients. We found a marked difference in the distribution of different subtypes of antero-inferior labrum lesions between the two age groups. Group 2 had significantly less combined Bankart /Perthes lesions and more ALPSA lesions than Group 1.

We believe that increased awareness of the different pattern of injuries in female and older patients will be helpful in pre-operative planning and the implementation of the appropriate surgical management.

REFERENCES

- Enger M, Skjaker SA, Melhuus K, Nordsletten L, Pripp AH, Moosmayer S, Brox JI. Shoulder injuries from birth to old age: A 1-year prospective study of 3031 shoulder injuries in an urban population. *Injury*. 2018 Jul; **49(7)**: 1324-1329, [PMID: 29861311]; [DOI: 10.1016/j.injury.2018.05.013]
- Kardouni JR, Mckinnon CJ, Seitz AL. Incidence of Shoulder Dislocations and the Rate of Recurrent Instability in soldiers. *Med Sci Sports Exerc* 2016 Nov; **48(11)**: 2150-2156. [PMID: 27327025]; [DOI: 10.1249/MSS.0000000000001011]
- Iossifidis A, Ibrahim E, Mitra P, Petrou C. Accuracy of magnetic resonance arthrography in the detection and classification of chronic antero-inferior labrum lesions. *Int. J. of Orth.* 2020 October 28; **7(5)**: 1366-1369. [DOI: 10.17554/j.issn.2311-5106.2020.07.3003]
- De Coninck T, Ngai S, Tafur M, Chung B. Imaging the Glenoid Labrum and Labral Tears. *Radiographics*. 2016 Oct; **36(6)**: 1628-1647. [PMID: 27726737]; [DOI: 10.1148/rg.2016160020]
- Pouliart N, Doering S, Shahabpor M. What can the Radiologist do to Help the Surgeon Manage Shoulder Instability. *Belg Soc Radiol*. 2016 Nov 19; **100(1)**: 105. [PMID: 30151496]; [PMCID: PMC6100640]; [DOI: 10.5334/jbr-btr.1227]
- Smith TO, Drew BT, Toms AP. A meta-analysis of the diagnostic test accuracy of MRA and MRI for the detection of glenoid labral injury. *Arch Orthop Trauma Surg*. 2012, Jul; **132(7)**: 905-9. [PMID: 22395821]; [DOI: 10.1007/s00402-012-1493-8]
- Waldt S, Burkart A, Imhoff AB, Bruegel M, Rummeny EJ, Woertler K. Anterior shoulder instability: accuracy of MR arthrography in the classification of antero-inferior labroligamentous injuries. *Radiology*. 2005; **237(2)**: 578-583. [PMID: 16244267]; [DOI: 10.1148/radiol.2372041429]

8. Sanders TG, Miller MD. A systematic approach to magnetic resonance imaging interpretation of sports medicine injuries of the shoulder. *Am J Sports Med.* 2005; **33**(7): 1088-105. [PMID: 15983127]; [DOI: 10.1177/0363546505278255]
9. Saba L, De Filippo M. MR arthrography evaluation in patients with traumatic anterior shoulder instability. *Journal of Orthopaedics.* 2017; **14**: 73-76. [PMID: 27829728]; [PMCID: PMC5094292]; [DOI: 10.1016/j.jor.2016.10.017]
10. Tischer T, Vogt S, Kreuz PC, et al. Arthroscopic anatomy, variants, and pathologic findings in shoulder instability. *Arthroscopy.* 2011; **27**: 1434-1443. [PMID: 21871774.]; [DOI: 10.1016/j.arthro.2011.05.017]
11. Spatschil A, Landsiedl F, Anderl W, Imhoff A, Seiler H, Vassilev I, Klein W, Boszotta H, Hoffmann F, Rupp S. Posttraumatic anterior-inferior instability of the shoulder: arthroscopic findings and clinical correlations. *Arch Orthop Trauma Surg.* 2006; **126**: 217-222. [PMID: 16217670]; [DOI: 10.1007/s00402-005-0006-4]
12. Antonio GE, Griffith JF, Yu AB, Yung PS, Chan KM, Ahuja AT. First-time shoulder dislocation: high prevalence of labral injury and age-related differences revealed by MR arthrography. *J Magn Reson Imaging.* 2007; **26**: 983-991. [PMID: 17896393]; [DOI: 10.1002/jmri.21092]
13. Lee BG, Cho NS, Rhee YG: Anterior labroligamentous periosteal sleeve avulsion lesion in arthroscopic capsulolabral repair for anterior shoulder instability. *Knee Surg Sports Traumatol Arthrosc.* 2011; **19**: 1563-1569. [PMID: 21607741]; [DOI: 10.1007/s00167-011-1531-z]
14. Bankart ASB. Recurrent or habitual dislocation of the shoulder-joint. *Br Med J.* 1923; **II**: 1132-3. [PMID: 20771383PMCID: PMC2317614]; [DOI: 10.1136/bmj.2.3285.1132]
15. Bankart ASB. The pathology and treatment of recurrent dislocation of the shoulder joint. *Br J Surg* 1938; **26**(26): 23-9. [DOI: 10.1002/bjs.18002610104]
16. Levine WN, Flatow EL. The pathophysiology of shoulder instability. *Am J Sports Med* 2000; **28**(6): 910-7. [PMID: 11101119]; [DOI: 10.1177/03635465000280062501]
17. Neviasser TJ. The anterior labroligamentous periosteal sleeve avulsion lesion: a cause of anterior instability of the shoulder. *Arthroscopy* 1993; **9**(1): 17-21. [PMID: 8442824]; [DOI: 10.1016/s0749-8063(05)80338-x]
18. Rugg CM, Hettrich CM, Ortiz S, Wolf B, MOON instability Group, Zhang AL. Surgical stabilisation for first time shoulder dislocators: a multicenter analysis. *J Shoulder Elbow Surg.* 2018 Apr; **27**(4): 674-685. [PMID: 29321108]; [DOI: 10.1016/j.jse.2017.10.041]
19. Shin S-J, Ko YW, Lee J. Intra-articular lesions and their relation to arthroscopic stabilisation failure in young patients with first-time and recurrent shoulder dislocations. *J Shoulder Elbow Surg.* 2016; **25**: 1756-1763. [PMID: 27260995]; [DOI: 10.1016/j.jse.2016.03.002]
20. Habermeyer P, Gleyze P, Rickert M (1999) Evolution of lesions of the labrum-ligament complex in posttraumatic anterior shoulder instability: a prospective study. *J Shoulder Elbow Surg.* **8**: 66-74. [PMID: 10077800]; [DOI: 10.1016/s1058-2746(99)90058-7]
21. Kim DS, Yoon YS, Yi CH. Prevalence comparison of accompanying lesions between primary and recurrent anterior dislocation in the shoulder. *Am J Sports Med.* 2010; **38**: 2071-2076. [PMID: 20709942]; [DOI: 10.1177/0363546510371607]
22. Snyder SJ, Banas MP, Karzel RP. An analysis of 140 injuries to the superior glenoid labrum. *J Shoulder Elbow Surg.* 1995; **4**(4): 243-248. [PMID: 8542365]; [DOI: 10.1016/s1058-2746(05)80015-1]
23. Magnuson JA, Wolf BR, Cronin KJ, Jacobs CA, Ortiz SF, Bishop JY, Baumgarten KM; MOON Shoulder Group, Hettrich CM. Sex related differences in patients undergoing surgery for shoulder instability: a Multicenter Orthopaedic Outcomes Network (MOON) Shoulder Instability cohort study. *J Shoulder Elbow Surg.* 2019 Jun; **28**(6): 1013-1021. [PMID: 31003889]; [DOI: 10.1016/j.jse.2019.02.020]
24. Owens BD, Agel J, Mountcastle SB, Cameron KL, Nelson BJ. Incidence of glenohumeral instability in collegiate athletics. *Am J Sports Med.* 2009; **37**: 1750-4. [PMID: 19556471]; [DOI: 10.1177/0363546509334591]