

## Multilevel Lumbar En-bloc Vertebrectomy for Chordoma

Jark J.D. Bosma<sup>1</sup>, M.D

1 One Health group, 131 Psalter Lane, Sheffield, S11 8UX, United Kingdom

**Conflict-of-interest statement:** The author(s) declare(s) that there is no conflict of interest regarding the publication of this paper.

**Open-Access:** This article is an open-access article which was selected by an in-house editor and fully peer-reviewed by external reviewers. It is distributed in accordance with the Creative Commons Attribution Non Commercial (CC BY-NC 4.0) license, which permits others to distribute, remix, adapt, build upon this work non-commercially, and license their derivative works on different terms, provided the original work is properly cited and the use is non-commercial. See: <http://creativecommons.org/licenses/by-nc/4.0/>

**Correspondence to:** Jark J.D. Bosma, One Health group, 131 Psalter Lane, Sheffield, S11 8UX, United Kingdom.  
Email: [jark.bosma@onehealth.co.uk](mailto:jark.bosma@onehealth.co.uk); [jark.bosma@gmail.com](mailto:jark.bosma@gmail.com)  
Telephone: + 44 114 250 5510

Received: July 5, 2021

Revised: September 20, 2021

Accepted: September 24 2021

Published online: October 28, 2021

### ABSTRACT

**OBJECTIVE:** To demonstrate that total en bloc removal of chordoma involving multiple vertebrae of the lumbar spine is achievable, using a technique previously described for single level tumors. It is a technically demanding procedure which requires careful planning. We also show that femoral or tibial allograft provides a strong and cheaper alternative to modern cages and should be considered for anterior reconstruction in these cases.

**METHODS:** We describe in detail the technique used in a patient who presented with a lumbar chordoma extending over three vertebral bodies, L3 to L5, which in addition had expanded bilaterally into the paravertebral region. The initial reconstruction failed as the intervertebral cage dislocated. We revised this with tibial allograft and obtained a solid construct this way.

**RESULTS:** Complete en bloc excision and stable reconstruction was ultimately achieved despite the difficulties we encountered. At

five years the patient remained disease free.

**CONCLUSIONS:** En bloc resection of chordoma involving multiple lumbar vertebrae is feasible. The technique described may be used for other tumors involving the lumbar spine, perhaps even in cases where more than three levels are involved. Tibial or femoral allograft provides a better and cheaper alternative to cages and can be useful when resources are scarce.

**Key words:** Chordoma; En bloc resection; Multilevel vertebrectomy; Spondylectomy; Corpectomy

© 2021 The Author(s). Published by ACT Publishing Group Ltd. All rights reserved.

Bosma JJD. Multilevel Lumbar En-bloc Vertebrectomy for Chordoma. *International Journal of Orthopaedics* 2021; 8(5): 1558-1564 Available from: URL: <http://www.ghrnet.org/index.php/ijo/article/view/3217>

### INTRODUCTION

Chordoma is a rare primary tumor of the spine. Patients often present when the tumor spreads beyond the vertebral margins and removal is a major surgical challenge. En bloc removal offers the best chance of long-term survival.

In our case, the chordoma extended over three vertebral bodies and had spread beyond the margins of the vertebral walls. A year earlier, following posterior decompression, biopsy and stabilisation, it was diagnosed as Renal Cell Carcinoma and treated with radiotherapy.

We describe how we achieved en bloc removal of this tumor and reconstruction of the spine in a two-stage anterior-posterior procedure, applying the principles and surgical approach, previously described for chordoma confined to a single lumbar vertebral body<sup>[1]</sup>.

### CASE REPORT

#### Presentation

A 55-year old man was referred for treatment of a lumbar chordoma.

One year earlier, he was treated elsewhere for Cauda Equina Syndrome. A large tumor arising from the lower lumbar vertebrae was found on imaging. He underwent a laminectomy, biopsy and stabilisation L2 to L5 (Figure 1).

A histological diagnosis of Renal Cell Carcinoma was made. It was treated with radiotherapy.

The following year, the patient got worsening back pain, abdominal pain and bilateral leg pain; he became wheelchair bound. Neurologically, he remained intact. Further MRI showed no significant change, and the histology was revised to chordoma.

His analgesic regime included gabapentin 800 mg/day, amitriptyline 50 mg/day, morphine 400 mg/day, Ibuprofen 1200 mg/day, paracetamol 2 g/day, and top-up oramorph and ketamine.

He had a past history of assault when he was stabbed in the abdomen requiring surgery. He suffered erectile dysfunction ever since.

**Examination:** Because of severe pain, the patient had difficulty mobilizing. Neurologically he was intact. There was no root tension.

**Investigations**

MRI showed tumor occupying a large part of L3, most of the vertebral body of L4 with right paravertebral extension, and extension in the upper central posterior part of the vertebral body of L5. The pedicle screws in L5 were laterally placed, clear from the tumor (Figure 2).

**Treatment**

We proceeded with en bloc vertebrectomy involving L3, L4, and L5 in

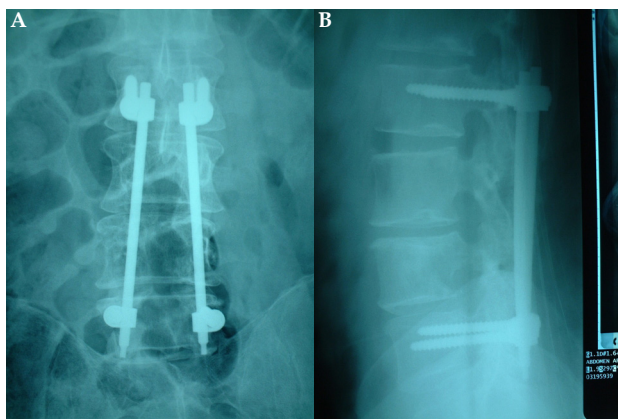


Figure 1 AP (A) and lateral (B) X-rays of the lumbar spine.

a two-stage procedure. We chose reconstruction with a custom made expandable cage (Obelisc, Ulrich, Germany). The specifications of the cage were discussed with the company prior to surgery.

**Surgery**

**First stage – posterior procedure:** The previous lumbar wound was reopened (midline incision) The posterior elements were exposed from D12 to S3. There was dense scarring. Swabs and large cottonoids were used to line the wound and ‘protect’ all the normal tissue. The existing pedicle screw system was removed and the screw holes in L5 immediately plugged with bone wax. New pedicle screws (Crypton, Ulrich, Germany) were (re-)inserted in L1, L2, S1 and S2 (Alar) under fluoroscopy screening. Dissection was carried out to expose the pedicles of L3, 4 and 5; these were cut with an osteotome and the posterior elements were removed (Figure 3). The nerve roots were protected with a MacDonald dissector.

Under microscopic vision, the theca was dissected free from the vertebrae; there were no adhesences. The epidural veins were coagulated with bipolar diathermy. The posterior wall of the vertebral

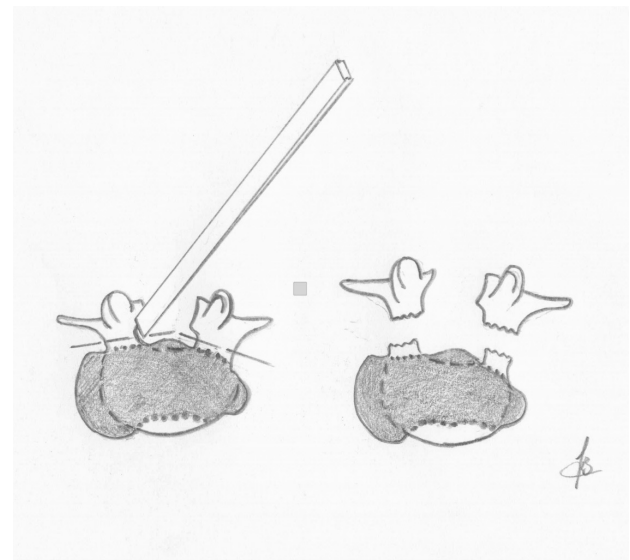


Figure 3 Drawing which shows how the pedicles were cut with an osteotome to remove the posterior elements.

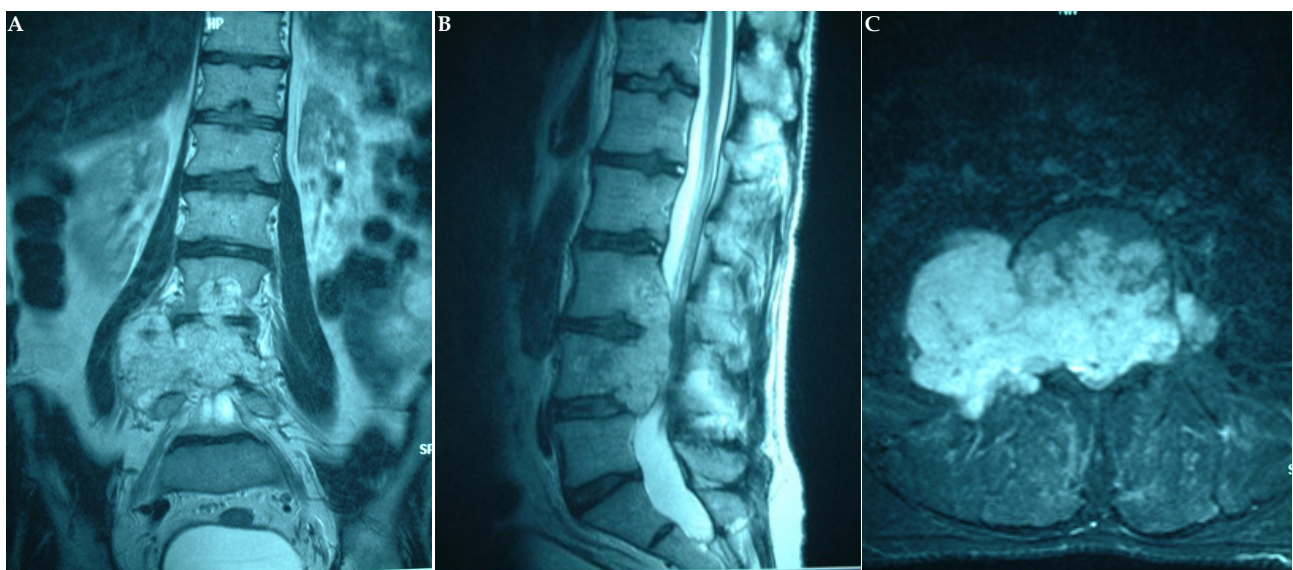


Figure 2 MRI. T2 weighted coronal image (A) showing multilevel involvement, T2 weighted sagittal MRI (B) which shows extension of the chordoma into the upper posterior edge of L5, and axial STIR sequence (C) which shows the tumor extending into the paravertebral regions.

column was carefully inspected. Where the tumor bulge was seen, it had a very smooth capsule surface. The annulus of the L2/3 and L5/S1 disc were incised and the discs were partly removed. A silastic sheath was placed between the theca and the vertebral column. The posterior construct was completed with rods and a cross connector. The procedure had taken 18 hours, much longer than anticipated because of the scarring. Blood loss was 8 units. The patient was taken to Intensive Care and kept ventilated before the second stage the following day.

**Surgery**

**Second stage – Anterior procedure:** Through a transperitoneal approach, the column was exposed. This was difficult because of peritoneal adhesions. Blood loss was very significant. High bifurcation of the aorta and vena cava was noted (Figure 7).

The lateral extent of the tumor was determined. On the right side there was a significant bulge of the tumor displacing the psoas muscle laterally, exactly as expected from the MRI. There was a clear plane of dissection; the mass separated easily from the muscle without breaching the tumor. On the left side this was the same, but the extending mass was very small. Large cottonoids were placed between the tumor and the paravertebral tissues laterally. The vessels were retracted and protected with vascular slings. Then the remainder of the discs L2/3 and L5/S1 were removed. This resulted in a significant “wobbliness” of the spine which was only supported by the pedicle screw system. The bloc was still not entirely free and careful dissection was needed to mobilise it.

Whilst retracting the Iliac vessels, the bulk of the lower part of the specimen could not pass safely between the large vessels superiorly. Inferiorly, there was just enough space to bring the specimen into the pelvis and leave it out. This created a very large column defect of approximately 17 cm.

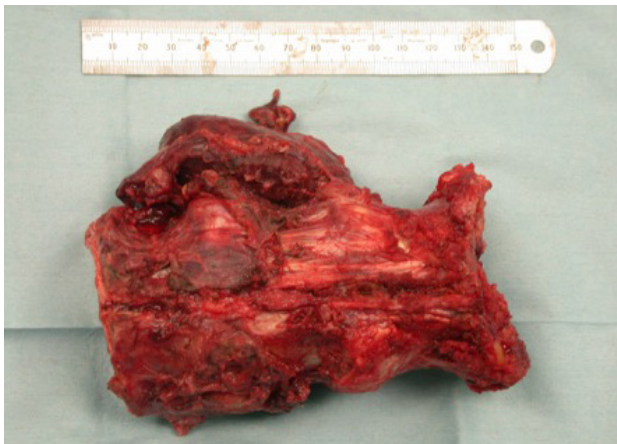Unfortunately, we found dural tears over both L5 nerve roots laterally (extraforaminal). These were covered with cottonoids. We released the retractors temporarily to allow the tissues to recover and meticulous haemostasis was carried out.

Time was taken to inspect the operative field, and the specimen; no breach of tumor was identified. En bloc removal was achieved (Figure 4). This was subsequently confirmed with detailed histological microscopic examination.

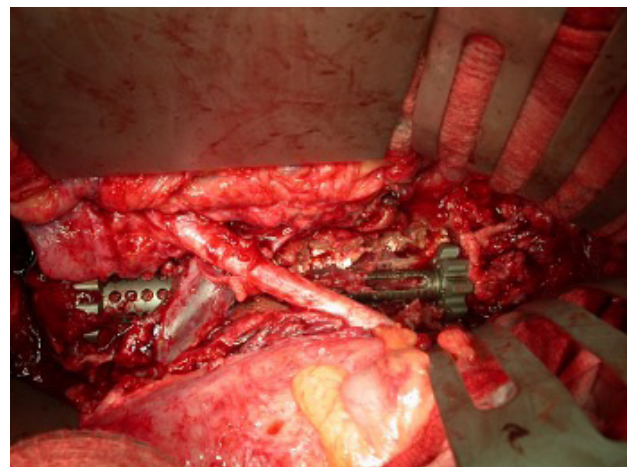
The dural tears were repaired with a surgicel and Tisseel patch.

The custom-made cage was filled with synthetic graft. Because of the high origin of the iliac vessels with the awkward crossing of the right iliac artery and left Iliac vein over the defect, the cage could not just be put into the defect and expanded. The vessels had to be negotiated without causing vascular injury (removing the specimen was somehow easier). We managed this by retracting the right iliac artery to the left, minimally retracting the more vulnerable left Iliac vein to the right, and -different to the removal of the specimen- inserting the cage from the cranial end of the defect. The cage could then be expanded to fit snugly.

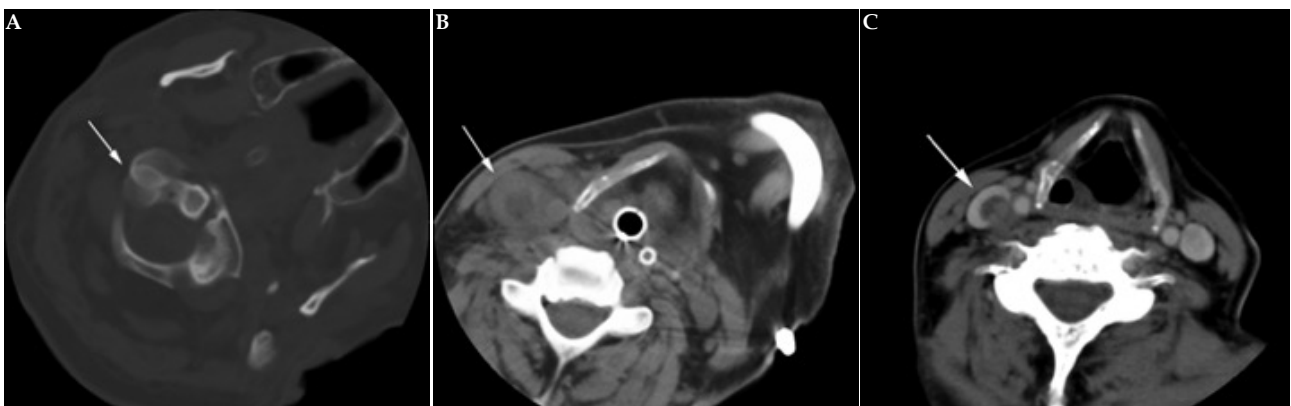
Further synthetic graft was packed around the cage. Following haemostasis, the wound was closed in layers. This procedure took 18 hours and was associated with a very high blood loss: 29 units.



**Figure 4** The surgical specimen, frontal view, the caudal end on the left side of the picture. Note the paravertebral extension, bulky on the right side of L4 and L5, and a sliver on the left at the same levels. Also note the size of the specimen (15 cm long).



**Figure 6** Anterior construct, cage dislodged. Clearly visible is how the cage has slipped anteriorly over S1 (left side of the picture).



**Figure 5** CT demonstrating rotatory subluxation (A) and internal jugular vein thrombosis (arrow) on pre-contrast (B) and post contrast (C) axial images.



**Postoperative course**

The patient was kept in intensive care for several days mainly for monitoring of his fluid balance and metabolic status after the significant blood loss and transfusions. He had postoperative ileus and also developed a Torticollis whilst intubated. The latter was triggered by internal jugular vein thrombosis as shown on CT (Figure 5), similar to Grisel Syndrome. This was treated conservatively and spontaneously resolved within a few days.

After extubation it was apparent he had vocal cord palsy, but this gradually resolved.

The nature of his pain was completely different. However, he did have a bilateral foot drop, probably because of the traction on the nerve roots when the specimen was removed.

Early after mobilization he developed some difficulty with abdominal pain. X-rays showed that the cage had dislocated, the caudal end having slipped forward over S1. We decided to remove the cage and replace it with a large allograft (cadaveric tibia) instead and use buttress screws (AO) to hold it in place.

**Revision Procedure**

The abdominal wound was reopened. Exposure this time was much easier (the procedure took 8 hours and 15 min, the blood loss was 6 units). The cage was dislocated as seen on X-rays (Figure 6). The cage height was reduced before it was lifted out downwards recreating the defect (Figure 7). The synthetic graft in and around it was removed. The tibial graft was then cut to size. Placing it proved difficult as it was bulkier than the cage: the wider end was meant to sit on the sacrum and could not be placed directly into the defect from the cranial end. The crossing iliac vein and artery were gently lifted upwards, away from the defect, just like they were lifted by the dislocated cage, and this way we could place the wide caudal end of the graft onto the sacrum, slightly countersink it and, with application of some traction, jam it and countersink it cranially. Four bicortical AO screws were placed with washers as a buttress, two obliquely upwards into the L2 vertebral body, and two obliquely downwards into the sacrum (Figure 8). Following haemostasis the wound was again closed in layers.

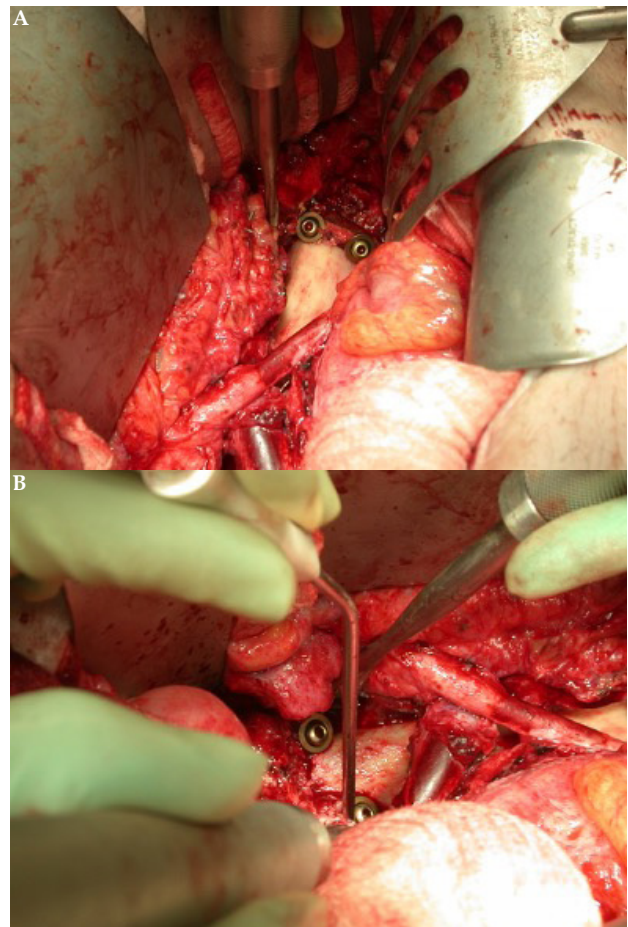
Postoperatively, the patient required only a short stay in intensive care. Postoperative X-rays showed satisfactory positioning of the construct (Figure 9).

**Postoperative course**

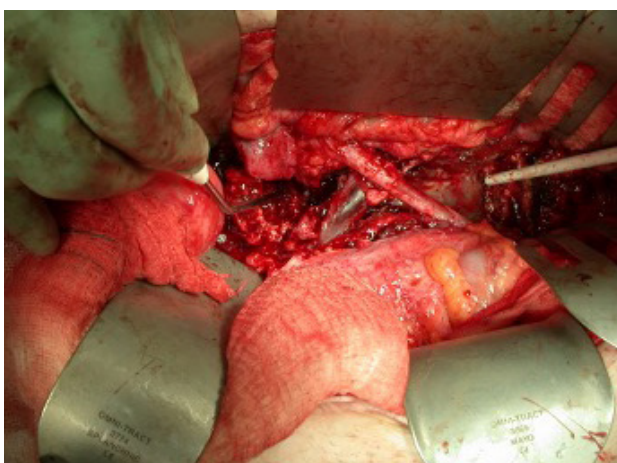
The patient gradually improved and started walking again but

required bilateral ankle foot orthoses initially. The original pain slowly resolved and over time the analgesic requirement was drastically reduced. By 1 year he was only taking tramadol, paracetamol and co-codamol as and when required, and he was ambulant but using crutches. Postoperative X-rays showed good positioning of the graft and fixation.

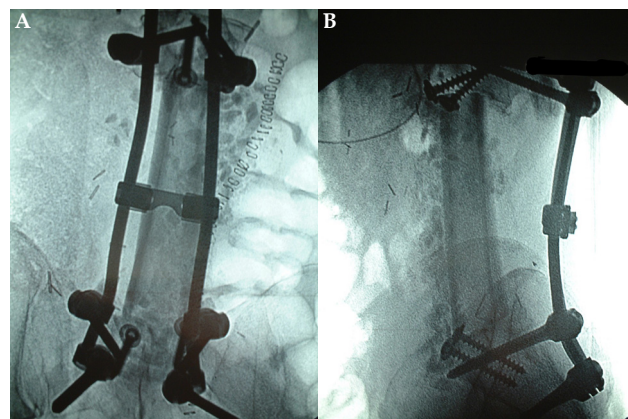
Although he required TA lengthening, at 40 months he had bilaterally mild weakness of ankle dorsiflexion (4/5) only and was walking without aid. There was some numbness over the dorsum of both feet and he was only taking paracetamol for back ache occasionally.



**Figure 8** Cranial end (A) and caudal (B) ends of the tibial graft construct in situ. Note the buttress screws.



**Figure 7** Surgical field after removal of the dislodged cage; note the high bifurcation and origin of the Iliac vessels. The white sucker points at the dura at the cranial end of the resection field.



**Figure 9** Postoperative AP (A) and lateral (B) X-rays of the lumbar spine showing satisfactory position of the graft and instrumentation. Note S2 alar screws.

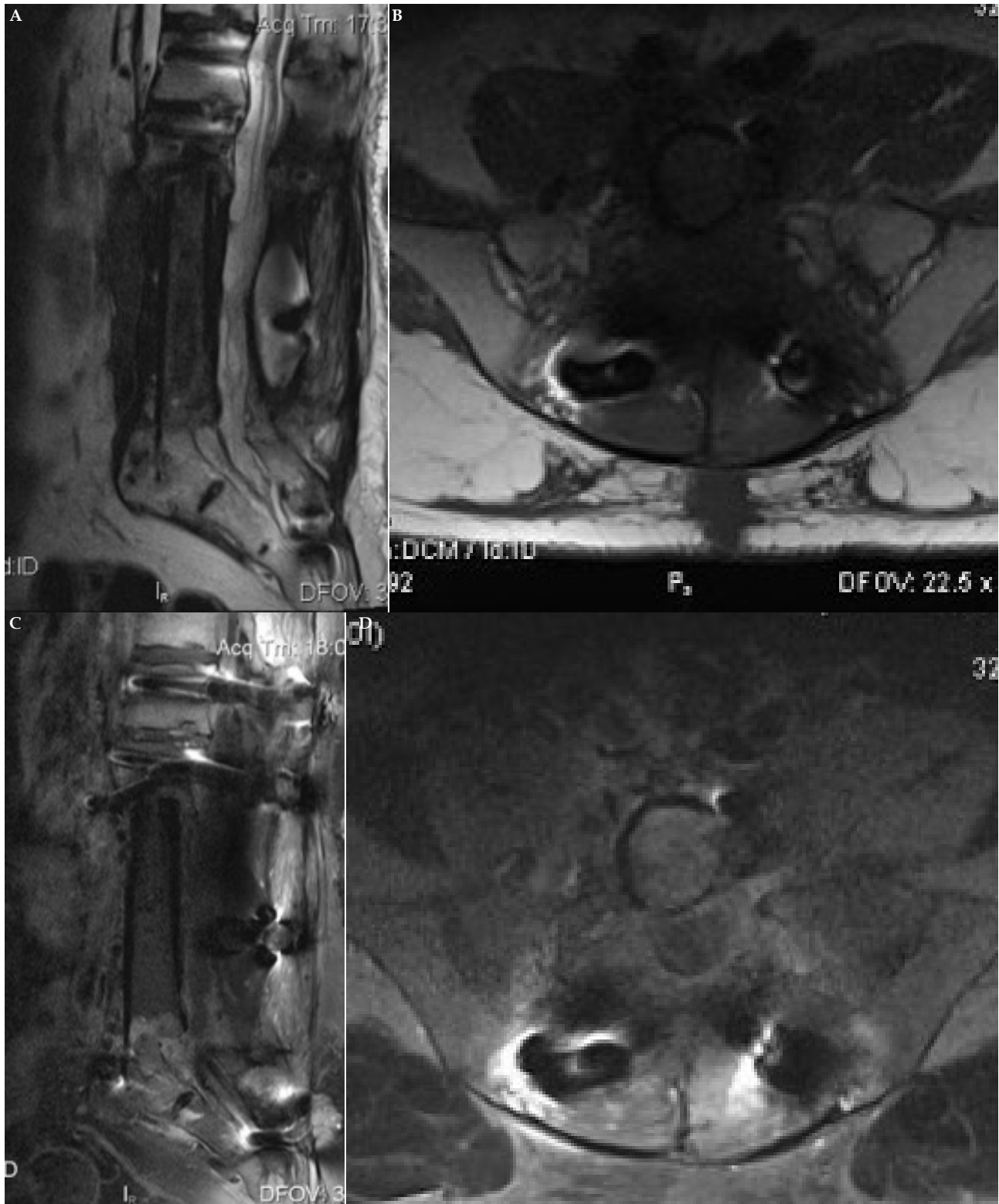
At 5 years follow up the MRI showed no evidence of recurrence, and bone growth at the cranial and caudal ends of the graft with no failure of the construct (Figure 10).

## DISCUSSION

Chordomas of the lumbar spine are very rare. Nevertheless, with myeloma they are the commonest primary malignant tumors of the

spine.<sup>2</sup> Most appear to involve a single vertebra<sup>1,3-8</sup>. Older literature suggests it often involves multiple vertebrae. It is a unique feature of chordomas to grow through the discs, whereas cancers involving the spine are “stopped” by the disc<sup>9</sup>. Hence, one would expect to see multilevel involvement in cases of chordoma more often. The difference is probably due to earlier diagnosis with newer imaging techniques, especially MRI.

A chordoma which involves three vertebrae presents a huge



**Figure 10** MRI at 5 years follow up, T2 Sagittal (A) and T1 axial (B) pre-Gadolinium images and T1 sagittal (C) and axial (D) post-Gadolinium images showing no evidence of recurrence and bone ingrowth at the cranial and caudal ends.

surgical challenge. A similar case was reported elsewhere, but in that particular case en bloc resection was impossible<sup>[10]</sup>. We achieved en bloc resection successfully, using a previously described surgical technique<sup>[1]</sup>. Despite the enormous defect that was created, and the difficulties we encountered, a stable construct was created. Moreover, the patient's pain improved significantly after surgery and he remained disease free in the medium term. We felt that the benefit of surgery outweighed the complications that had occurred.

Because this tumor is so rare, it is uncertain what the best treatment is for these. In principal they are malignant tumors and they can metastasise<sup>[5,9,11,12]</sup>. But, they are slow growing, and there is an argument for conservative management<sup>[7]</sup>. However, those tumors that arise from true vertebrae tend to be more aggressive<sup>[13]</sup>. Therefore, few will argue against intervention once they become symptomatic. In our case, intense pain had become a problem. This appears to be so in most cases that are described in the literature<sup>[14]</sup>. Neurological symptoms are quite rare and may take a very long time before they develop<sup>[9,12,15]</sup>. Local spread may therefore have occurred before the diagnosis is made<sup>[14]</sup>. In our case the tumor had expanded beyond the vertebral margins, but was contained by a firm capsule. Such capsule formation is found when the chordoma is not too far advanced<sup>[11]</sup>. Rarely, the patient presents with an acute Cauda Equina Syndrome, as ours did in the initial presentation<sup>[8,9,13,14]</sup>. In such cases emergency decompression and stabilization remains the aim of the acute treatment.

In elective cases the main goal of treatment is tumor control and stabilization of the spine. Local control is achievable, but any spillage of tumor intraoperatively appears to be associated with early local recurrence and more aggressive behaviour of the tumor<sup>[12,13]</sup>. In addition, they tend to then metastasise, whereas long term control and survival can be achieved when extralesional surgery is carried out, no spillage of tumor has occurred, and the tumor was removed in toto<sup>[1,13,16]</sup>. In the largest study to date, the group from The AOSpine Knowledge Forum Tumor database demonstrated that Enneking Appropriate resection is associated with a significant reduction in the risk of local recurrence when compared to Enneking Inappropriate resection. This supports the view that a wide resection is important. Whilst the multivariate analysis of this cohort did not corroborate the longer median survival that was seen with the univariate analysis, it should be noted that the median follow up was only 2.6 years<sup>[17]</sup>.

The challenge in our case was precisely to not breach the tumor margins as it had expanded beyond the vertebral walls. Wide excision with a margin of normal tissue was not realistic, but a dissection plane was easily identified, and the capsule was not breached. Given the 5 year survival without evidence of recurrence, this may be sufficient.

Different stabilization techniques and grafts have been used in the past, including iliac strut graft, cages, combination with posterolateral fusion and telescopic bolts with methylmethacrylate<sup>[1,10,18-20]</sup>. Because of our previous experience with expandable cages, we felt quite confident after talking to the manufacturer that a large expandable cage with synthetic graft would work well in combination with a solid posterior construct. We were proven wrong as the inferior surface of the cage was difficult to fit on the slope of the sacrum and indeed the cage slipped as the patient was mobilized. Having created a solid construct with a cadaveric graft supported with buttress screws, we recommend using this instead, especially in cases involving more than one level.

Posterior stabilization in addition is required and should extend at least two segments above and two segments below the anterior construct<sup>[21]</sup>.

The role of adjuvant or preoperative radiotherapy is not fully established. Chordomas are radio-resistant, but it is beneficial when there has been spillage or incomplete removal of the tumor and increases the 5-year survival up to 62%<sup>[2,16,22]</sup>. Proton-beam radiotherapy may offer better results; local control rates and 5-year survival rates are better when compared with conventional radiotherapy<sup>[23,24]</sup>. Postoperative radiotherapy is however associated with an increased risk of instrumentation failure<sup>[25]</sup>. Chemotherapy has as yet no role to play<sup>[16]</sup>. In cases where surgical extirpation is not an option, vertebroplasty can be considered for pain relief<sup>[5]</sup>.

## CONCLUSION

En bloc vertebrectomy for tumors involving multiple vertebrae is feasible in selected cases. In our opinion the best graft for anterior reconstruction is provided by cadaveric long bone (femur or tibia), which in itself is strong enough to carry body weight. The graft should be secured to prevent it dislodging.

Allograft is also cheaper than 'hardware', an important consideration when resources are scarce.

The technique described may be used in the future for similar tumors maybe even those involving more than three vertebrae.

## Declarations

- (1) Funding: B. Braun Medical Ltd. Sheffield, UK, is the sponsor for Open Access publication (fees) of this paper.
- (2) Conflicts of interest/Competing interests: none.
- (3) Ethics approval: not applicable.
- (4) Consent to participate: Verbal consent was obtained from the patient for presentation and publication of this case.
- (5) Consent for publication: Verbal consent was obtained from the patient for presentation and publication of this case.
- (6) Availability of data and material: not applicable.
- (7) Code availability: not applicable.
- (8) Authors' contributions: Jark Bosma is the sole author of this article.

## REFERENCES

1. Bosma JJD, Pigott TJD, Pennie BH, Jaffray DC. En bloc removal of the lower lumbar vertebral body for chordoma. Report of two cases. *J Neurosurg (Spine)*. 2001; **94**: 284-291. [PMID: 11302633]; [DOI: 10.3171/spi.2001.94.2.0284]
2. Dahlin DC. Bone Tumors. General Aspects and Data on 8,542 Cases. Springfield Ill: Charles C. Thomas; 1986.
3. Bas T, Bas P, Prieto M, Ramos V, Bas JL, Espinosa C. A lumbar chordoma treated with a wide resection. *Eur Spine J*. 1994; **3**: 115-117. [PMID: 7874548]; [DOI: 10.1007/BF02221451]
4. Chatterjee S, Bodhey NK, Gupta AK, Perikaruppan A. Chordoma of the lumbar spine presenting as sciatica and treated with vertebroplasty. *Cardiovasc Intervent Radiol*. 2010; **33**(6): 1278-81. [PMID: 19768499]; [DOI: 10.1007/s00270-009-9701-9]
5. Delank KS, Kriegsmann J, Drees P, Eckardt A, Eysel P. Metastasizing chordoma of the lumbar spine. *Eur Spine J*. 2002; **11**(2): 167-171. [PMID: 11956925]; [PMCID: PMC3610512]; [DOI: 10.1007/s00586-001-0375-5]
6. Heary RF, Vaccaro AR, Benevia J, Cotler JM. "En-bloc" vertebrectomy in the mobile lumbar spine. *Surg Neurol*. 1998; **50**: 548-556. [PMID: 9870815]; [DOI: 10.1016/s0090-3019(98)00078-0]
7. Terzi S, Mobarec S, Bandiera S, Gasbarrini A, Barbanti-Brodano G, Alberghini M, Boriani S. Diagnosis and treatment of benign notochordal cell tumors of the spine: report of 3 cases and literature review. *Spine*. 2012; **37**(21): E1356-60. [PMID:



- 22772575]; [DOI: 10.1097/BRS.0b013e318266e7e6]
8. Tharmabala M, LaBrash D, Kanthan R. Acute cauda equina syndrome secondary to lumbar chordoma: case report and literature review. *Spine J.* 2013; **13(11)**: e35-43. [PMID: 24021618]; [DOI: 10.1016/j.spinee.2013.06.058]
  9. Paillas JE, Serratrice G, Legré J. Les Tumeurs Vestigiales. In: Masson et C<sup>ie</sup>, editors. Les Tumeurs Primitives du Rachis. Paris: libraires de l'académie de médecine; 1963. pp 125-137.
  10. Sivabalan P, Li J, Mobbs RJ. Extensive chordoma and unique reconstructive approach. *Eur Spine J.* 2011; **20 Suppl 2**: S336-342. [PMID: 21479854]; [PMCID: PMC3111489]; [DOI: 10.1007/s00586-011-1785-7]
  11. Lichtenstein L. Bone Tumors. 3rd edn. C.V. Sainty Louis: Mosby Company; 1965.
  12. MacCarthy CS, Dahlin DC, Heffelfinger MJ. Chordomas of the neural axis. In: Vinken PJ and Bruyn GW, editors. Handbook of Clinical Neurology Vol.19, Tumors of the Spine and Spinal Cord, Part I. Amsterdam: North-Holland Publishing Company; 1976. pp 287-292.
  13. Sundaresan N. Chordomas. *Clin Orthop.* 1986; **204**: 135-142. [PMID: 3956004]
  14. Sundaresan N, Galicich JH, Chu FC, Huvos AG. Spinal chordomas. *J Neurosurg.* 1979; **50**: 312-319. [PMID: 422982]; [DOI: 10.3171/jns.1979.50.3.0312]
  15. Portmann J. [Chordoma of the spine.]. *Z Orthop Ihre Grenzgeb.* 1973; **111**: 755-763. (Ger) [PMID: 4273139]
  16. Chevalier X, Voisin MC, Brugières P, Ducoup-Lepointe H, Avouac B, Marty M, J Martigny, P H Hernigou, D Goutallier, J Villiaume. [Chordoma of the mobile spine. Report of 8 cases. Review of the literature]. *Rev Rhum Mal Osteoartic.* 1990; **57**: 767-778. (Fr) [PMID: 2291067]
  17. Gokaslan ZL, Zadnik PL, Sciubba DM, Germscheid N, Goodwin R, Wolinsky J-P, Bettgowda C, Groves ML, Luzzati A, Rhines LD, Fisher CG, Varga PP, Dekutoski MB, Clarke MJ, Fehlings MG, Quraishi NA, Chou D, Reynolds JJ, Williams RP, Kawahara N, Boriani S. Mobile spine chordoma: results of 166 patients from the AOSpine Knowledge Forum Tumor database. *J Neurosurg Spine.* 2016; **24(4)**: 644-651. [PMID: 26682601]; [DOI: 10.3171/2015.7.SPINE15201]
  18. Boriani S, Chevalley F, Weinstein JN, Biagini R, Campanacci L, De lure F, et al. Chordoma of the spine above the sacrum. Treatment and outcome in 21 cases. *Spine.* 1996; **21**: 1569-1577. [PMID: 8817786]; [DOI: 10.1097/00007632-199607010-00017]
  19. Polster J, Wuisman P, Härle A, Matthiass HH, Brinckmann P. [Ventral stabilization of primary tumors and metastases of the spine with vertebral body implant and palacos]. *Z Orthop Ihre Grenzgeb.* 1989; **127**: 414-417. (Ger). [PMID: 281594]; [DOI: 10.1055/s-2008-1044690]
  20. Senning A, Weber G, Yasargil MG. Zur operativen Behandlung von Tumoren der Wirbelsäule. *Schweiz Med Wochenschr.* 1962; **48**: 1574-76. (Ger) [PMID: 13987971]
  21. Mazel CH, Roy-Camille R. Spinal fusion in the treatment of spinal tumors. *Spine: State of the Art Rev.* 1992; **6**: 515-527.
  22. Rich TA, Schiller A, Suit HD, Mankin HJ. Clinical and pathologic review of 48 cases of chordoma. *Cancer.* 1985; **56**: 182-187. [PMID: 2408725]; [DOI: 10.1002/1097-0142(19850701)56:1<182::aid-cnrcr2820560131>3.0.co; 2-j]
  23. Holliday EB, Mitra HS, Somerson JS, Rhines LD, Mahajan A, Brown PD, et al. Postoperative proton therapy for chordomas and chondrosarcomas of the spine: adjuvant versus salvage radiation therapy. *Spine.* 2015; **40(8)**: 544-549. [PMID: 25627289]; [DOI: 10.1097/BRS.0000000000000804]
  24. Rotondo RL, Folkert W, Liesch NJ, Chen YL, Pedlow FX, Schwab JH, Rosenberg AE, Nielsen GP, Szymonifka J, Ferreira AE, Hornicek FJ, DeLaney TF. High-dose proton-based radiation therapy in the management of spine chordomas: outcomes and clinicopathological prognostic factors. *J Neurosurg (Spine).* 2015; **23(6)**: 788-797. Epub 2015 Sep 4. [PMID: 26340383]; [DOI: 10.3171/2015.3.SPINE14716]
  25. Sciubba DM, De la Garza Ramos R, Goodwin CR, Xu R, Bydon A, Witham TF, Gokaslan ZL, Wolinsky JP. Total en bloc spondylectomy for locally aggressive and primary malignant tumors of the lumbar spine. *Eur Spine J.* 2016; **25(12)**: 4080-87. Epub 2016 Jun 4. [PMID: 27262560]; [DOI: 10.1007/s00586-016-4641-y]