

## Complex Dorsal Metacarpophalangeal Dislocation of Index Finger- A case report

Tchaa Hodabalo Towoezim<sup>1</sup>, Solotiana Ranboaniaina<sup>2</sup>, Kolima Ehliou Akloa<sup>3</sup>, Kosivi Fortey<sup>3</sup>, Michel Berger<sup>2</sup>, Gregoire Anani Abalo<sup>3</sup>

1 Department of Traumatology, Teaching Hospital of Kara ; University of kara, Togo;

2 Department of Traumatology, Douai Hospital, Lille, France;

3 Department of traumatology, Sylvanus Olympio Teaching Hospital of Lomé; University of lomé, Togo.

**Conflict-of-interest statement:** The author(s) declare(s) that there is no conflict of interest regarding the publication of this paper.

**Open-Access:** This article is an open-access article which was selected by an in-house editor and fully peer-reviewed by external reviewers. It is distributed in accordance with the Creative Commons Attribution Non Commercial (CC BY-NC 4.0) license, which permits others to distribute, remix, adapt, build upon this work non-commercially, and license their derivative works on different terms, provided the original work is properly cited and the use is non-commercial. See: <http://creativecommons.org/licenses/by-nc/4.0/>

**Correspondence to:** Tchaa Hodabalo Towoezim, CHU Kara BP: 18, Kara, Togo.

Email: [antoinetowoezim@yahoo.com](mailto:antoinetowoezim@yahoo.com)

Telephone: + (228) 90 30 07 45

Received: July 5, 2021

Revised: September 20, 2021

Accepted: September 24 2021

Published online: October 28, 2021

### ABSTRACT

Complex posterior metacarpophalangeal dislocations of the long fingers are rare, typically caused by entrapment of the volar plate within the joint space. They require surgical reduction to release the soft tissues interposed between the metacarpal head and the proximal phalanx. but there is an operative risk of digital nerve injury because of intricate displacement of the normal anatomy. We report the case of a 30-year-old patient who presented to the emergency department at the second day after his trauma with a complex posterior metacarpophalangeal dislocation of the right index finger. After failure of the closed reduction attempt, the dislocation was reduced surgically by an volar approach. The neurovascular bundle has been identified and carefully removed. The volar plate has been

reduced, resulting in reduction of the dislocation. The volar plate has been completely repaired. At six weeks, all the range of motion of the MCP and other joints of the index finger had been found. At the last follow-up, the joint was still stable. Different techniques are described in the literature for the reduction of the complex posterior dislocations of long fingers, but the volar approach remains the best for palmar plate reduction and its full repair, which may decrease the risk of late instability.

**Key words:** Metacarpophalangeal joint; Dislocation; Index; Volar plate

© 2021 The Author(s). Published by ACT Publishing Group Ltd. All rights reserved.

Towoezim TH, Ranboaniaina S, Akloa KE, Fortey K, Berger M, Abalo GA. Complex Dorsal Metacarpophalangeal Dislocation of Index Finger- A case report. *International Journal of Orthopaedics* 2021; 8(5): 1565-1567 Available from: URL: <http://www.ghrnet.org/index.php/ijo/article/view/3218>

### INTRODUCTION

Metacarpophalangeal (MCP) dislocations of long fingers are uncommon and often caused by high-energy trauma<sup>[1]</sup>. Dorsal dislocations are the most frequent. They are said to be simple when closed reduction is possible; or complex when they are irreducible to closed maneuvers<sup>[2]</sup>. Complex dislocations require surgical reduction to release the soft tissues interposed between the metacarpal head and the proximal phalanx<sup>[2,3]</sup>. We present a case of complex dorsal dislocation of the metacarpophalangeal joint of the index that we successfully treated surgically by an volar approach.

### CASE DESCRIPTION

A 30-year-old patient, right-handed, with no significant medical or surgical history, presented to the emergency department the day after his trauma for pain and relative functional impotence of the right index finger following a sports accident. The patient was playing football when he fell on the palms of both hands, elbows extended. The pain was moderate, localized to the index finger. Active flexion of the metacarpophalangeal joint was impossible. On physical

examination, the patient had moderate swelling with slight external rotation of the finger. There was pain on palpation of the MCP which remained blocked in extension, with an palmar prominence of the second metacarpal head. The base of the proximal phalanx was palpated dorsally. The patient denied paresthesia. Sensation and capillary refill time were normal over the finger. The x-ray confirmed the diagnosis of dislocation of the MCP joint in its dorsal variety (Figure 1).

The attempt to reduce by closed technique was unsuccessful. It was concluded that there was a complex MCP dislocation and therefore a surgical reduction was required. By an volar approach, the head of the second metacarpal was exposed, the disinserted volar plate being found behind, wedged between the head of the metacarpal and the base of the proximal phalanx (Figure 2). Traction was performed on the finger, mobilization and reduction of the palmar plate forward resulted in reduced dislocation. The palmar plate was reinserted on the metacarpal neck by an anchor. Postoperatively, the patient was placed in splint with 45 ° of flexion of the metacarpophalangeal joint for 3 weeks, then rehabilitation was performed. Six weeks after the trauma, functional recovery of the index finger was complete; X-rays showed the reduction was in place (Figure 3). One year postoperatively, there was no functional complaint.

## DISCUSSION

MCP dislocations of the long fingers are relatively rare, and the index and little fingers are the most common<sup>[2]</sup>. Closed dislocations are more frequent than open dislocations, and the posterior varieties are more frequent than the anterior ones<sup>[4]</sup>. The frequency of MCP dislocations of the index and ring fingers is explained on the one hand by their anatomical position which increases their vulnerability to trauma, and on the other hand by the lack of stabilization by two adjacent deep transverse metacarpal ligaments<sup>[2]</sup>. Dorsal dislocation result from forced hyperextension of the digit on an outstretched hand<sup>[2]</sup>. The clinical examination makes it possible to evoke the diagnosis, the X-ray of the hand makes it possible to confirm the posterior MCP dislocation<sup>[5]</sup>. When patients consult late, some authors recommend CT scan for a definite diagnosis and the search for associated osteochondral lesions<sup>[1]</sup>.

For simple posterior dislocations, closed reduction is possible by flexing the wrist and proximal interphalangeal joint while pressure is applied to the base of the proximal phalanx<sup>[5]</sup>. When closed reduction fails, the dislocation is said to be complex and then requires surgical reduction. This irreducibility is due to the fact that soft tissues are trapped within the joint space between the base of the proximal phalanx and the dorsal metacarpal head. It may be the dorsal capsule associated with the ulnar collateral ligament, but especially the volar plate, isolated or associated with the ulnar collateral ligament, flexor tendons, or lumbrical muscle tendon<sup>[2,4]</sup>. Several approaches have been described in the literature:

The dorsal approach is undoubtedly the most used. Described by Farabeuf in 1876, it has the advantage of allowing excellent exposure for evaluation of the volar plate that may become tented over the metacarpal head. It allowed also repair of osteochondral fractures and avoids the digital neurovascular bundle. It is therefore recommended to young surgeons. The major disadvantage is that the volar plate is unrepairable, exposing MCP joint to the risk of late instability<sup>[2,3,6]</sup>.

The volar surgical approach comes second in terms of frequency of use. Described by Kaplan in 1957, it allows for better access and visualization the strangulated metacarpal head and the volar plate. Thus a better reduction of the volar plate is obtained, as well as the restoration of the MCP joint by the full repair of the volar

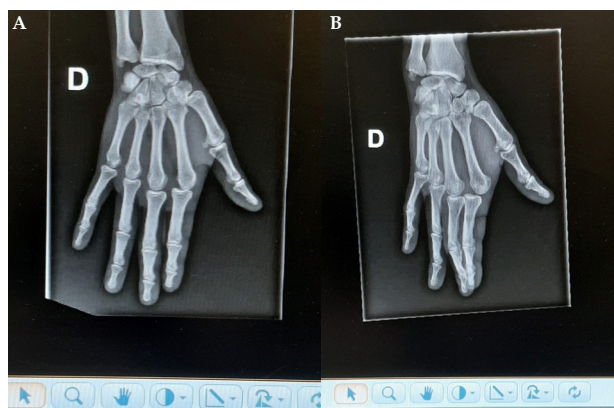


Figure 1 Right hand anteroposterior (A) and lateral (B) radiographs preoperatively demonstrate dorsal dislocation of the index MCP joint.

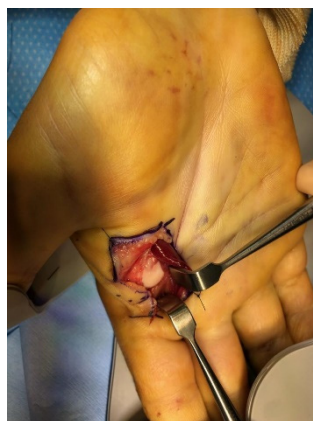

Figure 2 Clinical aspect after volar approach. The dislocated MCP joint is visualized, the entrapped volar plate is seen adjacent to the metacarpal head.

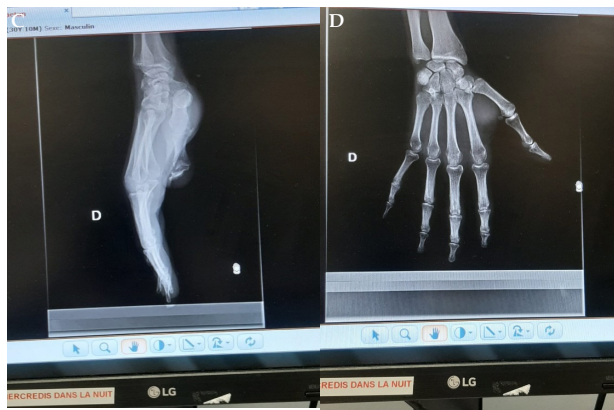

Figure 3 Right index finger anteroposterior (C) and lateral (D) radiographs at 6-weeks follow-up demonstrate a well reduced index MCP joint.

plate, making the reduction more stable. The dislocation displaces the neurovascular bundle superficially and immediately under the skin. This change in anatomy increases the risk of damage to the neurovascular structures through the volar approach. For this, volar approach is recommended to experienced surgeons<sup>[2,3,5,7]</sup>.

The lateral approach was recently described by Pereira<sup>[3]</sup>. It offers the advantage of volar and dorsal access, reduction and repair of the volar plate, as well as repair of dorsal osteochondral lesions. On the other hand, the risk of nerve damage has not been reported<sup>[2,3,8]</sup>. Kodama, Itotani and Mizuseki described arthroscopic reduction which has the advantage of a less invasive dorsal entry point. This would avoid the risk of nerve damage, also allows exploration of the joint and reduction of volar plate without damage to it. The

disadvantage is the impossibility of extra-articular access and therefore difficult to analyze if, apart from the volar plate, other anatomical lesions were associated or not<sup>[9]</sup>. Finally, percutaneous minimally invasive approaches have been described. Although they are simple, there is the risk of nerve and cartilage damage<sup>[10]</sup>.

## CONCLUSION

Complex dorsal metacarpophalangeal dislocations of the index finger are rare. They require a surgical approach. The volar approach can lead to iatrogenic neurovascular lesions, but it allows the reduction and full repair of the volar plate, guaranteeing the stability of the reduction.

## REFERENCES

- Chitnis SS, Chitnis SL. Indication for CT following index finger metacarpophalangeal joint dislocation-A case report. *Trauma Case Reports, Elsevier* 2018; **18**: 31-36. [PMID: 30533480]; [DOI: 10.1016/j.tcr.2018.11.014]
- Sumarriva G, Cook B, Godoy G, Waldron S. Pediatric Complex Metacarpophalangeal Joint Dislocation of the Index Finger. *Ochsner Journal* 2018; **18**(4): 398-401. [PMID: 30559627]; [DOI: 10.31486/toj.18.0032]
- Pereira JM, Quesado M, Silva M, Carvalho JDD, Nogueira H, Alves J. The Lateral Approach in the surgical treatment of a Complex Dorsal Metacarpophalangeal joint Dislocation of the Index Finger. *Case Rep Orthop* 2019; **2019**: 1063829, 5P. [PMID: 31093396]; [10.1155/2019/1063829]
- Zrig M, Mnif H, Koubaa M, Jawahdou R, Sahnoun N, Abid A. Luxation palmaire de l'articulation métacarpophalangienne des doigts longs: à propos d'un cas. *Chirurgie de la main, Elsevier Masson* 2009; **28**(5): 306-309. [PMID : 19717326]; [10.1016/j.main.2009.06.004]
- Dinh P, Franklin A, Hutchison B, Schnall SB, Fassola I. Metacarpophalangeal joint dislocation. *J Am Acad Orthop Surg* 2009; **17**(5): 318-324. [PMID: 19411643]; [10.5435/00124635-200905000-00006]
- Becton JL, Christian JD, Goodwin HN, Jackson JG. A simplified technique for treating the complex dislocation of the index metacarpophalangeal joint. *The Journal of Bone & Joint Surgery* 1975; **57**(5): 698-700. [PMID: 1150718]
- Kaplan EB. Dorsal dislocation of the metacarpophalangeal joint of the index finger. *The Journal of Bone & Joint Surgery* 1957; **39**(5): 1081-1086. [PMID: 13475407]
- Farabeuf L. De la luxation du pouce en arrière. *Maitrise Orthopédique* 2004; **136**: 632-640.
- Kodama A, Itotani Y, Mizuseki T. Arthroscopic Reduction of Complex Dorsal Metacarpophalangeal Dislocation of Index Finger. *Arthroscopy techniques* 2014; **3**(2): pp e261-e264. [PMID: 24904773]; [DOI: 10.1016/j.eats.2013.11.008]
- Sodha S, Breslow GD, Chang B. Percutaneous technique for reduction of complex metacarpophalangeal dislocations. *Ann Plast Surg* 2004; **52**: 562-565. [PMID: 15166981]; [10.1097/01.sap.0000123351.12922.f4]