

## First-time Shoulder Dislocation: Review of Operative Versus Non-Operative Management

Iossifidis A<sup>1</sup>, Khoriaty AA<sup>1</sup>, Togiag G<sup>1</sup>

<sup>1</sup> Croydon University Hospital, London, UK.

**Conflict-of-interest statement:** The author(s) declare(s) that there is no conflict of interest regarding the publication of this paper.

**Open-Access:** This article is an open-access article which was selected by an in-house editor and fully peer-reviewed by external reviewers. It is distributed in accordance with the Creative Commons Attribution Non Commercial (CC BY-NC 4.0) license, which permits others to distribute, remix, adapt, build upon this work non-commercially, and license their derivative works on different terms, provided the original work is properly cited and the use is non-commercial. See: <http://creativecommons.org/licenses/by-nc/4.0/>

**Correspondence to:** Mr Anestis Iossifidis, MD, FRCS Ed, FRCS Ed (orth.), Senior Orthopaedic Surgeon, Head of Shoulder & Upper Limb Unit. Croydon University Hospital, 530 London Road, Croydon, London, CR7 7YE, UK.

**Email:** [anestis.iossifidis@gmail.com](mailto:anestis.iossifidis@gmail.com)

**Received:** October 15, 2021

**Revised:** November 23, 2021

**Accepted:** December 1 2021

**Published online:** December 28, 2021

### ABSTRACT

The management of first-time shoulder dislocation has long been a subject of controversy among shoulder surgeons. The benefits of surgery have to be offset against the risks. In this article, the authors examine the evidence for and against operative treatment when considering this complicated subset of patients and put forward an algorithm for decision making on operative versus non operative management.

**Key words:** Shoulder stabilisation; First-time shoulder dislocation; Bankart lesion; Hill-Sachs lesion

© 2021 The Author(s). Published by ACT Publishing Group Ltd. All rights reserved.

Iossifidis A, Khoriaty AA, Togiag G. First-time Shoulder Dislocation: Review of Operative Versus Non-operative Management.

*International Journal of Orthopaedics* 2021; 8(6): 1568-1572  
Available from: URL: <http://www.ghrnet.org/index.php/ijo/article/view/3243>

### INTRODUCTION

Treatment of first-time dislocation with an initial period of immobilisation and subsequent physiotherapy have been the mainstay of conservative management. The chances however of redislocation must also be considered, along with any sequelae such as osteoarthritis.

In this review, the authors examine the evidence for and against operative management when considering this complicated subset of patients and put forward an algorithm for decision making on operative versus non operative management.

### NON OPERATIVE MANAGEMENT

Traditionally, the practice of immobilisation followed by a period of rehabilitation with physiotherapy has been practiced in conservative treatment of traumatic shoulder dislocations. Hovelius et al<sup>[1]</sup> followed a series of 257 first time dislocated shoulders over a period of 25 years and found that approximately half of these (in patients aged 12-25) had not recurred or had become stable over time. Gender and athletic activity were not found to affect the redislocation rate. Immobilization after the primary dislocation did not appear to change the prognosis.

The position of immobilisation has also been the subject of debate, with Itoi et al<sup>[2]</sup> indicating that immobilisation in external rotation resulted in tensioning the subscapularis muscle is thus applying a force which pressed the joint capsule against the neck of the glenoid. Their cadaveric study showed that the edges of a simulated Bankart lesion were coapted when the arm was held in external rotation. These findings were contradicted by a similar cadaveric study conducted by Limpisvasti et al, who concluded that external rotation of the shoulder did not create contact pressure between the subscapularis and the anterior labrum before or after anterior dislocation<sup>[3]</sup>. The in vitro nature of these studies has been put forward as an explanation for the incongruity of these findings. Itoi et al further investigated the position of immobilisation in vivo with a Magnetic resonance imaging (MRI) study<sup>[4]</sup>. Their scans revealed that immobilisation in external rotation better approximated the Bankart lesion to the glenoid neck than the conventional position of internal

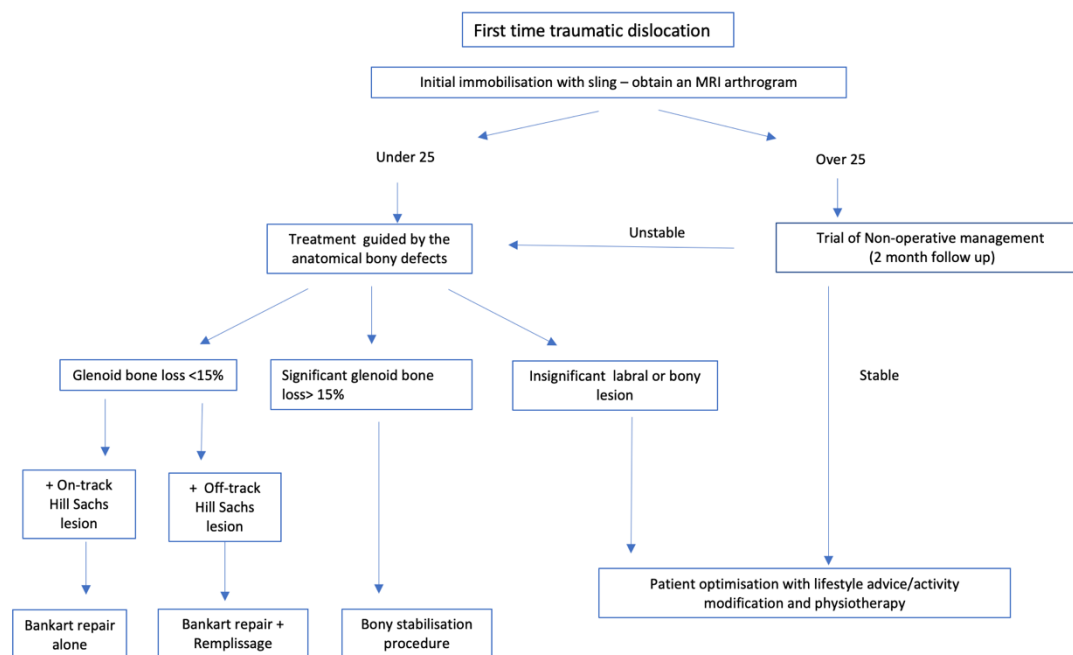


Figure 1 Management algorithm of first-time shoulder dislocation.

rotation. However, these findings were once again challenged, with Chetouani et al<sup>[5]</sup> finding that external rotation of the shoulder did not result in reduction of the labrum. This may have been due to the fact that different ranges of external rotation were used in each. An in vivo arthroscopic study by Hart et al<sup>[6]</sup> on 25 patients noted that Reduction of the Bankart lesion was improved in external rotation in 92% of the patients studied. The authors did however note that the reduction was usually incomplete and that the labrum failed to recover a fully normal position.

The clinical trials performed on the subject have yielded mixed results. Itoi et al<sup>[7]</sup> published a preliminary study on 40 shoulders examining the clinical difference in recurrence rate after immobilisation in external rotation. The recurrence rate was 30% in the internal rotation group and 0% in the external rotation group at a mean follow up of 15.5 months. This difference was more pronounced among the under 30s (45% Vs 0%). The same group published a larger study involving 198 patients with a recurrence rate of 26% Vs 42% favouring external rotation<sup>[8]</sup>. A case series by Tanaka et al<sup>[9]</sup> suggested that external rotation immobilization may not be as effective as noted in previous studies – particularly as the subset of patients were all highly active young men with primary traumatic anterior shoulder dislocation or subluxation. They also concluded that patients’ symptoms after external rotation immobilization depended on more than the fact that the anteroinferior labrum was not reduced on MRI.

## RISK FACTORS FOR SUBSEQUENT DISLOCATION

When considering the subset of patients more likely to require subsequent surgery, the first consideration should always be centred on the chance of subsequent redislocation.

Robinson et al<sup>[10]</sup> quantified the risk of redislocation in a prospective cohort study of 252 patients (15-35 years old) who sustained a first time anterior glenohumeral dislocation. These patients were treated with sling immobilization, which was followed by a program of physiotherapy. A survival analysis was performed and subsequent instability occurred in 55.7% of patients within

two years. This increased to 66.8% by the five-year mark. The younger, male patients were at the highest risk of instability. In total, 86.7% of all of the patients with recurrent instability developed this complication within two years of the index event. A small but measurable degree of functional impairment was present at two years after the initial dislocation in most patients. The risk of recurrent dislocation was found to be inversely proportional to the age of the patient at the time of the index event. Males under the age of 16 were found to have an 86% chance of redislocation (vs females at 54%). This dropped to 29% in 35-year-olds (vs females at 13%).

At the extremes of age, the difference in redislocation rate is more stark, with Marans et al<sup>[11]</sup> reporting a redislocation rate of 100% in patients with an open physis. In patients over the age of 50, the recurrence rate has been described as 14-22%<sup>[12]</sup>.

## CONSEQUENCES OF NON-OPERATIVE MANAGEMENT

Hovelius et al<sup>[13]</sup> carried out a separate study on the aforementioned group of patients. Radiographic evaluation of the patient cohort at 25 year follow up, found that mild arthropathy had developed in 29% of patients studied, moderate in 9%, and severe in 17%. In the subset of patients without recurrent instability 18% had moderate/severe arthropathy. This increased to 39% in unstable shoulders and was found to be 26% for surgically stabilised shoulders. The age at primary dislocation, recurrence, participation in high-energy sports and alcohol abuse were factors associated with the development of osteoarthritis. A retrospective review of 570 patients by Buscayret et al<sup>[14]</sup> set the rate of osteoarthritis at 9.2%, though it is important to note that the average length of follow up was 6.5 years. Risk factors for the development of osteoarthritis were age at the index dislocation and at surgery, increased length of time between the index dislocation and surgery, as well as the presence of osseous glenoid rim lesions.

The consequences of non-operative management were not only limited to the development of osteoarthritis. De Carli et al (2019) performed a prospective study of 160 patients with a first-time anterior shoulder dislocation. A total of 64 patients opted for surgical treatment versus 96, who opted for non-operative management. The

patients were aged 15-25. At long term follow-up, recurrence rate, patient reported outcomes and return to sport were all found to be superior in the surgical group<sup>[15]</sup>.

## OPERATIVE MANAGEMENT AND RECURRENCE RATE

Arthroscopic and open soft tissue and bony procedures as well as arthroscopic lavage have been used to treat instability<sup>[16]</sup>. The type of procedure is determined by both anatomical considerations as well as surgical preference. Arthroscopic lavage has been postulated to be beneficial with regards to recurrence rate by removing any existing haematoma and recentring the humeral head within the glenohumeral joint. Wintzell *et al*<sup>[16]</sup> conducted a prospective randomized trial on 30 consecutive patients with traumatic primary anterior shoulder dislocation. The patients were between 18 and 30 years of age with no previous history of shoulder instability. At the 2 years (20%) of the lavage group had re-dislocated compared with (60%) of 15 patients in the nonoperative group. Arthroscopic lavage itself has been compared with soft tissue repair and found to be inferior. Chahal *et al*<sup>[17]</sup> compared arthroscopic Bankart repair to washout and non-operative treatment and found that the rate of recurrent instability was significantly lower among participants undergoing anatomic Bankart repair compared with those undergoing immobilization or arthroscopic lavage. Western Ontario Shoulder Instability scores were better with anatomic Bankart repair compared with either of the other two therapeutic pathways.

In a long term study with a randomised control trial comparing long-term results after surgical and conservative treatment of first time traumatic anterior shoulder dislocation, Jakobsen *et al*<sup>[18]</sup> found a significantly higher incidence of recurrent instability in patients with non-operative management compared with open repair. At 2 years' follow-up 54% of the conservatively treated patients had recurrent instability vs 3% after open surgical repair. At 8 years 74% of patients in the non-operatively treated group had an unsatisfactory outcome as assessed by the Oxford shoulder score. This contrasted starkly with the surgical group: 72% had a good or excellent result at 10 year follow up. Sachs *et al*<sup>[19]</sup> carried out a prospective study on 131 patients. They concluded that younger patients involved in contact or collision sports or who require "overhead occupational use of the arm" were more likely to suffer from subsequent dislocation of the shoulder.

## DISCUSSION

It is increasingly clear from the literature that early operative intervention is superior to non-operative management in the prevention of recurrence, particularly in young, active male patients. This is borne out in case series by Kramer *et al* (2019)<sup>[20]</sup> and reviews of the literature<sup>[21]</sup>. The wide range of papers published within the literature would by and large support this. Franklin *et al* (2019) conducted a review of the English literature and concluded that recurrent instability was very likely in young patients<sup>[21]</sup>. They noted that the recurrence rate for young patients was often greater than 70%. In a younger cohort, with a longer life expectancy the recurrent chances of instability and subsequent articular damage were deemed unacceptable. The high level of functional outcome associated with surgical intervention would appear to justify the relatively small risks of surgery<sup>[22,23]</sup>. Nevertheless, recurrence in the adolescent population remains an issue despite intervention in certain cases<sup>[24]</sup>. Careful consideration should be given to a discussion detailing the risks and

benefits of non-operative versus operative management. Pairing of a young patient's injury pattern, risk factors, and/or athletic goals is essential<sup>[25]</sup>.

The benefits of surgery in a slightly older population are also evident. A multicentre analysis by Rugg *et al* (2018) demonstrated that first-time shoulder dislocators who underwent stabilization were more likely to undergo an arthroscopic procedure and were less likely to have bone loss or biceps pathology compared with recurrent dislocators who did not undergo surgery<sup>[26]</sup>. A study of 257 patients by Hovelius *et al* (2016) followed younger patients (aged under 40) for a period of 25 years<sup>[27]</sup>. In the under 25s, half of all first-time dislocations had stabilisation surgery and two-thirds developed different stages of arthropathy within 25 years. The authors commented that this was a surprisingly high figure. This figure should probably be interpreted within the context of the fact that stabilisation surgery has evolved considerably in this period of time. Compared with the figures at 10years (9%), moderate to severe arthropathy appeared to increase by 1% a year. When mild arthropathy was included, this figure rose to 56% after 25 years. All shoulders in alcoholic patients at 25years had severe arthropathy. Of interest, it was noted that 17% of shoulders without any recurrence at all had moderate or severe arthropathy and a further 32% had mild arthropathy (when the alcoholics were excluded). This indicated that a shoulder dislocation as a standalone event is associated with arthropathy. It was observed that 21% of operated shoulders (alcoholics excluded) had moderate/severe arthropathy and a further 19% mild. The fact that these figures were lower than those for shoulders stabilised at a later time, led the authors to suggest that stabilisation prevented the evolution of arthropathy.

Questions have to be asked about the role of non-operative management. The literature is not without contradictory findings. These may be explained by the sheer heterogeneity of the available studies. Patient populations, compliance rates, rehab protocols and surgical technique do make it difficult to draw broad conclusions on the superiority of one intervention over the other. The sheer variety in case mix is also relevant as it is known that the type of treatment should be tailored to the individual patient based on the extent of the anatomical injury.

Tools to predict the recurrence rate among patients aged 16-40 years have been published, with Olds *et al* (2019) concluding that six physical and psychosocial factors can be used to predict recurrent shoulder instability following a first-time traumatic anterior shoulder dislocation<sup>[28]</sup>. These were found to be : lack of immobilisation, higher levels of activity, the presence of bony Bankart and /or Hill-Sachs lesions, higher levels of pain and disability, higher levels of fear of reinjury and decreased quality of life. Of note, hand dominance was not found to influence redislocation rate.

## CONCLUSION

The authors therefore advocate management of these injuries on a case-by-case basis. Consideration of the patient's age, activity level, gender, anatomical insult and expectations should lead clinicians to seek a joint decision on patient's management, while having a low threshold to intervene surgically should an initial period of non-operative management prove unsuccessful. As an aid to decision making, and based on the evidence available, the authors put forward the following algorithm for decision making on operative versus non operative management. Fig 1. We have taken into account the variability in anatomical insult to the shoulder, age, activity levels and relevant comorbidities.

All patients with a first-time dislocation of the shoulder should undergo an acute MRI. This provides an arthrogram detailing the extent of soft tissue and bony injury. In the over 40s and after MRI exclusion of a cuff tear, a trial of non-operative management for 2 months should always be performed as the risk of redislocation is lower than in young and more active patients. The management of patients aged 25–40 should commence with a period of non-operative management and physiotherapy. Careful consideration is then given to their desired activity level and expectations. In the under 25s the authors would strongly consider surgical intervention.

The type of surgical intervention in each case should be guided by the anatomical defects on the MRI. Those with purely anterior soft tissue defects with insignificant or on-track Hill Sachs lesions should be treated with a Bankart repair alone. Those with off-track lesions should undergo a Bankart with a Remplissage procedure. Finally, in cases with significant bony loss of the glenoid (>15%), a Latarjet procedure should be considered<sup>[29]</sup>.

## REFERENCES

- Hovellius L, Olofsson A, Sandström B, et al. Nonoperative treatment of primary anterior shoulder dislocation in patients forty years of age and younger. a prospective twenty-five-year follow-up. *J Bone Joint Surg Am.* 2008; **90**(5): 945-952. [PMID: 18451384]; [DOI: 10.2106/JBJS.G.00070]
- Itoi E, Hatakeyama Y, Urayama M, Pradhan RL, Kido T, Sato K. Position of immobilization after dislocation of the shoulder. A cadaveric study. *J Bone Joint Surg Am.* 1999; **81**(3): 385-390. [PMID: 10199277]
- Limpisvasti O, Yang BY, Hosseinzadeh P, Leba T-B, Tibone JE, Lee TQ. The Effect of Glenohumeral Position on the Shoulder after Traumatic Anterior Dislocation. *Am J Sports Med.* 2008; **36**(4): 775-780. [PMID: 18212348]; [DOI: 10.1177/0363546507312163]
- Itoi E, Sashi R, Minagawa H, Shimizu T, Wakabayashi I, Sato K. Position of immobilization after dislocation of the glenohumeral joint. A study with use of magnetic resonance imaging. *J Bone Joint Surg Am.* 2001; **83**(5): 661-667. [PMID: 11379734]; [DOI: 10.2106/00004623-200105000-00003]
- Chetouani M, Ropars M, Marin F, Hutten D, Duvauferrier R, Thomazeau H. Is MRI useful to assess labral reduction following acute anterior shoulder dislocation? *Orthopaedics & Traumatology: Surgery & Research.* 2010; **96**(3): 203-207. [PMID: 20488136]; [DOI: 10.1016/j.otsr.2009.12.004]
- Hart WJ, Kelly CP. Arthroscopic observation of capsulolabral reduction after shoulder dislocation. *Journal of Shoulder and Elbow Surgery.* 2005; **14**(2): 134-137. [PMID: 15789005]; [DOI: 10.1016/j.jse.2004.07.002]
- Itoi E, Hatakeyama Y, Kido T, et al. A new method of immobilization after traumatic anterior dislocation of the shoulder: a preliminary study. *Journal of Shoulder and Elbow Surgery.* 2003; **12**(5): 413-415. [PMID: 14564258]; [DOI: 10.1016/s1058-2746(03)00171-x]
- Itoi E, Hatakeyama Y, Sato T, et al. Immobilization in external rotation after shoulder dislocation reduces the risk of recurrence. A randomized controlled trial. *J Bone Joint Surg Am.* 2007; **89**(10): 2124-2131. [PMID: 17908886]; [DOI: 10.2106/JBJS.F.00654]
- Tanaka Y, Okamura K, Imai T. Effectiveness of external rotation immobilization in highly active young men with traumatic primary anterior shoulder dislocation or subluxation. *Orthopedics.* 2010; **33**(9): 670. [PMID: 20839708]; [DOI: 10.3928/01477447-20100722-07]
- Robinson CM, Howes J, Murdoch H, Will E, Graham C. Functional outcome and risk of recurrent instability after primary traumatic anterior shoulder dislocation in young patients. *J Bone Joint Surg Am.* 2006; **88**(11): 2326-2336. [PMID: 17079387]; [DOI: 10.2106/JBJS.E.01327]
- Marans HJ, Angel KR, Schemitsch EH, Wedge JH. The fate of traumatic anterior dislocation of the shoulder in children. *J Bone Joint Surg Am.* 1992; **74**(8): 1242-1244. [PMID: 1400553]
- Polyzois I, Dattani R, Gupta R, Levy O, Narvani AA. Traumatic First Time Shoulder Dislocation: Surgery vs Non-Operative Treatment. *NUMBER.* 2016; **4**(2): 5. [PMID: 27200385]; [PMCID: PMC4852033]
- Hovellius L, Saeboe M. Neer Award 2008: Arthropathy after primary anterior shoulder dislocation--223 shoulders prospectively followed up for twenty-five years. *J Shoulder Elbow Surg.* 2009; **18**(3): 339-347. [PMID: 19254851]; [DOI: 10.1016/j.jse.2008.11.004]
- Buscayret F, Edwards TB, Szabo I, Adeleine P, Coudane H, Walch G. Glenohumeral arthrosis in anterior instability before and after surgical treatment: incidence and contributing factors. *Am J Sports Med* 2004; **32**(5): 1165-72. [PMID: 15262638]; [DOI: 10.1177/0363546503262686]
- De Carli A, Vadalà AP, Lanzetti R, et al. Early surgical treatment of first-time anterior glenohumeral dislocation in a young, active population is superior to conservative management at long-term follow-up. *Int Orthop.* 2019; **43**(12): 2799-2805. [PMID: 31392495]; [DOI: 10.1007/s00264-019-04382-2]
- Wintzell G, Haglund-Åkerlind Y, Nowak J, Larsson S. Arthroscopic lavage compared with nonoperative treatment for traumatic primary anterior shoulder dislocation: A 2-year follow-up of a prospective randomized study. *Journal of Shoulder and Elbow Surgery.* 1999; **8**(5): 399-402. [PMID: 10543589]; [DOI: 10.1016/s1058-2746(99)90066-6]
- Chahal J, Marks PH, Macdonald PB, et al. Anatomic Bankart repair compared with nonoperative treatment and/or arthroscopic lavage for first-time traumatic shoulder dislocation. *Arthroscopy.* 2012; **28**(4): 565-575. [PMID: 22336435]; [DOI: 10.1016/j.arthro.2011.11.012]
- Jakobsen BW, Johannsen HV, Suder P, Søbjerg JO. Primary Repair Versus Conservative Treatment of First-Time Traumatic Anterior Dislocation of the Shoulder: A Randomized Study With 10-Year Follow-up. *Arthroscopy: The Journal of Arthroscopic & Related Surgery.* 2007; **23**(2): 118-123. [DOI: 10.1016/j.arthro.2006.11.004]
- Sachs RA, Lin D, Stone ML, Paxton E, Kuney M. Can the need for future surgery for acute traumatic anterior shoulder dislocation be predicted? *J Bone Joint Surg Am.* 2007; **89**(8): 1665-1674. [PMID: 17671003]; [DOI: 10.2106/JBJS.F.00261]
- Kramer J, Gajudo G, Pandya NK. Risk of Recurrent Instability After Arthroscopic Stabilization for Shoulder Instability in Adolescent Patients. *Orthopaedic Journal of Sports Medicine.* 2019; **7**(9): 232596711986899. [PMID: 31555715]; [PMCID: PMC6749790]; [DOI: 10.1177/2325967119868995]
- Franklin CC, Weiss JM. The Natural History of Pediatric and Adolescent Shoulder Dislocation. *Journal of Pediatric Orthopaedics.* 2019; **39**(Supplement 1): S50-S52. [PMID: 31169649]; [DOI: 10.1097/BPO.0000000000001374]
- Shanmugaraj A, Chai D, Sarraj M, et al. Surgical stabilization of pediatric anterior shoulder instability yields high recurrence rates: a systematic review. *Knee Surg Sports Traumatol Arthrosc.* 2021; **29**(1): 192-201. [PMID: 32112125]; [DOI: 10.1007/s00167-020-05913-w]
- Saper MG, Milchtein C, Zondervan RL, Andrews JR, Ostrander RV. Outcomes After Arthroscopic Bankart Repair in Adolescent Athletes Participating in Collision and Contact Sports. *Orthopaedic Journal of Sports Medicine.* 2017; **5**(3): 232596711769795. [PMID: 28451607]; [PMCID: PMC5400177]; [DOI: 10.1177/2325967117697950]
- Bonazza NA, Riboh JC. Management of Recurrent Anterior Shoulder Instability After Surgical Stabilization in Children and

- Adolescents. *Curr Rev Musculoskelet Med.* 2020; **13(2)**: 164-172. [PMID: 32076937]; [PMCID: PMC7174442]; [DOI: 10.1007/s12178-020-09612-4]
25. Lin KM, James EW, Spitzer E, Fabricant PD. Pediatric and adolescent anterior shoulder instability: clinical management of first-time dislocators. *Current Opinion in Pediatrics.* 2018; **30(1)**: 49-56. [PMID: 29135565]; [DOI: 10.1097/MOP.0000000000000566]
  26. Rugg CM, Hettrich CM, Ortiz S, et al. Surgical stabilization for first-time shoulder dislocators: a multicenter analysis. *Journal of Shoulder and Elbow Surgery.* 2018; **27(4)**: 674-685. [PMID: 29321108]; [DOI: 10.1016/j.jse.2017.10.041]
  27. Hovelius L, Rahme H. Primary anterior dislocation of the shoulder: long-term prognosis at the age of 40 years or younger. *Knee Surg Sports Traumatol Arthrosc.* 2016; **24(2)**: 330-342. [PMID: 26754859]; [DOI: 10.1007/s00167-015-3980-2]
  28. Olds MK, Ellis R, Parmar P, Kersten P. Who will redislocate his/her shoulder? Predicting recurrent instability following a first traumatic anterior shoulder dislocation. *BMJ Open Sport Exerc Med.* 2019; **5(1)**: e000447. [PMID: 30899544]; [PMCID: PMC6407568]; [DOI: 10.1136/bmjsem-2018-000447]
  29. Iossifidis A, Khoriaty AA. Hill-Sachs Remplissage procedure and its role in arthroscopic stabilisation of the shoulder. *International Journal of Orthopaedics* **8(4)**: 1493-1496. [DOI: 10.17554/j.issn.2311-5106.2021.08.420]