

Modified Direct Lateral Approach Total Hip Arthroplasty With Good Functional Outcomes and Low Complication Rates: A Prospective Study of 450 Patients for 6 Years of Follow up

Awadhesh Kumar Pandey¹, Suleyman Diako², Joseph Mwamba Kabongo³

1 Specialist Orthopaedic Surgeon, Welwitschia Medipark Hospital, Walvis Bay, Namibia;

2 Orthopaedic Resident, State Hospital Oshakati, Namibia;

3 Specialist Interventional Radiologist, Welwitschia Medipark Hospital, Walvis, Bay, Namibia.

Conflict-of-interest statement: The author(s) declare(s) that there is no conflict of interest regarding the publication of this paper.

Open-Access: This article is an open-access article which was selected by an in-house editor and fully peer-reviewed by external reviewers. It is distributed in accordance with the Creative Commons Attribution Non Commercial (CC BY-NC 4.0) license, which permits others to distribute, remix, adapt, build upon this work non-commercially, and license their derivative works on different terms, provided the original work is properly cited and the use is non-commercial. See: <http://creativecommons.org/licenses/by-nc/4.0/>

Correspondence to: Awadhesh Kumar Pandey, Specialist Orthopaedic Surgeon, Welwitschia Medipark Hospital, Walvis Bay, Namibia.

Email: awadheshkpandey6@gmail.com

Tele: +264 816803828

Received: November 30, 2021

Revised: December 8, 2021

Accepted: December 13 2021

Published online: December 28, 2021

ABSTRACT

Total hip replacement is commonly performed surgeries for all types of Hip arthritis and intracapsular fracture neck femur in more than 50 years of age group patients worldwide. Three main surgical approaches, which have been widely studied in literature for THA have their own risks and complications per and postoperatively. We conducted a prospective study for our primary total hip arthroplasty operated by modified direct lateral approach. We randomly followed our 450 Total Hip Replacement patients from 2013-2019. We utilized direct lateral small incision modified minimal Vastusgluteal split approach in lateral position. Our results showed

excellent outcomes on HHS and VAS scale. We had one post op hip dislocation, managed with closed reduction and skin traction for 1 week with gradual weight bearing over 3 weeks. We encountered one septic complication which needed liner exchange with thorough soft tissue debridement and vacuum dressing with suppressive antibiotics for 6 weeks. Our 3rd patient complained of painful limping with Trendelenburgh gait. There was no superior gluteal nerve injury on MRI. He was diagnosed with severe degenerative lumbar spinal stenosis with L4-S1 nerve roots compression. There were 2 intra-operative incomplete stable trochanteric fractures, which were successfully managed with encirclage cable wiring without any adverse effects on outcome. Length of hospital stay ranged from 2-5 days. Cup positioning were moderately accurate according to Lewinnek safe zone. All patients received Tranexamic acid intraoperatively to minimize bleeding and 8 patients required blood transfusion.

Key words: Total Hip Arthroplasty (THA); Direct Lateral Approach (DLA); Direct Anterior Approach (DAA); Posterior Approach (PA); Antero Lateral Approach (ALA); Harris Hip Approach (HHS); Visual analogue Scale (VAS)

© 2021 The Author(s). Published by ACT Publishing Group Ltd. All rights reserved.

Pandey AK, Diako S, Kabongo JM. Modified Direct Lateral Approach Total Hip Arthroplasty With Good Functional Outcomes and Low Complication Rates: A Prospective Study of 450 Patients for 6 Years of Follow up. *International Journal of Orthopaedics* 2021; 8(6): 1573-1579 Available from: URL: <http://www.ghrnet.org/index.php/ijo/article/view/3244>

INTRODUCTION

Total hip arthroplasty (THA) is the most effective surgical approach for reducing pain and preserving function in heavily degraded joints as well as intra capsular fracture neck femur in more than 50 years of age group. Hip replacement surgery is one of the most successful operations in all of medicine. Since the early 1960s, improvements in joint replacement surgical techniques and technology have greatly increased the effectiveness of total hip replacement. According to the

Agency for Healthcare Research and Quality, more than 450,000 total hip replacements are performed each year in the United States (AAOS).

The success rate for this surgery is high, with greater than 95% of patients experiencing relief from hip pain. The success rate of hip replacements 10 years after surgery is 90- 95% and at 20 years 80- 85% (HSS.edu). The procedure can be performed using a variety of surgical approaches, but the posterior approach, direct lateral approach, and direct anterior approach are by far the most common across the globe. Each approach has its own unique advantages and disadvantages, but all can be safely and successfully utilized for THA. Strong, convincing, high-quality studies comparing the different approaches are lacking currently. Surgeons are therefore recommended to choose whichever approach they are most comfortable and experienced using^[1].

Commonly used surgical approaches for THA include the lateral, posterior and anterior approaches. The lateral approach involves surgical release and repair of the abductor musculature. The potential functional implications of violating the abductors are unclear but may negatively impact gait mechanics, including a Trendelenburg gait or a compensatory contralateral pelvic tilt. Conversely, the posterior approach involves release and repair of the short external rotators, which can result in changes to rotatory kinetics. Finally, the anterior approach uses an internervous plane between sartorius and tensor fascia latae that attempts to spare the surrounding hip musculature. The presumed advantage of this approach is avoiding the deficits seen with the lateral and posterior approaches. However, cadaveric studies have suggested that abductor muscle damage is observed during a THA using an anterior approach, and surgical releases (i.e., piriformis, tensor fascia latae) are sometimes required to improve exposure during preparation of the femur and acetabulum^[2]. Modified Hardinge approach offers good visualization of the acetabulum, facilitating optimal cup positioning as well as excellent stability of

the total hip joint^[3].

In one study, modified direct lateral approach significantly reduced THA dislocation rate^[4]. The available evidence suggests that DAA may be associated with better early postoperative functional rehabilitation, lower levels of perceived pain, and shorter hospitalization time. On the other hand, DAA may be associated with longer surgery time. The two arthroplasty approaches appear to be associated with similar rates of perioperative surgical complications and transfusion, similar results on radiographic and gait analyses, and similar serum levels of inflammation and muscle damage markers. The available evidence does not allow to determine whether DAA or the lateral approach is superior; more large, well-designed studies are needed to explore the results of this meta-analysis in greater detail^[5].

According to Daniel et al “Patients Reported Outcomes 6 months following THA dramatically improved regardless of the plane of surgical approach, suggesting that choice of surgical approach can be left to the discretion of surgeons and patients without fear of differential early outcomes”^[6].

No case for superiority of one approach over the other can be made, except for the reduction in postoperative Trendelenburg test-positive patients using the direct anterior approach compared with when using the direct lateral approach. Irrespective of approach, patients with a positive Trendelenburg test had clinically worse scores than those with a negative test, indicating the importance of ensuring good abductor function when performing THA. The direct anterior approach was associated with nerve injuries that were not seen in the group treated with the lateral approach^[7].

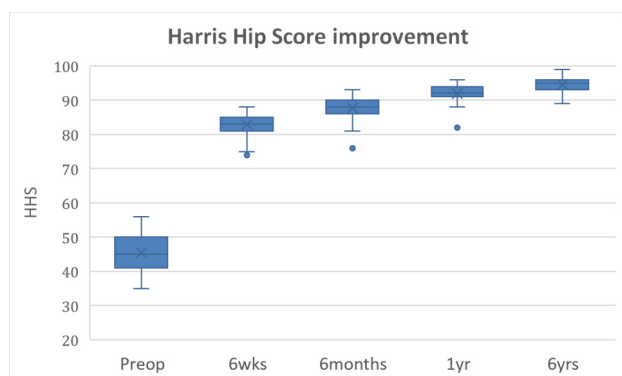


Figure 1 Box Plot shows markedly improving HHS postoperatively.

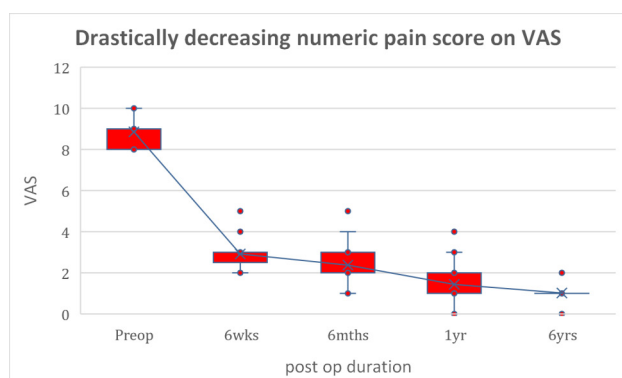


Figure 2 Box Plot showing drastic postoperative improvement in pain on Visual Analogue Scale.

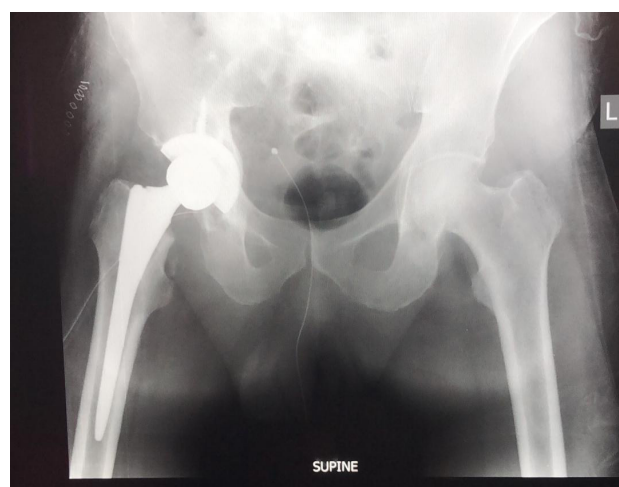


Figure 3 Post op THA 1.

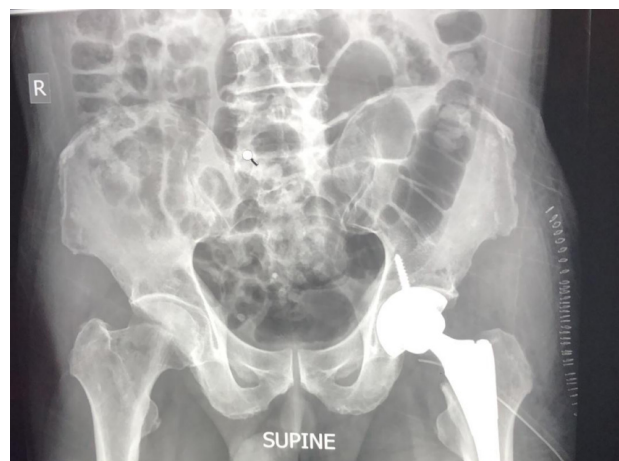


Figure 4 Post op THA 2.

Table 1 Pre-operative and Post-operative HHS and VAS.

	Pre-op	Post-op 6 weeks	Post-op 6 months	Post-op 1 Year	Post-op 6 Years
Mean HHS,	45.33	82.83	87.81	91.92	94.52
SD	5.43	3.12	3.15	3	2.06
CI (95%)	(43.67-46.71)	(82.01-83.64)	(86.99-88.63)	(91.13-92.69)	(93.93-95.10)
Mean VAS,	8.85	2.92	2.37	1.42	1.5
SD	0.73	0.7	0.83 (2.15-2.58)	0.77	0.71
CI (95%)	(9.04-8.66)	(2.73-3.09)		(1.22-1.62)	(0.84-1.19)

Table 2 Intraoperative and postoperative Complications.

Complications	Age/Sex	N.	POD	Interventions	Duration	Course	Outcome	%
DVT, PE	77Y/F	1	2	ICU	3	Respiratory arrest, Ventilator	Death	0.22
Infection	56Y/M	1	5	Debridement +Liner exchange+ Vacuum dressing+Antibiotics	4 weeks	Wound Dry, Swab negative	Painless joint at 6 weeks, discharge home	0.22
Fractures	56Y/M 67Y/M	2						0.44
Dislocation	58Y/M	1						0.22
LLD	58Y/M	1		Orthopedic shoes		10 mm		0.22
Limping Trendelenburg gait	84Y/M	1						0.22
Readmission within 30 days		2						0.44
Blood Transfusion		8						1.78
Aseptic Loosening								Nil

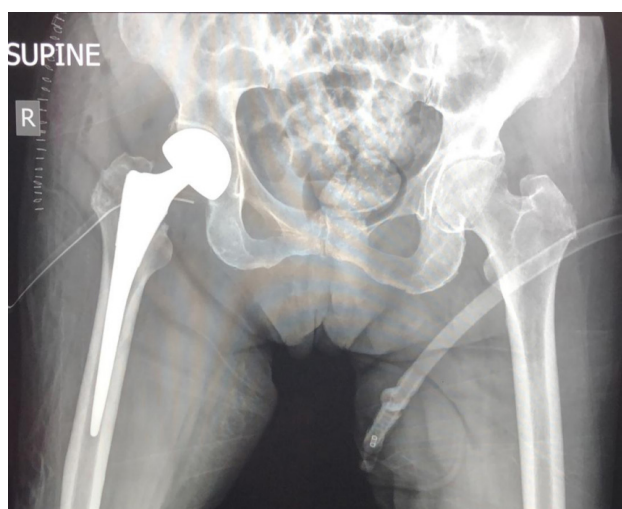

Figure 5 Post op THA 3.

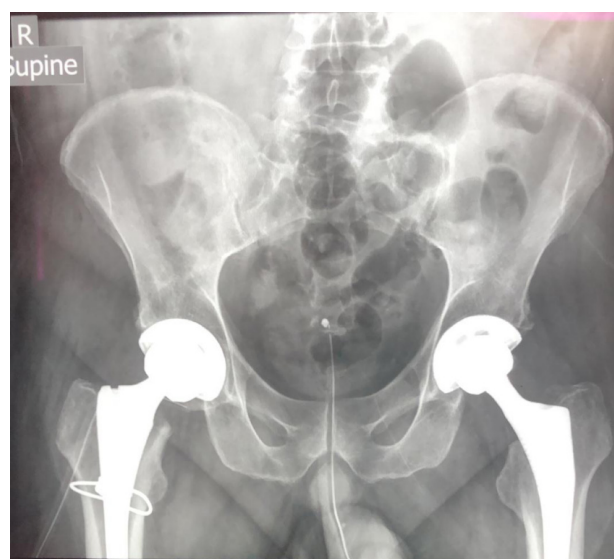


Figure 7 Post op Bilateral THA with right trochanteric cable for intraoperative undisplaced stable Trochanteric fracture.

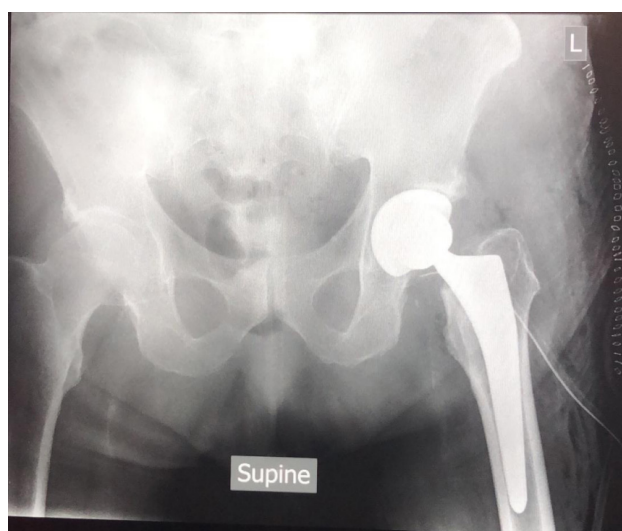

Figure 6 Post op THA 4.

Due to lack of convincing evidence about superiority of any approach in the literatures, we decided to randomly select and follow our 450 direct lateral approach cementless THA prospectively for 6 years. We assessed them clinically and radiologically at 6 weeks, 6 months, 1 year and 6 years. We found good functional outcomes on HHS and low complication rates like previously reported published data.

METHODS

Patients' information

After taking hospital ethics committee approval for the study, we followed 450 patients who underwent primary total hip replacement between 2010 to 2019. Data included both male and female population, age group ranging from 45 to 90 years, with primary degenerative OA, secondary OA due to trauma, AVN Femoral head,

& neglected DDH, as well as fracture Neck Femur. All patients were operated without navigation with preoperative templating and intraoperative visual guide tools to optimize implants size, cup inclination, anteversion, offset and leg length.

Preoperative evaluation

They all had thorough Preoperative radiographic, Pre-anesthetic and comorbidities evaluation before booked in theatre list. Preoperative templating was performed to determine leg length discrepancies, Acetabular COR, Femoral Head COR, Neck Osteotomy site, approximate cup and stem sizes. All of our patients received low molecular weight heparin as per standard international protocol for prevention of DVT and PE. Most of the patients received intraoperative antifibrinolytic drug (Tranexamic acid -Cyklokapron) to minimize blood loss and blood transfusion.

Surgical Techniques

Most of the patients were given regional anesthesia except few, who were deemed unfit for regional anesthesia and general anesthesia was administered. All operations were performed in lateral decubitus position with sacral and pubic symphysis post support to stabilize pelvis. Patients were secured at shoulder to ensure pelvis and shoulder remain at the same level and parallel to the floor throughout the surgery in order to have proper intraoperative assessment of cup inclination & anteversion angles to avoid cup malpositioning. Operative hip and knee joints were flexed between 40-50 degrees. All the bony prominences were well padded.

Direct Lateral surgical approach mini skin incision (8-10 cm) centered on the Greater Trochanter Tip, Tensor Fasciae Latae was incised and Vasogluteal musculotendinous complex was exposed. Charnley's retractor was placed for optimal exposure of the operative field. With the help of monopolar diathermy Vasogluteal musculotendinous complex curvilinear, shallow inverted U-shaped split was made from gluteal tubercle in the direction of their muscle fibers at the junction of anterior one fourth and posterior three fourth. Utmost care was taken to limit proximal extent of the Gluteal Medius Muscle split within 3 cm from tip of the Greater Trochanter to avoid superior gluteal nerve injury, which is situated approximately 5 cm superior to GTT between Gluteus Medius and Gluteus Minimus Muscles. We ensured thick musculotendinous anterior flap elevation from anterior Trochanteric surface for proper suturing and closure at the end of the procedure and making drill holes suturing for very thin fragile flap for stronger and secured bone to tendon healing. Gluteal Minimus was also split and released in the same direction and anterior capsulotomy with capsulectomy performed in the direction of Neck Femur towards Acetabulum, in inverted T fashion. Hohmann retractors were placed along superior and inferior aspects of Neck Femur. Neck osteotomy was performed at the preoperatively measured level, either after dislocating the joint or in-situ depending upon the ease of procedure. Steinmann pin was inserted on supraacetabular region of strong iliac bone and East-West retractor was applied from Steinmann pin superiorly to Neck osteotomy site inferiorly for better exposure and Acetabular preparation. Hohmann retractors were applied on anterior, posterior and inferior Acetabular margins. Transverse Acetabular Ligament was well exposed for the reference of intraoperative cup positioning. Acetabular reaming, preparation, trialing and implantation were done in neutral leg position. Femur was levered out of the wound by adduction, flexion and external rotation maneuvers with leg hanging down in the sterile bag and patella facing upwards. Femoral preparation was started with box chisel, reamers and broaches. Trialing was done with last

well-fitting Femoral broach and trial head. Joint stability, mobility without impingement and leg length equalization were ascertained. Intraoperative leg length equalization was determined by Knee to Heel matching during prosthesis trial and suture length techniques, by stitching one marked fixed point at supra-acetabular region and other on Greater trochanteric point. Final femoral stem & head were inserted and hip joint was reduced.

Adequate emphasis was given for the repair of Vasogluteal flap with PDS.

Advantages

This modified direct lateral mini-incision surgical approach THA has comparable operative time to other commonly described approaches with significantly less blood loss and blood transfusion requirements. It provides excellent unobstructed exposures of acetabulum and Femur for proper preparation, reaming and implant positioning. This surgical technique has extremely low risk of dislocation, implants malpositioning and impingement. Patients encountered mild to moderate grade postoperative pain, which could well managed with commonly used NSAIDs post operation. Most of the patients in our series managed to stand and walk full wt. bearing within 12 hrs. after operation.

Disadvantages

Abductor split, and superior gluteal nerve damage are the two well known disadvantages of direct lateral THA, which can be minimized significantly with careful identification of anatomical landmarks, limiting superior Abductor split level within 3-5 cm from Greater Trochanter tip and proper closure of vasogluteal flap with reinforcing sutures from Greater Trochanter drill holes.

Indications

Primary degenerative OA Hip, Secondary OA Hip joint due to AVN, DDH and Trauma, Fracture Neck Femur and Revision THA.

Contraindication

Neuromuscular or post-surgical Abductor insufficiency.

Post-operative course

All patients mobilized within 12 hrs. after operation, starting with on bed rehabilitation to FWB standing and walking with walking frame /crutches. Patients were advised to discard supports after attaining proper balance during walking. Most of our patients were discharged 2-3 days post-operatively after first wound dressing and attached to rehabilitation & post op wound care out-patient clinic for further rehabilitation and suture removal. All patients were followed up at 6 weeks, 6 months, 1 years and 6 years. Follow up functional outcome was measured on HHS; pain was measured on VAS. X-Ray was done at immediate post op and at each follow up time. Cup abduction angle was measured on AP view pelvis by angle between inter teardrop line and tangential line passing through open face of cup. Cup inclination angle was measured by Woo & Morey as well as Ischilolateral methods.

RESULTS AND DISCUSSION

We followed 450 patients prospectively, who underwent cementless THA between 2013 to 2019. 310 male patients with unilateral uncemented THA, 5 male patients with bilateral uncemented THA and 130 female patients with uncemented THA with age group ranging from 48 years to 88 years were included in the study.

XLSTAT and R studio software were used for statistical analysis. Mean age 65.78 years and SD 8.53, CI (67.99-63.58).

Pre-op HHS mean was 45.33, SD 5.43, which improved significantly postoperatively to 82.83, SD 3.12 at 6 weeks, 87.81. SD 3.15 at 6 months, 91.92, SD 3.00 at 1 year and 94.52, SD 2.06 at 6 years.

Hip pain was measured on Visual Analogue Scale (VAS). Mean Preop VAS was 8.85, SD 0.73 which reduced drastically, as measured on VAS, postoperatively to 2.92, SD 0.83 at 6 weeks, 2.37 SD 0.83 at 6 months, 1.42 SD 0.77 at 1 year, 1.50 SD 0.71.

We encountered total 7 complications among 450 patients operated by this uniquely modified mini-incision direct lateral THA. The overall complication rate in our series was 1.56%.

There were 1 septic complication (0.22%), 1 DVT / PE complication leading to death on postoperative day 2 (0.22%), 1 dislocation (0.22%), 2 intraoperative un-displaced trochanteric fracture (0.44%), 1 limb length discrepancy (0.22%), 1 limping with Trendelenburg gait (0.22%), 2 readmissions within 30 days (0.44%) and 8 blood transfusion (1.78%), 77 years female patient with fracture neck femur without major comorbidities was operated on admission day 3. She was on low molecular weight heparin as per international arthroplasty protocol, but she developed DVT /PE as confirmed by limb vessels colored doppler sonography and CT PA, admitted in ICU, intubated and put on ventilator due to respiratory failure but she succumbed on postoperative day 2.

56 years male patient with fracture neck femur whose THA was performed after 1 week due to some logistic problems developed wound drainage on post op day 5. He was taken to operation theatre and debrided thoroughly with polyethylene liner change and put on suppressive antibiotics for 6 weeks according to pus swab culture and sensitivity reports. We also applied vacuum drain for 3 weeks post operatively for more efficient wound drainage to avoid any potential space and collection. Infection got settled out after 4 weeks without any seropurulent wound drainage. He walked home with dry painless hip at 4 weeks with sterile swab results and decreased inflammatory markers.

We had 2 intraoperative un-displaced unicortical incomplete stable peri trochanteric fracture which we immediately noticed during final hard blows of femoral stem insertion. In both cases femoral stem stability and positioning were unaltered. We realized that it was preventable. We managed it with reinforcing cable wires. It did not affect physiotherapy protocol and they both were mobilized PWB with crutches on postop day- 2 and FWB from 4 weeks onwards. There was no significant difference on pain score and analgesics dosages as compared to other THA patients without complications. Fractures were not appreciated on post op x-ray and healed uneventfully.

One 58 years old male patient who had bilateral staged THA, developed posterior dislocation Right hip on 2nd post op day which was managed with closed reduction under sedation and skin traction for 2 weeks. He was mobilized after 2 weeks with FWB. He underwent Left THA after 6 weeks without any post-operative issues. We had 1 significant limb length discrepancy (10mm) in the series which was managed with Orthopedic shoe raise. It was probably due to incorrect neck osteotomy and improper visualization guide for limb length equalization during trial and final implantation.

One 84 years old male patient with history of lumbar fusion had a fall with fracture neck femur. He was known hypertensive, diabetic and CKD patient on chronic medication, his comorbid conditions were well controlled. He was operated within 24 hrs. of injury. Uncemented THA was performed without perioperative complications. He had slow early rehabilitation and prolonged

painful limping with Trendelenburg gait. At 6 weeks postop Xray implants positioning was within expected range of acetabular cup anteverision and inclination without varus placement of femoral stem. We ordered Lumbar spine and focused hip MRI to assess preexisting spinal pathology and iatrogenic superior gluteal nerve injury.

Radiologist reported severe degenerative spinal stenosis with radiculopathy L4-L5 nerve root compression without superior gluteal nerve injury. His Trendelenburg gait could be attributed largely to spinal radiculopathy and to a lesser extent to abductor muscles damage intraoperatively.

There were 2 brief hospital readmissions within 30 days postop period for nonspecific reasons. Both were discharged without any major interventions and post discharge course was uneventful.

In our series 8 patients received blood transfusion during perioperative period due to dropping hemoglobin with subsequent optimization of Hemoglobin level.

Xray did not show signs of aseptic loosening in any patient throughout their follow up.

The difference between preop HHS and post op HHS at 6 weeks as well as preop VAS and postop VAS were clinically as well as statistically significant ($p < 0.05$) as measured by t-Test Paired Two Sample for Means.

Restoration of normal hip biomechanics is a key goal of total hip arthroplasty (THA) which favorably affects functional recovery.⁸ Because neither direct lateral approach nor posterior approach is truly muscle sparing, one major concern often cited against them is muscle damage. Each requires the splitting and release of some muscle: Gluteus maximus and external rotators during posterior approach, gluteus medius, and minimus during direct lateral approach¹¹. Eight studies reported the occurrence of 7 types of perioperative surgical complications and meta-analysis showed that both direct anterior approach and the lateral approach were associated with similar risk of dislocation, intraoperative fracture, nerve palsy, superficial infection, deep infection, and postoperative hematoma⁵. Konyves et al in their study reported mean limb length discrepancy after the posterior approach 1.2 mm and after the direct lateral 6 mm. Templating made no significant difference to limb length discrepancy. They found no significant difference in the Oxford Hip Score between the posterior and other approaches after 3 months and after 12 months of follow up⁹.

Though our study is not a comparative one, we found quite similar functional outcomes and complication rates through modified direct lateral THA as reported in various literatures.

Layson et al found no significant difference between leg length and offset with the use of intraoperative fluoroscopy with direct anterior (DAA) approach compared to no intraoperative imaging with anterolateral (ALA) approach. They quoted that DAA, and ALA are equally effective approaches for re-establishing symmetric leg length and offset in hemi hip arthroplasty (HHA) for femoral neck fractures. In his study, the ALA had a shorter surgical time compared to DAA, potentially due to the utilization of intraoperative fluoroscopy for this technique during the DAA¹⁰.

Another review by BD.M et al concluded that modified direct lateral approach has greatly diminished the potentially devastating complication of postoperative instability and is associated with an acceptable level and severity of limp and heterotopic ossification. The approach provides excellent exposure in primary total hip arthroplasty to allow accurate placement of components in an efficient manner⁴.

We had one patient with 10 mm of leg lengthening. He reported dissatisfaction about the procedure. We addressed his concerns with

Shoe raise, and eventually he got improved. We need to follow up closely if he remains asymptomatic or develop further complications due to altered hip and spine biomechanics related to limb length discrepancy. Hofstede et al published that there is not enough evidence to draw succinct conclusions on preoperative predictors for postoperative outcome in THA, as results of studies are conflicting, and the methodological quality is low^[11].

Another study showed that short-term outcomes of THA through direct anterior approach (DAA) were overall better than THA through conventional approaches (CAs). Total hip arthroplasty through direct anterior approach had a shorter incision length, a tendency towards a lower pain VAS 1 day postoperatively and better early postoperative functional outcome than THA through CAs. The intraoperative blood loss showed indifferent results. THA through DAA had a longer operation time than THA through CAs^[12]. Our surgical time ranged from 60 to 100 minutes depending on severities and complexities of hip pathology.

In a study reported by Greidanus et al, they did not find superior functional outcomes after anterolateral THA compared to direct lateral and Posterolateral approaches in 135 patients with a minimum follow up of 24 months. Furthermore, they reported that muscle-sparing approach does not necessarily lead to a higher hip abductor strength one year post-operation. They highlighted the fact that there is still an ongoing debate in this context. There were few statistical differences and no clinically important differences in terms of validated or patients reported outcomes scores (including the HHS, OHS, 6MWD OR EQ-5D) between the direct lateral and the direct anterior approach at any time point^[7,13].

In one study by Jolles B et al found no significant difference between posterior and direct lateral surgical approaches was found. The presence of postoperative Trendelenburg gait was not significantly different between these surgical approaches. The risk of nerve palsy or injury was significantly higher among the direct lateral approach patients; (20%) versus (2%) for posterior approach patients. However, there were no significant differences when comparing this risk nerve by nerve for both approaches, in particular for the sciatic nerve. They quoted that quality and quantity of information extracted from the trials performed to date are insufficient to make any firm conclusion on the optimum choice of surgical approach in adult patients undergoing primary THA for OA^[14].

Sara C graves et al^[15] reported that with suitable experience, the direct-anterior approach can be performed with expected results like those of the posterior approach. There may be transient and small benefits to the direct-anterior approach, including improved physical function at 3 months after surgery. However, the greater operative blood loss and greater likelihood of blood transfusions, even when the surgeon is experienced, may be a disadvantage. They said that any benefits that accrue to the patients who had the direct-anterior approach would be transient and modest. Prospective randomized studies on the topic are needed to address the differences between surgical approaches more definitively.

Drew JM et al, rightly pointed out that those in favor of the posterolateral approach cite its utilitarian nature, familiarity, and technical reproducibility, while critics point to an increased risk of dislocation. Proponents of the direct lateral and anterolateral approaches most frequently cite extraordinary stability while disbelievers focus on the risk of persistent postoperative limp. In the face of largely inconclusive data to definitively support any one over another, an individual surgeon's preferred approach to THA therefore may be influenced by several subjective factors, including exposure during training, influence of mentors, and the balance of potential

risks and benefits that the available evidence has suggested may apply to each approach. Indeed, surgeons have come to appreciate the characteristic set of pros and cons reliably associated with each technique^[16].

CONCLUSION

In our case series, we randomly selected and prospectively followed 450 cohorts of THA patients, operated by modified direct lateral approach with relatively shorter skin incision. Utmost care was taken while making anterior third vasogluteal flap in continuity. In patients with fragile flap, thin wafer of Greater Trochanter was elevated for sturdy repair and faster healing. We strictly limited our proximal gluteal split up to 3-4 cm from Greater Trochanter tip to avoid iatrogenic superior gluteal nerve injury. Proper emphasis was given for strong vasogluteal flap repair. Our study showed good early and intermediate functional outcomes as measured on HHS and VAS at 6 weeks, 6 months, 1 year and 6 years follow ups and very low complication rates comparable to DAA and PA THA. Our impressive results might be due to modified vasogluteal split and meticulous repair techniques which we were very particular in all the cases. Other factors which might have affected overall results are excellent acetabular and femoral exposures which facilitated optimization of cup inclination and anteversions as well as femoral stem positioning and avoiding varus placement. As DAA THA has been evolving and many studies have shown excellent initial results in early functional recovery, ease of rehabilitation, decreased hospital stay and postoperative pain, some of the real challenges with this approach have not yet fully addressed. Data from direct anterior approach are still small and preliminary. Learning curve, LCFN & femoral nerve injuries and difficult exposures of femur leading to fracture and varus malpositioning of stem are the pertinent issues with DAA. Some of these problems could be avoided with navigation and robotic assisted THA but it's not widely available and only catering to tertiary level high volume institutions. Considering of all these limitations, we still have not reached to the point where superiority of one surgical approach over others can be established firmly. We recommend surgeons to continue with their most practical and comfortable approaches with regular modifications and polishing of shortcomings of traditional way, while at the same time try to adopt robotic assisted DAA in their surgical armamentarium.

Limitations of study

Main limitations of our study were small sample size and lack of comparison group Posterior THA or DAA THA.

Keywords and Abbreviations

Total Hip Arthroplasty (THA), Direct Lateral Approach (DLA), Direct Anterior Approach (DAA), Posterior Approach (PA), Antero Lateral Approach (ALA), Harris Hip Approach (HHS), Visual analogue Scale (VAS).

Acknowledgements

Authors convey their deep regards and thanks to State Hospital Oshakati & Welwitschia Medipark Hospital, Walvis Bay for providing all possible supports and logistics for smooth functioning of theaters during surgical procedures and overall patient managements.

Footnotes

Each author certifies that all the ethical principles of research were

followed, and informed consent was obtained from all the patients who participated in the study. No author received any kind of financial benefits to conduct this study.

REFERENCES

- Moretti VM, Post ZP. Surgical approaches for total hip arthroplasty. *Indian Journal of Orthopaedics*. 2017;51(4):368-376. [DOI: 10.4103/ORTHO.IJORTHO_317_16]; [PMID: 28790465]; [PMCID: PMC5525517]
- Petis S, Howard J, Lanting B, Jones I, Birmingham T, Vasarhelyi E. Comparing the anterior, posterior and lateral approach: Gait analysis in total hip arthroplasty. *Canadian Journal of Surgery*. 2018;61(1):50-57. [DOI: 10.1503/CJS.003217]; [PMCID: PMC5785289]; [PMID: 29368677]
- Goyal P, Lau A, McCalden R, Teeter MG, Howard JL, Lanting BA. Accuracy of the modified Hardinge approach in acetabular positioning. *Canadian Journal of Surgery*. 2016;59(4):247. doi:10.1503/CJS.011415; [PMID: 27240130]; [PMCID: PMC4961487]
- Mulliken BD, Rorabeck CH, Bourne RB, Nayak N. A modified direct lateral approach in total hip arthroplasty: a comprehensive review. *The Journal of arthroplasty*. 1998;13(7):737-747. [DOI: 10.1016/S0883-5403(98)90024-9]; [PMID: 9802658]
- Yue C, Kang P, Pei F. Comparison of direct anterior and lateral approaches in total hip arthroplasty: A systematic review and meta-analysis (PRISMA). *Medicine (United States)*. 2015;94(50). [DOI: 10.1097/MD.0000000000002126]; [PMID: 26683920]; [PMCID: PMC5058892]
- Finch DJ, Martin BI, Franklin PD, Magder LS, Pellegrini VD. Patient-Reported Outcomes Following Total Hip Arthroplasty: A Multicenter Comparison Based on Surgical Approaches. *Journal of Arthroplasty*. 2020;35(4):1029-1035.e3. [DOI: 10.1016/J.ARTH.2019.10.017]; [PMID: 31926776]; [PMCID: PMC8218222]
- Mjaaland KE, Kivle K, Svenningsens S, Nordsletten L. Do Postoperative Results Differ in a Randomized Trial Between a Direct Anterior and a Direct Lateral Approach in THA? *Clinical orthopaedics and related research*. 2019;477(1):145-155. [DOI: 10.1097/CORR.0000000000000439]; [PMID: 30179928]; [PMCID: PMC6345297]
- Flecher X, Ollivier M, Argenson JN. Lower limb length and offset in total hip arthroplasty. *Orthopaedics and Traumatology: Surgery and Research*. 2016;102(1): S9-S20. [DOI: 10.1016/J.OTSR.2015.11.001]; [PMID: 26797005]
- Konyves A, Bannister GC. The importance of leg length discrepancy after total hip arthroplasty. *Journal of Bone and Joint Surgery - Series B*. 2005;87(2):155-157. [DOI: 10.1302/0301-620X.87B2.14878]; [PMID: 15736733]
- Layson JT, Coon MS, Sharma R, Diedring B, Afsari A, Best B. Comparing Postoperative Leg Length Discrepancy and Femoral Offset Using Two Different Surgical Approaches for Hemiarthroplasty of the Hip. *Spartan Medical Research Journal*. 2021;6(2):2021. [DOI: 10.51894/001C.25096]; [PMID: 34532620]; [PMCID: PMC8405281]
- Hofstede SN, Gademan MGJ, Vliet Vlieland TPM, Nelissen RGHH, Marang-Van De Mheen PJ. Preoperative predictors for outcomes after total hip replacement in patients with osteoarthritis: A systematic review. *BMC Musculoskeletal Disorders*. 2016;17(1). [DOI: 10.1186/S12891-016-1070-3]; [PMID: 27184266]; [PMCID: PMC4869370]
- Lazaru P, Bueschges S, Ramadanov N. Direct anterior approach (DAA) vs. conventional approaches in total hip arthroplasty: A RCT meta-analysis with an overview of related meta-analyses. *PLOS ONE*. 2021;16(8): e0255888. [DOI: 10.1371/JOURNAL.PONE.0255888]; [PMID: 34428236]; [PMCID: PMC8384214]
- Fuchs M, Hein MA, Faschingbauer M, Sgroi M, Bieger R, Reichel H, Freitag T. Abductor Muscle Force after Straight-Stem Compared to Short-Stem Total Hip Arthroplasty through a Modified Direct Lateral Approach: Functional Assessment of 70 Consecutive Patients of a Randomized Controlled Clinical Trial. *Journal of Clinical Medicine*. 2021;10(6):1235. [DOI: 10.3390/JCM10061235]; [PMID: 33809713]; [PMCID: PMC8002373]
- Jolles B, Bogoch E. Posterior versus lateral surgical approach for total hip arthroplasty in adults with osteoarthritis. *Cochrane Database of Systematic Reviews*. Published online October 20, 2003. [DOI: 10.1002/14651858.CD003828.PUB2]; [PMID: 14974039]
- Graves SC, Dropkin BM, Keeney BJ, Lurie JD, Tomek IM. Does surgical approach affect patient-reported function after primary THA? *Clinical Orthopaedics and Related Research*. 2016;474(4):971-981. [DOI: 10.1007/s11999-015-4639-5]; [PMID: 26620966]; [PMCID: PMC4773324]
- Drew JM. CORR Insights®: Do Postoperative Results Differ in a Randomized Trial between a Direct Anterior and a Direct Lateral Approach in THA? *Clinical Orthopaedics and Related Research*. 2019;477(1):156-158. [DOI: 10.1097/CORR.0000000000000475]; [PMID: 30575615, PMC: 6345300]