

Bilateral Massive Trochanteric Gluteal Juxta Articular Tumoral Calcinosis in an Adolescent Girl: A Rare Case Report

Awadhesh Kumar Pandey¹, Suleyman Diako², Joseph Mwamba Kabongo³

1 Specialist Orthopaedic Surgeon, Welwitschia Medipark Hospital, Walvis Bay, Namibia;

2 Orthopaedic Resident, State Hospital Oshakati, Namibia;

3 Specialist Interventional Radiologist, Welwitschia Medipark Hospital, Walvis, Bay, Namibia.

Conflict-of-interest statement: The author(s) declare(s) that there is no conflict of interest regarding the publication of this paper.

Open-Access: This article is an open-access article which was selected by an in-house editor and fully peer-reviewed by external reviewers. It is distributed in accordance with the Creative Commons Attribution Non Commercial (CC BY-NC 4.0) license, which permits others to distribute, remix, adapt, build upon this work non-commercially, and license their derivative works on different terms, provided the original work is properly cited and the use is non-commercial. See: <http://creativecommons.org/licenses/by-nc/4.0/>

Correspondence to: Awadhesh Kumar Pandey, Specialist Orthopaedic Surgeon, Welwitschia Medipark Hospital, Walvis Bay, Namibia.

Email: awadheshkpandey6@gmail.com

Tele: +264 816803828

Received: November 30, 2021

Revised: December 8, 2021

Accepted: December 13 2021

Published online: December 28, 2021

ABSTRACT

Juxta articular heterotopic ossification is well known but poorly understood clinico-pathological entity. It is commonly encountered in pediatric patients with trauma around Elbow joints and adult population with pelvi-acetabular fractures, after pelvi-acetabular open reduction internal fixation procedures and hip arthroplasty. Primary, hereditary and secondary renal or parathyroid tumoral calcinosis is rare clinical condition which mimics any large extraarticular calcified mass and sarcomas. Tumoral calcinosis is generalized pathological process which is often misdiagnosed and being confused with commonly described post traumatic or post-surgical localized juxta articular heterotopic ossification or myositis ossificans. It has largely non traumatic origin and involve extensor surfaces of large joints.

The lesions are often multiple, bilateral, massive, well defined and lobulated cystic calcified mass. In contrast, heterotopic ossification or myositis ossificans is localized disease and caused by soft tissue trauma in the vicinity of joint, which usually present with ill-defined ossified soft tissue lesions and joint stiffness. Differential diagnosis of tumoral calcinosis includes heterotopic ossification or myositis ossificans, calcific tendinitis, calcific myonecrosis, synovial osteochondromas, gouty tophi, osteosarcomas and synovial sarcomas. In this case report we present a rare primary bilateral trochanteric gluteal Tumoral calcinosis with successful complete removal without recurrence for 3 years of continuous follow up.

Key words: Myositis Ossificans (MO); Tumoral calcinosis (TC); Heterotopic Ossification (HO)

© 2021 The Author(s). Published by ACT Publishing Group Ltd. All rights reserved.

Pandey AK, Diako S, Kabongo JM. Bilateral Massive Trochanteric Gluteal Juxta Articular Tumoral Calcinosis in an Adolescent Girl: A Rare Case Report. *International Journal of Orthopaedics* 2021; 8(6): 1580-1584 Available from: URL: <http://www.ghrnet.org/index.php/ijo/article/view/3245>

INTRODUCTION

Tumoral calcinosis (TC) is a rare clinical and histopathologic syndrome characterized by calcium salt deposition in different peri-articular soft tissue regions. It mainly manifests in childhood or adolescence as painless, firm, tumor-like masses around the joints that may lead to joint function limitations specially when large^[1].

Pathologically TC has multiple cystic lesions lined by giant cells, histiocytes and filled with white chalky calcified material. Although the pathogenesis of tumoral calcinosis is not known, repeated tissue injuries and inflammation seem to play a role in initiating the calcifying process. For example, hemorrhaging or fat necrosis can lead to fibrosis with chronic inflammation, followed by massive calcification^[2]. Tumoral calcinosis is a rare disorder manifests by large calcific periarticular masses. Associated bone destruction has been described previously only once. The radiographic and computed tomographic (CT) findings of bone erosion in a case of tumoral calcinosis in a renal dialysis patient are presented. Although the presence of bone destruction may suggest a neoplasm, it does

not exclude the diagnosis of tumoral calcinosis^[3]. The radiologist plays a critical role in avoiding unnecessary invasive procedures and in guiding the selection of appropriate tests that can result in a conclusive diagnosis of tumoral calcinosis^[4].

In patients with massive tumoral calcinosis, treatment should focus on the management of underlying problems, such as serum calcium or phosphate imbalances and hyperparathyroidism. Reports indicate that parathyroidectomy or renal transplantation has led to rapid resolution in some patients. Surgical excision of the mass can often relieve symptoms due to focal compression. However, because the recurrence rate is high, surgery is usually combined with phosphate deprivation and administration of acetazolamide for long-term control^[5]. Most common differential diagnosis of Tumoral Calcinosis is Heterotopic Ossification. Heterotopic Ossification (HO), also known as paraosteopathy, myositis ossificans, and heterotopic calcification among others, is a commonly occurring condition that refers to ectopic bone formation in soft tissues^[6]. Heterotopic ossification (HO) is a diverse pathologic process, defined as the formation of extra skeletal bone in muscle and soft tissues. HO can be conceptualized as a tissue repair process gone awry and is a common complication of trauma and surgery^[7].

CASE DESCRIPTION

We present a case of 11 years old, female child with bilateral, painful, massive nontraumatic trochanteric, gluteal mass for 6 months duration. Other orthopedics colleagues in the region previously saw this patient but they refrained to handle it because of horrific looking clinico radiological pictures and confusion to establish proper diagnosis before surgical intervention.

Patient presented with 6 months history of progressively increasing bilateral Trochanteric gluteal mass with sharp, severe pain (R>L) pain (SIQORA), non-radiating, aggravated by walking with significant limping and quite disabling.

Family, Drug and Past H/O were not significant. Examination of mass - 25×20 cm –Right side, 15×10 cm – left side, Gluteal, Trochanteric region, Warm, nontender, firm, well-defined, restricted mobility, skin pinchable, firm consistency, non-compressible, Non-Pulsatile, No visible dilated veins, No regional Lymphadenopathy.

We had following differential diagnosis in mind; Myositis Ossificans (MO), Synovial Osteochondromatosis, Synovial sarcoma, Osteosarcoma, Calcific myonecrosis.

Xray, CT scan and blood works were ordered. Provisional diagnosis of primary tumoral calcinosis was made based on high index of clinical suspicion, normal serum biochemical and inflammatory markers with peculiar radiological findings without bony erosions. Complete surgical excision was performed by direct lateral approach. Mass was observed immediately under fascia lata and attached to Greater Trochanter by thin cord of fibrous tissue. Gluteus Maximus, Gluteus Medius and Vastus Lateralis muscles were compressed and displaced with varying degrees. Right side larger lesion was excised first followed by left side after 1 month. Complete en-masse removal with surrounding thin cuff of fascia was performed bilaterally with minimal effect on normal anatomy of the region.

Intraoperative findings – multilobulated mass filled with chalky white and yellow viscous fluid attached with Greater Trochanter.

Surrounding Muscles were hyperemic and compressed with intact overall architecture. Surrounding bones were not involved. No Neurovascular infiltration was noticed.

Histopathological examination showed multiloculated

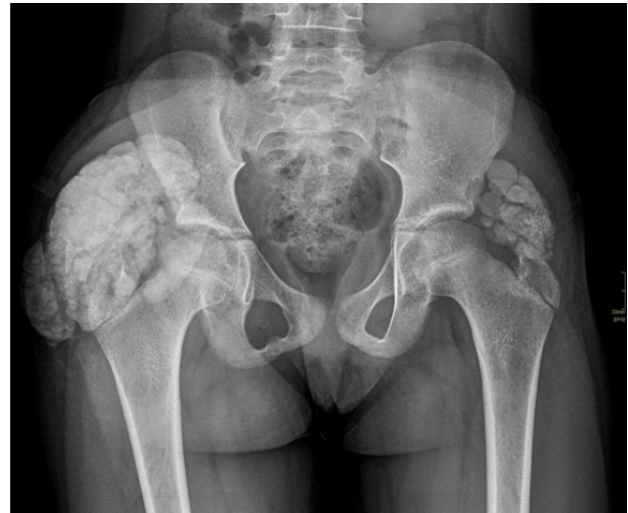

Figure 1 Preoperative Xray shows juxta articular bilateral Trochanteric lobulated, cystic, calcified mass.

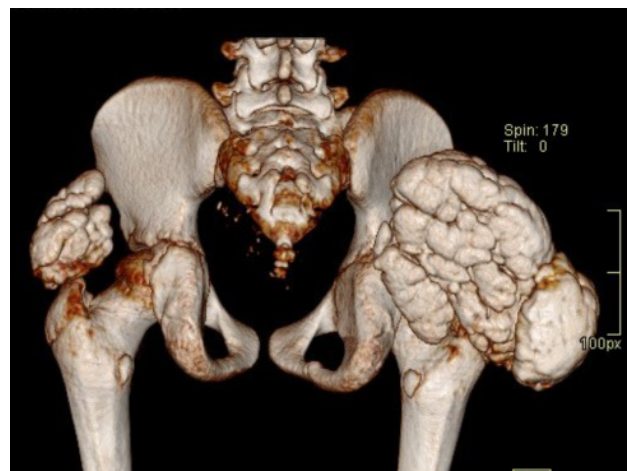

Figure 2 Preoperative 3D CT scan shows juxta articular bilateral Trochanteric lobulated, mass.

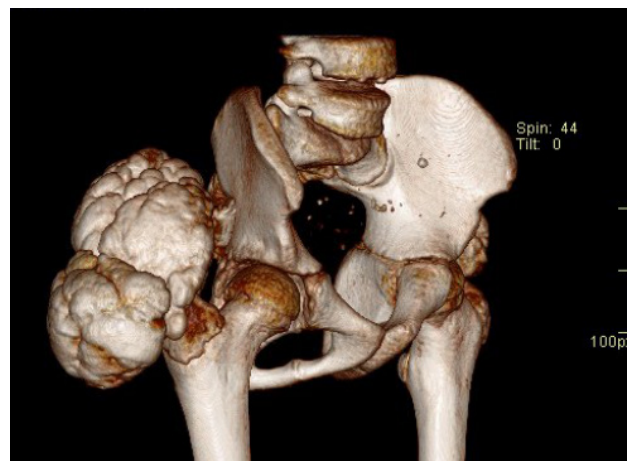


Figure 3 Preoperative 3D CT scan shows juxta articular bilateral Trochanteric lobulated, mass.

characteristic compartments containing liquid chalky white content together with calcifications. Pathological diagnosis of TUMORAL CALCINOSIS was established. Repeat serum biochemistry at 1 year follow up showed S. Calcium-2.19 mmol/L (normal range 2.23-2.58 mmol/L), S.Phosphate-1.78 mmol/L (normal range 0.78-1.53 mmol/L),S.Albumin-35 (normal range 36-51 gm/L),

Corrected Calcium-2.32 mmol/L (normal range 2.10-2.53 mmol/L), S.AL.P-353 (normal range 83-382 IU/L). Mild hypocalcemia and hyperphosphatemia were noticed. Patient was followed up for 3 years. No recurrence was observed clinically and radiologically.

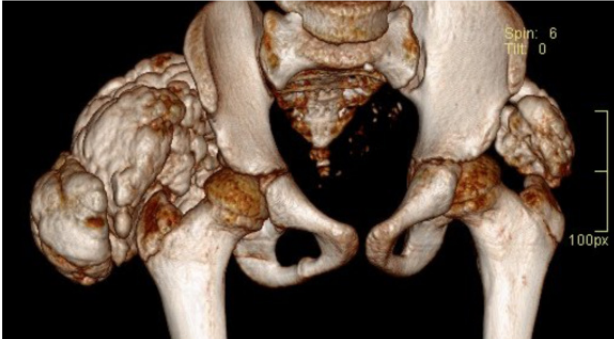

Figure 4 Preoperative 3D CT scan shows juxta articular bilateral Trochanteric lobulated, mass without bony infiltration.

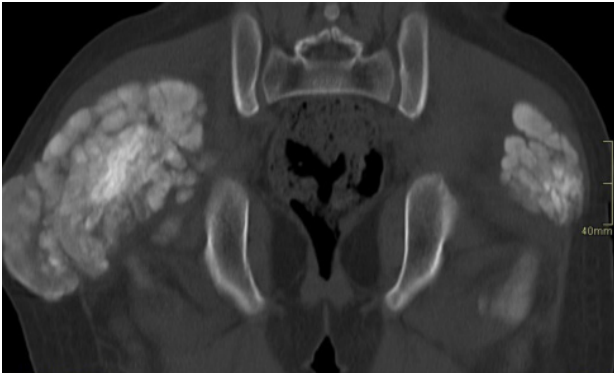


Figure 5 Preoperative CT scan shows juxta articular bilateral Trochanteric lobulated, amorphous, calcified mass with sedimentation sign.

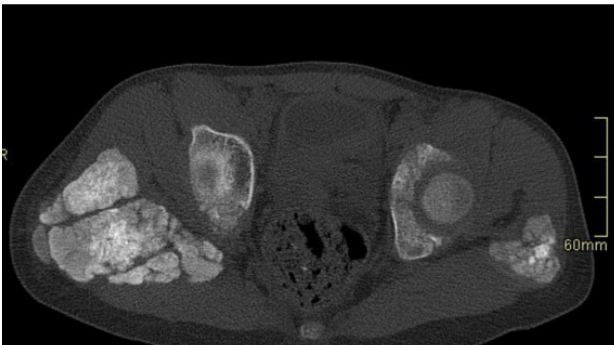


Figure 6 Preoperative CT scan shows juxta articular bilateral Trochanteric lobulated, amorphous, calcified mass with sedimentation sign.

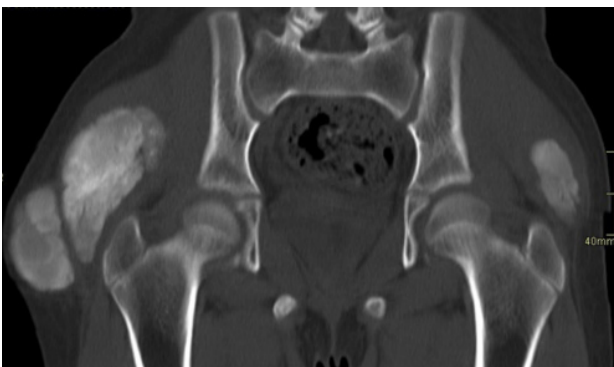

Figure 7 Preoperative CT scan shows juxta articular bilateral Trochanteric lobulated, cystic, calcified mass.

DISCUSSION

Tumoral calcinosis is a clinico pathological diagnosis characterized by massive nontraumatic subcutaneous periarticular multilobulated calcified lesion without dermatological or visceral involvements. It is broadly classified into primary and secondary types. It usually has normal serum calcium and phosphorus levels. It has long been misdiagnosed as myositis ossificans by Orthopedic surgeons because of similar clinical presentations, rare occurrence and very few literatures available on TC.

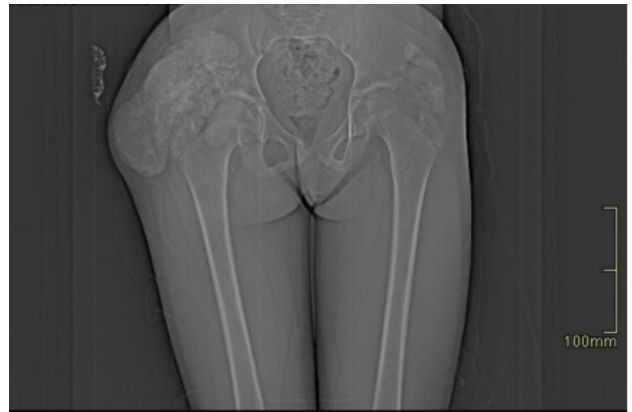

Figure 8 Preoperative CT scan shows juxta articular bilateral Trochanteric lobulated, cystic, calcified mass.

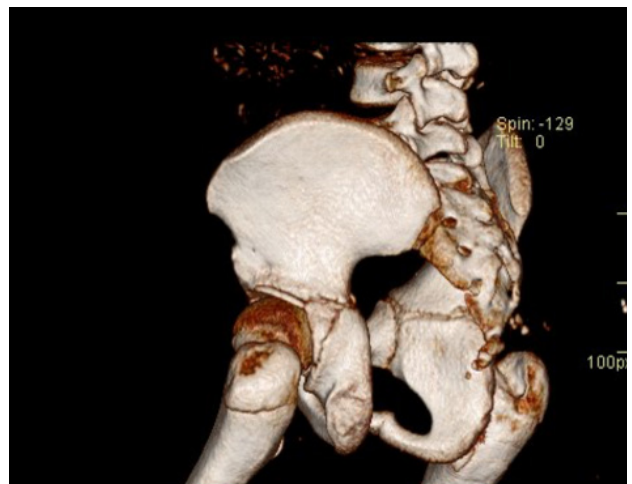

Figure 9 Post op CT scan after 1 year shows no recurrence.

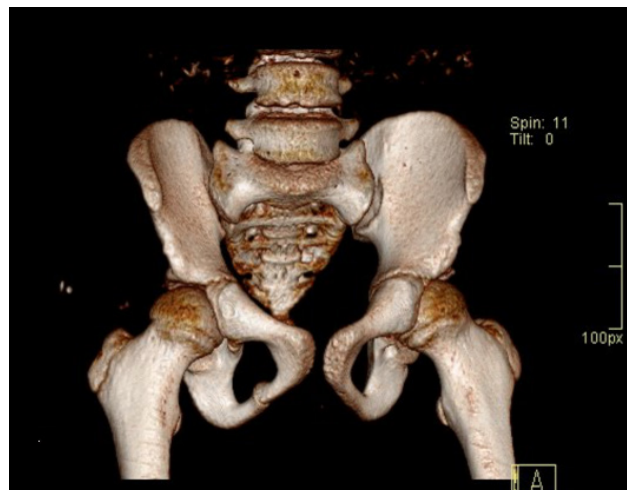


Figure 10 Post op CT scan after 1 year shows no recurrence.

Pathogenesis of Tumoral calcinosis is not well understood due to scarcity literature. It is commonly misdiagnosed as myositis ossificans. Tumoral calcinosis is clinico pathological diagnosis caused by generalized periarticular soft tissue calcium salt deposition. Basic pathology starts with disturbances in finely balanced intricate calcium and phosphate homeostasis in the body. Low Phosphate excretion leading to phosphate retention and calcium phosphate deposition in soft tissues is the chain of events in tumoral calcinosis formation. Lesions are multiloculated, cystic nature filled with white material formed by precipitation of calcium carbonate, calcium phosphate and calcium hydroxyapatite crystals. Tumoral calcinosis is broadly divided into 2 categories, primary genetic type and secondary, mainly due to chronic kidney disease. Primary Tumoral calcinosis can further be divided into primary normophosphatemic TC and primary hyperphosphatemic TC. It has inherent serum hyperphosphatemia state due to inherent decrease phosphate excretion and increase phosphate retention in the body. Secondary tumoral calcinosis is due to decrease phosphate excretion caused by deteriorating renal function and 2^o and 3^o hyperparathyroidism state leading to deranged calcium and phosphorus homeostasis. It can affect any age group with preponderance in 1st and 2nd decades of life with slightly more prevalent in females.

It takes several years to become clinically apparent lesions. TC usually presents with bilateral, nontender, firm, well defined large mass primarily affecting proximal joints like hips and shoulders, but other joints can also be involved including smaller joints of hands & feet, spinal and mandibular joints. It has chronic slowly progressive course.

Due to periarticular location and size of the lesion, TC can cause significant disfigurement, pain due to stretching and compression, joint dysfunction, limping and disability. Tumoral calcinosis classically does not infiltrate bones and neurovascular structures, the basis on which it can be differentiated from bony or soft tissue sarcomas. It can cause compressive neuropathy and vasculopathy. Clinicians should have high index of suspicion to correctly diagnose tumoral calcinosis particularly in pediatric patients with bilateral non traumatic large juxta articular subcutaneous masses after excluding other more commonly prevalent and easily diagnosable conditions like heterotopic ossification and sarcomas.

Imaging modalities for Tumoral calcinosis begins from plane Xray. It shows juxta-articular multilobulated, amorphous, cystic calcifications. CT scan provides further details, dimensions and relationship of lesions to neighboring bones. It can play vital roles in surgical planning. Lesions are generally cystic loculations with fluid levels with sedimentation sign. CT scan also differentiate Sarcomas from tumoral calcinosis based on bony infiltration and destruction which is typically absent in Tumoral Calcinosis.

MRI can be used to identify detailed soft tissue involvement and monitoring after surgical therapy to detect early recurrence before lesions are appreciated on CT or plane radiography. Bone scans can also be utilized to detect suspected multiple lesions in the body.

Biopsy of tumoral calcinosis shows peculiar multiple chalky white calcium filled compartments, which differentiates it from other common musculoskeletal lesions with ectopic calcifications.

All patients with suspected TC lesions should be evaluated for renal function tests, serum calcium, phosphorus, Alkaline Phosphatase, PTH and Vit D levels to rule out major renal and parathyroid pathology and to classify into primary or secondary TC.

Treatment of tumoral calcinosis depends on type, cause and clinical presentations.

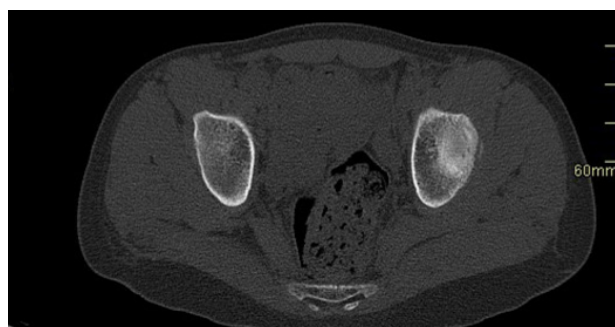

Figure 11 Post op CT scan after 1 year shows no recurrence.

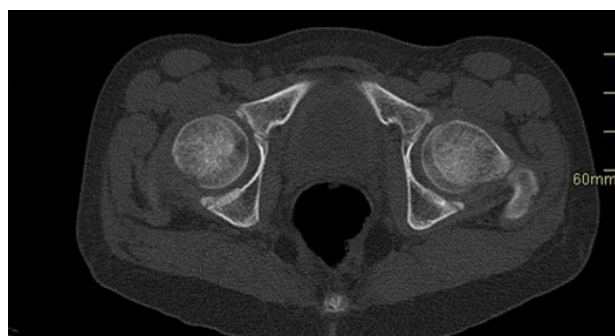

Figure 12 Post op CT scan after 1 year shows no recurrence.

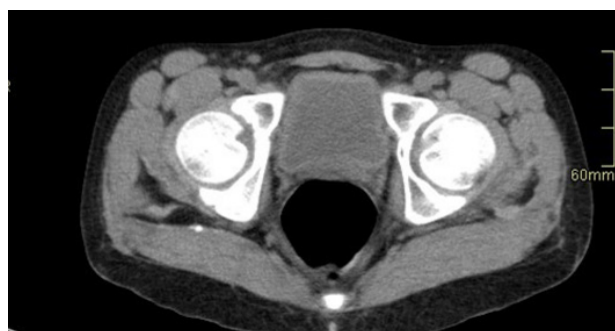

Figure 13 Post op CT scan after 1 year shows no recurrence.

In primary genetic tumoral calcinosis with significant functional impairments, pain, joint dysfunction, compressive symptoms, cosmetic disfigurement surgical resection is the mainstay of treatment. It can be supplemented with further medical treatment based on biochemical markers, especially serum phosphate level. Medical management can begin with dietary phosphate restrictions and oral Aluminum hydroxide phosphate binders to decrease phosphate absorption. Acetazolamide can also be used for increased renal phosphate excretion. Secondary tumoral calcinosis caused by chronic renal impairments is primarily managed by optimizing renal functions and deranged serum chemistry. Dietary restrictions of calcium and phosphate, bisphosphonate, dialysis, renal transplant can be advocated at various stage of renal dysfunctions. Parathyroidectomy can be considered in some resistant cases of secondary TC with Hyperparathyroidism.

Brief Summary of The Case

In this case report, an adolescent girl presented with gradually progressive painful bilateral Trochanteric Gluteal mass with significant cosmetic and functional impairments. After high level of clinical suspicion and radiological confirmation of the noninvasive nature of the lesion with normal blood work up. provisional diagnosis of primary tumoral calcinosis was made. Diagnosis

was further confirmed by Xray and CT scan. Successful complete surgical excision was performed. Histopathological diagnosis of Tumoral Calcinosis was established. Patient was regularly followed up for 1 year. She had excellent outcome cosmetically as well functionally. She did not report pain as well as limping. Blood Biochemistry at 1 year showed mild hypocalcemia and hyperphosphatemia which might be fitting to primary tumoral calcinosis diagnosis, which needs further long term follow up and evaluation to establish proper cause and medical intervention for prevention of recurrent lesions.

CONCLUSION

Diagnosis of tumoral calcinosis is typically based on high degree of clinical suspicion, radiological features and classical histopathological findings. Serum biochemistry should be done in all cases to evaluate renal function and calcium and phosphate levels. Management is based on types, pathological cause and clinical staging.

Conservative treatment is considered in early stages of disease, reserving surgical excision to patients with disabling symptoms as we did in this patient.

In secondary cases, medical treatment is mainstay. Treatment failure may warrant renal dialysis, transplantation and parathyroidectomy, surgical excision of the lesions should be reserved for failed conservative measures and disabling local symptoms.

REFERENCES

1. Fathi I, Sakr M. Review of tumoral calcinosis: A rare clinico-pathological entity. *World Journal of Clinical Cases*. 2014;2(9):409. [DOI: 10.12998/WJCC.V2.I9.409]; [PMCID: PMC4163761]
2. Chi D, Kamochi H, Sunaga A, et al. Tumoral calcinosis: A giant tumoral mass in the shoulder joint of a dialysis patient. *Plastic and Reconstructive Surgery - Global Open*. 2018;6(4). [DOI: 10.1097/GOX.0000000000001730]; [PMCID: PMC5977958]
3. Meltzer CC, Fishman EK, Scott WW. Tumoral calcinosis causing bone erosion in a renal dialysis patient. *Clinical Imaging*. 1992;16(1):49-51. [DOI: 10.1016/0899-7071(92)90091-M]; [PMID:1540864]
4. Olsen KM, Chew FS. Tumoral calcinosis: Pearls, polemics, and alternative possibilities. *Radiographics*. 2006;26(3):871-885. [DOI: 10.1148/RG.263055099]
5. Lai LA, Hsiao MY, Wu CH, Wang TG, Özçakar L. Big Gain, No Pain: Tumoral Calcinosis. Published online 2018. [DOI: 10.1016/j.amjmed.2017.09.003]; [PMID: 28923522]
6. Mujtaba B, Taher A, Fiala MJ, et al. Heterotopic Ossification: Radiological and Pathological Review. *Radiology and Oncology*. 2019;53(3):275. [DOI: 10.2478/RAON-2019-0039]; [PMID: 31553710]; [PMCID: PMC6765162]
7. Meyers C, Lisiecki J, Miller S, et al. Heterotopic Ossification: A Comprehensive Review. *JBMR Plus*. 2019;3(4). [DOI: 10.1002/JBM4.10172]; [PMID: 31044187]; [PMCID: PMC6478587]