

## Treatment of Osteochondral Lesions in the Ankle With a Particulated Juvenile Cartilage Allograft: Four-Year Outcomes

Aida Sarcon MD1\*, Christopher Kreulen MD2,3, J. Chris Coetzee MD 4,5, Steven Neufeld MD6, Gregory Berlet MD7, Paul Ryan MD8, Justin Robbins MD8,9, Robert Neher PhD10, Karim Boukhemis MD11, Lew Schon MD12,13, Eric Giza MD2,3

- 1 Mayo Clinic, Dept of Surgery, Rochester, MN, USA
- 2 University of California Davis Dept of Orthopaedic Surgery, Sacramento, CA, USA
- 3 University of California Davis Medical Center, Sacramento, CA, USA
- 4 Twin Cities Orthopedics, Edina, MN, USA
- 5 University of Minnesota, Cities Campus, Minneapolis, MN, USA
- 6 Orthopaedic Foot and Ankle Center of Washington, Falls Church, VA, USA
- 7 Orthopedic Foot and Ankle Center, Columbus, OH, USA
- 8 Tripler Army Medical Center, Honolulu, HI, USA
- 9 Madigan Army Medical Center, Tacoma, WA, USA
- 10 Zimmer Biomet, Warsaw, IN, USA
- 11 Scott Orthopedic Center, Huntington, WV, USA
- 12 Medstar Health Research Institute, Hyattsville, MD, USA
- 13 Union Memorial Hospital, Baltimore, MD, USA

**Open-Access:** This article is an open-access article which was selected by an in-house editor and fully peer-reviewed by external reviewers. It is distributed in accordance with the Creative Commons Attribution Non Commercial (CC BY-NC 4.0) license, which permits others to distribute, remix, adapt, build upon this work non-commercially, and license their derivative works on different terms, provided the original work is properly cited and the use is non-commercial. See: <http://creativecommons.org/licenses/by-nc/4.0/>

**Correspondence to:** Aida Sarcon, MD, Resident Physician, Dept. of Surgery, Mayo Clinic, 200 1st street SW, Rochester, MN 55904, USA.

**Email:** [aidasarcon@gmail.com](mailto:aidasarcon@gmail.com)

**Received:** March 4, 2022

**Revised:** April 2, 2022

**Accepted:** April 6 2022

**Published online:** May 6, 2022

### ABSTRACT

**PURPOSE:** This investigation reports mid-term clinical outcomes

after treating osteochondral lesions of the talus (OLTs) with a particulated juvenile cartilage allograft (PJCA). It was hypothesized that treatment of OLTs with PJCA would lead to significant improvement in pre to postoperative patient reported outcomes (PROMs).

**METHODS:** The study was a multicenter longitudinal prospective case series. Lesions were treated with a PJCA. Primary outcomes were pain, function, and activity levels. Clinical outcomes for 24 prospective subjects over 4-years are presented. The overall PROMs were analyzed using repeated measures models to account for patient visits over time and to control for variability between patients. Repeated measures analyses was used to assess effect of OLT size, operative technique, and prior ankle operations. PROMs, stratified by OLT size, was further analyzed to assess improvement by OLT size.

**RESULTS:** There was significant pre to postoperative improvement in the overall pain, Short-form 12 Health survey physical, Foot and Ankle Ability Measure activities of daily living, and Foot and Ankle Ability Measure sport ( $n = 22$ ) scores at 12, 24, 36, and 48-months ( $p < 0.05$ ). There were no significant pre to postoperative changes in the overall Short-form mental health scores ( $p > 0.05$ ). Lesions less than 150mm<sup>2</sup> predominantly achieved significant pre to postoperative improvement in scores over 48-months. Except for the sport scores at select visits, there were no differences in outcomes among postoperative visits ( $p > 0.05$ ). When the variables of OLT sizes, operative technique, and prior ankle operation were compared, repeated measures did not reveal any differences between these variables in effect on PROMs.

**CONCLUSIONS:** Four-year outcomes suggest that treatment with a PJCA led to improved function and pain levels without symptom worsening, and it is an effective operative intervention for symptomatic lesions irrespective of lesion size.

**Key words:** Osteochondral lesions; Talus; Particulated juvenile cartilage allograft; Biologics

**Level of Evidence:** IV, Case series

© 2022 The Author(s). Published by ACT Publishing Group Ltd. All rights reserved.

Sarcon A, Kreulen C, Coetzee JC, Neufeld S, Berlet G, Ryan P, Robbins J, Neher R, Boukhemis K, Schon L, Giza E. Treatment of Osteochondral Lesions in the Ankle With a Particulated Juvenile Cartilage Allograft: Four-Year Outcomes. *International Journal of Orthopaedics* 2022; **9(2)**: 1641-1647 Available from: URL: <http://www.ghrnet.org/index.php/ijo/article/view/3267>

## INTRODUCTION

There are many operative options for symptomatic OLTs. These include debridement, bone marrow stimulation (BMS), and osteochondral autograft/allograft transplantation (OAT), as well as restorative measures such as autologous chondrocyte implantation (ACI), autologous matrix-induced chondrogenesis, and matrix-induced autologous chondrocyte transplantation. Although BMS is considered a cost-effective first-line intervention, clinical success is limited with larger lesions<sup>[1,2,3]</sup>, and it results in formation of fibrocartilage which is less resilient than hyaline<sup>[4,5]</sup>. Reportedly, lesions greater than 150mm<sup>2</sup> often require alternative therapies<sup>[3]</sup>. An OAT is indicated for lesions greater than 15mm in diameter, and an osteochondral graft is usually harvested from the patient's knee or from a fresh talus allograft<sup>[5,6]</sup>. Although this provides the advantage of direct replacement with native cartilage from an asymptomatic site, it is highly technical, and accessing a normal joint is associated with donor site morbidity<sup>[5]</sup>. ACI has shown promising outcomes hyaline formation<sup>[4]</sup>, however it is a costly staged procedure with limited comparison studies<sup>[6]</sup>. Thus, there is a need for minimally invasive techniques with favorable repair response<sup>[7]</sup>.

Particulated juvenile cartilage allograft or PJCA (DeNovo® NT Natural Tissue; Zimmer Biomet, Warsaw, IN) is a restorative technique for OLTs. Viable cartilaginous pieces are obtained from juvenile donors as immature chondrocytes have greater regenerative capabilities than adult cells<sup>[8]</sup>. It is a single-staged procedure indicated for primary or revision symptomatic OLTs<sup>[9]</sup>. Kruse et al. published the first case detailing the arthroscopic delivery of PJCA for OLT, and noted the patient's pain and activity limitations completely resolved after 6-months<sup>[10]</sup>. More studies<sup>[7,11-20]</sup> have since been published, although middle to long-term prospective clinical outcomes are limited. The purpose of this study was to report mid-term clinical outcomes after treating OLTs with a PJCA. It was hypothesized that treatment of OLTs with PJCA would lead to significant improvement in pre to postoperative patient reported outcomes (PROMs).

## METHODS AND MATERIALS

### Design and Subjects

This was a longitudinal prospective multicenter, single-arm, cohort study. Institutional review board approval and informed consent were obtained. The study's inclusion criteria for prospective patients were (1) articular cartilage lesion(s) of the ankle for which arthroscopy or operation with PJCA was warranted, (2) voluntary consent, (3) stable health and operative candidate, (4) over the age of 18 years, and (5) willing and able to comply with postoperative rehabilitation and routine scheduled visits. The exclusion criteria were (1) high operative risk, (2) pregnant or breast feeding, (3) clinical diagnosed autoimmune disease, (4) active joint infection or history of chronic joint infection at operative site, (5) medical history that would make the subject unreliable for study, and (6) any combination of variables in the investigators' judgment that should exclude a potential subject.

The PJCA (DeNovo® NT; Zimmer Biomet, Warsaw, IN) is listed with the US Food and Drug Administration as a commercially

available product and is used as intended for articular cartilage repair. Subjects were prospectively evaluated at 6, 12, 18, 24, 36, 48, and 60-months postoperatively. The investigators are board certified orthopedic surgeons who specialize in foot and ankle operation. Experienced research personnel also assisted the study's procedures and subjects' rehabilitation under the direction of the investigators. Given the inherent post-market design of the study, an official enrollment number via power analysis was not identified; however, it was anticipated that a large number of subjects would participate. Yet, due to loss of funding and loss to follow up, the study was prematurely closed. Thus, this study reports clinical outcomes for 24 subjects (24 ankles) that had at least 4-year data. Subjects were treated prospectively between May 2011 to February 2013 by 8 surgeons at 5 study centers.

### Outcomes

Primary outcomes collected were pain, function, and activity levels. The PROMs were VAS pain (100 mm) score, Foot and Ankle Ability Measure (FAAM) Activity of Daily living (ADL) and FAAM-Sports subscales, and Short-Form 12v2 Health Survey (SF-12) physical and mental health subscales. The VAS measures pain intensity on a 100 mm visual scale ("0" indicates "no pain" and the maximum score of "100" indicates "the worst pain imaginable"). The FAAM-ADL and FAAM-Sports subscales were scored from "0" to "100". The SF-12 utilizes a more complex scoring algorithm, although the US population mean score is 50 (SD ± 10) for either subscale<sup>[21]</sup>. The postoperative ankle status was reported via a global satisfaction survey as either "improved", "same", "worse", or "intolerable".

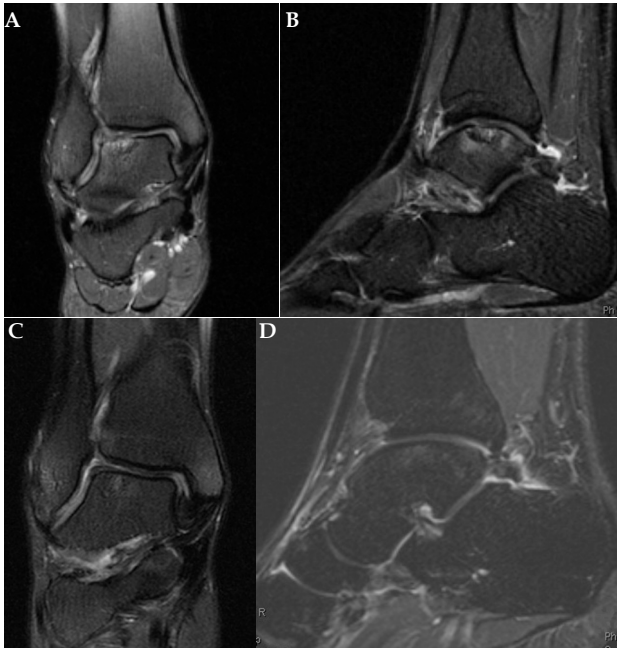
Lesions were characterized by Hepple Magnetic Resonance Imaging (MRI) stage<sup>[22]</sup> and International Cartilage Repair Society (ICRS) grade (Figure 1). The OLTs were sized using the lesions' anterior to posterior and medial to lateral measurements. The OLTs were defined as small (less than 50 mm<sup>2</sup>), medium (50 to 150 mm<sup>2</sup>), large (greater than 150 mm<sup>2</sup>). The number of concomitant procedures, lesion size by operative technique, and adverse events related to the PJCA were reported. Treatment failure was defined as greater than 50 % of PJCA requiring revision and ultimately the subject was withdrawn. Reoperation with either minimal chondroplasty (i.e.-debridement), partial (less than 50%) PJCA revision, or non-graft related intervention were still included in the study (Figure 2).

### Operative Technique

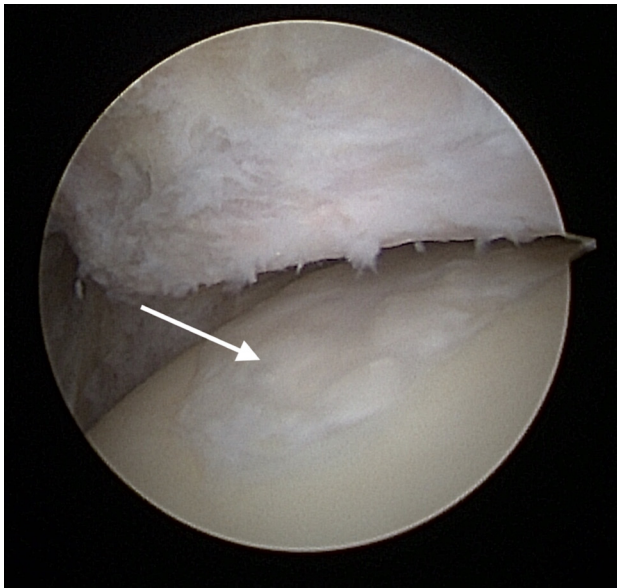
The procedure was performed open or arthroscopically. Traction was applied to the ankle if needed. A tibial plafondplasty was performed when necessary to visualize more posteriorly located lesions. Next, the lesion was curetted to create stable and vertical borders (Figure 3). All arthroscopic inflow was halted, and the lesion was dried via a suction device. Bone grafting of a cystic defect was performed at the discretion of the surgeon for lesions greater than 5mm deep. The DeNovo NT graft was loaded into a delivery cannula system, and fibrin was applied to the lesion's base. After one to two minutes, the PJCA was placed via cannula (Figure 4) or manually if with an open incision. The graft was distributed to cover the defect (Figure 5).

A minimum of 50% fill-volume was considered sufficient for repair as determined by the distributor. After several minutes, the lesion was covered with additional fibrin (attention to avoid a proud PJCA / fibrin construct). Once fully set, the ankle was gently ranged to contour the graft's surface. After final inspection and skin closure, a splint was applied to the operative limb.

The postoperative protocol was standardized. During the initial 6-weeks postoperatively, the patients were nonweightbearing. After



**Figure 1** A: preoperative coronal T2 MRI, demonstrating increased talar edema and a large lateral osteochondral defect. B: preoperative sagittal T2 MRI, demonstrating increased talar edema and a large lateral osteochondral defect. C: Two-year postoperative coronal T2 MRI, demonstrating intact particulate juvenile cartilage allograft with resolution of talar edema. D: Two-year postoperative sagittal T2 MRI, demonstrating intact particulate juvenile cartilage allograft with resolution of talar edema.

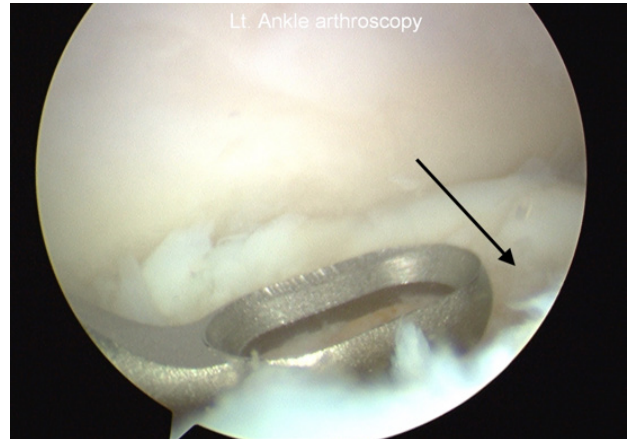


**Figure 2** Arthroscopic view of intact particulate juvenile cartilage allograft(white arrow) during a second-look arthroscopy performed at 18-months postoperatively (The patient returned to the operating room for anterior debridement due to soft tissue impingement).

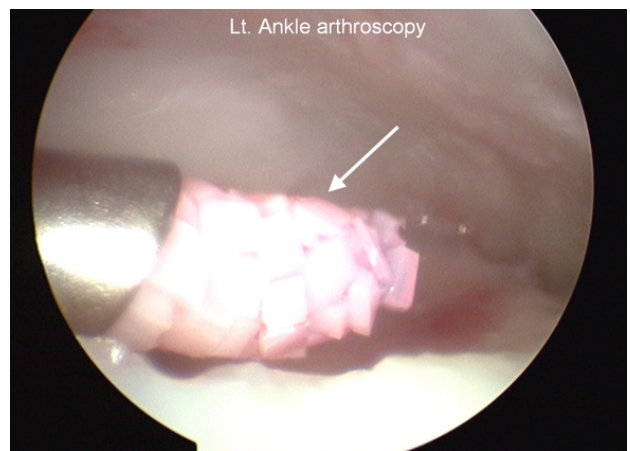
2-weeks, patients were encouraged to perform gentle range of motion exercises. At 6-weeks postoperatively, weightbearing activities were progressed as tolerated in a CAM boot. The boot was weaned by 6 to 12 weeks. Higher impact activities were allowed after 6-months.

**Statistical Analysis**

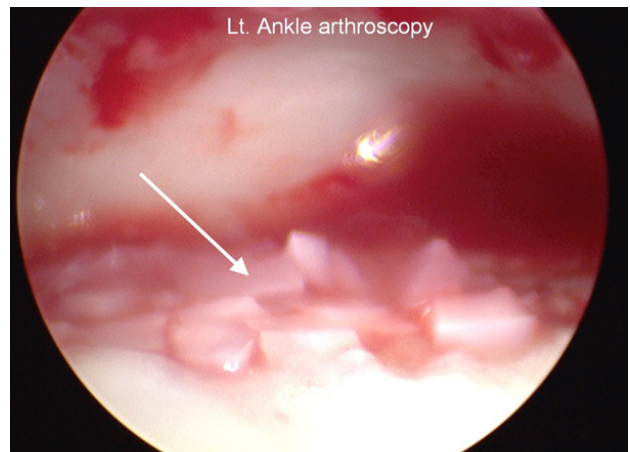
The SAS Software 9.4 (SAS Institute, Inc, Cary, NC) and Proc Mixed procedure used to perform repeated measures analyses on the overall PROMs to evaluate pre-to postoperative and between



**Figure 3** Arthroscopic view, curettage of osteochondral defect(black arrow) to create a stable and vertical border.



**Figure 4** Arthroscopic view, delivery of particulate juvenile cartilage allograft(white arrow) via cannula system.



**Figure 5** Arthroscopic view, particulate juvenile cartilage allograft(white arrow) placed onto the defect.

visit differences in means. The Anderson-Darling and Kolmogorov-Smirnov normality tests revealed normally distributed data. PROMs were further stratified by size and analyzed with repeated measures. The overall PROMs and PROMs by size were risk adjusted for age and concomitant procedures. The Fisher's exact test was applied to evaluate differences between lesion size and operative technique.

P values <0.05 were considered statistically significant and are unadjusted for multiplicity. Categorical variables are presented as counts and / or percentages, and continuous data as means, standard

deviations (SD), and range. The overall PROMs’ estimated mean at preoperative and postoperative visits are reported with P values using repeated measures analyses. Repeated measures analyses were used to also assess effect of OLT size, operative technique, and prior ankle operations differences on PROMs scores at different patient visits.

## RESULTS

A total of 205 subjects were treated. Of those, 167 attended the preoperative visit, 193 attended postoperative visits, and 157 attended both. The number of patients with evaluable preoperative scores at the respective visit are: 123 at the preoperative visit, 100 at the 6-month visit, 76 at 12-months, 62 at 18-months, 62 at 2-years, 39 at 3-years, and 24 at 4-years. The number of subjects lost to follow up and reasons are: 101 to site closure, 46 to no status provided, 27 to lost to follow up, 15 to treatment failure, six to withdrawal, three to unable to return, five to “not otherwise specified”, one to withdrawal by investigator, and one to death. Thus, this study focused on the results of the 24 subjects with at least 4-year evaluable data.

The patient demographics are listed in table 1. There were 24 subjects with 25 treated study lesions: 24 OLTs and one tibial lesion. One subject had two lesions, a tibial and an OLT (tibial lesion was excluded from analysis due to its small size). All (25/25) lesions were unilateral. Four subjects did not engage in preoperative exercise. Preoperatively, subjects were asked to report their ability to carry out daily activities in the past year; 17 out of 24 subjects were unable to carry out such activities with the average number of days being  $108.94 \pm 98.45$  (range, 5 to 365).

The OLT’s characteristics, number of concomitant procedures, and adverse events are listed on Table 2. Fifty-four percent (13/24) of the cases had prior ankle operation (i.e.- debridement, microfracture, subchondroplasty, and/or a combination of the procedures). One of 24 (4.2%) subjects received graft-related reoperation with minimal PJAC debridement within 6.8 months postoperatively for OLT of  $176.0 \text{ mm}^2$ ; this was not considered treatment failure by the present study’s definition. Ninety-two percent (22/24) of the patients had at least one concomitant procedure; synovectomy was performed most frequently at 75% (18/24), followed by soft tissue impingement resection at 16.7% (4/24), microfracture in 16.7% (4/24), osteophyte removal in 12.5% (3/24), and bone marrow aspiration in 8.3% (2/24). A number of other concomitant procedures occurred in just one patient.

The overall pre-to postoperative changes were significant, except for the SF-12 mental scores (Table 3). The FAAM-sport score significantly decreased between the 24 and 36-month visits, and later significantly increased between the 36 and 48-month visit; this led to similar scores at 24 and 48-months. At 48 months postoperatively, all (24/24) subjects reported “improved” on perceived ankle status on the global satisfaction survey.

Repeated measures analyses did not reveal any significant differences in PROMs by OLT size ( $p > 0.05$ ). Even though OLT size was not statistically significant in predicting outcomes, due to clinical interest and little research on OLT size, the results were stratified by size to explore size effect on outcomes. The PROMs by size are shown in Table 4. Except for data collected for FAAM Sport PROM, there were three small, 15 medium, and five large OLTs. Compared to preoperative scores, only small and medium sized OLTs achieved significant pain reduction and improvement in SF-12 physical scores at all visits. Large OLTs achieved a significant pre-to postoperative improvement in SF-12 physical score only at the 24-month visit. Only medium OLTs had a significant pre-to postoperative increase

Table 1 Patient demographics (n = 24).

Variable	Value
<b>Gender</b>	
F: M	16: 08
Age (Avg age years)	41.2 (range,19 to 63)
<b>Smoker</b>	
Current	1
Former	6
No	17
BMI (Avg Kg/m <sup>2</sup> )	28.5 ± 6.02 (range, 19.4 to 39.2)
<b>Laterality</b>	
Left: Right	9: 15
OLT Size (Avg area, n=23)	108.1 ± 60.0 mm <sup>2</sup> (range, 18.0 to 264.0)

Abbreviations: OLT, osteochondral lesions of the talus.

Table 2 OLT’s characteristics, adverse events, and number of concomitant procedures (n=24).

Variable	Value
Prior ankle operation(n=24)	13
<b>Operative technique(n=23)</b>	
Open	15
Arthroscopy	3
Extended portal	5
<b>Graft related Adverse events (n=17)</b>	
Ankle pain	9
Ankle swelling	2
Ankle stiffness	3
Other †	3
<b>Number of concomitant procedures(n=24)</b>	
None	2
One	9
Two	8
Three	2
Four	1
Five	2
<b>Hepple MRI Stage*</b>	
1	4.2% (1/24)
2A	12.5% (3/24)
2B	4.2% (1/24)
3	25% (6/24)
4	25% (6/24)
5	29.2% (7/24)
<b>ICRS Grade*</b>	
NA	4.2% (1/24)
2	4.2% (1/24)
3	25% (6/24)
4	66.7% (16/24)

Abbreviations: OLT, osteochondral lesions of the talus. NA, not available. ICRS, International Cartilage Repair Society grade. \* One subject had more than one treated study lesion, one on tibia and an OLT. The tibial lesion was classified as a Hepple Stage 2A and ICRS grade 4. † one had displacement of an osteochondral lesions fragment, one had joint clicking, & one sustained an ankle sprain

in SF-12 mental scores at 12 and 48-months. Small and medium OLTs achieved significant increase in FAAM-ADL scores at all visits compared to preoperative. Large OLTs achieved significant pre-to postoperative improvement of ADL at 12 and 24-month visits. Small OLTs had missing sport scores at 24 and 36-months, thus mean

**Table 3** The adjusted patient reported outcome estimated means  $\pm$  SE (95% confidence intervals) over 48 months.

PROM		n	Preop	Postop			
			12 months	24 months	36 months	48 months	
VAS pain (100mm)	24	42.7 $\pm$ 7.0	11.0 $\pm$ 6.9	10.7 $\pm$ 6.6	18.9 $\pm$ 8.4	7.5 $\pm$ 6.3	
		(28.4 to 57.1)	(-3.2 to 25.1) $p < 0.0001^a$	(-2.8 to 24.2) $p < 0.0001^a$	(1.7 to 36.1) $p < 0.0001^a$	(-5.6 to 20.5) $p < 0.0001^a$	
SF-12 physical	24	38.6 $\pm$ 2.2	51.0 $\pm$ 2.3	52.6 $\pm$ 2.4	50.8 $\pm$ 2.3	50.7 $\pm$ 2.3	
		(34.0 to 43.1)	(46.3 to 55.6) $p < 0.0001^a$	(47.6 to 57.5) $p < 0.0001^a$	(46.1 to 55.5) $p < 0.0001^a$	(46.0 to 55.4) $p < 0.0001^a$	
SF-mental	24	53.8 $\pm$ 3.2	56.5 $\pm$ 2.4	54.5 $\pm$ 2.6	57.4 $\pm$ 2.5	57.0 $\pm$ 2.5	
		(47.3 to 60.2)	(51.6 to 61.4)	(49.2 to 59.8)	(52.1 to 62.6)	(52.0 to 61.1)	
FAAM ADL	24	64.1 $\pm$ 4.6	91.2 $\pm$ 4.6	94.1 $\pm$ 4.0	91.7 $\pm$ 4.3	94.2 $\pm$ 4.1	
		(54.6 to 73.5)	(81.8 to 100.5), $p < 0.0001^a$	(85.7 to 102.4), $p < 0.0001^a$	(82.8 to 100.6), $p < 0.0001^a$	(85.7 to 102.6), $p < 0.0001^a$	
FAAM sport	22	28.5 $\pm$ 6.2	63.6 $\pm$ 8.1	72.5 $\pm$ 7.0	63.9 $\pm$ 8.1	75.5 $\pm$ 7.0	
		(15.7 to 41.3)	(47.0 to 80.3), $p < 0.0001^a$	(58.1 to 86.9), $p < 0.0001^a$	(47.3 to 80.5), $p < 0.0001^a$ , $p < 0.04^c$	(61.2 to 89.8), $p < 0.0001^a$ , $p < 0.02^d$	

Abbreviations: VAS, visual analog scale; SF-12, Short-Form 12 Health Survey; FAAM ADL, Foot and Ankle Ability Measure; ADL, activity of daily living score. a compared to preop; c compared to postop 24 months; d compared to postop 36 months.

**Table 4** The adjusted patient reported outcome estimated mean  $\pm$  SE (95% Confidence interval) by lesion size over 48 months. T-test p values are reported. ANOVA did not reveal statistical significant differences in outcomes when compared by size.

OLT Size		VAS	SF-12	SF-12	FAAM	FAAM
			Physical	Mental	ADL	Sport*
Small (n=3)	Preop	41.6 $\pm$ 16.4	28.0 $\pm$ 4.2	63.2 $\pm$ 4.7	58.2 $\pm$ 9.9	43.9 $\pm$ 16.5
		(1.5 to 81.7.0)	(18.0 to 37.9)	(51.9 to 74.4)	(34.9 to 81.6)	(-8.7 to 96.5)
	12 mo	5.3 $\pm$ 4.7	53.6 $\pm$ 4.2	55.9 $\pm$ 4.7	93.9 $\pm$ 9.9	66.4 $\pm$ 20.2
		(-6.3 to 16.9) $p = 0.038^a$	(43.6 to 63.6) $p < 0.004^a$	(44.7 to 67.1)	(70.6 to 117.3) $p < 0.04^a$	(2.0 to 130.7)
Medium (n=15)	24 mo	2.1 $\pm$ 1.1	56.8 $\pm$ 5.3	59.5 $\pm$ 5.9	100.0 $\pm$ 12.3	--†
		(-0.6 to 4.8) $p = 0.048^a$	(44.4 to 69.2) $p < 0.004^a$	(45.5 to 73.4)	(71.2 to 129.3) $p < 0.03^a$	
	36 mo	3.2 $\pm$ 1.5	53.9 $\pm$ 5.3	53.6 $\pm$ 5.9	99.0 $\pm$ 12.3	--†
		(-0.6 to 6.9) $p = 0.054^a$	(41.5 to 66.3) $p < 0.01^a$	(39.6 to 67.5)	(70.0 to 128.1) $p < 0.04^a$	
	48 mo	2.0 $\pm$ 0.9	56.2 $\pm$ 4.2	49.6 $\pm$ 4.7	94.7 $\pm$ 9.9	79.6 $\pm$ 20.2
		(-0.1 to 4.0) $p = 0.050^a$	(46.2 to 66.2) $p < 0.002^a$	(38.4 to 60.8)	(71.4 to 118.1) $p < 0.03^a$	(15.2 to 143.9)
Preop	47.2 $\pm$ 5.4	39.8 $\pm$ 1.7	50.4 $\pm$ 1.9	61.9 $\pm$ 2.5	25.9 $\pm$ 4.5	
	(36.4 to 57.9)	(36.4 to 43.2)	(46.5 to 54.2)	(56.8 to 67.0)	(16.9 to 34.9)	
12 mo	15.8 $\pm$ 5.6	49.8 $\pm$ 1.8	57.0 $\pm$ 2.0	89.8 $\pm$ 2.6	63.5 $\pm$ 5.3	
	(4.6 to 26.9) $p < 0.0001^a$	(46.3 to 53.3) $p < 0.0001^a$	(53.0 to 61.0) $p < 0.02^a$	(84.6 to 95.0) $p < 0.0001^a$	(52.9 to 74.0) $p < 0.0001^a$	
Large (n=5)	24 mo	16.9 $\pm$ 5.8	51.3 $\pm$ 1.8	54.1 $\pm$ 2.1	91.7 $\pm$ 2.7	77.3 $\pm$ 5.0
		(5.4 to 28.5) $p < 0.0003^a$	(47.6 to 55.0) $p < 0.0001^a$	(50.0 to 58.3)	(86.2 to 97.1) $p < 0.0001^a$	(67.2 to 87.4) $p < 0.0001^a$
	36 mo	21.8 $\pm$ 6.6	51.5 $\pm$ 2.1	56.1 $\pm$ 2.4	92.2 $\pm$ 3.3	78.1 $\pm$ 5.8
		(8.6 to 35.0) $p < 0.0004^a$	(47.3 to 55.7) $p < 0.0001^a$	(51.4 to 60.8)	(85.7 to 98.7) $p < 0.0001^a$	(66.5 to 89.7) $p < 0.0001^a$
	48 mo	7.9 $\pm$ 5.4	51.0 $\pm$ 1.7	56.3 $\pm$ 1.9	95.2 $\pm$ 2.5	83.5 $\pm$ 4.7
		(-2.9 to 18.7) $p < 0.0001^a$	(47.6 to 54.3) $p < 0.0001^a$	(52.4 to 60.1) $p < 0.03^a$	(90.2 to 100.3) $p < 0.0001^a$	(74.2 to 92.9) $p < 0.0001^a$ , $p < 0.01^b$
Preop	45.1 $\pm$ 10.6	40.4 $\pm$ 3.5	50.9 $\pm$ 3.9	59.1 $\pm$ 7.2	24.8 $\pm$ 11.2	
	(22.7 to 67.6)	(32.9 to 47.9)	(42.5 to 59.3)	(43.8 to 74.5)	(1.0 to 48.6)	
12 mo	28.3 $\pm$ 11.9	51.1 $\pm$ 3.9	50.9 $\pm$ 4.1	83.5 $\pm$ 8.1	68.1 $\pm$ 12.5	
	(3.2 to 53.4)	(42.7 to 59.4)	(41.6 to 60.3)	(66.4 to 100.7) $p < 0.04^a$	(41.4 to 94.8) $p < 0.02^a$	
Large (n=5)	24 mo	13.5 $\pm$ 11.8	52.4 $\pm$ 3.9	49.9 $\pm$ 4.4	85.5 $\pm$ 8.1	54.8 $\pm$ 12.5
		(-11.6 to 38.6)	(44.1 to 60.8) $p < 0.04^a$	(40.6 to 59.2)	(68.3 to 102.6) $p < 0.03^a$	(28.1 to 81.4)
	36 mo	23.9 $\pm$ 11.8	50.3 $\pm$ 3.9	57.5 $\pm$ 4.4	80.2 $\pm$ 8.1	39.7 $\pm$ 14.4
		(-1.2 to 49.0)	(41.9 to 58.6)	(48.2 to 66.8)	(63.0 to 97.3)	(8.9 to 70.5)
48 mo	17.9 $\pm$ 10.6	47.8 $\pm$ 3.5	56.6 $\pm$ 3.9	80.1 $\pm$ 7.2	58.2 $\pm$ 11.2	
	(-4.5 to 40.4)	(40.4 to 55.3)	(48.2 to 64.9)	(64.8 to 95.4)	(34.3 to 82.0)	

Abbreviations: VAS, visual analog scale; SF-12, Short-Form 12 Health Survey; FAAM ADL, Foot and Ankle Ability Measure; ADL, activity of daily living score. Small (<50 mm<sup>2</sup>), medium (<50 to 150 mm<sup>2</sup>), and large (>150 mm<sup>2</sup>) lesions. \* There were 2 small, 14 medium, and 5 large lesions. †Unable to estimate mean of small OLTs' FAAM sport scores at 24 & 36 month visit due to missing data. <sup>a</sup> Compared to preop; <sup>b</sup> Compared to 12 months.

estimates are unattained. Only medium OLTs predominantly achieved significant pre-to postoperative increase in FAAM-sport scores; a significant increase also occurred between the 12 and 48-month visits. Large OLTs generally had lower sport scores, although a significant pre-to postoperative increase only occurred at 12-months. Most PROMs did not significantly differ between visits (Table 3 and 4).

There was no statistical relationship between the technique used to implant the PJCA and lesion size ( $p > 0.05$ ). All small lesions were performed using open arthroscopy. The medium lesions were implanted either via arthroscopy ( $n = 2$ ), extended portal (extending the arthroscopic portals to 6-8 mm;  $n = 5$ ), or open arthroscopy ( $n = 8$ ). Large lesions were implanted arthroscopically ( $n = 1$ ) or via open

arthrotomy ( $n = 4$ ). Repeated measures analyses did not reveal any statistical difference in PROMs based on operative approach or prior ankle operation ( $p > 0.05$ ).

## DISCUSSION

The four-year prospective data revealed an overall significant improvement in physical health, sports-related activities, function, and pain after treating OLTs with PJCA compared to preoperative scores; thus, validating the study hypothesis. The similarities in scores between postoperative visits suggest that PJCA lead to symptom maintenance after initial improvement from preoperative irrespective of operative technique and lesion size. Fifty-four percent (13/24) of our subjects also had prior ankle operation. This can create a unique challenge for the surgeon given the altered operative anatomy. We found that even with prior ankle operation, OLTs can be effectively treated with PJCA as revealed by the significant pre-to postoperative improvement in PROMs.

In the present case series, the reoperation rate is 4.2% (1/24) which was performed with minimal debridement of the graft for an OLT of 176.0 mm<sup>2</sup>. Tan et al. evaluated four subjects with large OLTs who had failed treatment with PJCA<sup>[20]</sup>. Two subjects lacked allograft integration and two incurred bony and soft tissue impingement; the authors' stated the importance of acknowledging certain biological and mechanical factors when selecting candidates for PJCA<sup>[20]</sup>.

Our subjects had improved pain and function similar to other PJCA for OLT studies. Bleazey and Brigido retrospectively evaluated seven patients with cystic OLTs treated with medial malleolar osteotomy and reconstruction with PJCA/sponge subchondral allograft<sup>[11]</sup>. All seven patients had pre-to postoperative clinical improvement in pain and activity scores after 6-months<sup>[11]</sup>. Saltzman and colleagues' preliminary retrospective data of six ankles with mean follow-up of 13.04 months also revealed improved subjective pain and range of motion<sup>[19]</sup>. Lanham et al. retrospectively compared clinical outcomes ( $n = 12$ , mean follow-up 25.7 months) after treatment with either bone marrow aspirate (BMA) or PJCA<sup>[18]</sup>. The authors also found favorable FAAM-ADL score of 97.02 for PJCA (versus 77.77 for BMA)<sup>[18]</sup>, which is consistent with our study's ADL of 94.1 at 24 months.

Within the literature, it has been reported that size of a lesion can be used to predict clinical outcomes<sup>[1,2,23]</sup>. Given the popularity of BMS, most studies surround this operative technique. Chuckpaiwong et al. found that lesions less than 15mm had higher clinical success compared to larger lesions after arthroscopic BMS<sup>[2]</sup>. Choi et al. also found OLTs greater than 150mm<sup>2</sup> had higher failure rates after arthroscopic BMS<sup>[1]</sup>. However, it is unknown if these size cut-offs are generalizable in practice. Ramponi et al. systematic review showed vast heterogeneity among studies' definition of size and outcomes after BMS<sup>[23]</sup>.

Similar to the original BMS studies, there is controversy surrounding lesions size prediction on clinical outcomes following treatment with PJCA. In a retrospective case series of 15 subjects treated with PJCA (mean follow-up of 34.6 months), Dekker et al. showed that lesions greater than 125 mm<sup>2</sup> were significantly associated with failure<sup>[13]</sup>. In contrast, Karnovsky et al<sup>[17]</sup> and Lanham et al<sup>[18]</sup> did not find a significant association between size and clinical outcomes. Comparably, in the current analyses, size did not affect PROMs which is likely due to the greater amount of medium sizeable lesions. Nonetheless, a standardized method of reporting lesion sizes.

Success with microfracture has been reported with small OLTs.

Kim et al. retrospectively evaluated time-related changes of clinical outcomes after arthroscopic microfracture for OLTs 1.5cm<sup>2</sup> for at least three-years<sup>[24]</sup>. There was continued improvement of the AOFAS and pain scores up to two-years, and symptom maintenance for at least three-years<sup>[24]</sup>. Similarly, lesion size did not affect outcomes<sup>[24]</sup>. However, a major difference in Kim et al.'s study is that patients who worsened or failed to improve until 6-months postoperatively were excluded<sup>[24]</sup>. The authors also did not elaborate on inclusion of revision cases or those with prior ankle operation which may present the surgeon with an additional clinical challenge of altered anatomy. In study, found encouraging results since there was no symptom worsening irrespective of both prior ankle operation and initial worsening. However, further research is warranted to directly compare superiority of PJCA to microfracture alone in revision OLTs.

Other treatment options exist for large or recurrent OLTs. Ahmad and Jones compared osteochondral autograft ( $n = 20$ , mean follow-up of 35.2-months) to allograft ( $n = 20$ , mean follow-up of 40.5 months) for treatment of recurrent OLTs or large primary OLTs (greater than or equal to 1.5cm<sup>2</sup>), and found no differences between the groups in functional and pain scores<sup>[25]</sup>. The autograft's VAS score improved from preoperative of 7.9 to 2.2 postoperatively, and the allograft's preoperative score improved from 7.8 to 2.7 postoperatively<sup>[25]</sup>. The autograft's FAAM scores improved from a preoperative of 54.4 to 85.5 postoperatively, and the allograft's from 55.2 to 80.7<sup>[25]</sup>. We also found pre-to postoperative improvement at 48-months in FAAM-ADL (from 59.1 to 80.1) and pain (from 45.1 to 17.9) scores with large OLTs ( $n = 5$ ). However, this requires further investigation due to limited number of large lesions in the present series. A homogenous number of lesions in each category can provide further insight into the clinical predictors of treatment success.

The technical difficulty of PJCA implantation depends on the surgeon's level of comfort with performing open / arthroscopic procedures. The average duration of implantation was ~38 minutes ( $n = 20$ ). Similar to microfracture, it can be performed alone or concomitantly which can increase costs and/or the duration of the entire procedure. PJCA is approximately \$4,000 which is less costly than other restorative procedures such as ACI (>\$ 16,000) and talar allograft (~\$6500)<sup>[26]</sup>.

Our study's prospective design is a major strength; there are limited prospective studies evaluating mid-term clinical outcomes with PJCA, and we obtained preoperative scores to assess mean differences, therefore minimizing bias. Also, current studies on PJCA have nonuniform follow-up. Our series provides near complete four-years of clinical outcomes. We believe our data warrants further discussion as it helps provide clinical insight into using PJCA for symptomatic OLT.

Our study has limitations such as premature study closure which was secondary to a corporate merger of the company providing the research grant. Also, the small sample size may have affected the PROMs, particularly the mental-health scores. The sample size also led to an uneven distribution of sizeable lesions which were mostly medium OLTs; this may have affected the PROMs as there statistical difference between lesion sizes for PROM scores. The PROMs may have been affected by factors such as improvement of coexisting pathology (i.e.-ankle instability), or successful/compliance with rehabilitation. The authors also did not correlate PROMs with healing on postoperative MRI, nor was there a control or comparison group. Although the authors are aware of these limitations, this study contributes to the literature by providing prospective mid-term data on a biologic solution for OLTs.

## CONCLUSION

Four-year outcomes suggest that treatment with a PJCA led to improved function and pain levels without symptom worsening, and it is an effective operative intervention for symptomatic lesions irrespective of lesion size.

## REFERENCES

- Choi WJ PK, Kim BS, Lee JW. Osteochondral Lesion of the Talus: is there a critical defect size for poor outcome? *The American Journal of Sports Medicine* 2009;37(10):1974-80
- Chuckpaiwong B, Berkson EM, Theodore GH. Microfracture for osteochondral lesions of the ankle: outcome analysis and outcome predictors of 105 cases. *Arthroscopy* 2008;24(1):106-12 [DOI: 10.1016/j.arthro.2007.07.022]
- Cuttica DJ, Smith WB, Hyer CF, Philbin TM, Berlet GC. Osteochondral lesions of the talus: predictors of clinical outcome. *Foot Ankle Int* 2011;32(11):1045-51 [DOI: 10.3113/FAI.2011.1045]
- Giannini S, Buda R, Ruffilli A, Cavallo M, Pagliuzzi G, Bulzamini MC, Desando G, Luciani D, Vannini F. Arthroscopic autologous chondrocyte implantation in the ankle joint. *Knee Surg Sports Traumatol Arthrosc* 2014;22(6):1311-9 [DOI: 10.1007/s00167-013-2640-7]
- Adams S, Yao J, L S. Particulated Juvenile Cartilage Allograft Transplantation for Osteochondral Lesions of the Talus. *Techniques in Foot and Ankle Surgery* 2011;10(2):92-98
- Kraeutler MJ, Chahla J, Dean CS, Mitchell JJ, Santini-Araujo MG, Pinney SJ, Pascual-Garrido C. Current Concepts Review Update. *Foot Ankle Int* 2017;38(3):331-42 [DOI: 10.1177/1071100716677746]
- DeSandis BA, Haleem AM, Sofka CM, O'Malley MJ, Drakos MC. Arthroscopic Treatment of Osteochondral Lesions of the Talus Using Juvenile Articular Cartilage Allograft and Autologous Bone Marrow Aspirate Concentration. *J Foot Ankle Surg* 2018;57(2):273-80 [DOI: 10.1053/j.jfas.2017.09.009]
- Seow D, Yasui Y, Hurley ET, Ross AW, Murawski CD, Shimozone Y, Kennedy JG. Extracellular Matrix Cartilage Allograft and Particulate Cartilage Allograft for Osteochondral Lesions of the Knee and Ankle Joints: A Systematic Review. *Am J Sports Med* 2018;46(7):1758-66 [DOI: 10.1177/0363546517717494]
- Giza E, Delman C, Coetzee JC, Schon LC. Arthroscopic treatment of talus osteochondral lesions with particulated juvenile allograft cartilage. *Foot Ankle Int* 2014;35(10):1087-94 [DOI: 10.1177/1071100714548704]
- Kruse DL, Ng A, Paden M, Stone PA. Arthroscopic De Novo NT((R)) juvenile allograft cartilage implantation in the talus: a case presentation. *J Foot Ankle Surg* 2012;51(2):218-21 [DOI: 10.1053/j.jfas.2011.10.027]
- Bleazey S, Brigido SA. Reconstruction of complex osteochondral lesions of the talus with cylindrical sponge allograft and particulate juvenile cartilage graft: provisional results with a short-term follow-up. *Foot Ankle Spec* 2012;5(5):300-5 [DOI: 10.1177/1938640012457937]
- Coetzee JC, Giza E, Schon LC, Berlet GC, Neufeld S, Stone RM, Wilson EL. Treatment of osteochondral lesions of the talus with particulated juvenile cartilage. *Foot Ankle Int* 2013;34(9):1205-11 [DOI: 10.1177/1071100713485739]
- Dekker TJ, Steele JR, Federer AE, Easley ME, Hamid KS, Adams SB. Efficacy of Particulated Juvenile Cartilage Allograft Transplantation for Osteochondral Lesions of the Talus. *Foot Ankle Int* 2018;39(3):278-83 [DOI: 10.1177/1071100717745502]
- D'Ambrosi R, Maccario C, Serra N, Ursino C, Uselli FG. Relationship between symptomatic osteochondral lesions of the talus and quality of life, body mass index, age, size and anatomic location. *Foot Ankle Surg* 2018;24(4):365-72 [DOI: 10.1016/j.fas.2017.04.011]
- D'Ambrosi R, Maccario C, Ursino C, Serra N, Uselli FG. Combining Microfractures, Autologous Bone Graft, and Autologous Matrix-Induced Chondrogenesis for the Treatment of Juvenile Osteochondral Talar Lesions. *Foot Ankle Int* 2017;38(5):485-95 [DOI: 10.1177/1071100716687367]
- Giza E, Howell S. Allograft juvenile articular cartilage transplantation for treatment of talus osteochondral defects. *Foot Ankle Spec* 2013;6(2):141-4 [DOI: 10.1177/1938640013479934]
- Karnovsky SC, DeSandis B, Haleem AM, Sofka CM, O'Malley M, Drakos MC. Comparison of Juvenile Allogeneous Articular Cartilage and Bone Marrow Aspirate Concentrate Versus Microfracture With and Without Bone Marrow Aspirate Concentrate in Arthroscopic Treatment of Talar Osteochondral Lesions. *Foot Ankle Int* 2018;39(4):393-405 [DOI: 10.1177/1071100717746627]
- Lanham NS, Carroll JJ, Cooper MT, Perumal V, Park JS. A Comparison of Outcomes of Particulated Juvenile Articular Cartilage and Bone Marrow Aspirate Concentrate for Articular Cartilage Lesions of the Talus. *Foot Ankle Spec* 2017;10(4):315-21 [DOI: 10.1177/1938640016679697]
- Saltzman BM, Lin J, Lee S. Particulated Juvenile Articular Cartilage Allograft Transplantation for Osteochondral Talar Lesions. *Cartilage* 2017;8(1):61-72 [DOI: 10.1177/1947603516671358]
- Tan EW, Finney FT, Maccario C, Talusan PG, Zhang Z, Schon LC. Histological and Gross Evaluation through Second-Look Arthroscopy of Osteochondral Lesions of the Talus after Failed Treatment with Particulated Juvenile Cartilage: A Case Series. *J Orthop Case Rep* 2018;8(2):69-73 [DOI: 10.13107/jocr.2250-0685.1056]
- Gandek B, Ware JE, Aaronson NK, Apolone G, Bjorner JB, Brazier JE, Bullinger M, Kaasa S, Leplege A, Prieto L, Sullivan M. Cross-validation of item selection and scoring for the SF-12 Health Survey in nine countries: results from the IQOLA Project. International Quality of Life Assessment. *J Clin Epidemiol* 1998;51(11):1171-8
- Hepple S, Winson IG, Glew D. Osteochondral lesions of the talus: a revised classification. *Foot Ankle Int* 1999;20(12):789-93
- Ramponi L, Yasui Y, Murawski CD, Ferkel RD, DiGiovanni CW, Kerkhoffs G, Calder JDF, Takao M, Vannini F, Choi WJ, Lee JW, Stone J, Kennedy JG. Lesion Size Is a Predictor of Clinical Outcomes After Bone Marrow Stimulation for Osteochondral Lesions of the Talus: A Systematic Review. *Am J Sports Med* 2017;45(7):1698-705 [DOI: 10.1177/0363546516668292]
- Kim TY, Song SH, Baek JH, Hwang YG, Jeong BO. Analysis of the Changes in the Clinical Outcomes According to Time After Arthroscopic Microfracture of Osteochondral Lesions of the Talus. *Foot Ankle Int* 2018;1071100718794944 [DOI: 10.1177/1071100718794944]
- Ahmad J, Jones K. Comparison of Osteochondral Autografts and Allografts for Treatment of Recurrent or Large Talar Osteochondral Lesions. *Foot Ankle Int* 2016;37(1):40-50 [DOI: 10.1177/1071100715603191]
- Desai S. Treatment of osteochondral lesions of the talus with marrow stimulation and micronized allograft cartilage matrix: an all-arthroscopic technique. *Techniques in Foot and Ankle Surgery* 2014;13(3):167-73 [DOI: 10.1097/BTF.0000000000000056]