

Overview and Treatment for A Flatfoot in Children

Nguyen Ngoc Hung¹, MD, PhD; Hoang Hai Duc¹, MD, PhD; Le Tuan Anh¹, MD

¹ Vietnam National Hospital for Pediatrics, Dong Da District, Ha Noi, Viet Nam.

Conflict-of-interest statement: The author(s) declare(s) that there is no conflict of interest regarding the publication of this paper.

Open-Access: This article is an open-access article which was selected by an in-house editor and fully peer-reviewed by external reviewers. It is distributed in accordance with the Creative Commons Attribution Non Commercial (CC BY-NC 4.0) license, which permits others to distribute, remix, adapt, build upon this work non-commercially, and license their derivative works on different terms, provided the original work is properly cited and the use is non-commercial. See: <http://creativecommons.org/licenses/by-nc/4.0/>

Correspondence to: Nguyen Ngoc Hung MD, PhD, Associate Professor, VietNam National Hospital for Pediatrics, 18/879 La Thanh Road, Dong Da District, Ha Noi, Viet Nam.
Telephone: +84-0902 585658
Email: ngocyenhung@gmail.com

Received: February 28, 2022
Revised: March 23, 2022
Accepted: March 26 2022
Published online: May 6, 2022

ABSTRACT

Although the exact incidence of flatfoot in children is unknown, it is a common finding. All children have only minimal arch at birth, and more than 30% of infants have calcaneovalgus deformities in both feet. The condition is painless and usually clears up on its own without treatment; It is very rarely necessary to cast correction. Most children who visit an orthopedist for an evaluation for flatfoot will have flexible flatfoot without treatment. However, the examining physician must rule out other conditions that require treatment, such as congenital longitudinal defects, dorsal alignment, and misaligned feet. Left untreated, congenital vertical nails can lead to an awkward gait; Manipulation and casting have been tried, but most authors now agree that surgical treatment is necessary. Although dorsal alignment may be asymptomatic in adulthood, the anatomy will never be normal. Excision and interlacing of the digital extender or perforation is the treatment of choice for pelvic fusions; The outcome

of talocalcaneal union treatment is less predictable. Skewfoot should be treated with manipulation and serial casting as soon as discovered. In older children, it may be necessary to stabilize the hindfoot and realign the midfoot. Surgical management is rarely indicated for true soft flat feet. Many tendon transfer methods and reconstructive procedures have been advocated, but none have been shown to be equally successful. Nor is there any kind of support that has been shown to alter arch architecture. Although parents are often concerned about flat feet in their children, children often have no symptoms and no indication for treatment. In most cases, the best treatment is simply taking enough time to convince the family that no treatment is needed.

Key words: Flatfoot, Rigid; Osteotomy; Foot posture; Paediatric flat-foot; Functional anatomy

© 2022 The Author(s). Published by ACT Publishing Group Ltd. All rights reserved.

Hung NN, Duc HH, Anh LT. Overview and Treatment for A Flatfoot in Children. *International Journal of Orthopaedics* 2022; **9(2)**: 1614-1631 Available from: URL: <http://www.ghrnet.org/index.php/ijo/article/view/3292>

INTRODUCTION

Our bibliography on flatfoot suggests that the authors of recent works, such as Rao^[1] Rose^[2] and Staheli^[3] appear to have abandoned the treatment approach. conservative. Classic for this situation by earlier authors such as Lelivre^[4]. Viladot^[5] and Giannestras^[6]. Many authors doubt the effectiveness of orthopedic treatment of flat feet. Some authors, such as Broks^[7] Fowle^[8] and Volpon^[9] argue that flat feet are normal in childhood and that the condition resolves on its own without treatment.

Pes planovalgus is a common condition in children. Although often idiopathic, it may be associated with neuromuscular diseases, trunk alignment, and pelvic accessory syndrome. A common mistake made by surgeons is to regard flatfoot in children as a minor version of the adult flatfoot deformity. Indeed, the causes and management of malformations can be quite different. Often, children have no symptoms and the primary concern is foot shape or parental concerns about possible future mobility impairment. The most important challenge for physicians is to distinguish a potentially benign

condition from one that can be disabling if left untreated.

These authors say that the feet of most infants with what appears to be an infant become structurally normal by the time they are 12 or 13 years old.

The modern tendency to turn away from previously established practice aroused our curiosity and led us to carry out an epidemiological study of young children with flat feet in the province of Ma'laga. The study pays special attention to the lingering economic burden on parents given the significant cost of virtually unnecessary chiropractic treatments for this condition. Our findings lead us to ask the question posed in the title of this work: "Flexible flat feet in children: a real problem?".

Treatments to correct flatfoot deformities can be non-surgical or surgical. We can divide the surgical techniques used to correct this deformity into three categories: soft tissue, bone (bone and osteosarcoma), and joint displacement. It is unlikely that a single soft tissue procedure can successfully correct the deformity. For such reasons, the addition of bone procedures and/or neck treatment is warranted. Subtalar arthroereisis has been introduced in recent years to treat flatulence in children. Arthroereisis is a joint-saving technique that allows deformation correction through mechanical and mechanical action.

History

As with any orthopedic condition, a thorough history can often lead to an accurate diagnosis. Clinical age, presentation is important to determine whether flatulence is physiological or pathological in nature. In addition, a positive family history can help uncover the underlying cause of pes planus and can provide clinicians with an idea of whether flatfoot with a normal variant would be asymptomatic, or whether they are secondary to hereditary arthritis or familial ligament dilatation (eg, Ehlers-Danlos Syndrome)^[10]. Furthermore, if the patient presents with pain or no pain, this is important to establish an appropriate differential diagnosis. A thorough assessment of pain quality, severity, and time of onset helps differentiate the cause of the blisters. Because, for example, a painful flat foot without weight carries the right tumor, arthritis, or infection; all of these need to be appropriately improved. However, a changed activity level or the presence of a person with a limp may be the only signs of discomfort in young children, as they do not always complain of pain. Questions about history such as participation in barefoot sports (such as martial arts and gymnastics) and recent injuries should be asked. Do different factors, such as the presence of neuromuscular disorders, have to be considered in the context of the clinical presentation of pes planus in children.

NATURAL HISTORY OF FLATFOOT FLATFOOT

Very few people have studied the natural history of uncorrected flatfoot and the subsequent natural history of this condition when it was corrected. The literature is of questionable value in today's medical landscape that is emphasized on certification, level of clinical evidence, and research construction. There are no data to definitively demonstrate that flexible flatfoot in infants and children leads to long-term morbidity in adults. The flawed consensus on the need for flexible flat feet led to the development of two analytic, educational and opposing philosophies regarding treatment. Physicians today are forced to make decisions based on personal training and experience and on conclusions drawn from the literature. It is very difficult to evaluate the calculation validity of the so-called authoritative conclusions. Some decisions are based on data, but many are "expert

opinions". Even data-driven orientations to outcomes supported by analytical systems are at odds with conventional clinical experience. Faker missing this data. A study that addresses shoe and orthopedic questions as additions to the natural history of flexible feet shows how difficult it is to construct a prospective scientific study Readers interested, studied the article by Wenger et al^[11], Newsroom and 2 Letters to the newsrooms appeared in the same issue. Magic therapy? immune to citations and create your own share of controversy. It is possible to know for sure that it will solve the problem, but it is permanent and not without risk. When morbidity and potential costs are factored in, the work of proving potentially medically and legally necessary becomes all the more necessary.

There is a natural history to child development that cannot be denied. Staheli et al^[12] Studying 441 subjects usually aged 1 to 80 years and concluded that foot is common in infants, common in children and within the normal range of vision performed in adults. user. Their advice to Management is to document and observe. Gould et al^[13] studied 225 beginners and followed them for 4 years. All the toddlers as usual had pes planus as determined by radiographic and radiographic parameters. The growth arch does not depend on the tearing of the footwear. Children bring developer favors faster. Hypertension was evident in 77.9% and genu valgum in 92.3% of 5-year-old children.

Garcia-Rodriguez et al^[14] Study the prevalence of flexible flat feet in schoolchildren aged 4 to 13 years old in Malaga, Spain. They were ranked by importance of a sample that included 1181 children out of 198,858 primary school children. They created 3 age groups (4-5, 8-9 and 12-13) and classified the footprints into 3 types of flatfoot. They found the prevalence of flat feet to be 2.7%. 1181 young em get sample. Of the sample population, 168 (14.2%) were undergoing form correction, but only 2.7% met the diagnostic criteria for flatfoot. In the group that met the flatfoot criteria, only 28.1% were being corrected. Overweight children from 4 to 5 years old, the incidence of foot problems is increasing. They found the data with too many children in the group study had to be valid.

Lin et al^[15] Reassessment of flexible flat feet in preschool children in Taiwan using an analytical program. Twenty-seventy-seven preschool children (201 boys and 176 girls), aged 2 to 6 years, were enrolled in the study. Results for the impact of age, height, weight, anterior angle of the foot, degree of occurrence of head physiological percussion, and scores for flatfoot, respectively. Thus, for children without flat feet, the child performs tasks that may be poor quality and walk slowly, determined by information walking patterns. They concluded that the foot should not simply be seen as a complex problem of static alignment of the ankle and foot but could be the result of functional alteration work in all the detail below.

El et al^[16] Studied longitudinal profile in 579 students and assessed joint degree of generalization, foot angle of change, forefoot and hindfoot movement, and vertical arc. They rated 82.8% as normal and mild flatfoot, and 17.2% as moderate and severe soft flatfoot. It is important to note that there is a correlation between number plots and age and between increased transport points and age.

Pfeiffer et al^[17] studied 835 children between the ages of 3 and 6, based on the diagnosis of flatfoot on the site of the heel concave and poor arch formation. The rate of soft flat feet in the age group from 3 to 6 years old is 44%. The rate of pathological flat feet is less than 1%. Ten percent of children were wearing arch supports. The prevalence of flat feet decreased with age from 54% in the 3-year-old group to 24% in the 6-year-old group. More boys have flat feet than girls (52% versus 36%). Obesity was a complication in 13%. They concluded that the ability to walk barefoot was affected by age, sex,

and weight. They concluded that more than 90% of the treatments performed on their patient population were unnecessary.

Other investigators have studied specific populations to determine the relevance of parity in adults and passed this information on to children. The classic article by Harris and Beath^[18] from 1948 not only describes the ultraportable flatfoot with short Achilles tendon but also discusses some data from the Royal Canadian Medical Corps study from 1944. to 1945 on military foot problems. Among the 3619 Canadian soldiers, there were 25 cases of severe ultramobility flatfoot with short Achilles tendon, 192 cases of mild ultramobility foot with short Achilles tendon, 74 cases of spastic flatfoot, and 524 cases of characterized by low arches. They further concluded that the natural history of hypermobile flatfoot with short Achilles tendon is to cause it to worsen, and lose more mobility with increasing age. The disability is mild in childhood and may not manifest until adolescence. It worsens in young life, and by middle age it may have reached severe proportions^[18].

Cowan *et al*^[19] studied 246 US Army infantry cadets and their conclusions did not support the hypothesis that those with low arches were at higher risk of injury. Rudzki^[20] studied 350 men in the Australian Army and concluded that pes planus is not a significant factor in the development of recruit training trauma. Hogan and Staheli^[21] investigated the concept that treatment of flexible flat feet in children would prevent disability in adulthood. Proponents of not handling flexible flat feet cite military studies that show flexible flat feet are not the source of disability in soldiers. They studied 91 physically active civilian adult men and women and found no association between arch shape and pain sensation, suggesting that in the civilian population, the flexible flat-legged population does not. must be the source of the disability. They conclude that this Study is consistent with previous studies and that it provides further evidence against the practice of treating flexible flat feet in children.

Abdel-Fattah *et al*^[22] 61 studied 2,100 18- and 21-year-old recruits in the Saudi Army. The percentage of flat feet is 5%. Among them, the conclusions included family history, childhood wearing shoes, obesity, and Urban residency as important problems associated with flat feet. Because no flatfoot-related complaints were reported among the cases, their conclusion was that Flexible Flatfoot is not likely to be the cause of any disability.

ETIOLOGY

The high frequency of associated anomalies underscores the fact that longitudinal talus is a highly etiologically heterogeneous condition. Isolated vertical streaks appear to be the result of a problem during pregnancy. By the 7th week of pregnancy, the feet have noticeably stretched back and gradually plan in the following weeks. Injury must have occurred during this phase, possibly due to simultaneous shortening of both the triceps and extensors of the foot. A genetic component has been observed for flatfoot in isolation and in association with other malformations^[23].

Pathological changes have been studied in some children with multiple malformations who died prematurely. The main factor is displacement of the pelvis in the direction of the skull. It no longer fits with the anterior articular surface of the nail but is dorsal to the base of the nail.

The talus roofs slope down toward the middle of the calcaneus and stand upright. Simultaneously, the calcaneus is rotated posteriorly to each side. The slat remains in flexible plastic, allowing the slat to slide over it. All the ligaments and tendons on the medial side of the hindfoot essentially lengthen and form a dislocation pocket in which

the nail is located. The triceps and extensors of the foot are shortened and contracted.

PATHOPHYSIOLOGY

The function and structure of the medial longitudinal arch is influenced by many anatomical structures, all of which provide potential influences on pathophysiology. The posterior tibialis and corresponding muscles are important for the position of the hindfoot and foot during the gait cycle. Originating from the posterior aspect of the tibia, fascia, and fibula, the anterior tibial muscle and tendon next pass through the posterior aspect of the tibia and then insert through multiple bands into the iliac, wedge-shaped, tarsal bones, and tally nets. The ankle sphincter and anterior metatarsal muscle combined with the resulting submandibular inversion are the primary functions of the posterior tibia because the tendon is in the postoperative position. During the gait cycle, the foot must shift from a flexible heel-to-foot structure to accommodate uneven surfaces to a rigid extrusion structure to maintain a strong lever for movement^[24]. As the heel rises, the PTT begins to supplement the tarsal joint horizontally with the resulting subchondral inversion causing the femoral and tarsal axes to be perpendicular and thus locked.

The natural antagonist of the posterior tibial plateau is peroneus brevis, which is responsible for the abduction with the forefoot and the toppling of the lower body. When PTT deficiency occurs, some deformation force is generated.

The forefoot valgus combines with the long heel, creating the Achilles tendon contract and transform the gastrointestinal muscles into heel sheaths (rather than inverters); all contribute to the dynamic factors in heteromorphism.

Other structures important to the medial longitudinal arch are considered static. The distinct shape and size of the bony architecture of the central arch provides considerable stability. Recently, the spring ligament has received much attention as an important stabilizer of the medial arch. The simple ligament support system that surrounds the pelvic joint consists of several parts, including the external iliac ligament, the lower iliac ligament, and part of the superficial deltoid muscle. The degree of stability contributed by the spring ligament and the delta ligament complex remains unclear.

Therefore, for the normal function of the foot, it is of utmost importance that it transforms from a flexible structure in the heel that adapts to uneven surfaces to a rigid structure when extruded to maintain it. maintains a rigid structure to its surroundings, regardless of its average vertical arch height. The tendency to develop flexible flat feet is genetic and is the source of flat feet in many children.

The cause of this condition is most likely due to excessive laxity of the joint capsule and joint cushions that cause the arch of the ankle to collapse when weight is applied. Baby fat and basal laxity at this age tends to flatten out, and rapid growth can make it more apparent.

Several studies have shown that the importance for the development of the vertical arch is six years in advance. If wearing shoes does not contribute to arch failure, the age at which it begins takes into account the onset of flatfoot. The introduction of shoes before the age of six will cause children to have flat feet while if delayed until the children are older, a tendency to flat feet will appear.

Rigid flatfoot is a birth defect in which the bones of the neck cannot separate, leaving a cartilage-and-cartilaginous bridge between two or more ankle bones. Union restricts normal foot and leg movement, leading to inflammation of the involved joints. The muscle tendon crosses the subchondral joint and often enters subchondral arthritis secondary to spasm, hence the term "periosteal

contracture” of the flatfoot. The dorsal union accounts for about 1 percent of the population and is bilateral in 50 to 60 percent of patients^[25]. Pleural involvement accounts for 48% of all conjugations and usually becomes symptomatic when the patient is 8 to 12 years of age^[26]. Choroidal fusion occurs in 43% of patients and becomes symptomatic between 12 and 16 years of age.

PATHOGENESIS

There are two main theories explaining the pathogenesis of FFF: a type of vacuum that is present at birth and is associated with good joint mobility and normal muscle function. Duchenne. This theory was refuted by Basmajian *et al.*, whose electromyography studies of the muscles of the foot and ankle showed that the height of the longitudinal arch is determined by features of the bone-ligament complex and the maintenance muscles. balance, adjust the foot for uneven terrain, protect ligaments from abnormal stresses and propel the body forward. Proponents of this bone-ligament theory believe that the shape of the longitudinal arch under static loads is determined by the shape and interrelationship of the bones, along with the strength and durability of the ligament. It has not been shown that the irregular shapes of individual bones and joints represent primary or secondary regrowth of the long-standing foot, although most current authors conclude that loose Overuse of the ligament is the main abnormality. Muscles are essential for function and balance, but not for structural integrity. Mann and Inman^[27] determined that muscular activity is not required to support the arch when subjected to static weight. They also found that the intrinsic muscles are the main stabilizers of the foot during thrust, and that greater intrinsic muscle activity is required to stabilize the transverse hip and ankle joints in the walker. legs than in individuals with average height arches.

There are no long-term prospective studies of the natural history of untreated FFF in relation to the development of pain, only the cross-sectional study by Holmes *CF ed al*^[28]. They found that, while FFF was rarely a cause for concern, FFF-STA often caused pain and disability. It is unclear whether this short Achilles tendon in the foot is a primary pathological feature or a secondary developmental anomaly. Holmes *CF ed al*^[28] believe that FFF and FFF-STA are separate entities, although the literature on early clinical differentiation has not been reported.

See more of this source textEnter the source text for additional translation information.

BIOMECHANICS/PATHOLOGY

The functions of the foot include providing a stable, yet supple platform that adapts to the ground during the initial postural phase of gait, followed by conversion to a stiff lever while resisting. push. Some authors have described the complex mutual relationship between the bones of the midfoot and hindfoot as a gloved hinge^[29], although that analogy is clearly over simple. Using it as a first approximation or a basic foundation, one must understand more about the shape, structure, relationships, and motion of the submetallic joint complex to truly understand biomechanics. study of the foot.

The subchondral joint complex consists of three bones (possibly four, if one includes the cube), several important ligaments (including the spring, or calcaneo-navicular ligament), and multiple articular tablets. acts as a block. Nearly 200 years ago, Scarpa^[30] noted similarities between the subarticular complex and the hip. He compared the head of the femur to the tip of a fingernail, and the pelvis to the so-called “acetabulum”, a cup-like structure made up of the pelvis, spring ligament, and anterior end of the tibia. and its

sides. It’s not a perfect comparison, but the two anatomical regions share certain features that seem to make the comparison both valid and worthwhile. The hip, a simple ball and socket joint with central rotation, consists of two bones, an intraarticular ligament and a capsule. The subchondral joint is not a ball bearing and an independent joint, although the combined movements of the adjacent subchondral and tarsal joints give that impression. Its axis of motion lies in an oblique plane which is neither a front, a plane, nor a plane. This produces movements that are best described by the unique terms “inverse” and “motion”. The stable structure in the hip joint is the acetabulum (socket) joint, while the stable structure in the subarticular complex is the hoof. (ball). Inversion consists of pedal movement, supine and internal rotation of the acetabulum pedal around the tip of the nail. The static inversion of the subarticular joint is known as the hindfoot varus and is found in the cavovarus and clubfoot. Eversion is a combination of dorsi rotation, pronation, and external rotation of the acetabulum pedal around the talar head. The hindlimb is the static site of the subchondral joint and is seen in the fl affect and oblique.

The tibia and fibula rotate internally during the first half of the orthostatic phase of the gait cycle while the submandibular complex rotates. The stone pillar at the top of the talar is broken due to the loss of support from the acetabulum pedal. The feet become quite supple, unlocked and attentive. During the later part of the postural phase, the tibia and tibia rotate outward, while the submandibular complex rotates backwards, so that the acetabulum pedal once again supports the head of the clavicle. The back of the claws and the entire foot become stiffer, or locked. This relieves stress on the muscles and ligaments during pushups.

The leg fl exible fl begins the stance in an unlocked, grooved position, and does not fully transform into a rigid, inverted lever in the latter part of the pose. Building on the work of Mann and Inman^[31], who found that greater intrinsic muscle activity is required to stabilize the transverse ankle and subclavian joints in non-limb individuals than in individuals with average height arches, which can lead to tired and painful feet. Fortunately, leg fatigue and pain only seem to occur in some people who walk barefoot.

Orthopedists are advised to avoid using the term “development” in place of the term “walking leg”. and rotated outward, the middle foot is abducted, and the forefoot is raised relative to the hindfoot. The term “fl atfoot” covers all of these multisite circadian temporal anomalies and is therefore a better term choice.

ANATOMY OF FOOT IN CHILDREN

Normal Foot

The foot has 26 bones, 10 major extrinsic tendons, more than 30 joints, and numerous intrinsic myotendinous units and ligaments arranged together to form three arches^[32]. These structures must work in concert throughout life to allow the foot to support standing weight and absorb impact, store and release energy, and adapt to shifting loads during activity.

Arches of the Foot

The foot is constructed as a series of three intersecting arches: a longitudinal lateral arch, a longitudinal medial arch, and a transverse arch at the level of the distal tarsal bones (Figure 1). These arches are interrelated, so failure at one leads to dysfunction at the others. The lateral arch, which is composed of the calcaneus, cuboid bone, and fourth and fifth metatarsals, is rigid and functions to support body weight. The medial arch, comprising the calcaneus, talus, navicular, and cuneiform bones and the medial three metatarsals,

is taller and more flexible, which allows it to vary dynamically in shape and configuration during gait^[32] The osseous structures that form the longitudinal arches are referred to as the lateral and medial columns of the foot. The transverse arch is most commonly described as comprising the metatarsal bases and cuneiform and cuboid bones. Some authors recognize an additional transverse arch at the metatarsal heads, while Gray^[33] described a series of transverse arches at the foot, recognizing that the three arches act akin to the edges of a sail, forming a curved domelike structure with its apex at the medial midfoot. The apex of the intersection of the three arches is the transverse tarsal or midtarsal joint (talonavicular and calcaneocuboid articulations) with the talonavicular.

Infants are born with abundant plantar fat and flexible flat feet without any arch, which often engenders unnecessary parental distress. The arches develop rapidly when the child is 3-6 years old, with the medial arch appearing first, and the other arches maturing until growth ceases. Factors necessary for successful arch development include appropriate ossification, particularly at the sustentaculum tali and navicular bone; healthy soft-tissue stabilizers; proper plantar fascial tone; and a noncontracted Achilles tendon^[35]. Up to 15% of the population never develop well-defined arches. Developmental flatfoot among adults is considered physiologic unless the person becomes symptomatic. An estimated 7%-15% of adults with developmental flatfoot eventually develop symptoms that lead them to seek medical attention.

Normal development of foot in children

Despite their small size, newborn feet are very simple, consisting of 26 to 28 bones. The foot can be divided into three anatomical regions (Figure): hindfoot or hindfoot (talus and calcaneus); midfoot (pelvis, cuboid and three wedge bones); and forefoot (ankle and foot)^[36]. All children are born with flat feet. Almost every baby's feet initially have a large fat pad on the inner arch, which they slowly speak as they grow. The longitudinal arch of the foot is not present at birth and develops slowly during childhood, usually around the age of five or six. It is a process that occurs throughout growth and is unaffected by the presence or absence of external arch support. Sometimes arches take even longer to form and normal arches develop during the first decade of life, but this usually doesn't cause any problems. Flexible flatfoot is considered a manifestation of the looseness in the constitution that secures all the ligaments and joints, and if the arch of the foot is abnormal, it is usually the result of load-bearing stress. quantity. Most children with flat feet achieve immediate partial correction.

Concern about the child's foot position is a common reason for frequent consultations by healthcare professionals; Sports medicine specialists are often the first to recognize and advise on foot disease. In the decision-making process, it is essential to distinguish between the different forms of flatfoot: pediatric or adult, congenital or acquired, flexible or rigid. Although flat feet in children are a common finding, evidence for reliable and reproducible foot posture assessment techniques is scant. This review presents factors involved in arch formation and support, discusses procedures useful in assessing foot posture, and shows how to differentiate between flatfoot need treatment and the case just needs reassurance.

The arch of the foot is formed by the tarsal and tarsal bones, supported passively and limited by ligaments and tendons, allowing the foot to support the weight of the body in a standing and fully distributed position. forces generated when in contact with the ground during walking. All children are born with flat feet and a normal arch may not develop until they are 7-10 years old (Pfeiffer et al, 2006)

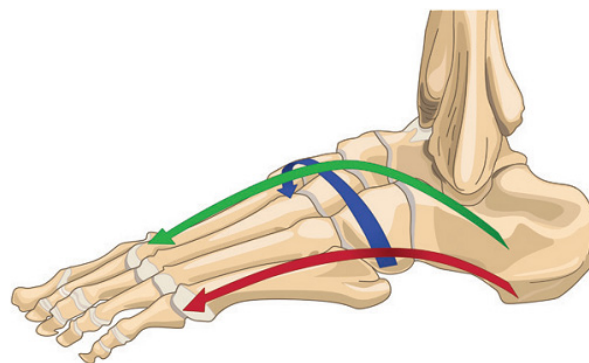


Figure 1 Illustration of the three intersecting arches of the foot. The longitudinal lateral arch (red) is relatively flat compared with the longitudinal medial arch (green). The transverse arch (blue) at the tarsometatarsal region runs perpendicular to the longitudinal arches and is taller medially than it is laterally. The talonavicular joint normally is located at the vault of the curved plane formed by these arches, and therefore it is the highest point of the foot, joint acting as the keystone of the triple arch complex^[34].

^[37]. The arch develops during childhood as part of the normal growth and strengthening of bones, ligaments, muscles, and tendons. When misaligned, deformed bones, or weakening of tendons or ligaments occur, foot deformity can develop.

Flat feet (pes planus) is a medical condition in which the entire sole of the foot is in complete or almost complete contact with the ground. Although the most common form is physiological flatfoot, progression to a more severe deformity can lead to the development of symptomatic flatfoot, causing subjective complaints and affect function (Haendlmayer and Harris, 2009)^[38]. However, the true significance of clinical findings is often misjudged. During the incision process, it is necessary to distinguish between different types of flatfoot deformities: pediatric or adult, congenital or acquired, flexible or rigid. It is also important to recognize the factors involved in the formation and maintenance of arches, to assess the correct foot posture to identify flatfoot deformities, and to differentiate between those that need treatment and those that just need reassurance.

Functional anatomy of the foot

The skeleton of each foot is made up of 28 bones: 7 legs, 5 ankles, 14 phalanges, and 2 sesamoid bones. From a functional point of view, the foot can be divided into three parts: the hindfoot, which is formed by the hoof and fibula, the midfoot, which consists of the pelvis, cuboid and three cuneiform bones, and the forefoot, formed by the ankle and phalanges (Moore et al, 2010)^[39]. The talus, calcaneus, cuboid, iliac, and three wedge-shaped bones form the trunk, including the hindfoot and midfoot.

The hindfoot extends from the infiltrate of the mandibular tubercle to the transverse tarsal joint (Chopart joint); The posterior portion includes the hoof of the talocalcaneonavicular joint and the calcaneocuboid joint. The anterior limit can be found superficially along the S-shaped line (medial convex and lateral concave) connecting the body of the pelvis (palpable anteriorly with the tip of the tumor medial) with the midline midline of the malleolus and the base tenderness of the 5 ankles. Movements of the midfoot over the hindfoot at the transverse tarsal joint increase inversion (rotation of the sole toward the medial plane) and inversion (lateral rotation of the sole), which mainly occurs at the subclavian joint. The anterior limit of the medial foot is posterior to the tarsal joint (Lisfranc joint), marked superficially by the slightly convex line between the lumen of the 1st cervical vertebra and the prominent tubular pattern of the 5th tarsal. This joint allows only slight sliding motion (Riola and Palma,

2001)^[40].

The shape of the tarsal and tarsal bones explains the presence of the longitudinal and transverse arches of the foot. The medial longitudinal arch extends between the sternum and hyoid (posterior pillar), and the 1st tarsus and the three cuneiform bones (anterior pillar). The keystone, corresponding to the top of the talus, is 15-18 mm above the ground. The lateral longitudinal arch is much flatter and rests on the ground at the barbell legs. It consists of the ulna (posterior), two lateral (anterior) ankles, and the cuboid (key), which can be 3-5 mm above the ground in weight-bearing feet. The horizontal arc runs from side to side at the level of the ankle joint. Its medial pillar is represented by the medial wedge and is the base of the first tarsal bone, the lateral pole is formed by the lateral wedge, the cube, and the base of the 3rd tarsal bone; keys have a timbre in seconds relative to an alternating iate wedge, possibly 18-20 mm above the ground (Moore et al., 2010)^[39].

The arch is passively maintained by aponeurosis and ligaments (long and short plantar ligaments, plantar calcaneonavicular ligaments) and dynamically supported by tendons of the extrinsic muscles (anterior tibialis, flexor longus and brevis), flexor digitorum longus and brevis for the longitudinal arch; peroneus longus, posterior tibia of the transverse arch) and by intrinsic muscles running between the pillars of the arch. These structures work together as a unit to support and properly distribute body weight during walking.

Clinical measurements

Arch index: Footprints were taken with carbon paper and the length of the foot (excluding the toes) was divided into an equal third. The arch index (AI) was calculated as the ratio of the area of the middle third of the footprint to the area of the footprint entire (Figure 1). Normal feet as characterized by AI range from 0.20 to 0.28, while a ratio higher than 0.32 indicates flat arched feet (Murley et al, 2009)^[41].

Normalised navicular height: Normalized pelvic height (truncated, NNHt) is the ratio of pelvic height (measured as the distance from the most medial protrusion of the iliac canal to the supporting surface) relative to table length. truncated foot (from first tarsal joint to proximal posterior aspect of heel. A value lower than 0.21 indicates flat arched foot (Murley et al., 2009)^[41].

In young adults, NNHt provided the strongest correlation with radiographic measurements. Both clinical measurement methods (AI and NNHt) can be used successfully to check flat foot posture, avoiding unnecessary referral to radiographs.

Radiographic measurements

X-ray examination of the foot is useful for diagnostic evaluation and profiling of the extent of the deformity; It becomes essential for preoperative planning and medical outcome evaluation. In flatfoot, it focuses on the relationship of the hoof and calcaneus, which can be evaluated in the sagittal plane in the lateral view and in the transverse plane in the anterior-posterior (AP) view, an initial graph. gland was obtained with the weight-bearing subject in a comfortable bipedal position (Murley et al., 2009)^[41].

Talocalcaneal Angle

The talocalcaneal angle (Kite angle) is formed by the intersection of two lines that coincide with the longitudinal axis of the talus and calcaneus in the horizontal plane. When the angle of inclination of the nail increased markedly, both on the anterior - posterior and lateral radiographs, a dislocation of the hind foot appeared.

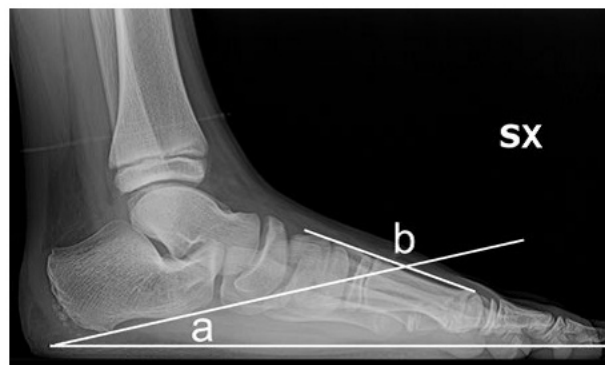

Figure 2 Flatfoot on the lateral view radiography.

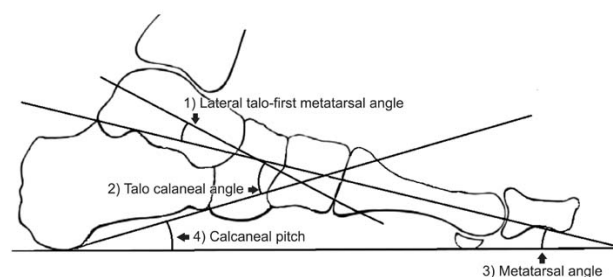


Figure 3 Flatfoot on the lateral view radiography.

Calcaneal inclination angle

It is the angle between the lower surface of the calcaneus and the supporting surface, as assessed on lateral radiographs. Lower inclination angles of water suggest flatter feet, however, the suggested normal values apply only to the adult population (17.9-25.4° for males and 17.2° for males and 17.2° for males). for male and range 17.2°). -23.3° for female).

Calcaneal-first metatarsal angle

It is the angle formed on the lateral radiograph by extending a line parallel to the inferior surface of the tibia over the sternocleidomastoid muscle and the dorsal surface of the first ankle. A larger value indicates a flatter foot, and the recommended normal range is 128.1-136.1° for men and 129.3-137.4° for women

Talo-navicular coverage angle

It is formed by a line, drawn on an anteroposterior radiograph, connecting the anterior and lateral poles of the nail tip, and a line drawn along the proximal articular surface of the pelvis. In flat feet, the tip of the nail is no longer covered by its joint with the pelvis and the angle of coverage of the toenail increases (may exceed 19.3° in men and 21.7° in women). with flat feet).

IMAGING DIAGNOSTIC FLATFOOT

Routine standard radiographs are not necessary for diagnosis. However, they should always be indicated for more accurate assessment of nonspecific pain, reduced flexibility, and for surgical planning^[42]. Anterior, posterior, and oblique views of the weight-bearing foot and ankle (AP) should be obtained. Ankle radiographs may show signs of ankle instability or even overload and medial physical damage. Hindfoot alignment can also be assessed using Saltzman X-rays^[43].

In case of accessory pelvic syndrome, in addition to the above mentioned projections, it is recommended to see the internal rotation oblique view. The pelvic union is best seen on 45° off-angle rotation,

while the pelvic union is best visualized on the axial view.

The most common radiographic measurement used is Meary’s angle (or talar-first metatarsal angle): An angle formed by a line through the long axis of the hoof and pelvis relative to the first tarsal axis. Flat feet show a negative Meany angle (apex plantar). In the lateral foot view, one can measure the angle of the lateral toenail, the angle of the ankle, and the pitch of the toenail. On the AP leg projection, one can assess the ankle angle and coverage angle of the ankle.

Computed tomography (CT) and magnetic resonance imaging (MRI) are not necessary unless in patients with an uncommon cause of flatfoot deformity^[44].

CT scans (possibly with weights) represent the gold standard for evaluating ankle connections. While many patients with tarsal fusion show some radiographic evidence (ie, the “C” sign, stony ridge, or fibrous bridge), sometimes this evidence may not be present, or unclear on standard radiographs^[6]. Similarly, MRI provides additional information on fibrous associations as well as in cases of accessory pelvic syndrome where the posterior tibial tendon may be injured^[45].

Normal Alignment

Radiography is used commonly for measuring foot alignment (Table 1). In the context of AAFD, measurements are used principally to evaluate longitudinal arch flattening, hindfoot valgus, and forefoot abduction (Table 1). The most commonly used metrics for the longitudinal arch are the Meary angle, the calcaneal inclination angle, and the calcaneal-fifth metatarsal angle (Figures 4).

DIAGNOSIS AND TREATMENT FOR PEDIATRIC FLATFOOT

This clinical practice guideline (CPG) is based on consensus of current clinical practice and a review of the clinical literature. This guideline was developed by the American College of Foot and Ankle Surgeons Clinical Practice Guidelines for Children. Instructions and references annotate each node of the respective paths.

PEDIATRIC FLATFOOT

Foot and ankle specialists admit, flat foot deformity is a common disease in pediatric patients. Flattening of the medial arch is a common finding in flat-footed people, and it is common in both children and adults. Pediatric flatfoot includes a group of conditions occurring in infants, children, and adolescents^[46] distinguished by

anatomical and etiological factors.

Flat feet may exist as a separate disease or as part of a larger clinical entity^[47]. These entities include general ligament laxity, nerve and muscle abnormalities, genetic conditions and syndromes, and collagen disorders.

Flat feet in children can be divided into flexible and rigid types. Flexible flat feet are characterized by normal arch when not carrying weights and flattened arch when standing. Flexible flat feet may be asymptomatic or symptomatic. Rigid flat feet are characterized by a flat arch that stiffens under load and reduces weight. Most flatulence diseases are associated with an underlying disease that requires special consideration.

Skewfoot is an uncommon disorder characterized by a back foot

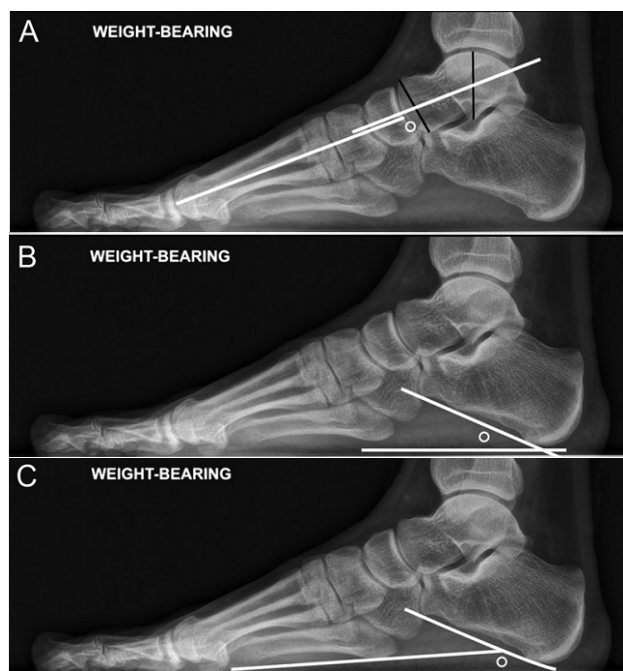


Figure 4 The three most commonly used measurements of foot alignment and arch integrity in a normal foot. A, Lateral radiograph shows the Meary angle between the axis of the talus bone and that of the first metatarsal. These axes are normally parallel and typically overlap, forming a nearly continuous line. The Meary angle is sensitive for diagnosis of AAFD, because it measures structures located at the medial column. B, Lateral radiograph shows the calcaneal inclination angle (or the calcaneal pitch angle), which is the angle between the inferior calcaneus and the horizontal plane. C, Lateral radiograph shows the calcaneus-fifth metatarsal angle, which is the angle between the inferior calcaneus and the inferior surface of the fifth metatarsal. Both structures are located at the lateral column.

Table 1 Commonly Used Radiographic Metrics of Foot Alignment.

		Alignment Angle (degrees)	
Metric	Construction	Normal	Abnormal
Lateral view: assessment of longitudinal arch			
Talus–first metatarsal angle (Meary angle)	Angle between the long axis of the talus and the long axis of the first metatarsal	0 (parallel)	Mild: > 4; Moderate: > 15; Severe: > 30
Calcaneal inclination angle	Angle between the line at the plantar calcaneal surface and the horizontal plane	20–30	Pes planus: <18
Calcaneal–fifth metatarsal angle	Angle between the line at the plantar calcaneal surface and the line at the inferior fifth metatarsal shaft	150–165	> 170
Anteroposterior view: assessment of heel valgus and forefoot abduction			
Talocalcaneal angle (kite angle)	Angle between the line bisecting the head and neck of the talus and the line parallel to the lateral surface of the calcaneus	>25–40	>40 (heel valgus); <25 (heel varus)
Talus–first metatarsal alignment	Line drawn along the long axis of the talus, extended into the forefoot, its orientation compared with that of the first metatarsal shaft	Talar axis angled slightly lateral to the shaft	Talar axis angled medial to the shaft
Talonavicular coverage angle	Angle between the articular surface of the talar head and the articular surface of the proximal navicular bone	0 (parallel)	>7

and an enlarged forefoot. Skewfoot has features of flatfoot and adductovarus deformity^[48].

Important history

Pediatricians and parents are often the first to recognize foot and ankle conditions in infants and children, but problems can go undetected for a long time. Age of onset is important for diagnostic and therapeutic decision-making. Additional considerations include family history, associated medical conditions, presence or absence of symptoms, history of trauma, activity level, prior treatment, and thorough review of systems.

No improvement, or clinical worsening, has been noted, contrary to the normal course and suggesting that the problem is more likely to persist with the potential for pathological sequelae. A family history of flatfoot suggests that similar problems can occur in children. Obesity, neuromuscular disorders, and structural abnormalities above the ankle (eg, retinopathy of the eye, tibia, tibia, femur inversion, length difference extremities) can influence both the natural history and severity of childhood flatfoot.

Flat feet can be associated with a number of subjective symptoms that may include foot, leg, and knee pain and postural symptoms. A history of trauma — acute or repetitive — can cause or manifest deformity of the foot. Flatfoot deformity can lead to reduced endurance and voluntary cessation of physical activities. Prior treatment may have modified the clinical presentation^[47]. A comprehensive history and review of systems may reveal previously unsuspected medical conditions^[47]. For example, history may reveal clumsiness and frequent falls. Difficulty climbing and difficulty arising from the floor associated with flatfoot may be indicative of Becker or Duchenne muscular dystrophy.

Significant Findings: The appearance of the foot during weight-bearing and non-weight-bearing indicates the presence and deformity pattern of flatfoot. Physical findings may include low arch structure, posterior foot dislocation, medial tarsal protrusion, altered gait, and the presence of calluses.

Assess the foot by assessing the ankle and foot flexors (with the knee extended and flexed) and the range of motion of the hindfoot, midfoot, and forefoot. The relationship of the forefoot to the hindfoot was also evaluated. The deformity can occur in flat feet in children, occurring along the medial column and at the top of the ankle, meniscus, dorsal sinus, and ankle.

The gait should be observed when the child is barefoot and wearing shoes. Gait should be assessed for prominence of midfoot, angle of foot advance, foot inclination (head turning and standing up during the hold phase), mid-heel contact with toes, the position of the knee and the presence of a limp.

Diagnostic observations and manipulations include heel inversion on tiptoe, medial arch reconstruction with hallucinations, and “too much toe sign.” Other physical findings including obesity, tibial pathology, genu valgum, tibial torsion, femoral torsion, dystonia, and ligamentous laxity may modify both the natural history and severity of flatfoot^[48].

Diagnosis: Information from the initial assessment and diagnostic tests correlates into a diagnosis. The differential diagnosis of flatfoot in children includes the following: soft flatfoot; rigid flat foot: congenital longitudinal talus (CVT); tarsal coalition; peroneal spastic flat foot no union; iatrogenic and deformity after trauma; oblique legs; and flatfoot from other, less frequently, causes^[47] Note that 4 of these conditions are longitudinal tarsus, dorsal fusion, lateral contracture flatfoot Unbonded and deformed iron/post-traumatic bones are rigid flatfoot types.

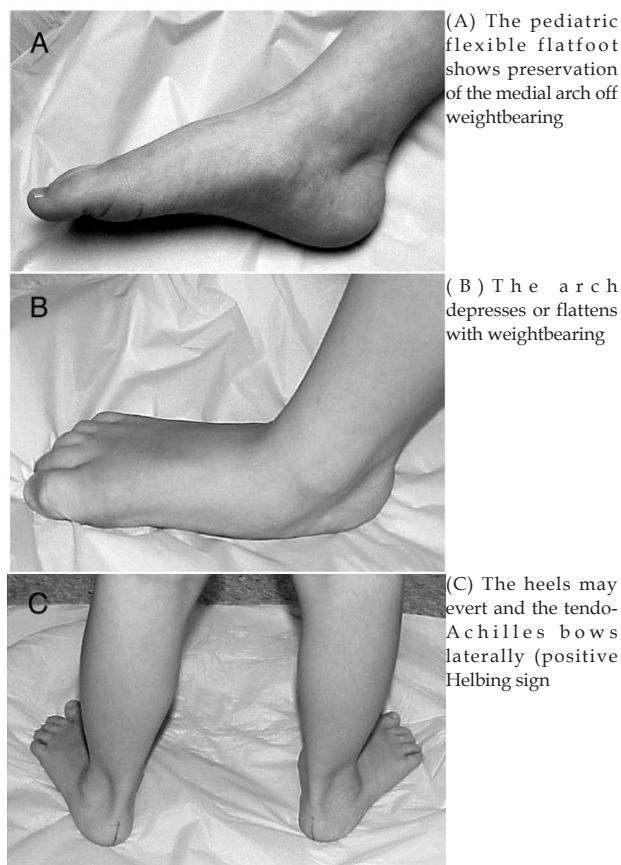


Figure 5 A-C. The pediatric flexible flatfoot. Imaging options may include radiographs (weight), computed tomography (CT), magnetic resonance imaging (MRI), and bone scans. Serological studies may be performed to distinguish mechanical symptoms or drug abuse from arthralgia, arthritis, and other inflammatory diseases in children.

Flexible Flatfoot

Asymptomatic Flexible Flatfoot: Asymptomatic soft flat feet can be physiological or non-physiological. Most types of flexor flatulence are physiological, asymptomatic, and require no treatment^[49]. Physiologically flexible flat feet follow a history of natural improvement over time. Periodic observation may be indicated to monitor for signs of progression. Treatment is usually not indicated^[50].

Nonphysiologically flexible flatfoot is characterized by progression over time. The degree of deformity is more severe in the non-physiological form than in the physiologically soft flatfoot. Excessive amount of heel stimulation; unstable pelvis. Additional findings include too tight heel laces and gait disturbances. Periodic observation is indicated for nonphysiological soft flat feet. Patients with heel laces may benefit from stretching^[49]. Orthotics may also be specified.

Children with asymptomatic floppy feet should be monitored clinically for symptoms and signs of progression. Continuous progression requires reevaluation to identify other underlying disease.

Symptomatic Flexible Flatfoot: Unlike asymptomatic and physiological soft flatfoot, symptomatic forms of soft flatfoot produce subjective complaints, alter function, and produce important objective findings. These include pain along the medial side of the foot; pain in the sphenoid sinus, legs and knees; reduced endurance; gait disorder; prominent central talu head; spike heels; and the tightness of the heel strap (**Figures 5**).

Initial treatment includes activity correction and chiropractic. Stretching exercises for equine deformities can be performed under the supervision of a physician or physiotherapist. Non-steroidal anti-inflammatory drugs may be indicated in more severe cases. Comorbidities, such as obesity, ligament sprains, hypotonia, and proximal limb problems, must be identified and managed, where possible.

If there is a positive clinical response and symptoms resolve, follow-up and orthopedics (when appropriate) should be instituted. If the clinical response is unsatisfactory, re-evaluation and additional work will be indicated.

When all nonsurgical treatment options have been exhausted, surgical intervention may be considered^[51].

Treatment: Non-surgical Approaches

If a child's flatfoot is asymptomatic, treatment is often not required. Instead, the condition will be observed and re-evaluated periodically by the foot and ankle surgeon. Custom orthotic devices may be considered for some cases of asymptomatic flatfoot (Figures 6).

In symptomatic pediatric flatfoot, treatment is required. The foot and ankle surgeon may select one or more approaches, depending on the child's particular case. Some examples of non-surgical options include: (1) **Activity modifications.** The child needs to temporarily decrease activities that bring pain as well as avoid prolonged walking or standing. (2) **Orthotic devices.** The foot and ankle surgeon can provide custom orthotic devices that fit inside the shoe to support the structure of the foot and improve function. (3) **Physical therapy.** Stretching exercises, supervised by the foot and ankle surgeon or a physical therapist, provide relief in some cases of flatfoot. (4) **Medications.** Nonsteroidal anti-inflammatory drugs (NSAIDs), such as ibuprofen, may be recommended to help reduce pain and inflammation. (5) **Shoe modifications.** The foot and ankle surgeon will advise you on footwear characteristics that are important for the child with flatfoot.

Treatment: In general, painless flatfoot requires no special treatment. Flexible flatfoot in a child almost never causes any problems and asymptomatic flexible flatfoot requires no treatment, and no evidence indicates that early treatment will prevent the development of symptomatic flexible flatfoot as an adult. In one prospective study^[52] 98 children with flexible flatfoot were treated with corrective orthopedic shoes, Helfeheel cup, a custom-molded plastic heel cup, or received no treatment.

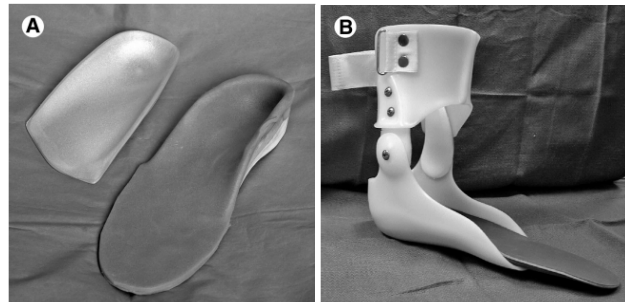
All of the groups demonstrated a significant improvement on radiographs, with no difference apparent among the groups after three years. Some children, however, may rapidly wear out the medial aspect of standard footwear. Excessive wear on shoes may be minimized by wearing more durable orthopedic oxford shoes, medial longitudinal arch supports and/or medial heel wedges. Proper footwear is important for the developing foot; but, whenever safety and comfort allow, going barefoot stimulates

The reduced incidence of flatfoot seen in barefoot populations suggests that muscle strength and mobility may be important factors in the normal development of the arches, and that a child is more likely to develop a flexible, yet strong arch when going barefoot. There is also evidence that using arch supports or even wearing shoes regularly before age 6 may worsen flat foot by interfering with the normal development of foot muscles (Figures 7).

If the child is 10 or older, the flexible flatfoot can be considered permanent, and long-term use of orthotics will be required to prevent future problems in the feet, lower extremities, and spine. This is especially true for overweight or athletically active young who are

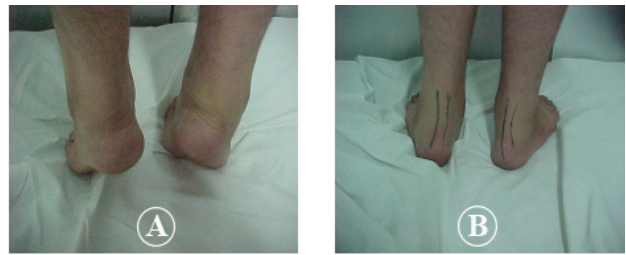

Figure 6 A-B. Tiptoe standing test, A: heel valgus and flat foot during weight bearing. B: during tiptoe standing, the heels toward the varus and arcges appear which show flexibility of flatfoot, proprioceptors and encourages muscular coordination and strength.



Figures 7 A-B. Orthotic management of flatfoot is accomplished with foot orthoses, which often include custom-made devices to accommodate the unique topography and degree of deformity present in the individual. The orthotic device may possess features of (A) a medial arch flange or deep heel seat, or (B) a full AFO (ankle-foot orthosis) that will support the entire ankle-tarsal complex.

symptomatic. They may experience mild aching along the bottom of the foot. Depending on the nature of the pain, treatment might begin with heel cord stretching exercises. If it persists, shoe inserts might be needed. Surgical treatment for persistent pain is rarely needed.

RIGID FLATFOOT

When Is Surgery Needed?

In some cases, surgery is necessary to relieve the symptoms and improve foot function. Foot and ankle surgeons perform a variety of techniques to treat the different types of pediatric flatfoot. The surgical procedure or combination of procedures selected for your child will depend on his or her particular type of flatfoot and degree of deformity.

A potentially negative effect of extrinsic factors on the shape and development of the longitudinal arch is suggested, but not proven, by studies from developing countries. In 1958, Sim-Fook and Hodgson^[53] reported that the flatfeet in their non-shoe-wearing Chinese study subjects were asymptomatic, mobile, and flexible. Somewhat surprisingly, they found a slightly higher incidence of flatfeet among the shoe-wearing population, some of which were painful and exhibited restricted mobility. Cavanagh^[54], in 1980, similarly reported that flatfoot was more common in children in India who wore close-toed shoes than in those who did not wear shoes or who wore slippers or sandals.

Surgery is rarely, if ever, indicated for flexible flatfoot. If the goal of surgery is to change the shape of the foot, a shape that does not necessarily create problems, the documented risks and complications related to surgery must be weighed against the generally benign natural history of the foot shape itself. Nevertheless, numerous surgical procedures to correct flatfoot have been proposed during the last century. They will be discussed and referenced specifically in the following paragraphs. The indications for these procedures, whether for the correction of deformity, relief of symptoms, or

prophylaxis against anticipated pain and disability, are difficult to ascertain from a review of the literature. Therefore, the absolute and comparative success of these procedures is unclear because the reported series: used inconsistent surgical indications; likely included at least some patients with diagnoses other than true FFF; had patients of significantly different ages; lacked standardized evaluation criteria; and frequently had short follow-up. The procedures can be categorized as soft tissue plications, tendon lengthenings and transfers (**Figure 8**), osseous excisions, osteotomies, arthrodesis of one or more joints, and the interposition of bone or synthetic implants into the sinus tarsi. Combinations of these procedures have been reported.

Rigid flat feet are characterized by a lowered arch in both weightlifters and non-weightlifters and reduced or no movement of the hindfoot and midfoot. Rigid flat feet may or may not be symptomatic. Most cases are related to the underlying disease that can be diagnosed by physical examination and imaging.

The differential diagnosis of spastic flatfoot in children includes CVT (congenital longitudinal) tarsal arthropathy, dorsal intervertebral spondylolisthesis, periosteal spastic flatfoot, and arthropathy trauma or anemia.

Bone excision operations^[55] have been abandoned because of their obvious destructive nature. Arthrodesis of one or more of the joints in the subtalar complex has been abandoned as treatment for FFF because of the detrimental effect of eliminating the shock absorbing function of that important joint complex. Talo-navicular^[56], subtalar^[57], and triple^[58] throdeses shift stress to the ankle and mid-tarsal joints, leading to premature degenerative arthrosis at those sites^[58, 59, 60] (**Figures 9, 10, 11**).

Congenital Vertical Talus: CVT deformity, also known as congenital convex pes valgus, is used by severe equinus of the rearfoot and by a rigid rocker-bottom appearance. There are 2 classes of this deformity: teratologic and idiopathic.

Teratologic CVT indicates the presence of underlying comorbid conditions. These include genetic syndromes, spinal dysraphisms, prune belly syndrome, de Barys syndrome, distal arthrogyposis, arthrogyposis multiplex congenita, congenital metacarpotalar syndrome, Rasmussen syndrome, and a host of chromosomal abnormalities.

Idiopathic CVT lacks specific etiologic factors. CVT has been associated with a tarsal coalition. Genetic issues in idiopathic CVT have not been resolved because of inconclusive data. Results of some studies suggest a hereditary component, whereas others fail to show patterns of inheritance.

Significant History: CVT deformity should be diagnosed at birth but it is sometimes confused with calcaneovalgus deformity or physiologic flatfoot. Symptoms begin at walking age, with difficulty bearing weight and wearing shoes. There may be a history of previous successful treatment.

Significant Findings: CVT is used by a rigid rocker-bottom appearance to the foot. Pathology findings include dorsal dislocation of the talonavicular joint, ankle equinus, contracture of the tendo-Achilles, long-toe flexors, posterior ankle capsule, peroneal tendons, and the anterior compartment tendons. The tibionavicular ligament is involved; the calcaneonavicular (spring) ligament is elongated.

The forefoot is most frequently abducted, but may occasionally be added^[61]. The calcaneocuboid articulation often remodels so that the entire plantar aspect of the foot is convex. Tibialis posterior and the peroneals may be displaced, the talar head becomes misshapen, and the deformity is extremely rigid. It is most likely resistant to closed reduction.

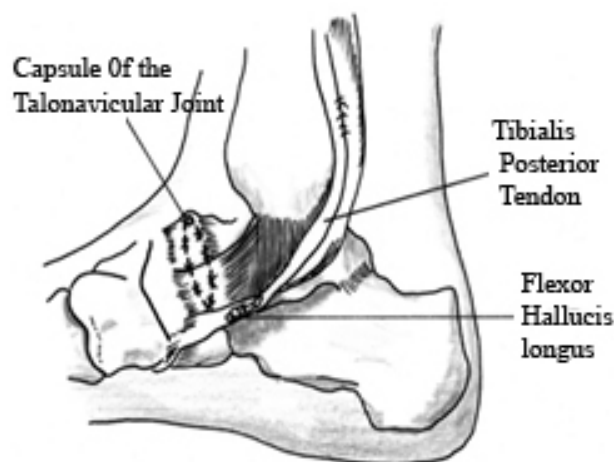


Figure 8 Schematic presentation of Tendon transfer and Augmentation of the Capsule of the Talonavicular Joint.

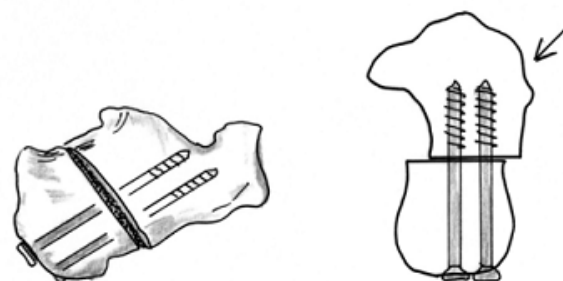
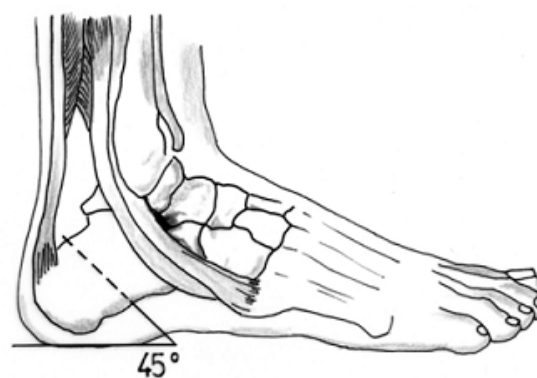


Figure 9 Schematic presentation for Medial Calcaneal Osteotomy.

Diagnostic Imaging: Plain radiographs are most often diagnostic. Lateral weightbearing radiographs show parallelism between the tibia and the talus. The calcaneus is in equinus.

If the navicular has not ossified, a plantarflexion stress lateral radiograph will determine the reducibility of the forefoot on the talus. The longitudinal axis of the first metatarsal will not align with the bisection of the talus. If the navicular has already ossified, its malposition in reference to the talus is visualized. It is not reduced on plantarflexion.

On the anteroposterior (AP) projection, the talocalcaneal (Kite) angle will be very wide. The navicular (if visualized)

Tarsal Coalition: The dorsal trunk connection is a congenital union of two or more tarsal bones that may be tubular, cartilaginous, or fibrous connections. The dorsal alignment rate is 1% to 2%^[62]. Talocalcaneal and calcaneonavicular bars are the most common. The Talocalcaneal union is most commonly found in the midface^[62]. Talonavicular and calcaneocuboid unions have also been described

but are much less common. Autosomal dominant inheritance has been suggested^[62] (**Figures 12**).

Important history: Dorsal association may be asymptomatic^[63]. Children and parents may be aware of foot and ankle stiffness, altered foot shape, muscle spasms, and protective gait abnormalities. Symptoms of a neck link are most common in adolescents or young adults who experience sudden weight gain and who engage in physical activities, such as sports and other forms of physical labor. The onset of symptoms may be insidious, ending with minor trauma or altered activity.

Significant findings: Most symptomatic links present with localized pain around the lateral ankle, sphenoid sinus, submandibular joint, or link site. Reduced or no range of motion of the hindfoot, with or without muscle spasms, and to some degree stiff flatfoot.

Pelvic junctions can be seen on both lateral and oblique radiographs of the foot as superior and medial extensions of the pelvis toward the lower pelvis (**Figure 12**). Depending on the degree of ossification of the bridge, there may be a gum line separating the 2 bones.

The 45° oblique plain radiograph view is best for detecting the pelvic union. Middle talocalcaneal alliances are difficult to visualize because of the complexity of their nature and because many are cartilaginous. Lateral radiographs may show a “C” sign or a halo sign (the C-shaped line formed by the medial border of the dome and the basilar fascia, which is a secondary sign of a union). Harris-Beath’s projections can be helpful, but they can be difficult to interpret because of problems with poor networks. If positive, the joint end plates of the midface are irregular, the faces are downward and centered, and there may be obvious partial bridging. If the angle of inclination is more than 20°, union is possible. Because of their difficulty in interpretation, CT and MRI studies have largely superseded Harris-Beath’s predictions (**Figure 12**).

CT is the diagnostic test of choice because of its ability to show tubular structures. It is especially useful for visualizing talocalcaneal alliances and for evaluating multiple alliances. Coronary imaging shows their location and involvement^[64].

MRI is particularly useful in evaluating the immature skeleton and determining the presence of other causes of peritoneal pain^[62]. It is useful in assessing fibrocartilage union and undifferentiated association in very young individuals^[62].

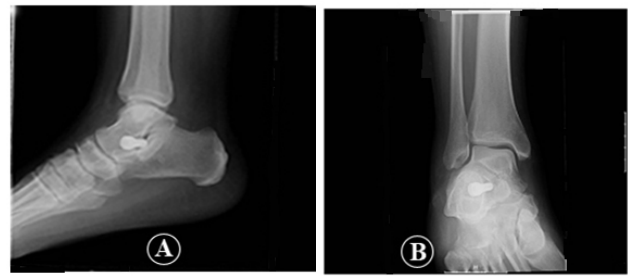
Bone scans were used to show increased stress at the joint surfaces. Bone scintigraphy is sensitive but not specific^[65].

Diagnose: The diagnosis of neck conjunctivitis is based on pain and loss of motion and supported by appropriate imaging studies. Links were classified by location, interstitial tissue type, degree of involvement, and secondary degenerative changes. Initial treatment.

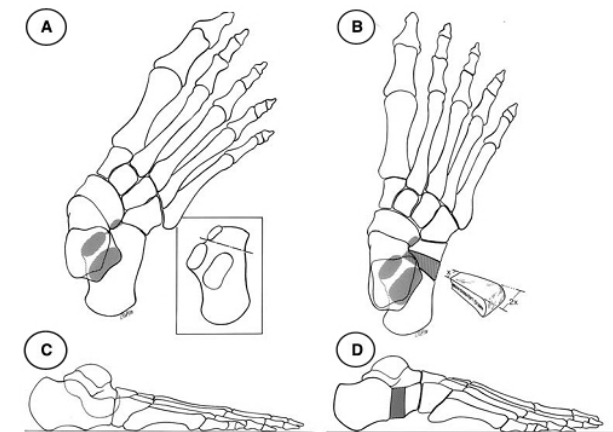
The initial treatment for any alliance should be nonsurgical^[62]. Patients with mild symptoms may respond well to a change in footwear, arch support, or custom orthotics. Activity modifiers, weight loss, anti-inflammatory drugs, and local anesthetic blocks may also be indicated (90). Cast immobilization for several weeks may be indicated for patients with more severe symptoms or peritoneal spasm.

Clinical response: After a period of nonsurgical treatment, the patient should be reevaluated. If symptoms are in remission, initial treatment options should be continued, with periodic monitoring of clinical progression.

Surgical intervention: Surgery should be considered for those who do not respond to nonsurgical treatment. Surgical treatment depends on the type of union. Union ablation may be indicated for individuals with no significant deformity or joint (**Figure 13**). In some cases,



Figures 10 A-B. Inserted screw to subtalar Joint.



Figures 11 A-B. Painful FFF. a, c Anteroposterior (AP) and lateral preoperative sketches of actual radiographs. The talo-first metatarsal angle is markedly abducted on the AP view. The lateral view shows severe talonavicular sag and a 0° calcaneal pitch. b, d AP and lateral sketches of actual radiographs following a calcaneal lengthening osteotomy and tendo-Achilles lengthening. All components of the deformity are corrected, subtalar motion is preserved, and symptoms are relieved.

cervical spondylectomy may be the procedure of choice.

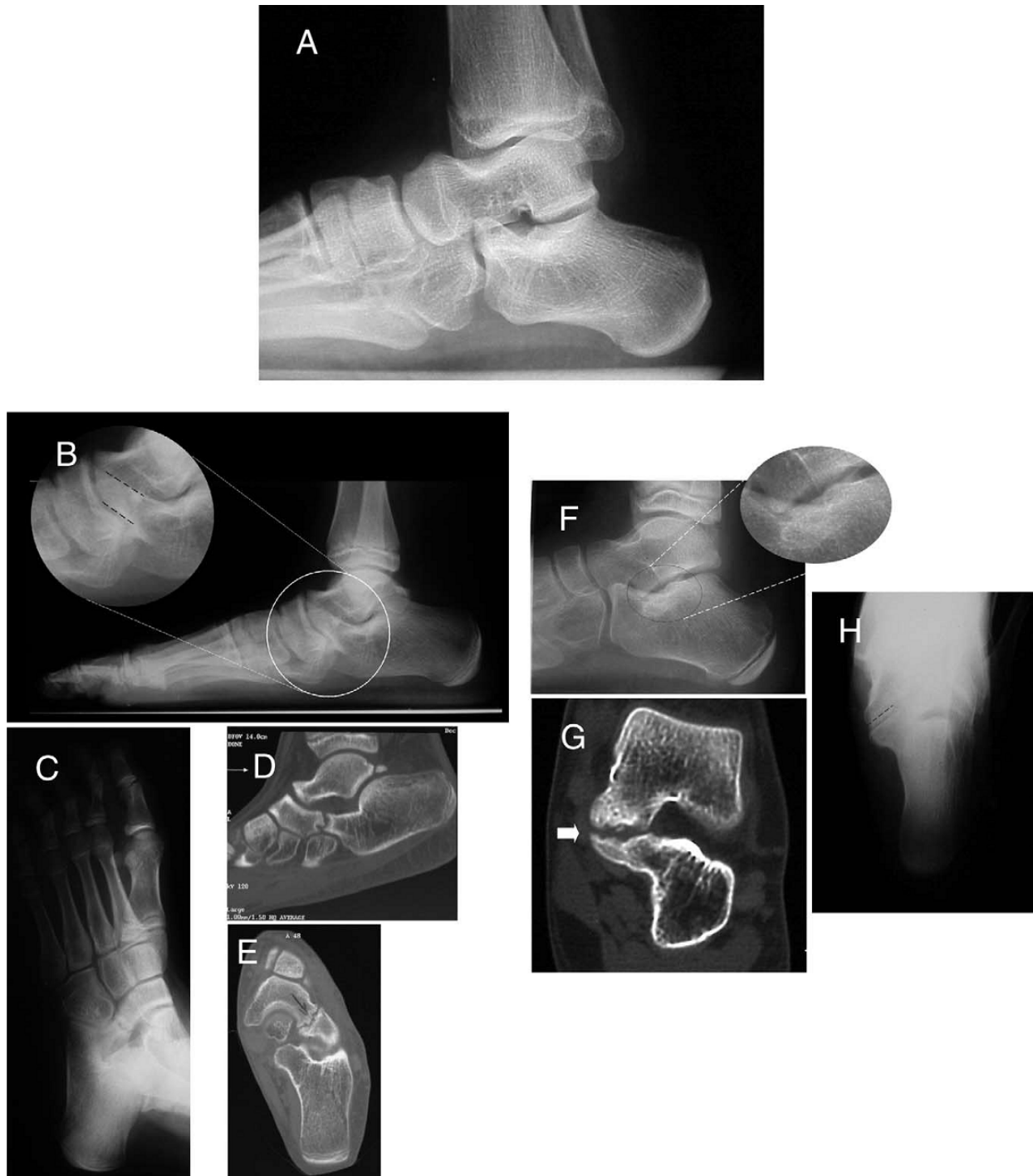In children with foot deformities, osteotomy combined with amputation should be performed. If significant joint changes are found, joint therapeutic techniques should be considered. The isolated talocalcaneal arthrodesis is indicated for submetallic alliances. If peritoneal degeneration is evident, a 3-joint puncture may also be indicated^[66].

Observation and supportive orthopedics should follow surgery (Node 8). If symptoms recur, the patient may need to return to nonsurgical options. These measures are unlikely to relieve symptoms adequately.

Peroneal Spastic Flatfoot Without Coalition: Unlinked peripelvic flatfoot is a painful foot deformity caused by contraction of the external muscles. Although dorsal trunk association is the most common cause of perimuscular spastic flatfoot, its presence cannot be confirmed in some cases. Other possible causes include juvenile rheumatoid arthritis^[67] sternoclavicular fracture of the hind foot, osteosarcoma, osteosarcoma^[68], dysplasia epiphysealis hemimelica (Trevor’s disease)^[69], and problems in the more proximal extremities (capital femoral slip)^[70]. When no cause can be found, the condition is referred to as idiopathic peroneal spastic flatfoot.

Important history: The patient has pain in the foot, followed by limitation of movement of the extrinsic muscles. Pain may occur with activity and symptoms may stem from trauma. Many patients had previously been evaluated for ankle alignment, but there were no objective or imaging findings to support the diagnosis.

Significant findings: Perineal muscle spasms, limited movement under the bones and ankles, foot indentations, and constant



Figures 12 Tarsal coalitions account for most rigid flatfoot deformities seen at the community level. (A) Talonavicular coalition may be seen as an incidental finding. These feet are usually asymptomatic. Calcaneonavicular bars are common. (B) The lateral radiograph shows an exaggerated projection of the distal calcaneus (anteater sign). (C) Lateral oblique projection shows the connection between the calcaneus and the navicular. (D and E) MRI and CT imaging techniques better delineate the pathology. The talocalcaneal coalition may be diagnostically more difficult. (F) The lateral radiograph may show irregularity of the middle facet or complete obliteration of the middle facet. (G) Special views, such as the Harris-Beath projection, should show parallel relationship between the middle and posterior facets. (G) Shown here is an oblique and poorly visualized middle facet. (H) This is verified with a CT image

or intermittent pain in response to activity are all signs of this condition. Clinical findings are not limited to the pelvic muscles. The extensions, anterior and posterior portions of the tibialis muscle are all involved.

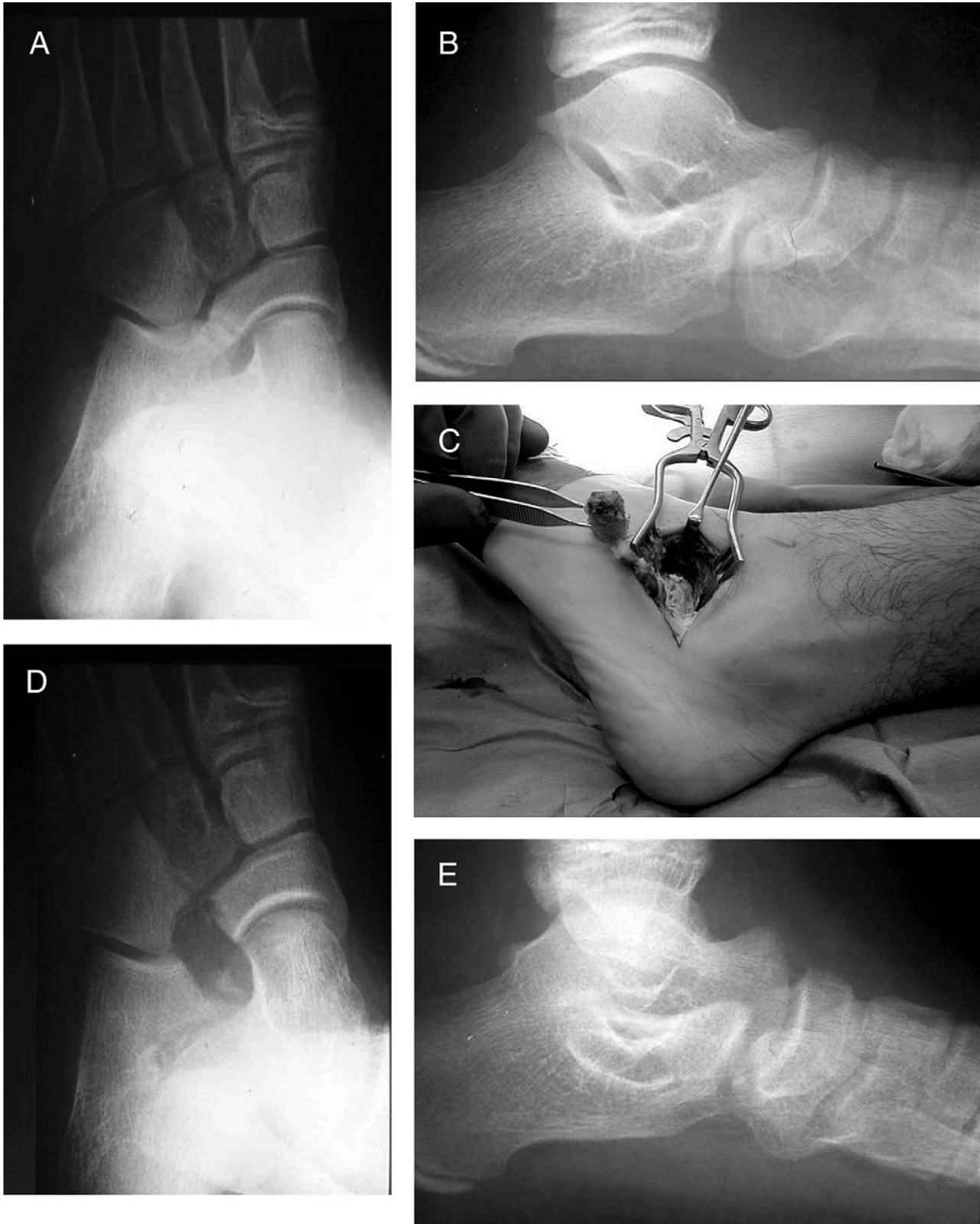
An out-of-the-way style with forward rotation of the foot. There is little or no thrust during the late postural phase of gait.

Diagnostic studies: Diagnostic imaging that does not show the lumbar intervertebral or the typical secondary findings of the lumbar intervertebral column may suggest other conditions that may explain

the condition, such as sternum defects, pathologic fractures, etc. bone cysts or osteomyelitis.

Preliminary bone scans can help locate the pathology. Whole body scintigraphy is useful to rule out many anatomical silent sites in systemic disease. In some cases, all imaging studies may be normal and further clinical investigation is indicated.

Laboratory studies should include an adequate blood cell count with differential reagents and an acute phase (erythrocyte sedimentation rate and C-reactive protein). Elevated inflammatory



Figures 13 Calcaneonavicular coalitions may be fibrous, cartilaginous, or osseous. Younger patients may benefit by excision of the bar. (A and B) Oblique and lateral radiographs demonstrate the bar as well as the pronatory foot deformity. (C) Shown is an intraoperative view of the excised fragment. Excision should restore the mobility of the rearfoot complex. (DandE) The postoperative oblique and lateral radiographs show adequate resection of the extraarticular bar.

markers suggest a rheumatic etiology and warrant further investigation or consultation.

Diagnose: Periosteal spastic flatfoot is a diagnosis of exclusion and may ultimately be considered idiopathic.

Initial treatment: When a specific cause is discovered, appropriate

treatment is directed to that cause. If the cause is unknown, the symptoms will determine the type of treatment. When symptoms are intermittent, activity modification may be helpful. This may include stopping sports, discouraging running and jumping activities, and removing the child from physical education class.

Activity modulation can be supplemented with non-steroidal anti-inflammatory drugs. Footwear modifications, arch support, and orthotics may also be beneficial.

In more difficult cases, immobilization with walking boots can be helpful. However, patient compliance is often an issue. This can be resolved with a cast under the knee and crutches. In extreme cases, the above cast can be considered. Perioral nerve blocks can often be both therapeutic and diagnostic.

Clinical response: If clinical response to treatment leads to resolution of symptoms and pain-free restoration of range of motion, further chiropractic treatment may be indicated and the patient should be monitored periodically.

Surgical intervention: If symptoms do not resolve with nonsurgical treatment, surgical options may be considered. Surgical procedures include osteotomy and bone reconstruction. Observation and supportive orthopedics should follow surgery.

Latrogenic and Posttraumatic Deformity: In more difficult cases, immobilization with walking boots can be helpful. However, patient compliance is often an issue. This can be resolved with a cast under the knee and crutches. In extreme cases, the above cast can be considered. Perioral nerve blocks are usually treatable and diagnosable.

Clinical response: If clinical response to treatment results in resolution of symptoms and restoration of range of motion without pain, additional chiropractic treatment may be indicated and the patient should be monitored periodically. period.

Surgical intervention: If symptoms do not resolve with nonsurgical treatment, surgical options may be considered. Surgical procedures include osteotomy and bone reconstruction. Observation and orthopedic support should follow the surgery.

This is especially true for talipes equinovarus^[71]. The goal of treatment is a flexible, stiff, and pain-free foot. In many cases, a perfect outcome is not possible. Often, the end result is a stiff foot and hopefully a stump.

Etiological factors include overcorrected clubfoot, uncorrected longitudinal nail^[72], unsuccessful flatfoot surgery, and end-stage trauma. Flat feet from an accident or after trauma can also be caused by manipulating a baby's soft, vulnerable infant's foot.

Important history: Patients with flatfoot or after trauma present with varying degrees of pain, loss of function, and progressive deformity. All of the feet in this category have a history of previous manipulation, surgery, or trauma. The onset of flatfoot can be immediate or slow down over several months or years.

Significant findings: Examination can identify pain, stiffness, scarring, abnormal function, and gait disturbance.

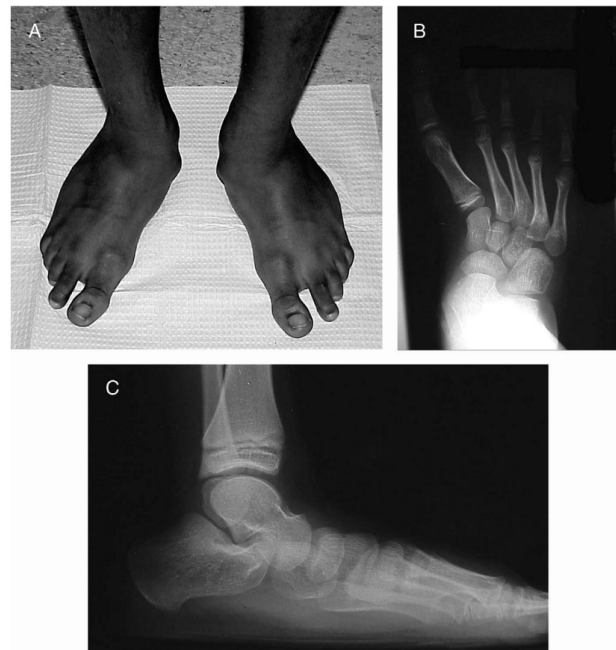Image analysis: Radiographs alone can show postoperative changes, retained hardware and implants, misalignment, and arthritis. CT, MRI, and bone scans can be helpful in further identifying deformities and evaluating residual pathology.

Diagnose: The patient's history, along with imaging studies, confirms the diagnosis of flat or post-traumatic foot.

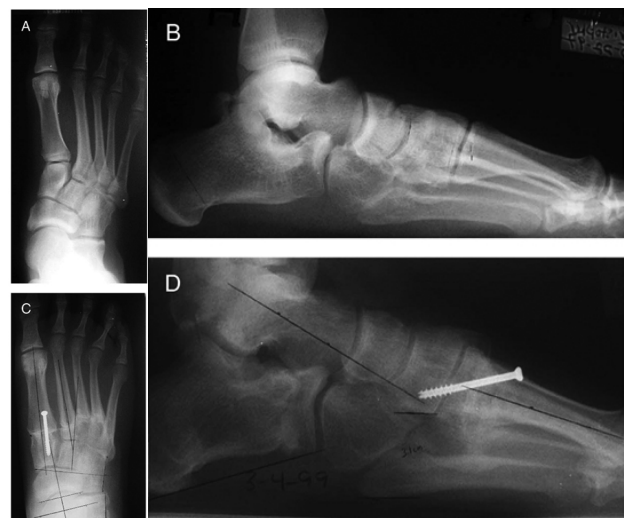
Initial treatment: Shoe modifications and splints may be indicated in the initial management of these deformities. Activity modification, weight loss, physical therapy, and non-steroidal anti-inflammatory drugs may be helpful.

Clinical response: If clinical response is satisfactory, continue monitoring and nonoperative management (Nodes 7 and 8).

Surgical intervention: If unresponsive to nonsurgical treatment, surgical intervention (Node 9) may be necessary to achieve the goal of stable pain-free paraplegia. Specific procedures target the deformity and condition of soft tissues, joints, and tubular structures.



Figures 14 Skewfoot, an uncommon but very severe variant of the flatfoot deformity, is characterized by rearfoot pronation, midfoot abduction, and metatarsus adductus. (A) This clinical photograph of an adolescent patient with skewfoot shows forefoot adduction—unlike forefoot abduction seen with most other flatfoot deformities. (B) The AP radiograph shows very prominent metatarsus adductus deformity with a large talocalcaneal angle. (C) The lateral radiograph shows sagittal plane failure of the medial column with talar ptosis (pathologic declination).



Figures 15 A. The AP radiograph is generally diagnostic. There is a Z orientation of the rearfoot, midfoot, and forefoot areas. B. Lateral radiograph shows the typical findings of pronation deformity. C and D. AP lateral radiographs show the surgical results of meta-tarsal-first cuneiform arthrodesis in combination with lesser metatarsal osteotomies to correct the metatarsus adductus, and a lateral column lengthening osteotomy of the calcaneus (Evans procedure).

Patient and parent education should be provided to encourage realistic expectations.

Soft tissue release, osteotomy, and arthroplasty^[72] are the most frequently used procedures. In certain cases, serious malformations can be identified by evidence of osteogenic distraction (Ilizarov)^[73]. Rarely, in cases of intractable pain and unstable deformity or chronic osteomyelitis, amputation followed by rehabilitation is a reasonable option for the patient to return to activities.

The patient should be observed for observation. Recurrence is possible and requires reevaluation.

Skewfoot: Skewfoot is used by the addition of the forefoot (metatarsus adductus) and the heel valgus^[74]. More severe cases involve middle leg abduction. There are no common clinical or radiological criteria for oblique foot disease and the natural history of idiopathic oblique foot disease is poorly understood. There are four types of foot dislocation: congenital idiopathic, syndromic, neurogenic, and iatrogenic.

Important history: Scoliosis may be asymptomatic or associated with pain from activity and difficulty wearing shoes^[75]. It is often misdiagnosed as large ankles and flexible flat feet. Oblique foot should be suspected if the infant does not respond favorably to the treatment of vitreous allergy.

Significant findings: The deformity is used as an S or Z-shaped foot with forefoot and hindfoot valgus^[74]. In children under 1 year of age, hindfoot deformities are not as obvious as forefoot deformities. There may be contracture of tendon-Achilles. Calluses and other skin problems can occur.

Image analysis: Standard radiographs show vitreous tamponade and severe heel spur (**Figure 14**).

Diagnose: Clinical and radiographic findings support confirmation of the diagnosis of oblique foot disease.

Initial treatment: Asymptomatic misalignment in older children does not require treatment. Management of oblique foot is based on age, severity, and presence of symptoms^[76]. Manipulation and serial casting can be assigned to Children^[76]. Stretching and activity-modifying exercises may relieve mild symptoms but they will not alter deformity. Splinting can be used to relieve symptoms but may relieve symptoms when the ankle is present. Nonsteroidal anti-inflammatory drugs may also be beneficial. Management of comorbidities is important.

Clinical response: Clinical response to treatment was assessed. Observation and continuation of initial treatment options are recommended for children in remission (Node 8).

Surgical intervention: Severe persistent symptoms may require surgical intervention. Surgical treatment must address both the forefoot and the hindfoot components (Figure 15). Helpful procedures include tarsal osteotomy and midfoot osteotomy to correct the forefoot. Lateral column lengthening, musculoskeletal osteotomy, and calcaneal tendon lengthening are used to correct the hindfoot.

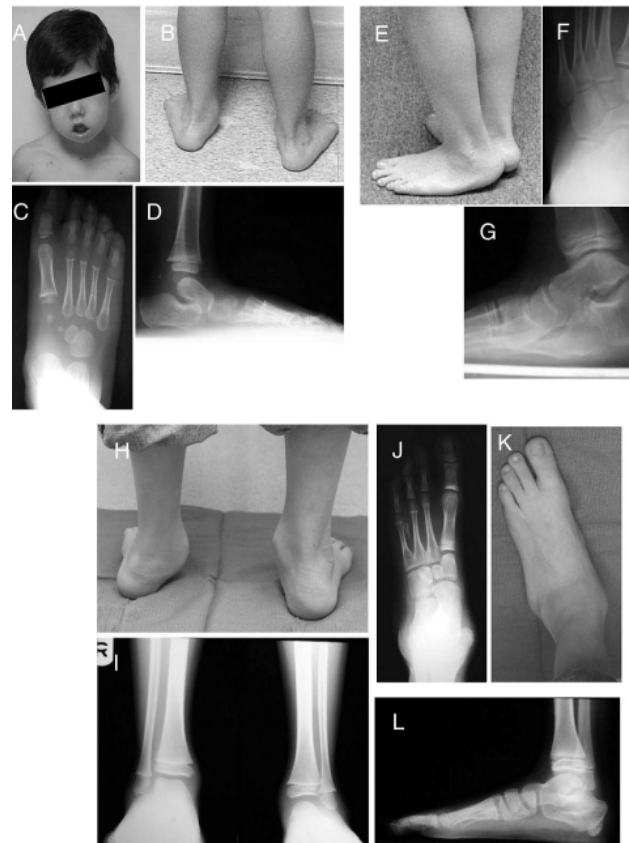
Other Causes of Pediatric Flatfoot: Some forms of childhood flatfoot deformities are not suitable for previous programs. They are unique because their clinical findings are dictated by the underlying disease.

In addition, the clinical approach to diagnosis and treatment depends on the etiology. Some have a completely unpredictable natural history and early intervention is undesirable until the problem has fully revealed itself.

Important history: These forms of flatfoot in children are associated with general ligament laxity; Marfan's disease; Ehlers Danlos; and Down syndrome, cerebral palsy, myeloma, growth retardation, genetic diseases and other syndromes (Figure 16).

Significant findings: Different types of foot deformities can be seen. The deformities range from ultra-mobility to rigidity. The physical examination of these children should include observational gait analysis, general joint mobility assessment to look for hyper- and dysarthria, and a thorough neurological examination. Feet should be checked for mobility, calluses and skin irritation.

Image analysis: Imaging should be performed according to clinical indications.



Figures 16 Flatfoot deformities in combination with systemic disease and syndromic patterns may be extremely difficult to treat. (A) Children with congenital myotonic dystrophy show characteristic facial weakness with a cupid bow mouth and inexpressive appearance. (B) Pronatory foot deformities are a regular feature shown clinically by excessive relaxed calcaneal stance position.

Diagnose: There is nothing unique about this group of pathologies that has not been discussed before. Refer to previous roadmaps for detailed discussion.

Initial treatment: When planning the treatment of flatfoot in children with pre-existing conditions, it is important to consider the patient's baseline function, the need for foot rest, and the natural history of the disease. pre-existing. Asymptomatic hyperplasia in children with the syndrome is usually best left alone (Node 5).

Treatment is based on the structural deformity and functional need placed on the foot. Treatment is usually indicated if the child is walking or is likely to become an ambulance. Children with an unstable base of support secondary to flatfoot can be treated with supportive orthopedics.

Surgical intervention: If splinting is unacceptable or does not provide a solid base of support, surgical intervention may be considered. Surgical options are aimed at the specific pathology and include osteopathic surgery, spondylolisthesis, spondylectomy, and tendon transfer. Long-term orthopedic management after surgical intervention is often recommended to maximize function.

Complications of flatfoot

One of the first signs that you may have fallen is pain. Sore feet and a tendency to swollen ankles, especially after standing or walking for long periods of time, are classic signs of flat feet. But they can also indicate other conditions, so it's best to seek professional diagnosis. Among the ten simple remedies that can resolve your flatfoot pain, such as custom orthotic devices that you wear inside your shoes to

compensate for a dropped arch. But if left untreated, your flat feet can lead to other health problems.

Plantar fasciitis: The ligament that runs from the back of the heel and through the length of the sole of the foot, called the plantar fascia, is susceptible to inflammation, a condition called plantar fasciitis. Characterized by heel pain that seems worse in the morning when you take your first steps of the day, plantar fasciitis often begins with flat feet.

Achilles tendonitis: Flat feet cause the Achilles tendon, which connects the calf to the heel, to work harder every time you walk or run. That additional stress can cause minor tears and tendinitis, a condition known as Achilles tendonitis.

To prevent the disease from progressing to a more severe form of Achilles tendinitis, it's best to rest, apply ice, and take anti-inflammatory medications. We may also recommend a brace or other orthopedic device to help stabilize as the wound heals.

Arthritis: A good arch will definitely give your feet, ankles, and the rest of your body a solid and stable foundation. When your arch is flat, you lose significant stability, and your joints tend to suffer the consequences of overuse. Overworked joints are prone to arthritis because the protective cartilage layer wears away and allows bones to rub against each other.

Toe problem: The shoe is designed to fit the foot of a person of normal arch height. If you have flat feet, shoes rubbing in the wrong place will lead to calluses and blisters. Over time, you can also develop bunion, joint deformity at the base of the big toe or big toe, and abnormal contractures of the toe joint.

Foot problem: Of course, flat feet are a problem in the legs, but they also lead to other complications in the legs. Technically, the tendon that makes up the normal arch of the foot is called the posterior tibial tendon, and whether you have a flat foot or not, if it becomes inflamed, you will have posterior tibial tendonitis and its accompanying symptoms, painful and unstable.

And if your foot sticks out (turns inward) because you don't have a supporting arch, it throws off your muscle balance and leads to calcium buildup and abnormal bone growth called heel.

Your feet and ankles have a huge responsibility in how they hold the weight of your entire body. That means any minor issues with your foot will automatically throw things out of alignment and set the stage for injury.

The first is your feet. Flat feet don't distribute your weight evenly, putting undue stress on the muscles, bones, and tendons of your legs, leading to shin splints and stress fractures.

If you are experiencing any complications of flatfoot, Dr. Preece or Dr. Groberg can treat your condition, help you manage flatfoot and keep you mobile and pain-free. Again. Contact us at 801-285-6332 or request an online appointment to learn how to treat your flatfoot.

Complications of flatfoot after surgery

Common complications of tricuspid arthritis are bone failure, varus deformity of the hind foot, arthritis secondary to the medial and ankle joints, wound infections, organ failure, etc.

Non-healing wounds are a major cause of persistent pain and dissatisfaction after surgery. The most common disorganized location is the fish-scale roof fork. We believe that good results and few complications can be achieved if surgeons pay attention to relevant factors such as correct judgment and preservation of lower extremity incisions, strict aseptic technique and tissue protection. softness, suitable incision selection, etc. in detail. There are relatively few cases of lack of randomized controlled trials and long-term follow-up. Future research should be improved gradually.

CONCLUSION

Pes planus is really a diagnosis of common sense with variable causes. Each patient must be evaluated thoroughly to determine the underlying cause of flat plate. Treatment plans should be individualized to cause and reserved for symptomatic cases or cases where family history, gait dysfunction, or other comorbidities suggest a greater likelihood of dysfunction overtime.

REFERENCES

1. Rao UB, Joseph B. The influence of footwear on the prevalence of flat foot. *J Bone Joint Surg.* 1992; **74B**: 525-527. [PMID: 1624509]
2. Rose GK. Flat feet in children. *Br Med J.* 1990; **301**: 1330-1331 [PMID: 3820110]; [DOI: 10.7547/87507315-77-1-2]
3. Staheli LT. Evaluation of planovalgus foot deformities with special reference to the natural history. *J Am Pediatr Med Assoc.* 1987; **77**: 2-6. [PMID: 3820110]; [DOI: 10.7547/87507315-77-1-2]
4. Lelivre J, Lelivre JF. *Patología del pie.* Barcelona, Spain: Toray Masson; 1982
5. Viladot A. Nuevo método de exploración estática del pie: El fotopodograma. *Clin Lab.* 1954; **57**: 114-154
6. Giannestras NJ. *Trastornos del pie.* Barcelona, Spain: Salvat; 1979
7. Brooks MH. Flat feet in children. *Br Med J.* 1991; **302**: 237
8. Fowler AW. Correspondence. *J Bone Joint Surg.* 1990; **72A**: 471
9. Volpon JB. Footprint analysis during the growth period. *J Pediatr Orthop.* 1994; **14**: 83-85 [PMID: 8113378]; [DOI: 10.1097/01241398-199401000-00017]
10. Harris EJ, Vanore JV, Thomas JL, et al. Diagnosis and treatment of flat feet in children. *J Foot Ankle Surg.* 2004; **43**: 341-373. [PMID: 15605048]; [DOI: 10.1053/j.jfas.2004.09.013]
11. Wenger DR, Mauldin D, Speck G, et al. Corrective shoes and inserts as treatment for flexible flatfoot in infants and children. *J Bone Joint Surg Am* 1989; **71(6)**: 800-10. [PMID: 2663868]
12. Staheli L, Chew DE, Corbett M. The longitudinal arch. A survey of eight hundred and eighty-two feet in normal children and adults. *J Bone Joint Surg Am* 1987; **69(2)**: 426-8. [PMID: 3818704]
13. Gould N, Moreland M, Alvarez R, et al: Development of the child's arch History and Pathophysiology of Flexible Flatfoot 2156. *Foot Ankle* 1989; **9(5)**: 241-5. [PMID: 2731836]; [DOI: 10.1177/107110078900900506]
14. Garcia-Rodriguez A, Martin-Jimenez F, Carnero-Varo M, et al. Flexible flat feet in children: a real problem? *Pediatrics* 1999; **103(6)**: e84.
15. Lin CJ, Lai KA, Kuan TS, et al. Correlating factors and clinical significance of flexible flatfoot in preschool children. *J Pediatr Orthop* 2001; **21(3)**: 378-82.
16. El O, Akcali O, Kosay C, et al. Flexible flatfoot and related factors in primary school children: a report of a screening study. *Rheumatol Int* 2006; **26(11)**: 1050-3.
17. Pfeiffer M, Kotz R, Ledl T, et al. Prevalence of flat foot in preschool-aged children. *Pediatrics* 2006; **118 (2)**: 634-9. [PMID: 16882817]; [DOI: 10.1542/peds.2005-2126]
18. Harris RI, Beath T. Hypermobil flatfoot with short tendo Achilles. *J Bone Joint Surg Am* 1948; **30**: 116-40. [PMID: 18921631]
19. Cowan DN, Jones BH, Robinson JR. Foot morphologic characteristics and risk of exercise-related injury. *Arch Fam Med* 1993; **2(7)**: 223-4. [PMID: 7906597]; [DOI: 10.1001/archfam.2.7.773]
20. Rudzki SJ. Injuries in Australian Army recruits. Part III: the accuracy of a pretraining orthopedics screen in predicting ultimate injury outcome. *Mil Med* 1997; **162(7)**: 41-3. [PMID: 9232978]
21. Hogan MT, Staheli LT. Arch height and lower limb pain: an

- adult civilian study. *Foot Ankle Int* 2002; **23**(1): 43-7. [PMID: 11822691]; [DOI: 10.1177/107110070202300108]
22. Abdel-Fattah MM, Hassanin MM, Felembane FA, et al. Flat foot among Saudi Arabian army recruits: prevalence and risk factors. *East Mediterr Health J.* 2006; **12** (1-2): 211-7. [PMID: 17037240]
 23. Stern HJ, Clark RD, Stroberg AJ, Shohat M. Autosomal dominant transmission of isolated congenital vertical talus. *Clin Genet* 1989 Dec; **36**(6): 427-30. [PMID: 2591068]
 24. Lowy LJ. Pediatric peroneal spastic flatfoot in the absence of coalition. A suggested protocol. *J Am Podiatr Med Assoc* 1998; **88**(4): 181-91. [PMID: 9581436]; [DOI: 10.7547/87507315-88-4-181]
 25. Goldner JL, Keats PK, Bassett FH, et al. Progressive talipes equinovarus due to trauma or degeneration of the posterior tibial tendon and medial plantar ligaments. *Orthop Clin North Am.* 1974; **5**(1): 39-51. [PMID: 4809543]
 26. Sachithanandam V, Joseph B. Influence of footwear on the prevalence of flat foot. A survey of 1846 skeletally mature persons. *J Bone Joint Surg.* 1995; **77**(2): 254-7. [PMID: 7706341]
 27. Mann R, Inman VT. Phasic activity of intrinsic muscles of the foot. *J Bone Joint Surg Am* 1969; **46**: 469-481. [PMID: 14131426]
 28. Holmes CF, Wilcox D, Fletcher JP. Effect of a modified, low-dye medial longitudinal arch taping procedure on the subtalar joint neutral position before and after light exercise. *J Orthop Sports Phys Ther* 2002; **32**(5): 194-201. [PMID: 12014823]; [DOI: 10.2519/jospt.2002.32.5.194]
 29. Manter JT. Movements of the subtalar and transverse tarsal joints. *Anat Rec* 1941; **80**: 397-410
 30. Scarpa A. A memoir on the congenital club feet of children, and of the mode of correcting that deformity. Edinburgh: Archibald Constable, **1818**: 8-15 (Translated by Wishart JH, Clin Orthop Relat Res 308: 4-7) [PMID: 7955698]
 31. Mann R, Inman VT. Phasic activity of intrinsic muscles of the foot. *J Bone Joint Surg Am* 1969; **46**: 469-481 [PMID: 14131426]
 32. Riegger CL. Anatomy of the ankle and foot. *Phys Ther* 1988; **68**(12): 1802-1814.
 33. Gray H. Arthrology. In: *Anatomy of the Human Body*. 37th ed. Edinburgh, Scotland: Churchill Livingstone, 1989; 542-544. [doi: 10.1136/emj.2005.027847]
 34. Richie DH Jr. Biomechanics and clinical analysis of the adult acquired flatfoot. *Clin Podiatr Med Surg* 2007; **24**(4): 617-644. [PMID: 17908633]; [DOI: 10.1016/j.cpm.2007.07.003]
 35. Gould N, Moreland M, Alvarez R, Trevino S, Fenwick J. Development of the child's arch. *Foot Ankle* 1989; **9** (5): 241-245. [PMID: 2731836]; [DOI: 10.1177/107110078900900506]
 36. Mital M. Children's feet. common worries of parents. *Prof Care Mother Child.* 2000; **10**(2): 33-4. [PMID: 11040762]
 37. Pfeiffer M, Kotz R, Ledl T, Hauser G, Sluga M. Prevalence of flat foot in preschool-aged children. *Pediatrics* 2006; **118**: 634-639. [PMID: 16882817]; [DOI: 10.1542/peds.2005-2126]
 38. Haendlmayer KT, Harris NJ. Flatfoot deformity: an overview. *Orthopaedics and Trauma* 2009; **23**: 395-403.
 39. Moore K., Dalley AF, Agur AMR. Clinically Oriented Anatomy. Lippincott Williams & Wilkins, Philadelphia (USA).
 40. Riola C, Palma A. Functional anatomy and imaging of the foot. *Ital. J. Anat. Embryol* 2001; **106**: 85-98. [PMID: 11504250]
 41. Murley GS, Menz HB, Landorf KB. A protocol for classifying normal and flat-arched foot posture for research studies using clinical and radiographic measurements. *J. Foot Ankle Res.* 2009; **2**: 22. [PMID: 19575811]; [DOI: 10.1186/1757-1146-2-22]
 42. De Pellegrin M, Moharamzadeh D, Strobl WM, Biedermann R, Tschauer C, Wirth T. Subtalar extra-articular screw arthroereisis (SESA) for the treatment of flexible flatfoot in children. *J Child Orthop.* 2014; **8**: 479-487. [PMID: 25413354]; [DOI: 10.1007/s11832-014-0619-7]
 43. Saltzman CL, el-Khoury GY. The hindfoot alignment view. *Foot Ankle Int.* 1995; **16**: 572-576. [PMID: 8563927]; [DOI: 10.1177/107110079501600911]
 44. Uselli FG, Montrasio UA. The calcaneo-stop procedure. *Foot Ankle Clin.* 2012; **17**: 183-194. [PMID: 22541519]; [DOI: 10.1016/j.fcl.2012.03.001]
 45. Dare DM, Dodwell ER. Pediatric flatfoot: cause, epidemiology, assessment, and treatment. *Curr Opin Pediatr.* 2014; **26**: 93-100. [PMID: 24346183]; [DOI: 10.1097/MOP.0000000000000039]
 46. Trott AW. Children's foot problems. *Orthop Clin North Am.* 1982; **13**: 641-654. [PMID: 7099593]
 47. Hefti F. Foot pain. *Orthopade.* 1999; **28**: 173-179. [PMID: 28246749]; [DOI: 10.1007/PL00003594]
 48. Sullivan RW. Correction of the hypermobile flatfoot by the subtalar arthroereisis procedure. *Mil Med.* 1985; **150**: 546-548.
 49. Cappello T, Song KM. Determining treatment of flatfeet in children. *Curr Opin Pediatr* 1998; **10**: 77-81. [PMID: 9529644]; [DOI: 10.1097/00008480-199802000-00016]
 50. Staheli LT. Planovalgus foot deformity. Current status. *J Am Podiatr Med Assoc* 1999; **89**: 94-99. [PMID: 10063780]; [DOI: 10.7547/87507315-89-2-94]
 51. Cappello T, Song KM. Determining treatment of flatfeet in children. *Curr Opin Pediatr* 1998; **10**: 77-81. [PMID: 9529644]; [DOI: 10.1097/00008480-199802000-00016]
 52. Hicks JH. The function of the plantar aponeurosis. *J Anat* 1951; **85**: 414-5.
 53. Sim-Fook L, Hodgson AR. A comparison of foot forms among the non-shoe and shoe-wearing Chinese population. *J Bone Joint Surg Am* 1958; **40**: 1058-1062 [PMID: 13587573]
 54. Cavanagh PR, Ae M. A technique for the display of pressure distributions beneath the foot. *J Biomech* 1980; **13**: 69-75. [DOI: 10.1016/0021-9290(80)90180-3]
 55. Evans D. Calcaneo-valgus deformity. *J Bone Joint Surg [Br]* 1975; **57**-B: 270-278. [PMID: 1171869]
 56. Davitt JS, MacWilliams BA, Armstrong PF. Plantar pressure and radiographic changes after distal calcaneal lengthening in children and adolescents. *J Pediatr Orthop* 2001; **21**: 70-75. [PMID: 11176357]; [DOI: 10.1097/00004694-200101000-00015]
 57. Oeffinger DJ, Pectol RW Jr, Tylkowski CM. Foot pressure and radiographic outcome measures of lateral column lengthening for pes planovalgus deformity. *Gait Posture* 2000; **12**: 189-195. [PMID: 11154928]; [DOI: 10.1016/S0966-6362(00)00075-8]
 58. Noritake K, Yoshihashi Y, Miyata T. Calcaneal lengthening for planovalgus foot deformity in children with spastic cerebral palsy. *J Pediatr Orthop B* 2005; **14**: 274-279. [PMID: 32099288]; [DOI: 10.1016/j.jcot.2018.07.021]
 59. Ettl V, Wollmerstedt N, Kirschner S, et al. Calcaneal lengthening for planovalgus deformity in children with cerebral palsy. *Foot Ankle Int* 2009; **30**: 398-404. [PMID: 19439138]; [DOI: 10.3113/FAI-2009-0398]
 60. Yoo WJ, Chung CY, Choi IH, Cho TJ, Kim DH. Calcaneal lengthening for the planovalgus foot deformity in children with cerebral palsy. *J Pediatr Orthop* 2005; **25**: 781-785. [PMID: 16294136]; [DOI: 10.1097/01.bpo.0000184650.26852.37]
 61. Badelon O, Rigault P, Pouliquen JC, Padovani JP, Guyonvarch J. Congenital convex clubfoot: a diagnostic and therapeutic study of 71 cases. *Int Orthop* 1984; **8**: 211-221. [PMID: 6530318]; [DOI: 10.1007/bf00269918]
 62. Kulik SA Jr, Clanton TO. Tarsal coalition. *Foot Ankle Int* 1996; **17**: 286-296. [PMID: 8734800]; [DOI: 10.1177/107110079601700509]
 63. Thometz J. Tarsal coalitions. *Foot Ankle Clin* 2002; **5**: 103-117.
 64. Herzenberg JE, Goldner JL, Martinez S, Silverman PM. Computerized tomography of talocalcaneal tarsal coalition: a clinical and anatomic study. *Foot Ankle* 1896; **6**: 273-288. [DOI: 10.1177/107110078600600601]
 65. de Lima RT, Mishkins FS. The bone scan in tarsal coalition: a case

- report. *Pediatric Radiology* 1996; **26**: 754-756. [DOI: 10.1007/BF01383400]
66. Cowell HR. Diagnosis and management of peroneal spastic flatfoot. *Instr Course Lect* 1975; **24**: 93-103.
 67. Glockenberg A, Weinreb A, Pevny J. Rheumatoid arthritis-induced peroneal spastic flatfoot. *J Am Podiatr Med Assoc* 1987; **77**: 185-187. [PMID: 3585749]; [DOI: 10.7547/87507315-77-4-185]
 68. Johnson JC. Peroneal spastic flatfoot syndrome. *SouthMed J* 1976; **69**: 807-809. [PMID: 935918]; [DOI: 10.1097/00007611-197606000-00043]
 69. Graves SC, Kuester DJ, Richardson EG. Dysplasia epiphysealis hemimelica (Trevor disease) presenting as peroneal spastic flatfoot deformity: a case report. *Foot Ankle* 1991; **12**: 55-58, 1991. [DOI: 10.1177/107110079101200111]
 70. Doig SG, Menelaus MB. Association of slipped upper femoral epiphysis and peroneal spastic flatfoot. *J Pediatr Orthop* 1991; **11**: 220-221. [DOI: 10.1097/01241398-199103000-00016]
 71. Weseley MS, Barenfeld PA, Barrett N. Complications of the treatment of clubfoot. *Clin Orthop* 1872; **84**: 93-96. [DOI: 10.1097/00003086-197205000-00017]
 72. Coleman SS. *Complex Foot Deformities in Children*, Lea and Febinger, Philadelphia, 1983.
 73. Herzenberg JE, Paley D. Ilizarov management of clubfoot deformity in young children. In *Foot and Ankle Clinics*, edited by MS Myerson, Saunders, Philadelphia, 1998.
 74. Green WB. Metatarsus adductus and skewfoot. *Instr Course Lect* 1994; **43**: 161-177, 1994.
 75. Mosca VS. Calcaneal lengthening for valgus deformity of the hindfoot. Results in children who had severe, symptomatic flatfoot and skewfoot. *J Bone Joint Surg* 1995; **77A**: 500-512.
 76. Covalier R, Lipton GE, Baden JR. Radiological case study. *Orthopedics* 1997; **20**: 727-730.