

Stromal Vascular Fraction for Musculoskeletal Lesions

E. Carlos Rodriguez-Merchan^{1,2}, MD, PhD; Carlos A. Encinas-Ullan¹, MD

1 Department of Orthopedic Surgery, La Paz University Hospital-IdiPaz, Madrid, Spain;

2 Osteoarticular Surgery Research, Hospital La Paz Institute for Health Research, IdiPAZ (La Paz University Hospital, Autonomous University of Madrid), Madrid, Spain;

Research performed at the Department of Orthopedic Surgery, La Paz University Hospital, Madrid, Spain.

Conflict-of-interest statement: The author(s) declare(s) that there is no conflict of interest regarding the publication of this paper.

Open-Access: This article is an open-access article which was selected by an in-house editor and fully peer-reviewed by external reviewers. It is distributed in accordance with the Creative Commons Attribution Non Commercial (CC BY-NC 4.0) license, which permits others to distribute, remix, adapt, build upon this work non-commercially, and license their derivative works on different terms, provided the original work is properly cited and the use is non-commercial. See: <http://creativecommons.org/licenses/by-nc/4.0/>

Correspondence to: E. Carlos Rodriguez-Merchan, Department of Orthopaedic Surgery, La Paz University Hospital-IdiPaz, Paseo de la Castellana 261, 28046-Madrid, Spain.

Email: ecrmerchan@hotmail.com

Received: May 23, 2022

Revised: June 7, 2022

Accepted: June 9 2022

Published online: June 28, 2022

ABSTRACT

Several clinical studies appear to demonstrate that intra-tendinous injections of stromal vascular fraction (SVF) are safe and effective in athletes suffering from recalcitrant Achilles tendinopathy and chronic lateral elbow tendinopathy. It has also been reported that intra-articular SVF injections appear to be effective and safe for the treatment of knee osteoarthritis. Local application of SVF has also proven useful in chronic diabetic foot ulcers. Ready-to-use extracellular matrix/SVF gel appears to be a favorable therapeutic approach to facilitating articular cartilage regeneration in patients with chondral lesions. However, there are insufficient high-quality

data to recommend SVF for athletes with sports soft-tissue knee injuries. Several experimental studies have suggested that SVF could be a good option to achieve bone regeneration. To confirm the usefulness of SVF in various musculoskeletal injuries and to recommend its routine clinical use, better designed studies are required.

Key words: Stromal vascular fraction; Osteoarthritis; Tendon healing; Bone regeneration; Cartilage regeneration

© 2022 The Author(s). Published by ACT Publishing Group Ltd. All rights reserved.

Rodriguez-Merchan EC, Encinas-Ullan CA. Stromal Vascular Fraction for Musculoskeletal Lesions. *International Journal of Orthopaedics* 2022; 9(3): 1658-1668 Available from: URL: <http://www.ghrnet.org/index.php/ijo/article/view/3314>

INTRODUCTION

Stromal vascular fraction (SVF) is a byproduct of adipose harvesting of excess fatty tissue. This fraction contains a large number of stem cells, which are known as adipose-derived stem cells (ASCs)^[1-5]. These cells are similar to those derived from bone marrow in that they are capable of multilineage differentiation^[6]. The SVF of adipose tissue is a potent source of various cell types (Figure 1).

According to the systematic review by Gentile et al, SVF cells derived from ASCs have been utilized for decades in regenerative plastic surgery for autologous purposes; however, little attention has been given to their possible allogenic function^[6]. Allogenic SVF transplants could make use of decellularized extracellular matrix as a donor scaffold, which would then be recellularized by the recipient's ASCs, thereby leading to advanced medicinal products for personalized use. These authors reported that allogenic transplantation of ASCs and extracellular matrix (ECM) was safe and effective and without significant adverse effects.

In 2020, Blaudez et al described how decellularized tissues and organs have been effectively utilized in tissue engineering and regenerative medicine^[7]. However, due to the complexity of each tissue (e.g., size, porosity, and ECM composition), there is no standardized protocol. Decellularization methods vary widely and have heterogeneous results. The authors reviewed the most common

strategies to achieve decellularization of soft and hard tissues for bone, tendon, and ligament regeneration. They suggest possible future applications for the use of natural ECM for the decoration of synthetic porous scaffolds⁷¹.

In this narrative review of the literature, the use of SVF for various musculoskeletal lesions is analyzed. The aim of this article is to review the literature on the efficacy of SVF in musculoskeletal injuries, mainly in cartilage, tendon, bone, diabetic foot ulcers, and soft-tissue sport injuries, but also in peripheral nerve injuries, soft-tissue defects, and hip dysplasia

EXPERIMENTAL STUDIES

In PubMed, using “SVF experimental studies” as keywords, there are 120 articles as of May 31, 2022. Of these, only 13 were selected because they were strictly related to the title of this article. Findings from several experimental studies have suggested that SVF could be of great utility in healing various musculoskeletal injuries (including tendon injuries, avascular necrosis of bone, chronic diabetes foot ulcers, degenerative joint disease of the spine, osteochondral defects, and osteoarthritis). Table 1 summarizes the most important studies in this regard¹⁸⁻²⁰.

CLINICAL STUDIES

In PubMed, using “SVF experimental studies” as keywords, there are 108 articles as of May 31, 2022. Of these, only 12 were selected because they were strictly related to the title of this article.

It is very important to know whether SVF is clinically useful in the various locomotor system injuries in which it has been used so far by many authors. In this way we will be able to inform the world orthopedic community about the efficacy of SVF in musculoskeletal pathology. It can be stated that the results of the clinical studies appear to suggest that the use of SVF could help heal various musculoskeletal injuries. These results are presented below according to the various types of lesions treated with SVF.

Cartilage Regeneration

Osteoarthritis: According to Mehranfar et al, osteoarthritis (OA) is one of the main causes of disability worldwide, with a relatively high prevalence in the elderly population²¹. Currently accepted treatments, such as exercise, anti-inflammatory drugs, and intra-articular corticosteroid injections, aim to control the pain experienced by patients with OA. Surgical options, such as osteotomies and joint replacements, are invasive therapeutic options for when conventional treatments fail²²⁻²⁷.

In recent decades, efforts have been made to treat musculoskeletal diseases using regenerative cell therapies. Adipose-derived SVF cells containing several cell types, including mesenchymal stem cells (MSCs), have been shown to be efficacious in the repair of cartilage injuries. An autologous blood product, platelet-rich plasma (PRP), acts as an adjuvant to surgical management, and its intra-articular administration has shown usefulness in the treatment of OA²¹.

Several preclinical studies have analyzed the efficacy of SVF in cartilage regeneration. All of them supported the use of SVF in the treatment of cartilage lesions due to the regenerative power that this product seemed to have²⁸⁻³². Among them, it is important to highlight that of Filardo et al published in 2021. These authors compared three techniques to exploit ASCs to manage OA in a preclinical study. They aimed to better understand ASCs' therapeutic capacity and determine the most appropriate technique for clinical

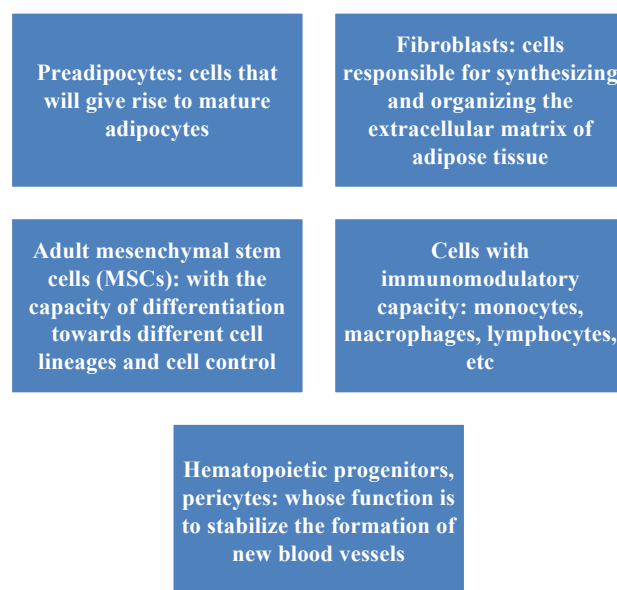


Figure 1 Cell types that are part of the stromal vascular fraction (SVF).

application²⁹. Biological samples of adipose tissue, processed by mechanical micro-fragmentation (MF), enzymatic digestion with SVF, or cell expansion of ASCs, were first characterized *in vitro* and then utilized *in vivo* in a surgically induced OA rabbit model with 4 groups: Group 1, control group (untreated/saline, 12 knees); Group 2, MF (24 knees); Group 3, SVF (24 knees); and Group 4, ASCs (24 knees). At 2 and 4 months following treatment, macroscopic, histological, histomorphometric, immunohistochemical, and blood and synovial fluid analyses were conducted. Samples obtained from all three techniques had 85%-95% viable cells. *In vivo* evaluations demonstrated no significant adverse effects or inflammatory reactions following the injections. The macroscopic Hanashi score showed no significant disparities between the treated groups and the controls. Histopathological assessment of synovial tissues demonstrated fewer signs of synovitis for MF, although the semiquantitative analysis (Krenn score) was not significantly different between the groups. In contrast, MF had the best outcomes in both qualitative and semiquantitative assessments of articular cartilage, with more uniform staining, smoother surfaces, and significantly better Laverty scores. Ultimately, MF, SVF, and expanded ASCs did not produce significant local or systemic complications in this preclinical model of OA. Among the various methods utilized, MF demonstrated the most promising results¹³.

Table 2 shows the main clinical studies on the use of SVF in cartilage regeneration (chondral defects and osteoarthritis)³³⁻⁴⁴.

In 2018, Pak et al published a systematic review on the effectiveness and safety of the management of painful knee, ankle, and hip OA⁴⁵. They concluded that there was no cure for OA for the aforementioned joints, but that management with ASCs, either in the form of adipose SVF cells or culture-expanded cells, could be a treatment option given the favorable data on their safety and efficacy. They also noted the engraftment and trophic factors involved in the mechanisms of cartilage regeneration by ASCs/MSCs. Among the trophic factors, extracellular vesicles, especially exosomes, appear to be increasingly important. The authors noted, however, that better quality investigations were required to clarify the mechanism of action of this type of treatment and to explore the possible use of MSCs on a widespread basis to treat OA by means of cartilage regeneration⁴⁵.

Table 1. Experimental studies on the beneficial role of stromal vascular fraction (SVF) in various musculoskeletal injuries.

AUTHORS	YEAR	INJURY	MATERIALS	RESULTS AND CONCLUSION
Behfar et al [8]	2014	Tendon injury	48 adult male New Zealand white rabbits were used. Twelve of rabbits were used as donors of bone marrow and adipose tissue, the rest were divided into control and treatment groups. The injury model was a unilateral complete transection of the deep digital flexor tendon.	No significant differences were observed at the 3rd week between SVF and BMSCs treated tendons in terms of all load related properties. However, at the 8th week SVF transplantation resulted in significantly increased energy absorption, stress and stiffness compared to BMSCs. The enhanced biomechanical properties of repairs in this study advocated the application of adipose derived SVF as an excellent source of multipotent cells instead of traditional BMSCs.
Marx et al [9]	2014	Hip dysplasia	This study evaluated the effect of autologous SVF (n = 4) or allogeneic cultured ASCs (n = 5) injected into acupuncture points in dogs with hip dysplasia and weak response to drug therapy. Canine ASCs have proliferation and differentiation potential similar to ASCs from other species.	After the first week of treatment, clinical assessment demonstrated marked amelioration compared with baseline results in all patients treated with autologous SVF and three of the dogs treated with allogeneic ASCs. On days 15 and 30, all dogs showed improvement in range of motion, lameness at trot, and pain on manipulation of the joints, except for one ASC-treated patient. Positive results were more clearly seen in the SVF-treated group. These findings showed that autologous SVF or allogeneic ASCs can be safely utilized in acupoint injection for treating hip dysplasia in dogs and represent an important therapeutic option for this type of pathology.
Kappos et al [10]	2015	Peripheral nerve injury	A 10-mm gap in the sciatic nerve of female Sprague-Dawley rats (7 groups of 7 animals, 8 weeks old) was bridged through a biodegradable fibrin conduit filled with ratASCs (rASCs), differentiated rASCs (drASCs), human (h)ASCs from the superficial and deep abdominal layer, human SVF, or rat Schwann cells, respectively. As a control, these authors resutured a nerve segment as an autograft. Long-run assessment was performed after 12 weeks comprising walking track, morphometric, and MRI analyses. The sciatic functional index was calculated. Cross sections of the nerve, proximal, distal, and in between the two sutures, were analyzed for re-/myelination and axon count. Gastrocnemius muscle weights were compared.	MRI proved biodegradation of the conduit. Differentiated rat ASCs performed significantly better than undifferentiated rASCs with less muscle atrophy and superior functional results. Superficial hASCs supported regeneration better than deep hASCs, in line with reported <i>in vitro</i> data. The best regeneration potential was accomplished by the drASC group when compared with other adipose tissue-derived cells. Considering the ease of procedure from harvesting to transplanting, these authors concluded that comparison of promising cells for nerve regeneration revealed that particularly differentiated ASCs could be a clinically translatable route toward new methods to enhance peripheral nerve repair.
Ozkan et al [11]	2016	Peripheral nerve injury	The study included 30 rats which were divided in three groups. In the first stage, an 8 mm nerve defect was created in tibial nerve of each rat. In Group 1, the defect was reconstructed with nerve graft, in group 2, the defect was reconstructed with vein graft, and in group 3, the defect was reconstructed with vein graft filled with SVF solution. After 3 months, the second surgical stage was carried out and nerve biopsies were taken. Tissue samples were observed histopathologically.	There were no statistically meaningful difference between nerve grafts, vein grafts and adipose tissue derived SVF- vein grafts combination groups considering myelin diameter and axonal diameter. Axon count was statistically superior in the nerve graft and study groups when compared to empty vein groups. These results supported the usage of stromal vascular fraction-vein graft combination for peripheral nerve defect repairs.
Ismail et al [12]	2017	Avascular necrosis of bone (AVN)	SVF cells were isolated from lipoaspirates and cultured onto porous hydroxyapatite scaffolds within a perfusion-based bioreactor system for 5 days. The resulting constructs were inserted into devitalized bone cylinders mimicking AVN-affected bone. A ligated vascular bundle was inserted upon subcutaneous implantation of constructs in nude rats. After 1 and 8 weeks <i>in vivo</i> , bone formation and vascularization were analyzed.	Newly-formed bone was encountered in 80% of SVF-seeded scaffolds after 8 weeks but not in unseeded controls. In both experimental groups, devitalized bone was revitalized by vascularized tissue after 8 weeks. SVF cells-based osteogenic constructs revitalized fully necrotic bone in a challenging AVN rat model of clinically-relevant size. SVF cells contributed to accelerated initial vascularization, to bone formation and to recruitment of pro-regenerative endogenous cells.
Deng et al [13]	2019	Chronic diabetes foot ulcer	This study investigated the healing effects of conditioned medium (CM) derived from a physiological 3D culture system engineered to use an extracellular matrix/sSVF) gel enriched for adipose on diabetic wounds in rats. This CM (Gel-CM) was compared with that from a 2D culture system that used SVF cells (SVF-CM). Keratinocytes, fibroblasts and wounds were treated with Gel-CM and SVF-CM, and cytokine levels in the CM types were quantified.	Proliferation and migration of keratinocytes and fibroblasts were higher after treatment with Gel-CM than with SVF-CM. Collagen secretion by fibroblasts and wound closure were highly stimulated by Gel-CM. Proteomic analyses showed a higher concentration of growth factors in Gel-CM than in SVF-CM. Gel-CM appeared to be a promising therapeutic option for managing diabetic wounds.
Kemilew et al [14]	2019	Degenerative joint disease of the spine	The aim of this study was to monitor VEGF levels after the administration of SVF in the course of treatment of dogs suffering from degenerative joint disease in the spinal region. The study was conducted on 10 dogs of both genders, aged between 6 and 13 years in which allogenic SVF of stem cells was administered intravenously. The control group was composed of 10 clinically healthy dogs. Before treatment and after 2- and 8-week intervals blood samples were obtained from the study group dogs in order to determine VEGF levels via immunoenzymatic test.	In a few days after SVF administration, pain relief and reduction of lameness were found. The VEGF level in 2 weeks after treatment was elevated, while in 8 weeks a decrease was encountered. Administration of allogenic stem cells had a positive influence on elevation of the VEGF levels in the blood serum of affected animals as well as their regeneration capacity.

An et al [15]	2020	Large soft tissue defects	The microstructure of EF fragments and the proportion of MSCs; CD45-/CD34+ in EF were detected. Wistar rats were divided into the following 3 groups randomly: the 1-mL EF group, the 0.5-mL EF group, and the control group. The tissue expansion was performed twice a week to maintain the capsule pressure at 60 mm Hg. After 4 weeks, inflation volume and histological changes, which included collagen content, cell proliferation, and capillary density, were observed to assess the effect of EF on tissue expansion.	Mechanical emulsification effectively destroyed the mature adipocytes in adipose tissue. The proportion of MSCs population in the EF fragments was $12.40 \pm 0.86\%$. After expansion, the inflation volume and the levels of collagen deposition, cell proliferation, and capillary density of the expanded tissue in the 1-mL EF group were significantly higher than that in the 0.5-mL EF group and the control group ($p < 0.05$). However, all these regenerative indicators in the 0.5-mL EF group showed no statistical difference from the control group ($p > 0.05$). The thickness of epidermal and dermal layers showed no significant difference among the 3 groups ($P > 0.05$). The findings of this study suggested that EF grafting can be used as a new alternative to increase tissue expansion efficiency.
Sahin et al [16]	2021	Osteochondral defect	This study evaluated the effect of adipose-derived SVF on osteochondral defects treated by hyaluronic acid (HA)-based scaffold in a rabbit model. Eighteen white New Zealand rabbits were randomly grouped into the experimental group (n=9) and control group (n=9). In all groups, osteochondral defects were induced on the weight-bearing surfaces of the right femoral medial condyles, and a HA-based scaffold was applied to the defect area with microfractures (MFs). In this study, 1 mL of adipose-derived SVF was injected into the knee joints of the rabbits in the experimental group.	At week 4, the O'Driscoll scores were higher in the control group than the experimental group, while there was no significant difference in the Brittberg scores between the two groups. At week 8, the O'Driscoll score and Brittberg scores were higher in the experimental group than in the control group. According to the microscopic evaluation, at the end of week 8, the cartilage thickness was greater in the experimental group, and nearly all of the defect area was filled with hyaline cartilage. Application of adipose-derived SVF with MF-HA-based scaffold was better than MF-HA-based scaffold treatment in improving osteochondral regeneration.
Palumbo Piccionello et al [17]	2021	Tendon injury	The hypothesis of this study was that SVF injection would improve tendon healing compared with the control group, decreasing inflammatory and matrix degrading, while augmenting anti-inflammatory expression and collagen synthesis in the early stage of tendon injury. Sixteen Apennine sheep aged 2 to 5 years underwent 500 UI type I collagenase injection into both common calcaneal tendons (CCT) to induce tendinopathy. After 15 days (T0), one CCT in every ovine underwent randomly to 2.5 mL of AAMG obtained by mechanical disruption and the contralateral CCTs received no treatment.	Clinical and ecographic evaluations were carried out after 4 weeks (T1) and 8 weeks (T2). Histological, immunohistochemical, real-time polymerase chain reaction (RT-PCR), and biomechanical evaluations were performed at T2. At T2, the treated group showed a final tendon diameter and a hardness expression (62%) that were similar to the original healthy tendon, with a significant recovery compared with the control group. Moreover, histological analysis of the treated group revealed an improvement in the fiber orientation score, fiber edema score, infiltrative-inflammatory process, and necrosis score compared with control group. Immunohistochemically, the treated group showed high expression of collagen 1, Factor VIII and significantly low expression of collagen 3. These data were confirmed by RT-PCR analysis. The study findings suggested that AAMGs obtained through mechanical disruption present a safe, efficient, and reliable technique, enhancing tendon healing.
Veronesi et al [18]	2021	Early OA	An in vivo model of early OA in sheep was treated through three different cell therapies (culture expanded ADSCs, SVF, and culture expanded AECs) thus to preserve the joint surface from the progression of the pathology. Three months after the treatment injections, their performance was evaluated through mechanical automated mapping (Young's modulus and cartilage thickness), gross evaluation of articular surfaces, and biochemical analysis of the synovial fluid.	No severe degeneration was found after 3 months from OA induction. Cartilage mechanical properties were crucial to identify early degeneration. All the treatments improved the macroscopic cartilage surface aspect and reduced pro-inflammatory cytokines in the synovial fluid. Among the three treatments, SVF highlighted the best performance while ADSCs the worst.
Bari et al [19]	2021	Bone regeneration	In this study, a new strategy to improve SmartBone® (SB) osteoinductivity was developed. SB scaffolds were loaded with lyosecretome, a freeze-dried formulation of mesenchymal stem cell (MSC)-secretome, containing proteins and extracellular vesicles (EVs). Lyosecretome-loaded SB scaffolds (SBlyo) were prepared using an absorption method. A burst release of proteins and EVs (38% and 50% after 30 minutes, respectively) was found, and then proteins were released more slowly with respect to EVs, most likely because they more strongly adsorbed onto the SB surface. In vitro tests were conducted using adipose tissue-SVF plated on SB or SBlyo.	After 14 days, significant cell proliferation improvement was found on SBlyo with respect to SB, where cells filled the cavities between the native trabeculae. On SB, on the other hand, the process was still present, but tissue formation was less organized at 60 days. On both scaffolds, cells differentiated into osteoblasts and were able to mineralize after 60 days. Nevertheless, SBlyo showed a higher expression of osteoblast markers and a higher quantity of newly formed trabeculae than SB alone. The quantification analysis of the newly formed mineralized tissue and the immunohistochemical studies showed that SBlyo induces bone formation more effectively. This osteoinductive effect is likely due to the osteogenic factors present in the lyosecretome, such as fibronectin, alpha-2-macroglobulin, apolipoprotein A, and TGF- β .
Sananta et al [20]	2022	Bone defect	The aim of this study was to determine the effect of administering SVF on bone defects' healing process evaluated based on the TGF- β 1. This was an animal study involving twelve Wistar strain Rattus norvegicus. They were divided into three groups: negative group (normal rats), positive group (rats with bone defect without SVF application), and SVF group (rats with bone defect with SVF application). After 30 days, the rats were sacrificed, the TGF- β 1 biomarker was assessed (quantified using ELISA)	TGF- β 1 biomarker expressions were higher in the group with SVF application than in the group without SVF application. All comparisons of the SVF group and positive control group showed significant differences. SVF application seemed to aid the healing process in a murine model with bone defect, marked by an increased level of TGF- β 1.

BMSCs, bone marrow derived mesenchymal stromal cells; ASCs, adipose-derived stem cells; MRI, magnetic resonance imaging; VEGF, vascular endothelial growth factor; EF, emulsified fat; MSCs, mesenchymal stem cells; AAMG, autologous micro-grafts; OA, osteoarthritis; ADSCs, adipose-derived stem cells; AECs, amniotic epithelial cells; TGF- β 2, transforming growth factor beta; TGF- β 1, transforming growth factor beta1; ELISA, enzyme-linked immunosorbent assay.

Table 2 Clinical studies on stromal vascular fraction (SVF) in cartilage regeneration (chondral defects and osteoarthritis).

AUTHORS	YEAR	MATERIALS	TREATMENT GROUPS	EVALUATION	RESULTS
Kim et al [34]	2014	49 patients (50 ankles) with full-thickness chondral defect of the talar dome	This study compared the clinical and MRI outcomes between an injection of MSCs with marrow stimulation (N=24) and marrow stimulation alone (N=26).	Clinical evaluation Radiography	At 16-25 months, clinical and MRI outcomes of an injection of an SVF containing MSCs with marrow stimulation were encouraging, compared with marrow stimulation alone
Gibbs et al [35]	2015	7 patients with OA of both knees	SVF+PRP	Clinical evaluation	This treatment appeared to be extremely effective for osteoarthritis disorders that have no drug treatment to halt disease progression.
Yokota et al [36]	2017	13 patients (with bilateral severe OA)	SVF	Clinical evaluation	After 1 and 6 months all the scores of JKOM, WOMAC, and VAS were significantly improved over baseline. Ultimately, the scores were improved by an average of 35% over baseline for JKOM, 32% improvement in WOMAC, and 40% for pain (VAS).
Nguyen et al [37]	2017	30 patients with OA	This study compared arthroscopic Microfracture alone with arthroscopic microfracture +SVF+PRP	Clinical evaluation Bone marrow edema	At 12 months all treatment group patients had significantly reduced pain and WOMAC scores, and increased Lysholm and VAS scores compared with the placebo group. These findings suggest that the SVF/PRP injection efficiently improved OA for 18 months after treatment.
Salikhof et al [38]	2018	1 patient with traumatic osteochondral lesion of the right medial femoral condyle 8 months after injury	Microfracture +SVF	Clinical evaluation Bone marrow edema Radiography	At 24 months the clinical score improved from 23 to 96 according to IKDC and from 10 to 90 according to EQ-VAS at 24 months follow-up. MRI 1 and 2 years after the surgery showed the recovery of the damaged cartilage thickness with somewhat uneven structure and a decrease in the trabecular edema of the femoral condyle.
Roato et al [39]	2019	20 patients with OA	SVF	Clinical evaluation Radiography	At 3, 6, and 18 months, all patients reported an improvement in terms of pain reduction and increase of function.
Tran et al [40]	2019	33 patients with OA	This study compared arthroscopic microfracture with arthroscopic microfracture +SVF	Clinical evaluation Bone marrow edema	At 12months, these authors observed a decreasing trend in VAS score and WOMAC index in the SVF-treated group up to 24 months, as compared with the placebo group. Besides, a significant increase and decrease in Lysholm and OS, respectively, were observed in the treatment group. Compared with the values before treatment, the greatly reduced WOMAC scores of KL3 than KL2 groups at 24 months, indicate more improvement in the KL3 group. Highly decreased BME in the treated group was also noted.
Hong et al [41]	2019	16 patients with bilateral OA of grade II or III	This study compared debridement +SVF with arthroscopic debridement+hyaluronic acid	Clinical evaluation Radiography	The SVF-treated knees showed significantly improvement in the mean VAS, WOMAC scores, and ROM at 12-months follow-up visit compared with the baseline. In contrast, the mean VAS, WOMAC scores, and ROM of the control group became even worse but not significant from baseline to the last follow-up visit. WORMS and MOCART measurements revealed a significant improvement of articular cartilage repair in SVF-treated knees compared with hyaluronic acid-treated knees.
Yokota et al [42]	2019	42 patients (59 knees)	These authors compared the clinical results of intra-articular injection with ASCs versus SVFs in individuals with OA of the knee	Clinical evaluation	ASCs and SVFs produced clinical ameliorations in individuals with OA of the knee, but also that ASCs outperformed SVFs in terms of early pain decrease, and with less comorbidity
Garza et al [43]	2020	Thirty-nine individuals were randomized to high-dose SVF, low-dose SVF, or placebo (1:1:1). This is a double-blinded prospective randomized controlled clinical trial (level 1 of evidence)	High-dose SVF, low-dose SVF, or placebo	Clinical evaluation MRI assessment	The high-dose and low-dose groups showed a greater percentage modification at 1 year compared with the placebo group. Review of MRI showed no changes in cartilage following injection. No serious adverse events were encountered.
Tsubosaka et al [44]	2020	These authors analyzed 57 patients who were managed with intra-articular injection of 2.5×10^7 SVF cells into the knee articulation.		Clinical evaluation Radiographic and MRI evaluation	The postoperative angle of knee extension at 6 and 12 months was substantially better than before operation. Postoperative WOMAC, VAS, and KOOS scores at 1, 3, 6, and 12 months were substantially better than preoperative scores. There were no significant differences in hip-knee-ankle angle among the 5 time periods. Postoperative T2 mapping values of the lateral femur and tibia were substantially greater at 12 months than before operation
Bisicchia et al [33]	2020	Two groups of 20 patients were arthroscopically treated with microfractures for a symptomatic focal chondral defect of the knee.	At the end of surgery, in the experimental group, micro-fragmented SVF was injected into the joint.	Clinical evaluation	No adverse reactions were noted. Analgesic and anti-inflammatory consumption was similar in both groups. At 1-month follow-up, no differences were noted between groups when compared to pre-operative scores. At 3-month follow-up, patients in both groups improved from the baseline in all variables. Significantly lower VAS scores were found in the experimental group. At 6- and 12-month follow-ups, patients in the experimental group scored better in all outcomes with a moderate effect size; in particular, better WOMAC scores were obtained at 12 months, achieving the primary end-point of the study.

MRI, magnetic resonance imaging; MSCs, mesenchymal stem cells; OA, osteoarthritis; PRP, platelet-rich plasma; JKOM, Japanese Knee Osteoarthritis Measure; WOMAC, Western Ontario and McMaster Universities Osteoarthritis Index; VAS, visual analog scale; IKDC, International Knee Documentation Committee; EQ-VAS, EuroQol-visual analogue scales; OS, MRI-based Outerbridge score; KL, Kellgren-Lawrence; BME, bone marrow edema; ROM, range of motion; WORMS, whole-organ magnetic resonance imaging score; MOCART, magnetic resonance observation of cartilage repair tissue; ASCs, adipose-derived stem cells; KOOS, Knee injury and Osteoarthritis Outcome Score.

As reported by Fotoubi et al in 2018, MSC therapy with PRP, SVF, and ASC injections for OA has progressed well, with optimistic data from studies of patients with OA^[46]. In 2019, DiMatteo et al published another systematic review evaluating the clinical use of “minimally” manipulated MSCs, either as bone marrow aspirate concentrate (BMAC) or as SVF, for the management of OA of the knee. They found an absence of high-quality investigations in the literature, which prevented them from making recommendations on the clinical use of one product over another. However, the use

SVF was secure and efficacious management for recalcitrant Achilles tendinopathy [35]

Intra-articular SVF injections could substantially reduce knee osteoarthritis symptoms and pain for at least 1 year [24]

For patients with knee osteoarthritis, intra-articular injection of adipose-derived stromal vascular fractions (ADSVFs) without adjuvant treatment was clinically efficacious and safe at short-run follow-up [32]

Figure 2 Studies with level 1 of evidence on the efficacy of stromal vascular fraction (SVF) in musculoskeletal (MSK) lesions.

of “minimally” manipulated MSCs (in the form of BMAC or SVF) has been demonstrated to be safe and to provide several short-term benefits^[47].

In 2021, Shanmugasundaram et al published another systematic review on the use of SVF injection for the management of knee OA. They stated that intra-articular SVF injection was a simple, accessible, and minimally invasive approach that could serve as a temporary alternative for individuals in whom other conservative and arthroscopic alternatives had failed. These authors found that intra-articular injection of SVF was a safe and efficacious method to treat OA of the knee. Nevertheless, they also noted that level 1 comparative investigations were required to support the utilization of adjuvants with SVF and also to compare the use of SVF (with or without adjuvants) with ASCs, PRP, and BMAC^[48].

The studies in a meta-analysis published by Agarwal et al in 2021 established the safety and efficacy of SVF therapy for knee OA in older adults and showed that the therapy diminished pain and improved knee function, suggesting that SVF might be an efficacious therapy to improve mobility in an aging population^[49]. A meta-analysis with level 4 evidence reported by Bolia et al has shown that a single SVF injection into the knee joint of patients with OA resulted in symptomatic improvement at the short-term follow-up. However, there was significant variation in the SVF injection preparation techniques across the studies and a lack of stratification of the results based on the radiologic classification of OA. Therefore,

these outcomes should be interpreted with caution^[50].

In a meta-analysis with level 1 evidence, Kim et al found that for patients with knee OA, intra-articular injection of adipose-derived stromal vascular fraction (ADSVF) without adjuvant treatment was clinically efficacious and safe at the short-term follow-up. Some degree of effectiveness was shown for cartilage regeneration in knee OA^[51].

In 2019, Yokota et al reported that intra-articular injection of ASCs had shown promise in reducing pain and improving the quality of cartilage in individuals with OA. Nonetheless, whereas most preclinical investigations had been performed with plastic-adherent ASCs, the majority of clinical trials were being performed with SVF prepared from adipose tissue without prior culture^[42]. In their study (cohort study; evidence level 3), they compared the clinical results of intra-articular injection of ASCs with SVF in individuals with knee OA. They retrospectively compared the 6-month results of 42 patients (59 knees) who received an intra-articular injection with 12.75 million ASCs and 38 patients (69 knees) who received a 5 ml injection of SVF. All individuals had Kellgren-Lawrence grade 2, 3, or 4 OA of the knee and had not responded to standard medical management. The parameters evaluated were the visual analog scale (VAS) pain score; the Knee injury and Osteoarthritis Outcome Score (KOOS) at baseline and at 1, 3, and 6 months after injection; and the Outcome Measures in Rheumatology-Osteoarthritis Research Society International (OMERACT-OARSI) criteria to evaluate favorable responses. No major adverse events occurred in either group. The SVF group had a greater frequency of knee effusion (SVF 8%, ASC 2%) and minor adverse events associated with the fat removal site (SVF 34%, ASC 5%). Both groups experienced improvements in the VAS and KOOS pain domains. In the ASC group, symptoms improved earlier (at 12 weeks; $p < 0.05$) and the VAS for pain diminished to a greater extent (55%; $p < 0.05$) compared with the SVF group (44%). The percentage of OMERACT-OARSI responders in the ASC group was slightly higher (ASC, 61%; SVF, 55%; $p = 0.25$). Ultimately, it was observed that both ASCs and SVF produced clinical improvements in individuals with knee OA; however, ASCs outperformed SVF in terms of early pain reduction and less comorbidity^[42].

In 2020, Garza et al published a double-blind, prospective, randomized controlled trial (evidence level 1) to assess the effectiveness of intra-articular MSCs for the management of knee OA (registration: NCT02726945, ClinicalTrials.gov identifier^[43]). Thirty-nine adults with painful knee OA were randomized to high-dose SVF, low-dose SVF, or placebo (1:1:1). SVF was obtained by liposuction, processed to produce the cell implant, and injected during the same clinic visit. Western Ontario and McMaster Universities Osteoarthritis Index (WOMAC) scores and magnetic resonance imaging (MRI) were obtained before the injection and at 6 and 12 months following the injection. The average percentage improvement in the WOMAC score at 6 months following injection for the high-dose, low-dose, and placebo groups was 83.9%, 51.5%, and 25%, respectively. The high-dose and low-dose groups showed statistically significant changes in WOMAC scores compared with the placebo group (high-dose, $p = 0.04$; low-dose, $p = 0.02$). The improvements were dose-dependent. The average percent modification in WOMAC score from baseline to 1 year after injection for the high-dose, low-dose, and placebo groups was 89.5%, 68.2%, and 0%, respectively. The high-dose and low-dose groups showed a greater change at 1 year compared with the placebo group (high-dose, $p = 0.006$; low-dose, $p = 0.009$). Review of MRI showed no changes in cartilage following injection. No serious adverse events were encountered. Ultimately,

intra-articular SVF injections were shown to substantially reduce knee OA symptoms and pain for at least 1 year. The effectiveness and safety shown in this placebo-controlled trial supported its application as a therapeutic alternative for symptomatic knee OA^[43].

In 2020, Tsubosaka et al studied 57 patients who were managed with intra-articular injection of 2.5×10^7 SVF cells into the knee articulation^[44]. All individuals were followed for 1 year or longer. The mean age at injection and follow-up were 69.4 and 13.7 months, respectively. The preoperative hip-knee-ankle angle was 6.7 degrees on average. SVF cells were prepared with the Celution 800/CRS system from individuals' abdominal subcutaneous fat or buttocks. The viability of SVF cells was 90.6% on average. Clinical assessments of the range of motion, WOMAC score, the VAS for pain and knee injury score, and the KOOS were performed. The hip-knee-ankle angle was evaluated by means of radiographs, and T2 mapping values utilizing a 1.5-T MRI unit were also evaluated. Both clinical and imaging assessments were performed before the surgery and at 1, 3, 6, and 12 months afterward and were compared across all time points ($p < 0.05$). The postoperative knee extension angle at 6 and 12 months was substantially better than before the surgery. Postoperative WOMAC, VAS, and KOOS scores at 1, 3, 6, and 12 months were substantially better than preoperative scores. There were no significant differences in the hip-knee-ankle angle among the 5 time periods, and postoperative T2 mapping values of the lateral femur and tibia were substantially greater at 12 months than before the surgery^[44].

Andia and Mafulli have recently stated that clinical SVF studies lack the quality required to answer major research questions, including clinical and structural efficacy, the optimal cell dose, the number of injections, and the specific protocol for cell delivery. They also noted that poor study designs are exacerbated by the diversity of patient phenotypes, which hinders comparisons between protocols^[52].

Chondral Defects: In 2020, Li et al reported that articular cartilage injuries remained a challenge for physicians, but that stem cells had become promising biologics in regenerative medicine, given that ASCs were shown to promote cartilage repair due to their multipotency. Nonetheless, enzymatic isolation and monolayer expansion of ASCs reduced their differentiation potential and limited their clinical utilization^[53]. These authors obtained a novel adipose tissue-derived product, ECM/SVF gel, by simple mechanical shifting and centrifugation to extract the fat and concentrate the efficacious components. Their study assessed the therapeutic efficacy of this natural biomaterial in the repair of articular cartilage defects. Scanning electron microscopy demonstrated that the fibrous structure of the ECM/SVF gel was maintained, and that the ASCs sprouted from the ECM/SVF-gel were characterized by their ability to differentiate into chondrocytes, osteoblasts, and adipocytes. In a rabbit model, cartilage defects of critical size (diameter, 4 mm; depth, 1.5 mm) were done and treated with MF or a combination of autologous ECM and SVF gel injection. The knees were assessed at 6 and 12 weeks by MRI, macroscopic observation, histology, and immunohistochemistry. The International Cartilage Repair Society score and histological score were significantly higher in the ECM/SVF-gel-treated group than in the MF-treated group. ECM/SVF gel clearly improved cartilage regeneration, integration with surrounding normal cartilage, and expression of the hyaline cartilage marker, type II collagen, compared with isolated MF treatment. In general, ready-to-use ECM/SVF gel appears to be a good therapeutic alternative to support articular cartilage regeneration. Additionally, thanks to its simple, rapid, cost-effective, enzyme-free, and minimally invasive preparation process, this gel could be a helpful alternative to stem

cell-based treatment^[53].

Bisicchia et al reported that injection of micro-fragmented SVF is safe and, when associated with microfractures, is more effective in clinical terms than microfractures alone in patients affected by symptomatic focal chondral lesions of the knee^[33]. Two groups of 20 patients were arthroscopically treated with microfractures for a symptomatic focal chondral defect of the knee. At the end of the surgery, in the experimental group, micro-fragmented SVF was injected into the joint. The primary endpoint was WOMAC score at 12 months. Secondary endpoints were adverse events, Oxford Knee Score, EQ-5D score, VAS for pain, and analgesic and anti-inflammatory consumption. All the patients were evaluated at the 12-month follow-up. No adverse reactions were noted. Analgesic and anti-inflammatory consumption were similar in both groups. At the 1-month follow-up, no differences were noted between groups when compared with preoperative scores. At the 3-month follow-up, patients in both groups improved from baseline in all variables. Significantly lower VAS pain scores were found in the experimental group. At the 6- and 12-month follow-ups, patients in the experimental group scored better on all variables, with a moderate effect size; in particular, better WOMAC scores were obtained at 12 months^[33].

Tendon Healing

Several studies have demonstrated the efficacy of SVF in tendon healing^[8,17,54-58]. In 2018, Uselli et al reported that although PRP injection had shown debatable outcomes for the management of Achilles tendinopathy, it remained the most widely utilized biological treatment approach. Recent data appear to show that the SVF of adipose tissue could counteract the deterioration of tendon homeostasis^[54]. In their study (a randomized controlled clinical trial with level 1 of evidence), they prospectively compared the effectiveness of PRP and SVF injection for the management of non-insertional Achilles tendinopathy. Forty-four individuals were enrolled; 23 were included in the PRP group and 21 in the SVF group, and they were managed unilaterally or bilaterally for a total of 28 tendons per group. All individuals (aged 18 to 55 years) were clinically evaluated preoperatively and at 15, 30, 60, 120, and 180 days after management, utilizing the VAS pain scale, the Victorian Institute of Sport Assessment-Achilles (VISA-A), the AOFAS (American Orthopedic Foot and Ankle Society) Ankle-Hindfoot Score, and the Short Form (36) Health Survey forms. Individuals were also assessed by ultrasound and MRI prior to management and after 4 (ultrasound only) and 6 months. Both methods produced a significant improvement over baseline. When comparing the 2 groups, the VAS, AOFAS, and VISA-A scores were substantially better at 15 and 30 days in the SVF group than in the PRP group ($p < 0.05$). At later time points, no significantly different scores between the groups were found. No correlation was observed between clinical and radiological manifestations. Both PRP and SVF were safe and effective approaches for recalcitrant Achilles tendinopathy. Individuals managed with SVF had faster outcomes, suggesting that such therapy should be considered for those requiring an earlier return to activities of daily living or sports^[54].

In 2021, Khoury et al studied the effect of ASC injection as a therapeutic procedure on lateral elbow tendinopathy (LET)^[58]. Eighteen tennis players with chronic and recalcitrant LET (who had been treated previously without success with nonsurgical methods) had a clinical assessment and MRI prior to intervention. SVF cells were expanded by *in vitro* culture and ASCs were obtained and characterized by flow cytometry. ASCs were injected at the site of

tendinopathy in a single procedure, which was followed by physical therapy. Players had a series of clinical assessments over a 1-year period and a repeat MRI at 6 months after injection. At 6 months, the clinical assessment showed significant improvements compared with baseline in mean VAS scores for the following: peak pain score (from 6.28 to 1; $p < 0.001$); mean QuickDASH-Compulsive arm, shoulder, and hand impairments score (51.38 to 12.33; $p < 0.001$); and QuickDASH-Sport score (56.94 to 8.68; $p < 0.001$). The tendinopathy grade of the validated MRI scoring system was also significantly ameliorated: 4.22 to 2.22 ($p < 0.001$). At 12 months post-injection, the VAS peak pain scores decreased further, to 0.74 ($p < 0.001$), and the QuickDASH-Compulsive score declined to 5.56 ($p < 0.001$). The mean time to return to tennis was 3.31 months after the intervention. Ultimately, tennis players with recalcitrant LET experienced significant clinical improvement and structural repair at the common tendon origin after injection of autologous ASCs. The results of this study are promising and open a new biologic therapeutic alternative to treat LET. Although the outcomes of this pilot study are positive, future well-designed investigations, i.e., prospective randomized trials, are required to outline the function of cell therapy in the treatment of LET^[58].

Bone Regeneration

In 2016, Saxer et al demonstrated that SVF cells, without expansion or exogenous priming, can spontaneously form bone tissue and vessel structures within a fracture microenvironment^[59]. Human SVF cells were loaded onto ceramic granules within fibrin gel and implanted in critical nude rat femoral fractures after locking-plate osteosynthesis, with cell-free grafts as controls. After 8 weeks, only SVF-treated fractures did not fail mechanically and they showed formation of ossicles at the repair site, with vascular and bone structures formed by human cells. The same materials combined with autologous SVF cells were then utilized to treat low-energy proximal humeral fractures in 8 patients (64–84 years of age) along with standard open reduction and internal fixation. Biopsies of the repair tissue after up to 12 months, upon plate revision or removal, showed formation of bone ossicles that were structurally disconnected and morphologically distinct from osteoconducted bone, suggesting the osteogenic nature of implanted SVF cells^[59].

In 2018, Roato et al showed that SVF plated on SmartBone, in the presence of osteogenic factors, had better osteoinductive capabilities than ASCs in terms of differentiation into bone cells, mineralization, and secretion of soluble factors stimulating osteoblasts. They observed an increasing area of new tissue over time, with and without osteogenic medium^[60].

As published by Zhang et al in 2018, conventional cell-based bone regeneration had 3 major disadvantages: insufficient cell supply, time-consuming *in vitro* expansion cultures, and restricted patient-friendliness in terms of cell isolation and the high number of visits to the clinic required^[61]. They attempted an alternative approach that utilized “easy access cells” that could be obtained intraoperatively to prepare cell-based constructs. They used SVF from human adipose tissue and human monocytes for intraoperative preparation of bone constructs. Conventional constructs grafted with expanded human ASCs derived from the same donor were established as controls. In addition, both cell types were combined or not with monocytes. The cellular interaction of SVF and human ASCs with human monocytes was assessed *in vitro*. The viability and bone regenerative capacity of the intraoperative constructs were confirmed histologically and histomorphometrically in an experimental study (creating bone defects in the femoral condyles of rats). SVF showed

in vitro osteogenic differentiation equal to that of expanded donor adipose-derived mesenchymal stem cells, which in both cases was significantly augmented following co-culture with monocytes. Furthermore, SVF and ASCs showed different immunoregulatory effects on monocytes/macrophages. After implantation in rat femur bone defects, SVF constructs showed better bone formation than ASC constructs and cell-free controls; no adverse events of monocyte addition were encountered. Ultimately, the feasibility of intraoperative preparation of SVF constructs and the superior bone regenerative capacity of SVF constructs compared with donor-matched ASC constructs were demonstrated. The superiority of SVF constructs was related to the differences between the immunoregulatory effects of SVF and ASCs^[61].

In 2021, Veronesi et al performed a review of the literature^[30]. SVF injected or implanted with or without scaffolds was shown to be a valid and in some ways superior approach to ASCs and bone marrow stem cells (BMSCs), due to the ability to differentiate into osteogenic, chondrogenic, and tenogenic lineages as well as promote cell and tissue regenerative potential.

Chronic Diabetes Foot Ulcers

In a pilot study reported in 2017, Vicenti et al compared the standard of care to autologous lipotransfer and SVF-enriched lipoinjection in 30 patients with diabetic foot ulcers. They found a clear superiority of SVF-enriched lipoinjection in terms of the percentage reduction of ulcer size and healing time^[62].

In 2018, Didangelos et al described a case of a patient with type I diabetes with a refractory foot ulcer that remained unhealed for 2 years despite conventional therapy. Autologous adipose-derived stromal vascular fraction suspended in autologous platelet-rich plasma was applied to the wound, which completely healed within 1 month. The wound remained closed with no complications during a 2-year follow-up period^[63].

In 2021, Carstens et al reported that diabetic foot ulcers (DFUs) result from diabetes-induced microarterial vascular disease and peripheral neuropathy. The presence of arteriosclerosis-induced macroarterial disease could further complicate the pathophysiology of DFUs. The latest publications on this topic suggest that MSC treatments could augment tissue regeneration^[64]. This phase I study was performed to determine the safety and effectiveness of local injections of autologous adipose-derived SVF cells to manage nonhealing DFUs larger than 3 cm in diameter. Sixty-three patients with type 2 diabetes with chronic DFUs—all amputation candidates—were treated with 30×10^6 SVF cells injected into the ulcer bed and periphery and along the pedal arteries; they were followed up at 6 and 12 months to assess ulcer closure. Doppler ultrasound was performed in a subgroup of patients to determine vascular structural parameters. No serious adverse events related to the intervention were found. At 6 months, 51 patients had 100% closure of their DFUs, and 8 had $\geq 75\%$ closure. Three patients had early amputations, and 1 died. At 12 months, 50 patients had 100% DFU healing and 4 had $\geq 85\%$ healing. Five patients died between the 6- and 12-month follow-up visits. None of the deaths were related to the intervention. Doppler studies performed on 11 patients showed increments in peak systolic velocity and the pulsatility index in 33 of 33 arteries, consistent with augmented distal arterial runoff. These outcomes show that SVF can be safely utilized to manage chronic DFU, with evidence of effectiveness (wound healing) and mechanisms of action including vascular repair and/or angiogenesis^[64].

In 2021, Yin et al evaluated the clinical efficacy of applying SVF

cells and platelet-rich plasma together in the treatment of recalcitrant chronic diabetic ulcer^[65]. Four patients (5 ulcers in total) who had received standard treatment for diabetic ulcers for at least 3 months that failed to heal were enrolled. All patients were treated with surgical debridement, cell suspension (SVF cells suspended in platelet-rich plasma) injection into the wound, and platelet-rich plasma gel coverage. The wounds were measured every week after treatment using a 2-dimensional digital camera and a 3-dimensional wound measurement device. All patients were followed for 4 months after the treatment. Four of the 5 ulcers healed completely within a mean of approximately 72 days. The average proportion of granulation tissue achieved 100% within 4 weeks for all cases. The wound size decreased to less than half of the original size for all cases 4 weeks after the treatment^[65].

Soft-tissue Sports Injuries

In 2021, Kader et al reported that an increasing number of hospitals offer purportedly “regenerative” stem-cell treatments, even though cell-based treatments might not act primarily as stem cells, given that they have not demonstrated the capacity to regenerate target tissues in all clinical publications^[66]. They therefore systematically reviewed the evidence for their use in sports injuries of the knee’s soft tissues. They reviewed 14 papers related to the utilization of MSC preparations in humans with knee sports injuries: 7 using cultured MSCs, 5 using BMAC, and 2 using SVF and tenocyte-like-cells. The majority of studies were evidence level 3 or lower ($n = 9$). Kader et al opined that there is insufficient high-quality information to recommend the use of cell-based treatments that demonstrate either ligamentous or tendinous healing, meniscal volume restoration, or post-traumatic OA amelioration/regression. Furthermore, the techniques of harvesting, preparation, and application of cells are very heterogeneous. Therefore, it is important to standardize protocols and their data, beginning with more basic scientific research on MSCs as well as well-designed and large randomized controlled trials^[66].

Figure 2 shows the studies with evidence level 1 on the efficacy of SVF in musculoskeletal lesions.

CONCLUSIONS

It has been reported that intra-articular SVF injections are safe and efficacious for the treatment of patients with knee OA, and that intra-tendinous injections of SVF are safe and efficacious for the management of recalcitrant Achilles tendinopathy and chronic lateral elbow tendinopathy. Ready-to-use ECM/SVF gel appears to be a good therapeutic alternative for articular cartilage regeneration in patients with chondral lesions. Local application of SVF can be safely and effectively used in patients with chronic diabetic foot ulcers. However, there is insufficient evidence to recommend the use of cell-based treatment in sports injuries of the soft tissues of the knee. Nevertheless, experimental studies suggest that SVF could be a new alternative to achieve bone regeneration.

REFERENCES

- Han S, Sun HM, Hwang KC, Kim SW. Adipose derived stromal vascular fraction cells: update on clinical utility and efficacy. *Crit Rev Eukaryot Gene Expr.* 2015; **25**: 145-152. [DOI: 10.1615/critrevukaryotgeneexpr.2015013057].
- Guo J, Nguyen A, Banyard DA, Fadavi D, Toronto JD, Wirth GA, et al. Stromal vascular fraction: a regenerative reality? Part 2: mechanisms of regenerative action. *J Plast Reconstr Aesthet Surg.* 2016; **69**: 180-188. [DOI: 10.1016/j.bjps.2015.10.014]. Epub 2015 Oct 24.
- Andia I, Maffulli N, Burgos-Alonso N. Stromal vascular fraction technologies and clinical applications. *Expert Opin Biol Ther.* 2019; **19**: 1289-1305. [DOI: 10.1080/14712598.2019.1671970]. Epub 2019 Sep 27.
- van Dongen JA, Harmsen MC, Stevens HP. Isolation of stromal vascular fraction by fractionation of adipose tissue. *Methods Mol Biol.* 2019; **1993**: 91-103. [DOI: 10.1007/978-1-4939-9473-1_8].
- Yang WT, Ke CY, Yeh KT, Huang SG, Lin ZY, Wu WT, et al. Stromal-vascular fraction and adipose-derived stem cell therapies improve cartilage regeneration in osteoarthritis-induced rats. *Sci Rep.* 2022; **12**(1): 2828. [DOI: 10.1038/s41598-022-06892-3].
- Gentile P, Sterodimas A, Pizzicannella J, Dionisi L, De Fazio D, Calabrese C, et al. Systematic Review: allogenic use of stromal vascular fraction (SVF) and decellularized extracellular matrices (ECM) as advanced therapy medicinal products (ATMP) in tissue regeneration. *Int J Mol Sci.* 2020; **21**(14): 4982. [DOI: 10.3390/ijms21144982].
- Blaudez F, Ivanovski S, Hamlet S, Vaquette C. An overview of decellularisation techniques of native tissues and tissue engineered products for bone, ligament and tendon regeneration. *Methods.* 2020; **171**: 28-40. [DOI: 10.1016/j.jymeth.2019.08.002]. Epub 2019 Aug 5. [PMID: 31394166]
- Behfar M, Javanmardi S, Sarrafzadeh-Rezaei F. Comparative study on functional effects of allotransplantation of bone marrow stromal cells and adipose derived stromal vascular fraction on tendon repair: a biomechanical study in rabbits. *Cell J.* 2014; **16**(3): 263-270. Epub 2014 Oct 4. [PMID: 24611149]; [PMCID: PMC4204193]
- Marx C, Silveira MD, Selbach I, da Silva AS, Braga LM, Camassola M, Nardi NB. Acupoint injection of autologous stromal vascular fraction and allogeneic adipose-derived stem cells to treat hip dysplasia in dogs. *Stem Cells Int.* 2014; **2014**: 391274. [DOI: 10.1155/2014/391274]. Epub 2014 Aug 11.
- Kappos EA, Engels PE, Tremp M, Meyer zu Schwabedissen M, di Summa P, Fischmann A, et al. Peripheral nerve repair: multimodal comparison of the long-term regenerative potential of adipose tissue-derived cells in a biodegradable conduit. *Stem Cells Dev.* 2015; **24**: 2127-2141. [DOI: 10.1089/scd.2014.0424]. Epub 2015 Jul 2.
- Özkan HS, Karataş Silistreli Ö, Ergür B, İrkören S. Repairing peripheral nerve defects by vein grafts filled with adipose tissue derived stromal vascular fraction: an experimental study in rats. *Ulus Travma Acil Cerrahi Derg.* 2016; **22**: 7-11. [DOI: 10.5505/tjtes.2015.12612].
- Ismail T, Osinga R, Todorov A Jr, Haumer A, Tchang LA, Epple C, et al. Engineered, axially-vascularized osteogenic grafts from human adipose-derived cells to treat avascular necrosis of bone in a rat model. *Acta Biomater.* 2017; **63**: 236-245. [DOI: 10.1016/j.actbio.2017.09.003]. Epub 2017 Sep 8.
- Deng C, He Y, Feng J, Dong Z, Yao Y, Lu F. Conditioned medium from 3D culture system of stromal vascular fraction cells accelerates wound healing in diabetic rats. *Regen Med.* 2019; **14**: 925-937. [DOI: 10.2217/rme-2018-0083]. Epub 2019 Oct 10.
- Kemilew J, Sobczyńska-Rak A, Żylińska B, Szponder T, Nowicka B, Urban B. The use of allogenic stromal vascular fraction (SVF) cells in degenerative joint disease of the spine in dogs. *In Vivo.* 2019; **33**: 1109-1117. [DOI: 10.21873/invivo.11580].
- An R, Li S, Sheng L, Cao W. Emulsified fat grafting accelerates tissue expansion: an experimental study in a rat model. *Ann Plast Surg.* 2020; **85**: 61-67. [DOI: 10.1097/SAP.0000000000002137].
- Şahin AA, Değirmenci E, Özturan KE, Fırat T, Kükner A. Effects of adipose tissue-derived stromal vascular fraction on osteochondral defects treated by hyaluronic acid-based scaffold: An experimental study. *Jt Dis Relat Surg.* 2021; **32**: 347-

354. [DOI: 10.52312/jdrs.2021.19]. Epub 2021 Jun 11.
17. Palumbo Piccionello A, Riccio V, Senesi L, Volta A, Pennasilico L, Botto R, et al. Adipose micro-grafts enhance tendinopathy healing in ovine model: An in vivo experimental perspective study. *Stem Cells Transl Med.* 2021; **10**: 1544-1560. [DOI: 10.1002/sctm.20-0496]. Epub 2021 Aug 16.
 18. Veronesi F, Berni M, Marchiori G, Cassiolas G, Muttini A, Barboni B, et al. Evaluation of cartilage biomechanics and knee joint microenvironment after different cell-based treatments in a sheep model of early osteoarthritis. *Int Orthop.* 2021; **45**: 427-435. [DOI: 10.1007/s00264-020-04701-y]. Epub 2020 Jul 14.
 19. Bari E, Roato I, Perale G, Rossi F, Genova T, Mussano F, et al. Biohybrid bovine bone matrix for controlled release of mesenchymal stem/stromal cell lyosecretome: a device for bone regeneration. *Int J Mol Sci.* 2021; **22**(8): 4064. [DOI: 10.3390/ijms22084064].
 20. Sananta P, Dradjat RS, Rosandi RD, Siahaan LD. TGF-1 biomarker level evaluation on fracture healing in a murine model with a bone defect after stromal vascular fraction application. *Med Glas (Zenica).* 2022; **19**: 63-67. [DOI: 10.17392/1459-21].
 21. Mehranfar S, Abdi Rad I, Mostafav E, Akbarzadeh A. The use of stromal vascular fraction (SVF), platelet-rich plasma (PRP) and stem cells in the treatment of osteoarthritis: an overview of clinical trials. *Artif Cells Nanomed Biotechnol.* 2019; **47**: 882-890. [DOI: 10.1080/21691401.2019.1576710].
 22. Quicke JG, Conaghan PG, Corp N, Peat G. Osteoarthritis year in review 2021: epidemiology & therapy. *Osteoarthritis Cartilage.* 2022; **30**: 196-206. [DOI: 10.1016/j.joca.2021.10.003]. Epub 2021 Oct 22.
 23. Di Francesco M, Fragassi A, Pannuzzo M, Ferreira M, Brahmachari S, Decuzzi P. Management of osteoarthritis: From drug molecules to nano/micromedicines. *Wiley Interdiscip Rev Nanomed Nanobiotechnol.* 2022; **14**(3): e1780. [DOI: 10.1002/wnan.1780]. Epub 2022 Mar 6.
 24. Nowaczyk A, Szwedowski D, Dallo I, Nowaczyk J. Overview of first-line and second-line pharmacotherapies for osteoarthritis with special focus on intra-articular treatment. *Int J Mol Sci.* 2022; **23**(3): 1566. [DOI: 10.3390/ijms23031566].
 25. Tognolo L, Maccarone MC, De Trane S, Scanu A, Masiero S, Fiore P. Therapeutic exercise and conservative injection treatment for early knee osteoarthritis in athletes: a scoping review. *Medicina (Kaunas).* 2022; **58**(1): 69. [DOI: 10.3390/medicina58010069].
 26. Hawker GA, King LK. The burden of osteoarthritis in older adults. *Clin Geriatr Med.* 2022; **38**: 181-192. [DOI: 10.1016/j.cger.2021.11.005].
 27. Wei N, Dai Z. The Role of Nutrition in Osteoarthritis: A Literature Review. *Clin Geriatr Med.* 2022; **38**: 303-322. [DOI: 10.1016/j.cger.2021.11.006].
 28. Desando G, Bartolotti I, Martini L, Giavaresi G, Nicoli Aldini N, Fini M, et al. Regenerative features of adipose tissue for osteoarthritis treatment in a rabbit model: enzymatic digestion versus mechanical disruption. *Int J Mol Sci.* 2019; **20**(11): 2636. [DOI: 10.3390/ijms20112636].
 29. Filardo G, Tschon M, Perdisa F, Brogini S, Cavallo C, Desando G, et al. Micro-fragmentation is a valid alternative to cell expansion and enzymatic digestion of adipose tissue for the treatment of knee osteoarthritis: a comparative preclinical study. *Knee Surg Sports Traumatol Arthrosc.* 2022; **30**: 773-781. [DOI: 10.1007/s00167-020-06373-y]. Epub 2021 Jan 19.
 30. Veronesi F, Maglio M, Contartese D, Martini L, Muttini A, Fini M. Stromal vascular fraction and amniotic epithelial cells: preclinical and clinical relevance in musculoskeletal regenerative medicine. *Stem Cells Int.* 2021; **2021**: 6632052. [DOI: 10.1155/2021/6632052]. eCollection 2021.
 31. Liu Y, Huang L, Zeng Y, Li M, Xie H, Shen B. Intra-articular injection of stromal vascular fraction for knee degenerative joint disease: a concise review of preclinical and clinical evidence. *Sci China Life Sci.* 2022 May 5. [DOI: 10.1007/s11427-021-2090-3]. Online ahead of print. [PMID: 35524910]
 32. Filardo G, Tschon M, Perdisa F, Brogini S, Cavallo C, Desando G, et al. Micro-fragmentation is a valid alternative to cell expansion and enzymatic digestion of adipose tissue for the treatment of knee osteoarthritis: a comparative preclinical study. *Knee Surg Sports Traumatol Arthrosc.* 2022; **30**: 773-781. [DOI: 10.1007/s00167-020-06373-y]. Epub 2021 Jan 19.
 33. Bisicchia S, Bernardi G, Pagnotta SM, Tudisco C. Micro-fragmented stromal-vascular fraction plus microfractures provide better clinical results than microfractures alone in symptomatic focal chondral lesions of the knee. *Knee Surg Sports Traumatol Arthrosc.* 2020; **28**: 1876-1884. [DOI: 10.1007/s00167-019-05621-0]. Epub 2019 Jul 11.
 34. Kim YS, Lee HJ, Choi YJ, Kim YI, Koh YG. Does an injection of a stromal vascular fraction containing adiposederived mesenchymal stem cells influence the outcomes of marrow stimulation in osteochondral lesions of the talus? A clinical and magnetic resonance imaging study. *Am J Sports Med* 2014; **42**: 2424-2434. [DOI: 10.1177/0363546514541778]. Epub 2014 Aug 8.
 35. Gibbs N, Diamond R, Sekyere EO, Thomas WD. Management of knee osteoarthritis by combined stromal vascular fraction cell therapy, platelet-rich plasma, and musculoskeletal exercises: a case series. *J Pain Res* 2015; **8**: 799-806. [DOI: 10.2147/JPR.S92090]. eCollection 2015.
 36. Yokota N, Yamakawa M, Shirata T, Kimura T, Kaneshima H. Clinical results following intra-articular injection of adipose-derived stromal vascular fraction cells in patients with osteoarthritis of the knee. *Regen Therapy* 2017; **6**: 108-112. [DOI: 10.1016/j.reth.2017.04.002]. eCollection 2017 Jun.
 37. Nguyen PD, Tran TDX, Nguyen HTN, Vu HT, Le PTB, Phan NLC, et al. Comparative clinical observation of arthroscopic microfracture in the presence and absence of a stromal vascular fraction injection for osteoarthritis. *Stem Cells Translat Med* 2017; **6**: 187-195. [DOI: 10.5966/sctm.2016-0023]. Epub 2016 Aug 29.
 38. Salikhov RZ, Masgutov RF, Chekunov MA, Tazetdinova LG, Masgutova G, Teplov OV, et al. The stromal vascular fraction from fat tissue in the treatment of osteochondral knee defect: case report. *Frontiers Med (Laussane)* 2018; **5**: 154. [DOI: 10.3389/fmed.2018.00154]. eCollection 2018.
 39. Roato I, Belisario DC, Compagno M, Lena A, Bistolfi A, Maccari L, et al. Concentrated adipose tissue infusion for the treatment of knee osteoarthritis: clinical and histological observations. *Int Orthop* 2019; **43**: 15-23. [DOI: 10.1007/s00264-018-4192-4]. Epub 2018 Oct 11.
 40. Tran TDX, Wu CM, Dubey NK, Deng YH, Su CW, Pham TT, et al. Time-and Kellgren-Lawrence grade-dependent changes in intraarticularly transplanted stromal vascular fraction in osteoarthritic patients. *Cell* 2019; **8**(4): 308. [DOI: 10.3390/cells8040308].
 41. Hong Z, Chen J, Zhang S, Zhao C, Bi M, Chen X, et al. Intra-articular injection of autologous adipose-derived stromal vascular fractions for knee osteoarthritis: a double-blind randomized self-controlled trial. *Int Orthop* 2019; **43**: 1123-1134. [DOI: 10.1007/s00264-018-4099-0]. Epub 2018 Aug 14.
 42. Yokota N, Hattori M, Ohtsuru T, Otsuji M, Lyman S, Shimomura K, et al. Comparative clinical outcomes after intra-articular injection with adipose-derived cultured stem cells or noncultured stromal vascular fraction for the treatment of knee osteoarthritis. *Am J Sports Med.* 2019; **47**: 2577-2583. [DOI: 10.1177/0363546519864359]. Epub 2019 Aug 2.
 43. Garza JR, Campbell RE, Tjoumakaris FP, Freedman KB, Miller LS, Santa Maria D, et al. Clinical efficacy of intra-articular mesenchymal stromal cells for the treatment of knee osteoarthritis: a double-blinded prospective randomized controlled clinical trial. *Am J Sports Med.* 2020; **48**: 588-598. [DOI:

- 10.1177/0363546519899923].
44. Tsubosaka M, Matsumoto T, Sobajima S, Matsushita T, Iwaguro H, Kuroda R. The influence of adipose-derived stromal vascular fraction cells on the treatment of knee osteoarthritis. *BMC Musculoskelet Disord.* 2020; **21**(1): 207. [DOI: 10.1186/s12891-020-03231-3].
 45. Pak J, Lee JH, Pak N, Pak Y, Park KS, Jeon JH, et al. Cartilage regeneration in humans with adipose tissue-derived stem cells and adipose stromal vascular fraction cells: updated status. *Int J Mol Sci.* 2018; **19**(7): 2146. [DOI: 10.3390/ijms19072146].
 46. Fotouhi A, Maleki A, Dolati S, Aghebati-Maleki A, Aghebati-Maleki L. Platelet rich plasma, stromal vascular fraction and autologous conditioned serum in treatment of knee osteoarthritis. *Biomed Pharmacother.* 2018; **104**: 652-660. [DOI: 10.1016/j.biopha.2018.05.019]. Epub 2018 May 25.
 47. Di Matteo B, Vandenbulcke F, Vitale ND, Iacono F, Ashmore K, Marcacci M, et al. Minimally manipulated mesenchymal stem cells for the treatment of knee osteoarthritis: a systematic review of clinical evidence. *Stem Cells Int.* 2019; **2019**: 1735242. [DOI: 10.1155/2019/1735242]. eCollection 2019.
 48. Shanmugasundaram S, Vaish A, Chavada V, Murrell WD, Vaishya R. Assessment of safety and efficacy of intra-articular injection of stromal vascular fraction for the treatment of knee osteoarthritis-a systematic review. *Int Orthop.* 2021; **45**: 615-625. [DOI: 10.1007/s00264-020-04926-x]. Epub 2021 Jan 12.
 49. Agarwal N, Mak C, Bojanic C, To K, Khan W. Meta-analysis of adipose tissue derived cell-based therapy for the treatment of knee osteoarthritis. *Cells* 2021; **10**(6): 1365. [DOI: 10.3390/cells10061365].
 50. Bolia IK, Bougioukli S, Hill WJ, Trasolini NA, Petrigliano FA, Lieberman JR, Weber AE. Clinical efficacy of bone marrow aspirate concentrate versus stromal vascular fraction injection in patients with knee osteoarthritis: a systematic review and meta-analysis. *Am J Sports Med.* 2021 Jun 8: 3635465211014500. [DOI: 10.1177/03635465211014500]. Online ahead of print. [PMID: 34102078]
 51. Kim KI, Kim MS, Kim JH. Intra-articular injection of autologous adipose-derived stem cells or stromal vascular fractions: are they effective for patients with knee osteoarthritis? A systematic review with meta-analysis of randomized controlled trials. *Am J Sports Med.* 2022 Jan 12: 3635465211053893. [DOI: 10.1177/03635465211053893]. Online ahead of print.
 52. Andia I, Maffulli N. Mesenchymal stromal cell products for intra-articular knee injections for conservative management of osteoarthritis. *Ther Adv Musculoskelet Dis.* 2021; **13**: 1759720X21996953. [DOI: 10.1177/1759720X21996953]. eCollection 2021.
 53. Li Q, Zhao F, Li Z, Duan X, Cheng J, Zhang J, et al. Autologous fractionated adipose tissue as a natural biomaterial and novel one-step stem cell therapy for repairing articular cartilage defects. *Front Cell Dev Biol.* 2020; **8**: 694. [DOI: 10.3389/fcell.2020.00694]. eCollection 2020.
 54. Uselli FG, Grassi M, Maccario C, Viganò M, Lanfranchi L, Alfieri Montrasio U, et al. Intratendinous adipose-derived stromal vascular fraction (SVF) injection provides a safe, efficacious treatment for Achilles tendinopathy: results of a randomized controlled clinical trial at a 6-month follow-up. *Knee Surg Sports Traumatol Arthrosc.* 2018; **26**: 2000-2010. [DOI: 10.1007/s00167-017-4479-9]. Epub 2017 Mar 1.
 55. Viganò M, Ragni E, Marmotti A, de Girolamo L. The effects of orthobiologics in the treatment of tendon pathologies: a systematic review of preclinical evidence. *J Exp Orthop.* 2022; **9**(1): 31. [DOI: 10.1186/s40634-022-00468-w].
 56. Polly SS, Nichols AEC, Donnini E, Inman DJ, Scott TJ, Apple SM, et al. Adipose-derived stromal vascular fraction and cultured stromal cells as trophic mediators for tendon healing. *J Orthop Res.* 2019; **37**: 1429-1439. [DOI: 10.1002/jor.24307]. Epub 2019 Apr 29.
 57. Khoury MA, Chamari K, Tabben M, Alkhelaifi K, Ricardo T, Damián C, et al. Expanded adipose derived mesenchymal stromal cells are effective in treating chronic insertional patellar tendinopathy: clinical and MRI evaluations of a pilot study. *J Exp Orthop.* 2021; **8**(1): 49. [DOI: 10.1186/s40634-021-00358-7].
 58. Khoury M, Tabben M, Rolón AU, Levi L, Chamari K, PD'Hooghe P. Promising improvement of chronic lateral elbow tendinopathy by using adipose derived mesenchymal stromal cells: a pilot study. *J Exp Orthop* 2021; **8**(1): 6. [DOI: 10.1186/s40634-020-00320-z].
 59. Saxer F, Scherberich A, Todorov A, Studer P, Miot S, Schreiner S, et al. Implantation of stromal vascular fraction progenitors at bone fracture sites: from a rat model to a first-in-man study. *Stem Cells* 2016; **34**: 2956-2966. [DOI: 10.1002/stem.2478]. Epub 2016 Sep 16.
 60. Roato I, Belisario DC, Compagno M, Verderio L, Sighinolfi A, Mussano F, et al. Adipose derived stromal vascular fraction/xenohybrid bone scaffold: an alternative source for bone regeneration. *Stem Cells Int* 2018; **2018**: 4126379. [DOI: 10.1155/2018/4126379]. eCollection 2018.
 61. Zhang Y, Grosfeld EC, Camargo WA, Tang H, Magri AMP, van den Beucken JJJP. Efficacy of intraoperatively prepared cell-based constructs for bone regeneration. *Stem Cell Res Ther.* 2018; **9**(1): 283. [DOI: 10.1186/s13287-018-1026-7].
 62. Vicenti G, Solarino G, Pesce V, Moretti L, Notarnicola A, Carrozzo M, AET AL. Autologous lipotransfer versus stromal vascular fraction enriched lipoinjection for diabetic foot wounds healing: a pilot study. *J Biol Regul Homeost Agents.* 2017; **31**(4 suppl 1): 141-146. [PMID: 29188676]
 63. Didangelos T, Koliakos G, Kouzi K, Arsos G, Kotzampassi K, Tziomalos K, et al. Accelerated healing of a diabetic foot ulcer using autologous stromal vascular fraction suspended in platelet-rich plasma. *Regen Med.* 2018; **13**: 277-281. [DOI: 10.2217/rme-2017-0069]. Epub 2018 May 1.
 64. Carstens MH, Quintana FJ, Calderwood ST, Sevilla JP, Ríos AB, Rivera CM, et al. Treatment of chronic diabetic foot ulcers with adipose-derived stromal vascular fraction cell injections: Safety and evidence of efficacy at 1 year. *Stem Cells Transl Med.* 2021; **10**: 1138-1147. [DOI: 10.1002/sctm.20-0497]. Epub 2021 Apr 7.
 65. Yin S, Yang X, Bi H, Zhao Z. Combined use of autologous stromal vascular fraction cells and platelet-rich plasma for chronic ulceration of the diabetic lower limb improves wound healing. *Int J Low Extrem Wounds* 2021; **20**: 135-142. [DOI: 10.1177/1534734620907978]. Epub 2020 Mar 4.
 66. Kader N, Asopa V, Baryeh K, Sochart D, Maffulli N, Kader D. Cell-based therapy in soft tissue sports injuries of the knee: a systematic review. *Expert Opin Biol Ther.* 2021; **21**(8): 1035-1047. [DOI: 10.1080/14712598.2021.1872538]. Epub 2021 Jan 19.