

Evidence-Based Management of a Deep Sternal Wound Infection and Complete Thoracic Dehiscence

Jose J. Monsivais¹, FACS; Reesha B. White²

1 Hand and Microsurgery Center of El Paso, El Paso Texas and Burrell College of Osteopathic Medicine, Las Cruces, New Mexico USA;

2 Burrell College of Osteopathic Medicine, Las Cruces, New Mexico USA.

Conflict-of-interest statement: The author(s) declare(s) that there is no conflict of interest regarding the publication of this paper.

Open-Access: This article is an open-access article which was selected by an in-house editor and fully peer-reviewed by external reviewers. It is distributed in accordance with the Creative Commons Attribution Non Commercial (CC BY-NC 4.0) license, which permits others to distribute, remix, adapt, build upon this work non-commercially, and license their derivative works on different terms, provided the original work is properly cited and the use is non-commercial. See: <http://creativecommons.org/licenses/by-nc/4.0/>

Correspondence to: Jose J. Monsivais, MD, FACS, Hand and Microsurgery Center of El Paso, 10201 Gateway West Suite 301, El Paso, Texas USA.

Email: handmicro@msn.com

Telephone: +915-590-3666

Received: May 28, 2022

Revised: June 9, 2022

Accepted: June 10 2022

Published online: June 28, 2022

ABSTRACT

This report emphasizes the importance of a staged treatment approach that is consistent with evidence-based recommendations for the management of deep sternal wound infection in a patient with multiple risk factors. A 64 year old male patient presented six months following aortic valve replacement via a median sternotomy with a deep sternal wound infection that had resulted in complete dehiscence of the thoracic wall and partial exposure of the pericardial sac. Treatment during the six months prior to the referral included several standard reconstructive attempts consisting of debridement, stainless steel wiring, IV antibiotics, and negative pressure wound therapy without improvement. As he was metabolically decompensated, the

metabolic abnormalities were corrected, and the patient underwent full -thickness debridement of the chest wall wound and sternum. The sternum was approximated using the Sternal ZIPFIX® System (DePuy Synthes). The left pectoralis major island flap was used to cover the sternum for re-vascularization to aid with treatment of sepsis and improve bony union. Antibiotic pellets were added prior to closure of the wound. In June 2016, the patient underwent debridement and closure of the chest wound. The patient is now five years post-operative, and is able to carry out all activities including long distance motorcycle riding.

Key words: Surgical wound infection; Sternum; Sternal dehiscence; Osteomyelitis

© 2022 The Author(s). Published by ACT Publishing Group Ltd. All rights reserved.

Monsivais JJ, White R. Evidence-Based Management of a Deep Sternal Wound Infection and Complete Thoracic Dehiscence. *International Journal of Orthopaedics* 2022; 9(3): 1694-1696 Available from: URL: <http://www.ghrnet.org/index.php/ijo/article/view/3318>

INTRODUCTION

Deep sternal wound infections (DWSI) following cardiac surgery are associated with increased mortality rates, reduced long-term survival, prolonged length of in-patient stay, and increased treatment^[1]. Therefore, it is critical that clinicians adhere to evidence-based recommendations^[2] to manage deep sternal wound infections in order to avoid these unfavorable and potentially devastating outcomes.

The aim of this case report is to describe a successfully treated case of sternal osteomyelitis and complete dehiscence of the thoracic wall. The report emphasizes the importance of an evidence-based staged treatment approach for the management of DWSI in a patient with multiple risk factors.

CASE DESCRIPTION

The patient was referred to the author, a reconstructive microsurgeon, six months after undergoing aortic valve replacement via a median sternotomy. The patient is a 64 year old male who presented to the

clinic with complete dehiscence of the thoracic wall secondary to a deep sternal wound infection measuring 20 cm in length and 5 cm in width with partial exposure of the pericardial sac (Figures 1A and 1 B).

He was in a metabolically decompensated condition. Treatment during the six months prior to the referral included several standard reconstructive attempts consisting of debridement, stainless steel wiring, IV antibiotics, and wound vacuums without improvement. The patient had also been started on high dose opiates during this time. His past medical history included diabetes, hypertension, atherosclerotic cardiovascular disease, gout, peptic ulcer disease, smoking, anticoagulation therapy, and chronic pain involving high dose opioids. He had a BMI of 31.1. A CT scan showed deep wound infection and large amounts of necrotic bone. At the first patient visit (March 2, 2016), the antibiotics were adjusted to sensitivity as reported by the lab and immediate modification of the multiple risk factors associated with deep sternal wound infections was initiated. These modifications included correcting anemia, hypoalbuminemia, and hypovolemia; optimizing serum glucose concentrations, weaning off high dose opiates, and encouraging smoking cessation.

Approximately six weeks later, the patient's metabolic abnormalities had been corrected. He underwent full -thickness debridement of the chest wall wound and sternum. The overlying granulation tissue was removed in order to allow for cancellous bone to be in contact on both sides. After mobilization, the sternum was approximated using the Sternal ZIPFIX® System (DePuy Synthes) and size belts were placed following the intercostal spaces. This method

was chosen since the tissue stability necessary for successful use of more traditional steel wiring or plating was not present due to severe inflammation and loss of sternal bone. Additionally, it is important to take into account that after debridement, the sternal surface area of bone decreases. The bone was also soft, creating the potential for screw displacement and/or fragmenting the sternum. With the use of the Sternal ZIPFIX® System the forces were distributed across a wider area and accounted for the tensile strength^[3]. Following approximation of the sternum, the left pectoralis major island flap was used to cover the sternum for re-vascularization to aid with treatment of sepsis and improve bony union. Antibiotic pellets were added prior to closure of the wound (Figures 2 A and 2 B).

A few months after the first procedure, the patient developed a hematoma secondary to the anticoagulation therapy used for the original valve replacement. The hematoma was drained and allowed to heal by secondary intention. The only other complicating factor which occurred was when one Sternal ZIPFIX® System band that had been placed on the floating rib ripped when the patient coughed, but there were no adverse consequences.

In June 2016, the patient underwent debridement and closure of the chest wound which now measured 7 cm long x 2cm wide. A Jackson-Pratt drain was temporarily placed and the wound was then reinforced with steri-strips. The patient was followed closely with clinic appointments, lab work, chest X-rays, and CT scans. One year after the operation, the patient had approximately 50% union, at two years 80% union. (Figures 3 A, B, C).

The patient is now six years post-operative, and is able to carry out all activities including long distance motorcycle riding.

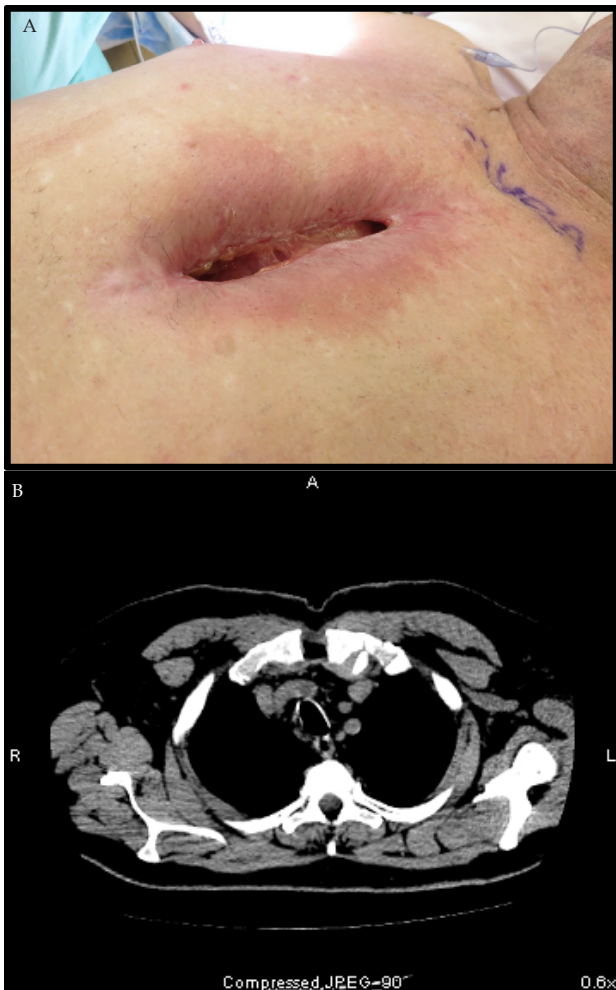


Figure 1 (A, B) Preoperative

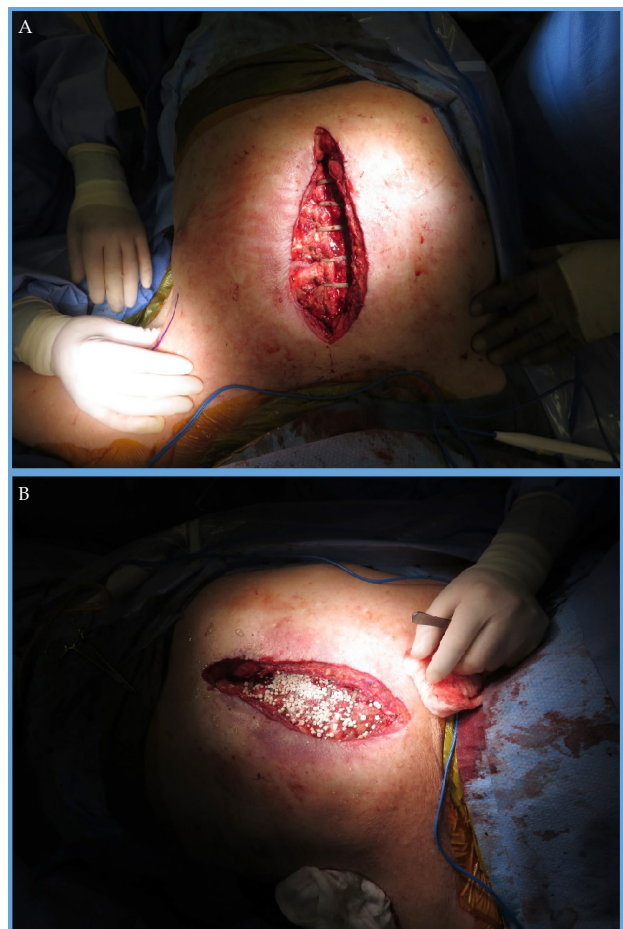


Figure 2 (A, B) Intraoperative

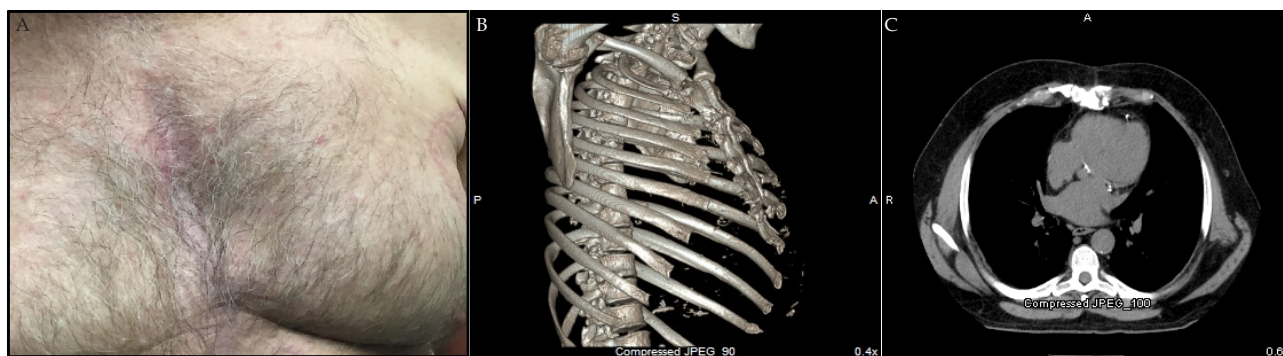


Figure 3 (A, B, C) Postoperative

DISCUSSION

DSWI continues to be a concerning complication of cardiac surgery due to association with increased mortality rates, prolonged hospital stay, and increased treatment costs^[1]. Given the severe consequences of DSWI, effective management is imperative.

Although principles of treating deep infections are standard (debridement of necrotic tissue, drainage of infected spaces, antibiotic therapy, and closure of the sternal space using the most appropriate technique), they must be individually tailored to each patient based on patient's overall clinical presentation, the depth of infection, and the organism causing the infection^[2].

Adherence to evidence-based recommendations is critically important in patients with multiple risk factors. Case studies available about DSWI in the literature focus on specific treatment options such as type of flap^[4], negative pressure wound therapy use and antibiotic instillation^[5], antibiotic loaded bone cement combined with negative pressure wound therapy^[6], and type of antibiotic^[7].

This case study adds an holistic staged treatment approach showing application of currently available guidelines^[2] for DSWI management in a patient with multiple risk factors. Correcting metabolic abnormalities prior to the surgical procedure is fundamental to the success of management. Additionally, the use of Sternal ZIPFIX System provided an excellent alternative when tissue stability necessary for traditional wiring or plating was absent.

CONCLUSION

The case emphasizes the importance of an holistic evidence-based staged treatment approach for the management of DWSI in a patient with multiple risk factors. Areas of emphasis include taking the time to correct metabolic abnormalities prior to surgical intervention and use of the Sternal ZIPFIX System when tissue stability for traditional

wiring or plating is absent. In some communities, reconstructive surgery is no longer carried out by Plastic Surgeons. This creates a gap that can be filled by Hand Surgeons who are well-versed in reconstructive microsurgery.

REFERENCES

1. Phoon PHY, Hwang NC. Deep sternal wound infection: Diagnosis, treatment, and prevention. *J Cardiothorac Vasc Anesth*. 2020; **34**: 1602-1613. [PMID: 31623967]; [DOI: 10.1053/j.jvca.2019.09.019]
2. Lazar HL, Vander Salm T, Engelman R, Orgill D, Gordon S. Prevention and management of sternal wound infections. *J Thorac Cardiovasc Surg*. 2016; **152**: 962-972. [PMID: 27555340]; [DOI: 10.1016/j.jtcvs.2016.01.060]
3. Nezafati P, Shomali A, Kahrom M, Omidvar Tehrani S, Dianatkah M, Nezafati MH. ZipFix versus conventional sternal closure: One-year follow-up. *Heart Lung Circ*. 2019; **28**(3): 443-449. [PMID: 29548913]; [DOI: 10.1016/j.hlc.2018.01.010]
4. Al-Ebrahim KE. Management of deep sternal wound infection: Complete sternal osteomyelitis. *Heart Surg Forum*. 2020; **23**(3): E281-E284. Published 2020 May 5. [PMID: 32524983]; [DOI: 10.1532/hcf.2805]
5. Morgante A, Romeo F. Deep sternal wound infections: A severe complication after cardiac surgery. *G Chir*. 2017; **38**(1): 33-36. [PMID: 28460201]; [PMCID: PMC5730397]; [DOI: 10.11138/gchir/2017.38.1.033]
6. Jiang X, Jiao G, Li M, Rong X. Using antibiotic-loaded bone cement for a patient with deep sternal wound infection after cardiac surgery. *Interact Cardiovasc Thorac Surg*. 2022; **34**(6): 1150-1151. [PMID: 34849902]; [PMCID: PMC9159415]; [DOI: 10.1093/icvts/ivab332]
7. Guzek A, Suwalski G, Tomaszewski D, Rybicki Z. Dalbavancin treatment in a deep sternal wound MRSA infection after coronary artery bypass surgery: A case report. *J Cardiothorac Surg*. 2018; **13**(1): 3. [PMID: 29304832]; [PMCID: PMC5755357]; [DOI: 10.1186/s13019-017-0690-5]