

Radial Palsy After Hinged External Fixator Application: A Terrible Complication of a Terrible Elbow Triad

Patricia Crespo-Lastras¹, MD; Eloy D. Tabeayo-Alvarez², MD; Daniel Lopez-Dorado³, MD; Francesca Teodonna⁴, MD; Pablo Vadillo-Cardona¹, MD, PhD; E. Carlos Rodriguez-Merchan¹, MD, PhD

1 Department of Orthopedic Surgery, La Paz University Hospital, Madrid, Spain;

2 Albert Einstein College of Medicine. Department of Orthopaedic Surgery, Montefiore Medical Center, New York, NY, USA;

3 Department of Orthopedic Surgery, Infanta Elena University Hospital, Madrid, Spain;

4 Department of Orthopedic Surgery, Jimenez Díaz Foundation University Hospital, Madrid, Spain.

Conflict-of-interest statement: The author(s) declare(s) that there is no conflict of interest regarding the publication of this paper.

Open-Access: This article is an open-access article which was selected by an in-house editor and fully peer-reviewed by external reviewers. It is distributed in accordance with the Creative Commons Attribution Non Commercial (CC BY-NC 4.0) license, which permits others to distribute, remix, adapt, build upon this work non-commercially, and license their derivative works on different terms, provided the original work is properly cited and the use is non-commercial. See: <http://creativecommons.org/licenses/by-nc/4.0/>

Correspondence to: E. Carlos Rodriguez-Merchan, Department of Orthopedic Surgery, La Paz University Hospital, Madrid, Spain.
Email: ecrmerchan@hotmail.com

Received: June 9, 2022

Revised: June 26, 2022

Accepted: June 29 2022

Published online: August 28, 2022

ABSTRACT

The use of an external fixator (EF) is getting more and more common in the treatment of elbow fracture-dislocations. However, radial nerve (RN) injury is a major complication. To the best of our knowledge, only 14 cases have been reported in literature. We present the case of a 46-year old man who suffered a complex elbow fracture-dislocation (terrible elbow triad). Closed reduction was performed in the Emergency Room. Five days later the patient underwent scheduled surgery. Osteosynthesis of the radial head and repair of the lateral collateral ligament, coronoid process and

the medial collateral ligament was performed. As residual partial instability at more of 60° of extension was observed, an EF was implanted percutaneously. In the postoperative period an incomplete sensory and motor RN injury was found and immediate rehabilitation treatment was indicated. At six weeks postoperative, removal of EF was carried out. Before extracting the pins, a perineurium injury of the RN in the deep plane caused by the most distal humeral pin without transection of the nerve was seen. Scar tissue debridement and suture of the perineurium plus coverage of the injured area with NerveProtector membrane were performed. Intraoperative elbow stability was achieved. After 18 months, the elbow was stable with a range of motion of 30°-120°, 5/5 strength of the wrist and 4/5 for finger extension. The last electromyography showed reinnervation signs. To avoid the iatrogenic injury of the RN, the implantation of an EF in the elbow must be always performed under direct visualization of the nerve.

Key words: Elbow; Terrible triad; External fixation; Radial nerve palsy

© 2022 The Author(s). Published by ACT Publishing Group Ltd. All rights reserved.

Crespo-Lastras P, Tabeayo-Alvarez ED, Lopez-Dorado D, Teodonna F, Vadillo-Cardona P, Rodriguez-Merchan EC. Radial Palsy After Hinged External Fixator Application: A Terrible Complication of a Terrible Elbow Triad. *International Journal of Orthopaedics* 2022; 9(4): 1681-1684 Available from: URL: <http://www.ghrnet.org/index.php/ijo/article/view/3335>

INTRODUCTION

The use of external fixators (EFs) in complex elbow injuries is standard practice. Multiple studies support their use in the treatment of elbow fracture-dislocations, to protect a ligamentous repair or reconstruction of acute or chronic ligamentous injuries, after arthrolysis due to stiffness or as a distractor after an interposition arthroplasty^[1-3].

Hinged EFs allow for early controlled range of motion (ROM) of the joint while providing support and stability to concomitant repairs or reconstructions. This can only be achieved when the hinged device

is correctly placed to recreate the axis of rotation of the elbow^[1,4].

Complications related to EFs can be classified in minor complications such as skin irritation or serous exudate from the pin tract (15%) and mayor complications such as pin tract infection, osteolysis or malalignment (up to 10%)^[2,5]. Radial nerve injury (RN) is a very uncommon major complication. To the best of our knowledge, only 14 cases have been reported, with a wide range of outcomes^[6,7].

Our goal is to describe our experience and provide a review of the current knowledge to minimize this complication and maximize the outcomes.

CASE REPORT

Our patient is a 46-year-old male who suffered a fall from a stair with an indirect trauma to the right elbow. He presented to the Emergency Room with a complex elbow fracture-dislocation, which required closed reduction under sedation (Figure 1). After five days of immobilization, the patient underwent scheduled surgery. A posterior incision was performed, and full thickness flaps were raised. The joint was approached through a Kocher interval, and subsequent anatomic reduction and fixation of the radial head was performed using 3 cannulated, headless screws (Acutrak, Acumed). Repair of the lateral collateral ligament (LCL) was performed using a suture anchor at the isometric point of the lateral epicondyle. Then, through the same posterior cutaneous incision, a Hotchkiss approach was developed to repair the coronoid-medial collateral ligament complex (MCL) with sutures through the bone-capsule interface into a suture anchor.

Once the repair of all bony and ligamentous structures was completed, residual instability beyond 60° of extension was found, and decision was made to apply an EF (*Dynamic Joint Distractor, DJD II, Stryker*)^[8]. Percutaneous stab incisions were made, using blunt dissection to reach the cortex, and passing the pins using a soft tissue protector. Standard technique was used to choose the location of the pins, looking for they were inserted at the distances of 3 and 5 cm proximal to the elbow joint line^[9] (Figure 2). The pin introduction was making by elbow joint flexed because the safe zone, a region where the RN would not be located on the humerus, was longer than in extension^[10].

In the early postoperative period, an incomplete sensory and motor RN injury was detected and immediate physical therapy was started. As suggested in previous research in a setting of a fracture-dislocation or chronic instability, 6 to 12 weeks of stabilization in an external fixator is recommended, to allow for bone and soft tissue healing. In our experience, 6 weeks of protection in an EF will suffice, and therefore, at post-operative week 6, removal of the EF was performed in the operating room^[2].

Using a lateral approach to the distal humerus, careful dissection was performed before extracting the pins. A perineurium injury of the RN was found, caused by the distal most humeral pin, without transection of the nerve (Figure 3). Scar tissue debridement and suture of the perineurium with #6-0 Prolene was performed, and the nerve was wrapped with a Nerve Protector membrane (Axoguard) (Figure 4). Intraoperative elbow stability was assessed, with a stable arc throughout the range, of 120-20°, and full pronation and supination.

An intensive rehabilitation (physical therapy) program was arranged, with poor compliance from the patient and multiple missed appointments. Electromyography performed 4 months after the initial surgery described a severe axonal injury. At 6 months of follow-up

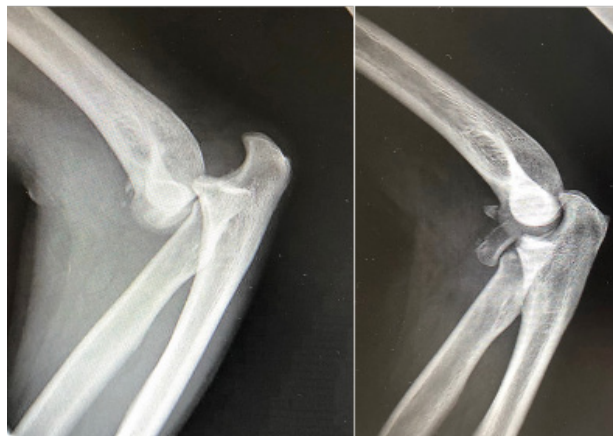

Figure 1 Pre- (left) and post-reduction (right) images.

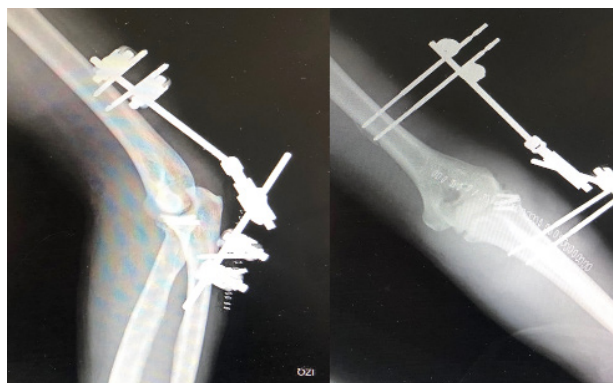

Figure 2 Postoperative X-ray control: lateral view (left); anteroposterior view (right).

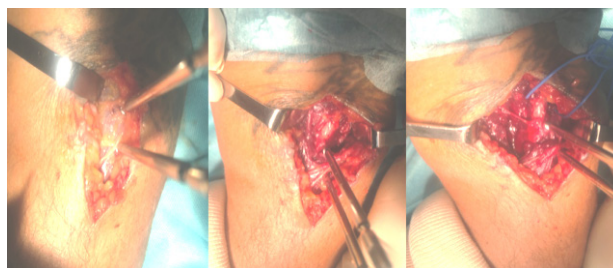

Figure 3 Intraoperative images during external fixator (EF) removal. The close relationship between the pin and the radial nerve can be appreciated.

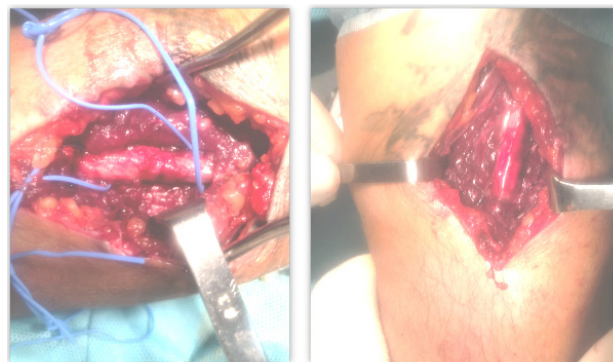


Figure 4 Scar tissue debridement and suture of the perineurium with Prolene 6/0 were performed, plus coverage of the injured area with Nerve Protector (Axoguard) membrane.

he had a stable elbow with a range of motion (ROM) of 40°-100°, complete pronation and supination (Figure 5), motor strength in wrist extension was 4/5 and finger extension was 3/5.

Table 1 Reported radial nerve injuries after elbow external fixation.

Cases	Type of EF	Pin introduction	Results	Year	Authors [Reference]
1	Orthofix	Open	Complete recovery	2017	Trigo et al [6]
2	DJD II	Percutaneous	No recovery		
3	DJD II	Percutaneous	Complete recovery		
4	DJD II	Percutaneous	Complete recovery	2016	Poglia et al [7]
5	-	Percutaneous	-	2014	Ring et al [3]
6	Orthofix	Open	Complete recovery	2013	Stavlas et al [4]
7	DJD II	Percutaneous	Complete recovery	2013	Caldwell et al [11]
8	DJD II	Percutaneous	No recovery		
9	DJD II	Percutaneous	No complete recovery	2011	Baumann et al [5]
10	DJD II	Percutaneous	No complete recovery		
11	DJD II	Percutaneous	No complete recovery		
12	CEH	Percutaneous	Complete recovery	2000	Fox et al [1]
13	CEH	Percutaneous	Complete recovery	1999	Tomaino et al [12]
14	CEH	Percutaneous	Good	1998	McKee et al [13]

EF, external fixator; DJD, Dynamic Joint Distractor; CEH, Compass Elbow Hinge

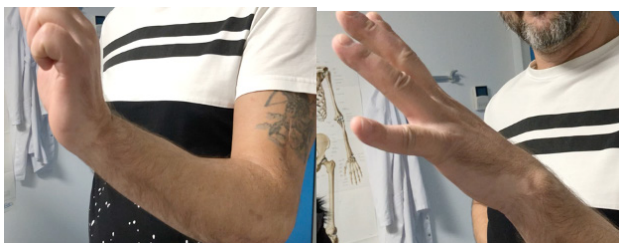

Figure 5 After one year and a half, the patient presented a stable elbow with a range of motion (ROM) of 30°-120°, 5/5 strength of the wrist and 4/5 for finger extension. The new electromyography (EMG) showed reinnervation signs compared to the previous one.

At final follow up, 1.5 years after the initial injury, the patient presented a stable elbow with a ROM of 30°-120°, 5/5 strength of the wrist and 4/5 for finger extension. A new electromyographic study showed reinnervation signs compared to the previous one. The radiographic result is shown in (Figure 6).

DISCUSSION

Iatrogenic injury of the RN is a devastating complication for both patient and surgeon. In the presented case, the RN became entrapped by the pin despite standard safety precautions such as blunt dissection and the use of a soft tissue protector, causing a high radial palsy. This is not an isolated case, as there are other similar injuries described in the literature. To our knowledge, there are at least another 14 cases that have been reported. In these cases different pin positioning techniques were chosen, and only 5 patients went onto full recovery (Table 1)^[1,3-7,11-13].

The RN presents an intricate trajectory at the distal humerus, making it prone to iatrogenic injuries. The nerve travels through the spiral groove in an oblique fashion, where it lays posterior to the proximal fibers of the medial head of the triceps muscle, which is interposed between the RN and the humerus in the first part of the spiral groove^[2]. Then the nerve can be found lateral to the humerus, as it perforates the intermuscular septum laterally to enter the anterior compartment. It then travels within the deep planes, in a groove between the brachialis and the proximal brachioradialis muscle^[9].

Multiple studies have analyzed the anatomic relationships of the RN in the normal population, in order to predict its location. Kaminemi *et al.* investigated the anatomic position of the RN in the medial-lateral plane, expressed as an intercondylar distance^[14]. They performed a study with 70 cadaveric specimens, measuring the exact

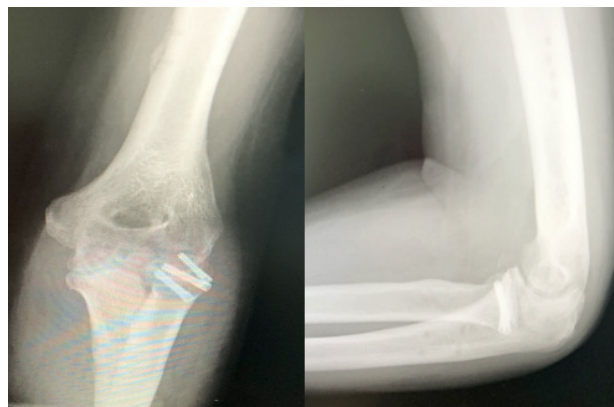


Figure 6 Radiographic study performed one year and a half after the fracture-dislocation showed a satisfactory result: anteroposterior view (left); lateral radiograph (right).

point were the radial nerve crossed into the anterior compartment. They measured the intercondylar distance and found that the nerve was never nearer than 1.2 transepicondylar distances from the lateral epicondyle. They concluded that lateral pins can be safely placed at 0.7 transepicondylar distances from the lateral epicondyle. However, upon dissection of 95 cadaveric specimens, Wegmann *et al* found that there is no safe zone in that anatomic region, due to the high degree of variability in the nerve trajectory at that level^[15].

Cheung *et al.* analyzed 100 EFs with two different configurations^[2]. The pins were usually placed with a percutaneous incision of the skin, performing blunt dissection to the bone and using a drill sleeve during pin placement. In their study, no nerve injuries were found. Their explanation for their findings was that the procedures were carried out by experienced surgeons and that in many cases the pins were placed under direct visualization. Clement *et al.* investigated the relationship between the radial nerve and the humeral pins following a percutaneous technique in 20 specimens^[9]. They found a RN injury in 4 of the 40 humeral pins placed. One of the proximal pins transected the RN, while in the other 3 cases it was the distal humeral pin that injured the nerve. In addition, in 9 cases the nerve was found to be in contact with the pins (5 proximally and 4 distally). The authors recommend that due to the high risk of RN injury, a bigger skin incision and blunt dissection to the humeral cortex should be performed prior to humeral pin placement. However, injury to the RN has also been reported after direct visualization and protection of the nerve^[6,11,12].

Lack of experience with the use of EF devices has been considered a relative contraindication to this procedure^[6,10,13], but the number of complications may be reduced by understanding the anatomy of the RN, and using meticulous and careful dissection prior to pin placement.

In conclusion, major neurologic complications associated with elbow EF can occur. Percutaneous techniques have a higher likelihood of such complications, but knowledge of the regional anatomy, as well as meticulous surgical planning and direct nerve visualization can help minimize the risk of iatrogenic RN injury.

REFERENCES

1. Fox RJ, Varitimidis SE, Plakseychuk A, Vardakas DG, Tomaino MM, Sotereanos DG. The compass elbow hinge: indications and initial results. *J Hand Surg* 2000; **25(6)**: 568-72. [DOI: 10.1054/jhsb.2000.0425].
2. Cheung EV, O'Driscoll SW, Morrey BF. Complications of hinged external fixators of the elbow. *J Shoulder Elbow Surg* 2008; **17(3)**: 447-53. [DOI: 10.1016/j.jse.2007.10.006]. Epub 2008 Mar 4.
3. Ring D, Bruinsma WE, Jupiter JB. Complications of hinged external fixation compared with cross-pinning of the elbow for acute and subacute instability. *Clin Orthop Relat Res* 2014; **472(7)**: 2044-8. [DOI: 10.1007/s11999-014-3510-].
4. Stavlas P, Gliatis J, Polyzois V, Polyzois D. Unilateral hinged external fixator of the elbow in complex elbow injuries. *Injury* 2004; **35(11)**: 1158-66. [DOI: 10.1016/j.injury.2003.09.002].
5. Baumann G, Nagy L, Jost B. Radial nerve disruption following application of a hinged elbow external fixator: a report of three cases. *J Bone Joint Surg Am* 2011; **93(10)**: e51. [DOI: 10.2106/JBJS.J.00436].
6. Trigo L, Sarasquete J, Noguera L, Proubasta I, Lamas C. Radial nerve injury following elbow external fixator: report of three cases and literature review. *Arch Orthop Trauma Surg.* j2017; **137(7)**: 953-7. [DOI: 10.1007/s00402-017-2711-1]. Epub 2017 May 8.
7. Poglia P, Wehrli L, Steinmetz S, Zermatten P. Radial nerve palsy after the use of an adjuvant hinged external fixator in a complex fracture-dislocation of the elbow: a case report and review of the literature. *J Med Case Reports.* 2016; **10(1)**: 121. [DOI: 10.1186/s13256-016-0904-9]; [PMID: 27170152]
8. Dynamic Joint Distractor II Extyernal Fixation System - Stryker MedED [pdf] https://www.google.es/url?esrc=s&q=&rct=j&sa=U&url=https://www.strykermeded.com/media/1673/dynamic-joint-distractor-ii.pdf&ved=2ahUKEwj3-JCm2-j3AhWqQjABHaeaAOIQFnoECAoQA&usg=AOvVaw1ncSIsyakJPnR2a_pGegt2 (last accessed 18 May 2022)
9. Clement H, Pichler W, Tesch NP, Heidari N, Grechenig W. Anatomical basis of the risk of radial nerve injury related to the technique of external fixation applied to the distal humerus. *Surg Radiol Anat* 2010; **32(3)**: 221-4. [DOI: 10.1007/s00276-009-0568-x]. Epub 2009 Oct 6.
10. Sukegawa K, Kuniyoshi K, Suzuki T, Matsuura Y, Onuma K, Kenmoku T, et al. Effects of the elbow flexion angle on the radial nerve location around the humerus: a cadaver study for safe installation of a hinged external fixator. *J Hand Surg Asian-Pac* 2018; **23(03)**: 388-94. [DOI: 10.1142/S242483551850042X].
11. Caldwell JM, Kim HM, Levine WN. Radial nerve injury associated with application of a hinged elbow external fixator: a report of 2 cases. *J Shoulder Elbow Surg* 2013; **22(3)**: e12-e16. [DOI: 10.1016/j.jse.2012.11.012]. Epub 2013 Jan 23.
12. Tomaino MM, Sotereanos DG, Westkaemper J, Plakseychuk A. Posterior interosseous nerve palsy following placement of the compass elbow hinge for acute instability: a case report. *J Hand Surg* 1999; **24(3)**: 554-60. [DOI: 10.1053/jhsu.1999.0554].
13. McKee MD, Bowden SH, King GJ, Patterson SD, Jupiter JB, Bamberger HB, et al. Management of recurrent, complex instability of the elbow with a hinged external fixator. *J Bone Joint Surg Br* 1998; **80(6)**: 1031-6. [DOI: 10.1302/0301-620x.80b6.8536].
14. Kamineni S, Ankem H, Patten DK. Anatomic relationship of the radial nerve to the elbow joint: Clinical implications of safe pin placement. *Clin Anat* 2009; **22(6)**: 684-8. [DOI: 10.1002/ca.20831].
15. Wegmann K, Lappen S, Pfau DB, Neiss WF, Müller LP, Burkhart KJ. Course of the radial nerve in relation to the center of rotation of the elbow—The need for a rational safe zone for lateral pin placement. *J Hand Surg* 2014; **39(6)**: 1136-40. [DOI: 10.1016/j.jhsa.2014.03.019]. Epub 2014 May 5.