

Articular Wear Patterns Observed in Hip Arthroscopic Patients Across Early Disease States: A Retrospective Cohort Study

Alexander N Eagles^{1,3}, Sharon Kermeci², Dale I Lovell³, Christopher KTG Erian², Patrick CL Weinrauch^{2,4}

1 School of Medicine, Gold Coast, Bond University, Gold Coast, Queensland, Australia;

2 Brisbane Hip Clinic, Brisbane, Queensland, Australia;

3 School of Health and Behavioural Science, University of the Sunshine Coast, Queensland, Australia;

4 School of Medicine, Gold Coast Campus, Griffith University, Gold Coast, Queensland, Australia.

Conflict-of-interest statement: The author(s) declare(s) that there is no conflict of interest regarding the publication of this paper.

Open-Access: This article is an open-access article which was selected by an in-house editor and fully peer-reviewed by external reviewers. It is distributed in accordance with the Creative Commons Attribution Non Commercial (CC BY-NC 4.0) license, which permits others to distribute, remix, adapt, build upon this work non-commercially, and license their derivative works on different terms, provided the original work is properly cited and the use is non-commercial. See: <http://creativecommons.org/licenses/by-nc/4.0/>

Correspondence to: Alexander N Eagles, School of Medicine, Gold Coast, Bond University, Gold Coast, Queensland, Australia.

Telephone: +61754594464

Email: alexander.eagles@health.qld.gov.au

Received: May 26, 2023

Revised: June 10, 2023

Accepted: June 13 2023

Published online: October 20, 2023

ABSTRACT

AIM: The aim of this study was to retrospectively analysis intraoperative hip arthroscopic data to observe acetabular, femoral and labral pathology irrespective of hip arthroscopic indication.

METHODS: This study represents the largest single retrospective study of 1127 patients between 2008 and 2013. 37.53 years (SD \pm 13.74) with an age range of 12-82.

RESULTS: Localisation of acetabular chondral pathology was widely variable with locations C1 and D1 representing the most common regions of damage. Femoral chondral pathology was reasonably evenly distributed with slight predominance at locates C and D.

Labral tears predominated in locations C and D. The femoral articular damage was predominantly grade 1, the acetabular articular damage was fairly evenly distributed.

DISCUSSION: Large proportions of wear were observed at the peripheral superior and anterior regions of the lunate surface of the acetabulum in keeping with previous research. However, a large proportion of the wear occurred in the more central regions less consistent with previous research. Our data did not reflect previous research that noted grade 4 acetabular damage frequently extending into superior posterior zones. The superior and anterior regions (C & D) were the predominate areas for labral tears identified within our population group.

Key words: Acetabular wear patterns; Femoral head wear patterns; Hip joint; Arthroscopy

© 2023 The Author(s). Published by ACT Publishing Group Ltd. All rights reserved.

Eagles AN, Kermeci S, Lovell DI, Erian KTG C, Weinrauch PCL. Articular Wear Patterns Observed in Hip Arthroscopic Patients Across Early Disease States: A Retrospective Cohort Study. *International Journal of Orthopaedics* 2023; **10(3)**: 1743-1747 Available from: URL: <http://www.ghrnet.org/index.php/ijo/article/view/3369>

INTRODUCTION

The hip joint (femoroacetabular joint) is a synovial ball and socket joint, produced by the articulation of the femoral head inferiorly in the acetabulum superiorly. The acetabulum is formed by the ossification centres of the ilium, ischium and pubis^[1,2]. Both the femoral head and acetabular surface are lined with articular cartilage, with the exception of where the ligament teres rises out of the femoral head and the central portion of the acetabulum, which contains fibroelastic fat covered by synovial membrane^[1,2]. The lunate surface of the acetabulum forms a crescent moon shape with the cartilage thickest and broadest in the anterosuperior position corresponding to the maximum region of pressure when standing erect^[1,2]. The anteriolateral aspect of the femoral head is the predominant site of load bearing in the erect position resulting in maximal articular cartilage thickness^[1,2]. The socket is deepened by the acetabular labrum which improves joint stability, increases joint surface

area, improves intra articular synovial fluid distribution, facilitates nutrition to the articular surface and reduces friction^[3-6]. The joint is reinforced with the fibrous capsule and pubofemoral, iliofemoral and ischiofemoral ligaments which prevent excessive abduction, extension and reinforce the capsule^[1].

The hip joint is susceptible to wear and degenerative pathology with increasing prevalence in patients of advancing age, history of dysplasia, femoroacetabular impingement (FAI), repetitive loading activities, obesity and previous trauma^[7-13]. The osseous anatomy and FAI influence the loading in the hip joint and are well established causes of chondral injury, degenerative change and labral injury^[9,10]. Furthermore labral injury has its self been identified as a cause of osteoarthritis in the hip^[14]. Loading patterns of repeated external rotation, flexion, abduction, adduction and having reduced internal rotation have been identified in the literature as particularly detrimental to the chondral surfaces and labrum^[15-17]. Due to the multifactorial and frequently overlapping aetiologies of the development of wear patterns of the acetabulum, labrum and femoral head, variation thereof frequently presents clinically.

Consequently, wear location varies depending on the predominant underlying aetiology. In dysplastic hips previous research has identified cartilage and labrum degeneration commonly originates in the anterosuperior portion and are typically preceded by those of the femoral head^[8]. While FAI and osseous changes predispose the labrum to greater mechanical force and appear to increase acute and chronic labral injuries and degenerative articular change, typically presenting anteriorly^[9,10,18]. Irrespective of wear location; intra-articular hip pathology often presents with groin and or hip pain which may have a referral pattern to the knee, especially in osteoarthritic change^[2,19,20]. The role of hip arthroscopy has increased in recent years with a number of improvements in technique and number of procedures performed^[21,22]. Indications for hip arthroscopy are vast including pathology of the central compartment, peripheral compartment, peritrochanteric compartment and deep gluteal space^[23]. While the indications for hip arthroscopic intervention and success thereof is an important domain of research, it is beyond the scope of this study which was to document the wear patterns within the largest cohort studied to date.

While previous research has analysed acetabular, femoral and labral wear location and pathology, previous research has not offered a comparable patient population to retrospectively analyse wear patterns regardless of the indication for hip arthroscopy. Pascual-Garrido et al does examine a significant patient population, however the inclusions are limited to patients with the diagnosis of FAI prior to the procedure^[24]. Similarly, Beck et al focused his analysis on location and damage to those patients with established impingement pathology^[9]. While Fontana et al found a proportion of patients with chondral lesions have no identifiable FAI^[25]. The established broader pathogenesis of acetabular, femoral and labral wear patterns is well established in the literature^[7-13]. Consequently, the authors believe the analysis of a large cohort of patients irrespective of indication for hip arthroscopy will offer meaningful insight into articular pathology across the spectrum of early disease states. Therefore, the purpose of this article was to examine the pattern of articular wear across various zones of the hip joint found at arthroscopy for the cohort of 1127 patients. We hypothesise that wear patterns would correspond with predominate load bearing sites, being the anterosuperior portion of the lunate surface of the acetabulum and the anterolaterally aspect of the femoral head. With respect to labral tears we hypothesised that they would predominate anteriorly as per previous literature^[18,26-28].

METHODOLOGY

Participants

Retrospective intraoperative analysis of hip arthroscopic data was used for this study. Data was collected between February 2008 to October 2013. A total of 1127 hip arthroscopic patients were included in the study [493 (43.75%) left hip, 634 (56.25%) right hip]. Average age of patients was 37.53 years (SD+/- 13.74) with an age range of 12-82. Of the patients included in the study 517 (45.87%) were female and 610 (54.13%) were male. 1001 were completed as unilateral hip arthroscopies and a further 126 as bilateral arthroscopies.

Inclusions and exclusion criteria

Patients were deemed eligible to participate in the study if they were receiving a unilateral or bilateral hip arthroscopy between 2008 and 2013 for investigative or therapeutic purposes. Pain or imaging identified pathology was the indication for surgery in all cases. No patient had a history of renal disease or demonstrated dysfunction on preoperative blood testing. Patients were excluded from the study if they had prosthetic material within the hip joint, had previous arthroscopic surgery with another surgeon, or received a repeat hip arthroscopy (the repeat data was not included in the analysis).

In total 39 patients were excluded for the study. Exclusion criteria included patients with a prosthetic acetabular surface (6 patients), previous hip arthroscopy to the same leg by another surgeon (15 patients) and patients receiving a repeat hip arthroscopy (18 patients) (second procedure was not included in the analysis).

Hip Arthroscopic Procedure

Hip arthroscopic procedures were performed under general anaesthesia, including muscle paralysis in the supine position with controlled hip distraction on a fracture table. Location and padding of traction points was confirmed and trial of traction released traction reapplied for the conduct of central compartment procedure. Ultrasound +/- II assisted posterior trochanteric portal development. Remaining central compartment portal(s) developed under direct arthroscopic vision. Portals developed over 1.2mm Nitinol wire. Particular attention was made to limit depth of incision over anterior portal to skin thickness only. Limited working portal capsulotomy performed as required. In peripheral compartment procedures, the traction is released and dedicated portals are established with limited capsulectomy. Saline irrigation, pressure, and flow rate are monitored. At the end of the procedure, 20 mL of naropin 0.75% and 1 mL of celestone were infiltrated into the hip joint.

Acetabular and femoral head wear location

Patients hip arthroscopic data was categorized by location and damage grade with respect to the acetabulum and femoral head. Regarding location; the acetabulum was further sub divided into an inner (50%) and outer (50%) zone for greater accuracy as per previous research^[25] (Figure 1A). As described by Fontana et al^[25] the acetabulum is divided in 5 sectors. 2 are inferior; A (posterior) and E (anterior) and 3 are superior; B, C and D. Each sector is subdivided in 2, a peripheral, marked with "0" and a central, marked with "1" (Figure 1A).

For the purposes of this study no grading classification was applied to the acetabular labrum tears, which was considered to be present or not present. Acetabular tear location was also reported using the A-E model (Figure 1A), which corresponds to the clockwise position, with the 12 position superior, 3 position anterior, 9 position posterior and 6 position inferior (Figure 1A)^[25]. The location of damage for

the femoral head was divided into four sections A (medial or fovea); B (anterior); C (superior) and D (posterior) as described in previous research (Figure 1b)^[25].

Classification of damage grade to the cartilage of the acetabulum and femoral head was adapted from Beck et al^[9] (Table 1). The grades of damage were subsequently represented as 0-4 in tables 2-4.

Statistics

As a retrospective descriptive study the primary objective of this study was to demonstrate the location and distribution of wear patterns across the acetabulum, labral and femoral head in the largest cohort of hip arthroscopic patients published to date. Data is represented in a series of tables with patient counts of location of damage on the Y axis and grade of damage in the X-axis. Percentages with respect to the total patient population (1127) are present in total columns.

Ethics

This research activity has received Institutional Review Board approval from the Uniting Health Care Health Research Ethics Committee (Queensland, Australia), and was conducted in accordance with the World Medical Association Declaration of Helsinki.

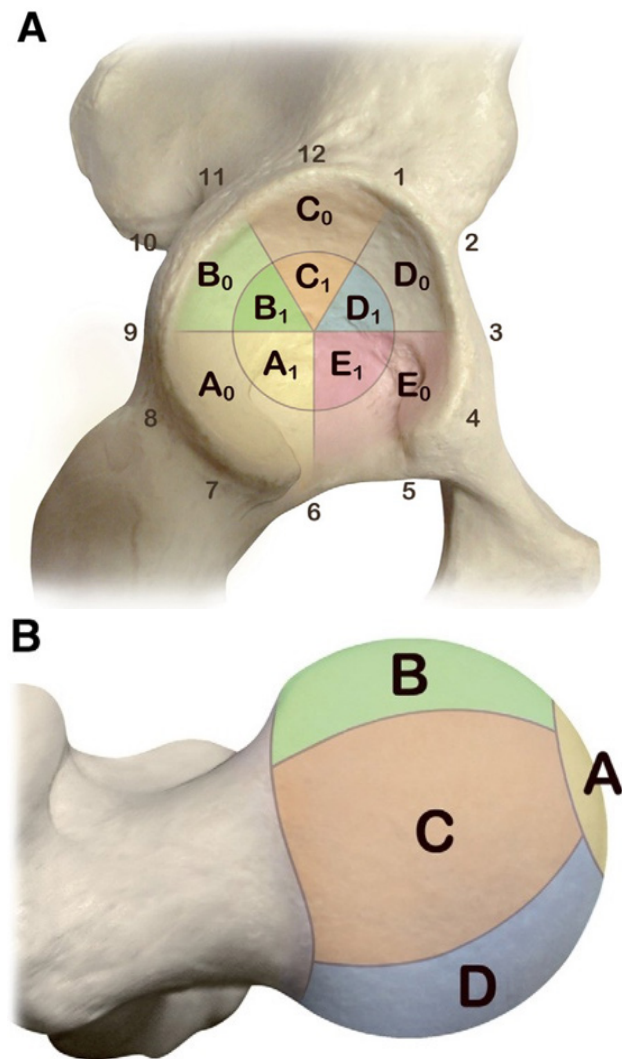


Figure 1 (A) Acetabular inner (A1-E1), acetabular outer (A0-E0) and labral zone (clockface 1-12) classifications. (B) Femoral head zone classification (A-D). Images adapted from Fontana et al^[25].

RESULTS

Femoral head chondral pathology was distributed as follows. location A: 137 (12.2%), B: 222 (19.7%), C: 292 (25.9%) and D: 229 (20.3%) (Table 1). Localisation of labral tears predominated in locations C and D. Distribution was as follows. A:5 (0.4%), B:127 (11.3%), C:724 (64.2%), D:749 (66.5%) and E:31 (2.8%) (Table 2). Localisation of acetabular chondral pathology was widely variable with locations C₁ and D₁ representing the most common regions of damage A₀: 12 (1.1%), B₀: 248 (22%), C₀: 298 (26.4%), D₀: 299 (26.5%), E₀: 9 (0.8%), A₁: 21 (1.9%), B₁: 271 (24%), C₁: 932 (82.7%), D₁: 789 (70%), E₁: 40 (3.5%) (Table 3).

Femoral chondral damage was identified as grade 1: 469 (41.6%), grade 2: 223 (19.8%), grade 3: 98 (8.69%), grade 4: 90 (7.99%) (Table 1). Acetabular damage was identified as grade 1: 852 (75.6%), grade 2: 699 (62%), grade 3: 662 (58.74%), grade 4: 706 (62.64%). Additional pathological findings within patient group included 49 (4.3%) patients that had associated ligament of tears tear, 178 (15.8%) had synovitis in the joint, 198 (17.6%) patients required femoral osteoplasty and 9 (0.8%) requiring acetabular osteoplasty.

Table 1 Classification of damage to cartilage as adapted from Beck et al^[9].

Description	Criteria
Normal (0)	Macroscopically sound cartilage
Malacia (1)	Roughening of surface, fibrillation
Debonding (2)	Loss of fixation to the subchondral bone, macroscopically sound cartilage; carpet phenomenon
Cleavage (3)	Loss of fixation to the subchondral bone; frayed edges, thinning of the cartilage, flap
Defect (4)	Full-thickness defect

Table 2 Localisation of Femoral Chondral Pathology and Grade of damage.

Grade of damage					
Location	1	2	3	4	Totals
A	39	21	23	54	137 (12.2%)
B	134	63	20	5	222 (19.7%)
C	163	77	35	17	292 (25.9%)
D	133	62	20	14	229 (20.3%)
Totals	469 (41.6%)	223 (19.8%)	98 (8.69%)	90 (7.99%)	

Table 3 Localisation of Labral Tears.

Location					
	A	B	C	D	E
Labral Tear	5 (0.4%)	127 (11.3%)	724 (64.2%)	749 (66.5%)	31 (2.8%)

Table 4 Localisation of Acetabular Chondral Pathology and Grade of damage.

Grade of damage					
Location	1	2	3	4	Totals
A0	6	5	0	1	12 (1.1%)
B0	175	65	7	1	248 (22%)
C0	201	69	17	11	298 (26.4%)
D0	211	67	11	10	299 (26.5%)
E0	2	4	2	1	9 (0.8%)
A1	12	6	3	0	21 (1.9%)
B1	70	88	52	61	271 (24%)
C1	91	195	298	348	932 (82.7%)
D1	72	183	265	269	789 (70%)
E1	12	17	7	4	40 (3.5%)
Totals	852 (75.6%)	699 (62%)	662 (58.74%)	706 (62.64%)	

DISCUSSION

The purpose of this study was to examine the pattern of articular wear across various zones of the hip joint found for the cohort of 1127 patients. We hypothesised that wear patterns would correspond with predominate load bearing sites, being the anterosuperior portion of the lunate surface of the acetabulum and the anterolateral aspect of the femoral head. With respect to labral tears we hypothesised that they would predominate anteriorly within the cohort.

The principle regions of damage within in the acetabulum was C₁ with 932 (82.7%) and D₁ 789 (70%) for the patient population. Furthermore, with zones C₁ and D₁ frequency of occurrence increase with degree of damage in ascending order (Table 4). There was also a predominance of grade 1-2 damage in the regions of B₀, C₀, D₀. Collectively these regions corresponded to the peripheral superior and anterior regions of the lunate surface of the acetabulum which was postulated to be the predominant regions of wear given the mechanical requirements. However, a large proportion of the wear occurred in the more central regions (C₁ and D₁) which was less consistent with previous research findings^[9,24,25]. Previous research examining acetabular wear location and degree of damage has been restricted to prior confirmed hip morphological pathology, typically FAI^[9,24]. While our research examined wear patterns irrespective of surgical indication, previous research that assessed acetabular wear location in individuals with cam impingement identified the predominant location of wear as anterosuperior in the acetabulum^[8,9,24]. While individuals with a pincer impingement exhibit damage that is located in a narrower strip, it is distributed more evenly circumferentially, affecting the anterior, superior, and lateral regions^[8,9,24]. Interestingly our data did not reflect previous research that noted grade 4 acetabular damage frequently extending into superior posterior zones (A Zones: Figure 1)^[11,25], although this observation was specific to individuals with hip dysplasia in one of the studies.

The superior and anterior regions (C & D) were the predominate areas for labral tears identified within our population group. Labral tears were almost non-existent in the posterior inferior region (zone A) with only 5 patients of the 1127 presenting with tears in that zone, representing 0.4%. 965 patients had a labral tear identified on arthroscopy representing 85.6 % of the patients. The regional distribution of labral tears found in our study is consistent with previous literature that also identified the superior and anterior regions of the labrum to be most susceptible to injury^[8,26-28]. Of the 965 patients, 931 (96.5%) had associated acetabular chondral and or femoral head damage. This is in keeping with previous research which has noted a “a high association between labral lesions and adjacent acetabular chondral damage, which is in support of the notion that labral lesions and degenerative pathology of the hip joint represent a continuum”^[18].

Damage to the femoral head was generally limited to grade 1 [469 (41.6%)] and grade 2 [223 (19.8%)] (Table 2). The distribution of wear was fairly evenly represented across the femoral head articular cartilage with a slight majority of the wear presenting in location C (Table 2). These findings were consistent with our hypothesis that the anterolateral aspect of the femoral head would be subject to more articular cartilage wear. Similarly Fontana et al also found that wear patterns in a population of 359 patients also predominated in location C on the femoral head articular cartilage^[25].

Limitations

Multiple geographical methods for describing acetabular and femoral

articular cartilage damage exist in the literature. The authors decided to use the location description described by Fontana et al^[25] due to its superior representation of the central acetabular zone which is not as well represented by other geographical methods^[29]. However, no research has examined the reliability of this method compared to other methods in use. Level of damage was assessed using the classification system described by Beck et al^[9]. While this method of assessing damage has been used extensively in the literature with 1831 citations to date, it was based on findings during hip dislocation procedure not arthroscopy. Although comparison studies have found fair intraobserver and interobserver reliability for the Beck classification (average Cohen k 0.33 and 0.65 respectively)^[30].

REFERENCES

1. Standring S, Ellis H, Healy J, Johnson D, Williams A, Collins P, Wigley C. Gray's anatomy: the anatomical basis of clinical practice. *American journal of neuroradiology* 2005;26(10):2703. [PMID: 25887376]; [DOI: 10.1016/j.arthro.2015.02.029]
2. Blom A, Warwick D, Whitehouse M. Apley & solomon's system of orthopaedics and trauma: CRC Press 2017.
3. Ferguson S, Bryant JT, Ganz R, Ito K. An in vitro investigation of the acetabular labral seal in hip joint mechanics. *Journal of biomechanics* 2003;36(2):171-78. [PMID: 12547354]; [DOI: 10.1016/s0021-9290(02)00365-2]
4. Cadet ER, Chan AK, Vorys GC, Gardner T, Yin B. Investigation of the preservation of the fluid seal effect in the repaired, partially resected, and reconstructed acetabular labrum in a cadaveric hip model. *The American journal of sports medicine* 2012;40(10):2218-23. [PMID: 22962293]; [DOI: 10.1177/0363546512457645]
5. Safran MR, Giordano G, Lindsey DP, Gold GE, Rosenberg J, Zaffagnini S, Giori NJ. Strains across the acetabular labrum during hip motion: a cadaveric model. *The American journal of sports medicine* 2011;39(1_suppl):92-102. [PMID: 21709038]; [DOI: 10.1177/0363546511414017]
6. Song Y, Ito H, Kourtis L, Safran MR, Carter DR, Giori NJ. Articular cartilage friction increases in hip joints after the removal of acetabular labrum. *Journal of biomechanics* 2012;45(3):524-30. [PMID: 22176711]; [DOI: 10.1016/j.jbiomech.2011.11.044]
7. Lespasio MJ, Sultan AA, Piuze NS, Khlopas A, Husni ME, Muschler GF, Mont MA. Hip osteoarthritis: a primer. *The Permanente Journal* 2018;22. [PMID: 29309269]; [DOI: 10.7812/TPP/17-084]
8. Noguchi Y, Miura H, Takasugi S-i, Iwamoto Y. Cartilage and labrum degeneration in the dysplastic hip generally originates in the anterosuperior weight-bearing area: an arthroscopic observation. *Arthroscopy: The Journal of Arthroscopic & Related Surgery* 1999;15(5):496-506. [PMID: 10424553]; [DOI: 10.1053/ar.1999.v15.015049]
9. Beck M, Kalhor M, Leunig M, Ganz R. Hip morphology influences the pattern of damage to the acetabular cartilage: femoroacetabular impingement as a cause of early osteoarthritis of the hip. *The Journal of bone and joint surgery British volume* 2005;87(7):1012-18. [PMID: 15972923]; [DOI: 10.1302/0301-620X.87B7.15203]
10. Bowman Jr KF, Fox J, Sekiya JK. A clinically relevant review of hip biomechanics. *Arthroscopy: The Journal of Arthroscopic & Related Surgery* 2010;26(8):1118-29. [PMID: 20678712]; [DOI: 10.1016/j.arthro.2010.01.027]
11. Kaya M, Suzuki T, Emori M, Yamashita T. Hip morphology influences the pattern of articular cartilage damage. *Knee Surgery, Sports Traumatology, Arthroscopy* 2016;24(6). [PMID: 25331654]; [DOI: 10.1007/s00167-014-3297-6]
12. Khanna V, Harris A, Farrokhhyar F, Choudur HN, Wong IH. Hip arthroscopy: prevalence of intra-articular pathological findings after traumatic injury of the hip. *Arthroscopy: The Journal*

- of Arthroscopic & Related Surgery* 2014;30(3):299-304. [PMID: 24581254]; [DOI: 10.1016/j.arthro.2013.11.027]
13. Lievense A, Bierma-Zeinstra S, Verhagen A, Van Baar M, Verhaar J, Koes B. Influence of obesity on the development of osteoarthritis of the hip: a systematic review. *Rheumatology* 2002;41(10):1155-62. [PMID: 12364636]; [DOI: 10.1093/rheumatology/41.10.1155]
 14. Harris W, Bourne R, Oh I. Intra-articular acetabular labrum: a possible etiological factor in certain cases of osteoarthritis of the hip. *JBJS* 1979;61(4):510-14. [PMID: 438237]
 15. Manning C, Hudson Z. Comparison of hip joint range of motion in professional youth and senior team footballers with age-matched controls: an indication of early degenerative change? *Physical Therapy in Sport* 2009;10(1):25-29. [PMID: 19218076]; [DOI: 10.1016/j.ptsp.2008.11.005]
 16. Leibold MR, Huijbregts PA, Jensen R. Concurrent criterion-related validity of physical examination tests for hip labral lesions: a systematic review. *Journal of Manual & Manipulative Therapy* 2008;16(2):24E-41E. [PMID: 19119387]; [DOI: 10.1179/jmt.2008.16.2.24E]
 17. Brukner P. *Brukner & Khan's clinical sports medicine*: McGraw-Hill North Ryde 2012.
 18. McCarthy JC, Noble PC, Schuck MR, Wright J, Lee J. The watershed labral lesion: its relationship to early arthritis of the hip. *The Journal of arthroplasty* 2001;16(8):81-87. [PMID: 11742456]; [DOI: 10.1054/arth.2001.28370]
 19. Ganz R, Parvizi J, Beck M, Leunig M, Nötzli H, Siebenrock KA. Femoroacetabular impingement: a cause for osteoarthritis of the hip. *Clinical Orthopaedics and Related Research* 2003;417:112-20. [PMID: 14646708]; [DOI: 10.1097/01.blo.0000096804.78689.c2]
 20. Parvizi J, Bican O, Bender B, Mortazavi SJ, Purtill JJ, Erickson J, Peters C. Arthroscopy for labral tears in patients with developmental dysplasia of the hip: a cautionary note. *The Journal of arthroplasty* 2009;24(6):110-13. [PMID: 19596542]; [DOI: 10.1016/j.arth.2009.05.021]
 21. Kemp JL, Collins NJ, Makdissi M, Schache AG, Machotka Z, Crossley K. Hip arthroscopy for intra-articular pathology: a systematic review of outcomes with and without femoral osteoplasty. *British journal of sports medicine* 2012;46(9):632-43. [PMID: 22194221]; [DOI: 10.1136/bjsports-2011-090428]
 22. Marin-Peña O, Tey-Pons M, Perez-Carro L, Said HG, Sierra P, Dantas P, Villar RN. The current situation in hip arthroscopy. *EFORT Open Reviews* 2017;2(3):58-65. [PMID: 28507776]; [DOI: 10.1302/2058-5241.2.150041]
 23. Ross JR, Larson CM, Bedi A. Indications for hip arthroscopy. *Sports Health* 2017;9(5):402-13. [PMID: 28678628]; [DOI: 10.1177/1941738117712675]
 24. Pascual-Garrido C, Li DJ, Grammatopoulos G, Yanik EL, Clohisy JC, Group A. The pattern of acetabular cartilage wear is hip morphology-dependent and patient demographic-dependent. *Clinical Orthopaedics and Related Research* 2019;477(5):1021-33. [PMID: 30998630]; [DOI: 10.1097/CORR.0000000000000649]
 25. Fontana A, Mancini D, Gironi A, Acerbi A. Hip osteochondral lesions: arthroscopic evaluation. *Hip International* 2016;26(1_suppl):S17-S22. [PMID: 27174061]; [DOI: 10.5301/hipint.5000406]
 26. Lewis CL, Sahrman SA. Acetabular labral tears. *Physical therapy* 2006;86(1):110-21. [PMID: 16386066]; [DOI: 10.1093/ptj/86.1.110]
 27. Narvani A, Tsiridis E, Tai C, Thomas P. Acetabular labrum and its tears. *British journal of sports medicine* 2003;37(3):207-11. [PMID: 12782544]; [DOI: 10.1136/bjism.37.3.207]
 28. Farjo LA, Glick JM, Sampson TG. Hip arthroscopy for acetabular labral tears. *Arthroscopy: The Journal of Arthroscopic & Related Surgery* 1999;15(2):132-37. [PMID: 10210068]; [DOI: 10.1053/ar.1999.v15.015013]
 29. Ilizaliturri Jr VM, Byrd JT, Sampson TG, Guanche CA, Philippon MJ, Kelly BT, Dienst M, Mardones R, Shonnard P, Larson CM. A geographic zone method to describe intra-articular pathology in hip arthroscopy: cadaveric study and preliminary report. *Arthroscopy: The Journal of Arthroscopic & Related Surgery* 2008;24(5):534-39. [PMID: 18442685]; [DOI: 10.1016/j.arthro.2007.11.019]
 30. Amenabar T, Piriz J, Mella C, Hetaimish BM, O'Donnell J. Reliability of 3 different arthroscopic classifications for chondral damage of the acetabulum. *Arthroscopy: The Journal of Arthroscopic & Related Surgery* 2015;31(8):1492-96. [PMID: 25887376]; [DOI: 10.1016/j.arthro.2015.02.029]