

Results of Clubfoot Treatment with Kite Method

Arben Gjonej, Risida Gjonej, Edvin Selmani, Gert Çausi

Arben Gjonej, Edvin Selmani, Gert Çausi, Service of Orthopaedic and Traumatology, University Hospital Center "Mother Theresa" Tirana, Albania

Risida Gjonej, Technical Medical Sciences Faculty, Tiranë, Albania
Correspondence to: Arben Gjonej, Service of Orthopaedic and Traumatology, University Hospital Center "Mother Theresa" Tirana, Albania

Email: arben_gjonej@hotmail.it

Telephone: +355682235341

Received: June 25, 2014

Revised: August 12, 2014

Accepted: August 18, 2014

Published online: September 29, 2014

ABSTRACT

AIM: The goal of this study is to evaluate the success of clubfoot treatment by Kite method regarding the relaps rate and need for open surgical correction.

METHODS: We have studied clinical charts of 2008-2010 from statistic department of Service of Orthopaedic and Traumatology "Prof Dr. Panajot Boga". The statistical method used is the Fisher-Student test. Accepted error is less than 5% ($p < 0.05$). Kite Method consists in conservative treatment with cast by gradual gentle manipulation. Intervention performed every 7-14 days. Treatment duration is approximately 6 months and at the end of the first 3 months of treatment, Achilles tenotomy was performed. Then we applied for 3 more months in plaster cast by changing it every 2-3 weeks. When treatment ends, family members were taught about exercises for foot and keeping Denis Brown shoes. In our country the ratio male: female was 1.7:1.

RESULTS: This study included 107 patients, of whom 68 were males and 39 females. Seventy four per cent of patients did not need surgery and others had need for surgical intervention. The success of the method used in our service proved to be 74%. Fourteen per cent of patients started treatment within 7 days of life and success has been 95%, 30% started treatment within 15 to 30 days, 14.9% have started treatment within the first 2-3 months after birth. While the rest of the treatment started 8-14 and 1-2 months after birth.

CONCLUSION: Kite method had a low success rate in our serie of clubfoot patients, so we do not recommend any more the use of this method for conservative treatment of clubfoot.

© 2014 ACT. All rights reserved.

Key words: Congenital clubfoot; Kite method; Ponseti method; Cast treatment

Gjonej A, Gjonej R, Selmani E, Çausi G. Results of Clubfoot Treatment with Kite Method. *International Journal of Orthopaedics* 2014; 1(3): 116-119 Available from: URL: <http://www.ghrnet.org/index.php/ijo/article/view/716>

INTRODUCTION

Congenital Clubfoot is the second most common congenital deformity in orthopedics after the congenital hip dysplasia, with an incidence ranging from 0.6 to 6.8 per 1,000 live births^[1-4] (Figure 1). Ethiological factors suspected for this malformation are: abnormal positioning of the fetus, toxins, temperature, infectious pathogens, medication, electromagnetic radiation but also genetic factors including: chromosomal abnormalities, genes associated with sex, single dominant genes, recessive genes^[5-7]. The latest Japanese theory indicates that the cause is a neuromuscular dysfunction, in



Figure 1 Congenital Clubfoot.

which there is a partial loss of intrauterine innervations and later recovered^[8-10]. To explain the etiology of this deformation born, are also made other studies-microscopic histological^[11,12]. There is also a theory which connects infectious etiology of clubfoot, with enterovirus infections in the period after conception. This theory is supported by several studies that have found a link to seasonality, with the incidence of clubfoot^[13,14]. So, many children with pesequinovarus, born in March-April period, which corresponds to the period of conception in June-July, where the incidence of enterovirus infections is higher.

Three main methods of conservative treatments described in literature are: Kite method, Ponseti Method, French Method. In our Country when it was established the treatment of this pathology by Prof Dr. Panajot Boga was used gradual gentle manipulation and correction according to Kite method. This anomaly consists distortion of the foot with four components: forefoot adduction and supination and heel varus and equinus. Often the cavus element can be added^[15-17].

The difference between the Kite and Ponseti method is the point of counterpressure. In the Kite method the point of counterpressure is the calcaneocuboid joint and in the Ponseti Method is the talar neck^[18]. Also another difference is that in the Ponseti method the first immobilization of the foot is in supination instead of Kite method which immobilizes the foot in pronation. We are evaluating the results of the Kite method as it is the only existing method of clubfoot treatment in our Institution for more than thirty years. The Ponseti one has just been starting its use in our Hospital and we will publish soon the comparative results between this two method^[19].

METHODS

We have studied clinical charts of clubfoot patients treated with Kite method during years 2008-2010 from statistic department of Service of Orthopaedic and Traumatology. This study is only for congenital clubfoot pathology and not those children with spastic or paralytic clubfoot. The average age of onset of treatment is 61 days and shows a late start treatment. The statistical method used is the Fisher-Student test. Accepted error is less than 5% ($p < 0.05$).

RESULTS

This study included 107 patients, of whom 68 were males and 39 females. Seventy four of patients did not need surgery and others had need for surgical intervention. In our country the ratio male: female was 1.7:1. This ratio approximates the international report, reported in the literature of 2:1 in favor of males (Figure 2, 3, 4 and 5).

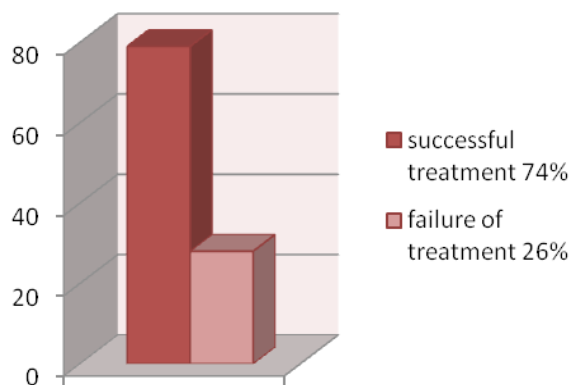


Figure 2 The graph refers to the success treatment of Kite method 2008-2010.

	2008	2009	2010	Total
Patient	34	32	41	107

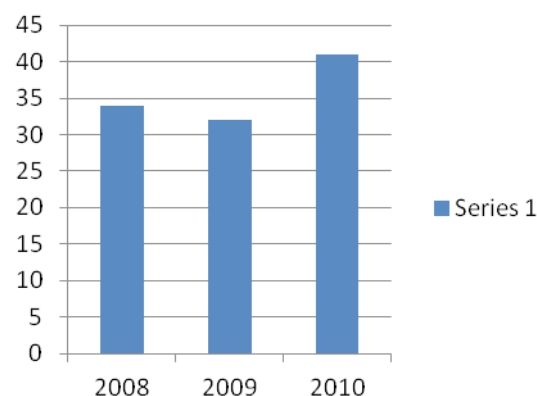


Figure 3 In the period 2008-2010 the total number of patients included in the study is 107.

	2008	2009	2010
Male	21	23	24
Female	13	9	17
Total	34	32	41

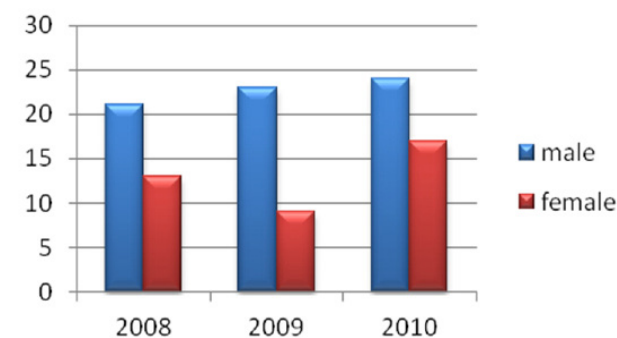


Figure 4 The graph refers to the male/female ratio.

beginning treatment	< 7 days	8-14 days	15-30 days	1-2 months	2-3 months
N=treated patients	15	25	32	19	16
N=success treated patients	14	21	25	10	6

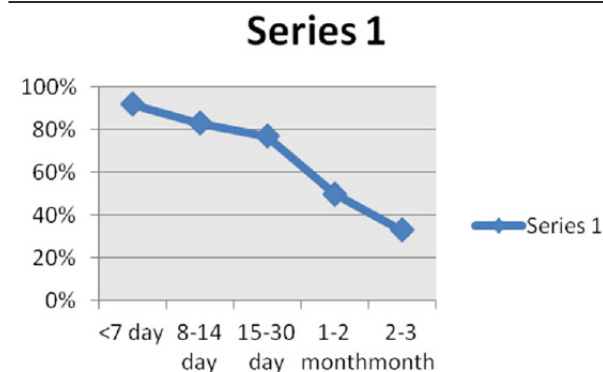


Figure 5 The percentage of success depending on the time of onset of treatment.

DISCUSSIONS

Clubfoot is a congenital pathology that occurs approximately 40 new cases each year are treated in our University Orthopedics,

Traumatology Service. Treatment of this deformation is still a challenge for the physician and cast technician, due to multiple recurrence.

Since the early 60s, when Prof. Panajot Boga codified the conservative treatment of this pathology with Kite method and in our service we have applied only his method. This method consists in conservative treatment with cast by gradual gentle manipulation. Manipulation performed every 7-14 days^[20]. Cast is placed below the knee in the first 2-3 sessions. Then made passage of cast over the knee for avoiding the cast scrolland correct the internal tibial torsion (Figure 6).

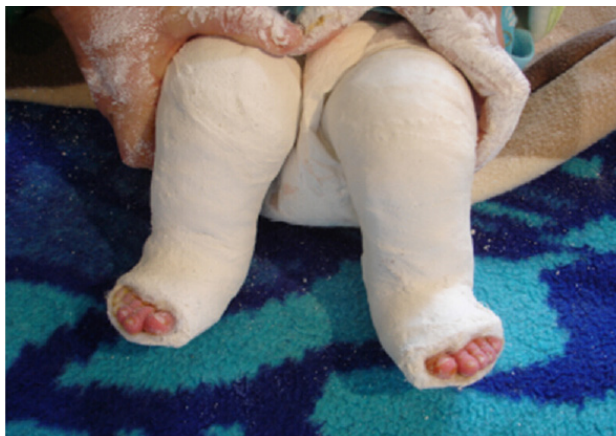

Figure 6 The photo show the treatment with cast over the knee.

Cast surfing damages the work achieved. Treatment duration is approximately 6 months and at the end of the first 3 months of treatment, Achilles tenotomy was performed (Figure 7).

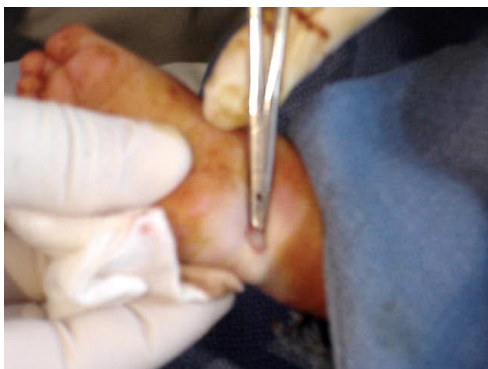

Figure 7 Achilles tenotomy.

Then again placed for 3 months in plaster by changing it every 2-3 weeks. When treatment ends, family members were taught about exercises foot and keeping Denis Brown shoes. These shoes are recommended to be kept for a period of 3 months day and night, except when applied physiotherapy^[21-24]. Then held only at bedtime (Figure 8 and 9).

CONFLICT OF INTERESTS

There are no conflicts of interest with regard to the present study.

REFERENCES

1 Barker S, Chesney D, Miedzybrodzka Z, Maffuli N: Genetics and epidemiology of idiopathic talipes equinovarus. *J Pediat Orthop* 2003; **23**: 265-272

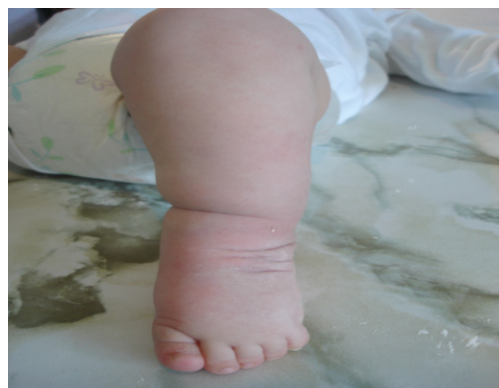

Figure 8 The result after treatment (6 months old).

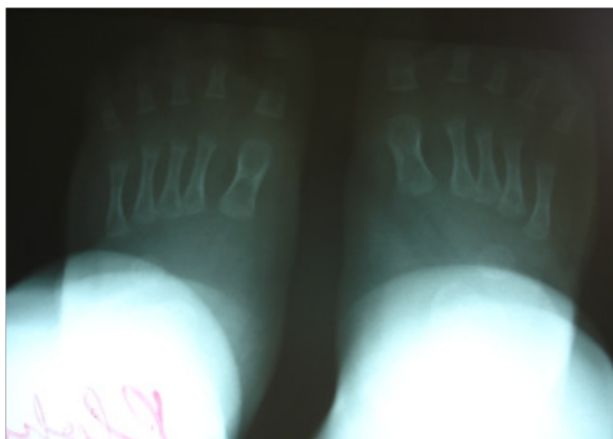

Figure 9 X-ray result after treatment.

2 Cartlidge IL. Clubfoot in the Polynesians:an epidemiological survey. *N Z Med J* 1983; **96**: 515-517

3 Dimeglio A, Bonnet F, Mazeau P, De Rosa V: Orthopaedic treatment and passive motion machine: consequences for the surgical treatment of clubfoot. *J Pediat Orthop B* 1996; **5**: 173-180

4 Cooper DM, Dietz FR: Treatment of idiopathic clubfoot.A thirty-year follow-up. *J Bone Joint Surg* 1995; **77-A**: 1477-1489

5 Delgado MR, Eilson H, Johnston C, Richards S, Karol L: A preliminary report of the use of botulinum toxin A in infants with clubfoot: four case studies. *J Pediatric Orthopaedics* 2000; **20**: 533-538

6 Lovell W, Price CT, Meehan PL. The foot, in Lovell W, Winter RB (eds): *Pediatric Orthopaedics*, ed 2. Philadelphia PA: Lippincott, 1986, pp 895-978

7 Kite JH. The treatment of congenital clubfoot. *JAMA* 1932; **99**:1156

8 Dobbs MB, Rudzky JR, Purcell DB, Walton T, Porter KR, Gurnett CA Factors predictive of outcome after use of the Ponseti method for the treatment of the idiopathic clubfeet. *J Bone Joint Surgery Am* 2004 Jan; **86-A(1)**: 22-7

9 Cummings RJ, Davidson RS, Armstrong PF, Lehman EB: Congenital Clubfoot. Instructional Course Lecture JBJS(A) Volume 84-A Number 2, 2002

10 Ippolito E, Fraracci L, Farsetti P, Di Mario M, Caterini R. The influence of treatment on the pathology of clubfoot:CT study at maturity. *JBJS British* 2004; Volume 86-B Number 4

11 Ippolito E, Farsetti P, Caterini R. Tudisco C. Long-term comparative results in patients with congenital clubfoot treated with two different protocols. *J Bone Joint Surg* 2003; **85-A**: 1286-1294

12 Jaffurs D, Evans CH. The human genome project.Implications for the treatment of musculoskeletal disease. *J Am Acad Orthop Surg* 1998; **6**: 1-14

13 Bensahel H, Guillaume A, Czukonyi Z, Desgrappes Y. Results of

- physical therapy for idiopathic clubfoot: A long term follow-up study. *J Pediatric Orthop* 1990; **21**: 137-141
- 14 Herzenberg JE, Radler C, Bor N.: Ponseti versus traditional methods of casting for idiopathic clubfoot. *J Ped Orthop* 2002; **22**: 517-521
 - 15 Dimeglio A. Abstract: Orthopaedic treatment and passive motion machine in clubfoot. Pediatric Orthopaedic Society of North America 2000 Annual Meeting. Rosemont IL. 2000 p. 47
 - 16 Dimeglio A, Bensahel H, Souchet P, Mazeau P, Bonnet F. Classification of Clubfoot, *J Pediatric Orthopaedic B* 1995; **4**: 129. 2004; 86-A:22-27
 - 17 Diepstraten AdF M. Congenital clubfoot: Hoë I do it. *Acta Orthop Scand* 1996; **67**: 312
 - 18 James LM. Maps of birth defect occurrence in the U.S. Birth defects monitoring program 1970-1987. *Teratology* 1993; **48**: 551-646
 - 19 Johnston W, Richards BS. Nonoperative treatment of clubfoot-the French technique. In Proceedings of Pediatric Orthopaedic of North America Annual meeting
 - 20 Boga P. Disa probleme te trajimit te Luksacionit Koksofemoral Kongenital dhe Pes Equinovarus ne vendin tonë. *Punime Kirurgjike* 1977 f. 117-123.
 - 21 Guerin M. Division of the tendon Achilles in clubfoot. *Lancet* 1935; **2**: 648,1999: May 15-19 ; Lake Buena Vista Florida p.25.
 - 22 Lovell W, Bailey T, Price CT, Purvis JM: The nonoperative management of the congenital clubfoot. *Orthop Rev* 1979; **8**: 113-115
 - 23 Macnicol MF. The management of clubfoot: Issues for debate. *JBJS British* 2003; Volume 85-B, Number 2, 167-170.
 - 24 Morcuende JA, Dolan LA, Dietz FR, Ponseti IV. Radical reduction in the rate of extensive corrective surgery for clubfoot using the Ponseti method. *Pediatrics* 2004; **113**: 376-380
- Peer reviewer:** Ndubuisi O.C. Onyemaechi, MD, Department Of Surgery, University Of Nigeria Teaching Hospital, Ituku-Ozalla, Enugu 400001, Nigeria.