

## Bone Scintigraphy in the Diagnosis of Lisfranc Fracture

Abdelhamid Elgazzar, MD, Abdelmonem Omar, MD, Mahmoud Al Feeli, MD, Azuwuiké Owunwanne, PhD, Amjad Al-Sayad, BSc

Abdelhamid Elgazzar, Azuwuiké Owunwanne, Department of Nuclear Medicine, Faculty of Medicine, Kuwait University, Kuwait  
Abdelmonem Omar, Mahmoud Al Feeli, Amjad Al-Sayad, Mubarak Al-Kabeer Hospital, Ministry of health, Kuwait  
Correspondence to: Abdelhamid H Elgazzar, MD, FCAP, Department of Nuclear Medicine, Faculty of Medicine, Kuwait University, P.O.Box 24923, Safat, 13110, Kuwait  
Email: [aelgazzar49@hotmail.com](mailto:aelgazzar49@hotmail.com)

Telephone: +965-2533-9836 Fax: +965-2533-9836  
Received: September 28, 2014 Revised: November 26, 2014  
Accepted: November 30, 2014  
Published online: December 23, 2014

### ABSTRACT

**AIM:** Lisfranc injuries are uncommon and difficult to diagnose. These injuries have a high potential for causing substantial disability related to post-traumatic osteoarthritis and should be managed early to avoid such complications. Lisfranc injuries are frequently missed on radiographs. Hence, bone scanning may be a useful modality in the diagnosis of Lisfranc fracture. To investigate the utility of bone scintigraphy in the diagnosis of radiographically undiagnosed cases of Lisfranc fracture.

**METHODS:** We studied Thirteen (13) cases of Lisfranc fracture (8 females and 5males), were included in this study. Each patient was intravenously administered 20 mCi (740 MBq) of Tc-99m MDP and three-phase bone scintigraphy was performed using a dual-head gamma camera, interfaced with computer. Whole body blood pool and delayed images were obtained as well as flow, blood pool and delayed images of the feet.

**RESULTS:** All the bone scintigraphic studies of the patients showed hyperemia of the affected foot in flow and blood pool studies and focal area of increased uptake at the mid foot region, particularly the tarsometatarsal joint in the delayed images typical of Lisfranc fracture. However, X-ray of affected foot previously obtained were available in 11 patients and were normal in 10 patients, while

suspicious reflex sympathetic dystrophy was reported in one.

**CONCLUSION:** This study showed the the importance of bone scintigraphy in the detection of radiologically occult lisfranc injuries. It also showed essence of being highly aware of the entity of Lisfranc fracture-dislocation when evaluating patients who have mid foot pain, swelling, and its scintigraphic pattern. We recommend that bone scintigraphy should be utilized more when X-ray is not diagnostic of Lisfranc fracture

© 2014 ACT. All rights reserved.

**Key words:** Lisfranc; Bone scintigraphy; Tarsometatarsal; Fracture; Dislocation

Elgazzar A, Omar A, Feeli MA, Owunwanne A, Al-Sayad A. Bone Scintigraphy in the Diagnosis of Lisfranc Fracture. *International Journal of Orthopaedics* 2014; 1(4): 160-163 Available from: URL: <http://www.ghrnet.org/index.php/ijo/article/view/792>

### INTRODUCTION

The tarsometatarsal joint complex, is known as Lisfranc, after Jacques Lisfranc De Saint Martin (1790-1847), a French surgeon in Napoleon army<sup>[1,2]</sup>. The Lisfranc joint is a complex polyarticular system with an intricate anatomic configuration of skeletal and nonskeletal elements and hence the term “ tarsometatarsal joint complex or Lisfranc”<sup>[2,3]</sup>. The skeletal elements are composed of the tarsometatarsal, intertarsal, and intermetatarsal articular joints (Figure 1). While the nonskeletal elements include the articular capsules, the various ligaments, the prolongations of the long plantar ligament (inferior calcaneocuboid ligament), and the tendons and expansions of the tibialis posterior, tibialis anterior, and peroneus longus, which all function to maintain the stability of the tarsometatarsal joints<sup>[2]</sup>.

Injuries to the Lisfranc joint, are uncommon, however, it is the site of the most common fracture-dislocation in the foot. Injuries to this joint occur in 1 per 55,000 individuals each year in the United States and are 2 to 3 times more common in men<sup>[4-5]</sup>.

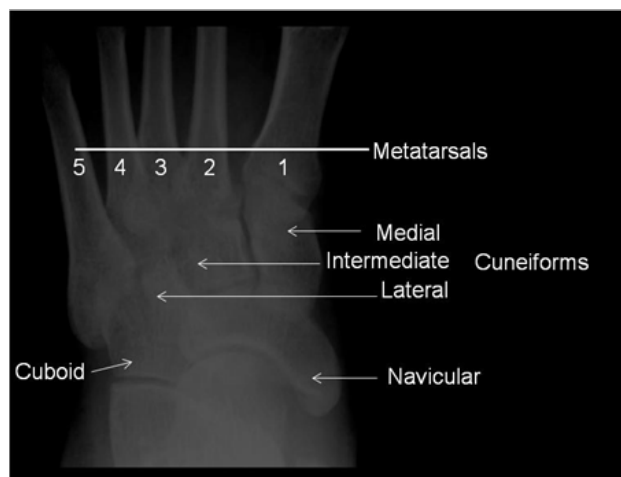
High-energy mechanisms are the more common causes of Lisfranc injury, with motor vehicle accidents accounting for 40 to 45% of the injuries<sup>[5]</sup>. Low-energy injuries, such as those that frequently occur during sports and recreational activities, account for approximately 30%<sup>[5]</sup>. These may initially go undiagnosed.

Fractures associated with Lisfranc injury most often occur at the base of the second metatarsal. They may also be seen in the 3<sup>rd</sup> metatarsal, 1<sup>st</sup> or 2<sup>nd</sup> cuneiform, or navicular bones<sup>[6]</sup>. Patients may present with swelling in the mid-foot, inability to bear weight, tenderness along the tarso-metatarsal joints, tenderness with passive abduction and/or pronation of the forefoot with the hind foot held flexed. The condition can be difficult to diagnose and overall approximately 20% of these injuries are missed or misdiagnosed on initial radiographic assessment<sup>[5]</sup>. The condition has a high potential for causing substantial disability related to post-traumatic osteoarthritis, loss of arch and chronic instability, and pain at the midfoot-forefoot articulation. Therefore, the condition should be diagnosed and be managed early to avoid such complications.

Radiographs including nonweight-bearing anteroposterior (AP), lateral, and 30° oblique views of the foot are the initial images obtained and overall up to 35% of Lisfranc injuries may be misdiagnosed or overlooked<sup>[7]</sup>. Furthermore, 50% of subtle Lisfranc injuries show normal nonweight-bearing images<sup>[8]</sup>. In a recent study the radiographs correctly identified 31 of the 45 cases (69%) of Lisfranc injury with a negative predictive value of 53%<sup>[9]</sup>. A weight-bearing radiograph with both feet on a single cassette or an abduction-pronation stress view has a better accuracy, but these are rarely done because of pain, necessitating a CT scan, bone scan or magnetic resonance imaging<sup>[10]</sup>.

The CT scan is useful if clinical suspicion is high when plain X-rays appear normal<sup>[9]</sup>. Although CT scan is also a better technique than conventional radiography for delineating detail<sup>[11]</sup>, it can also be false negative<sup>[12]</sup>. MRI has been reported to have the highest accuracy in the diagnosis<sup>[13]</sup>, however it is expensive.

Bone scintigraphy is an established useful modality in diagnosing bone disorders but it is underutilized in the diagnosis of Lisfranc fracture. There is very scanty information in the literature on scintigraphic diagnosis of Lisfranc fractures. The objective of this study was to investigate the utility of bone scintigraphy in diagnosis of radiologically occult suspected or incidentally unsuspected cases of Lisfranc fractures.



**Figure 1** Plain film of a normal foot illustrating the structure of the midfoot region, the site of Lisfranc injuries.

## METHODS

Bone scan reports from 2007-2013 were reviewed for “Lisfranc fracture” and 13 patients (aged 31 to 72 years; 8 females and 5 males) were found to have Lisfranc fracture. Images of the scintigraphic studies of all patients were reviewed independently by two observers (put the initials), and when difference of opinion occurred a decision was reached by consensus. Other imaging modalities and medical records were also reviewed. Final diagnosis was also obtained from the medical records.

All patients had either three phase or two phase bone scan because whole body blood pool imaging is acquired as a routine standard image for all bone scintigraphic studies in our laboratory. All the patients had been injected intravenously with 20-25 mCi (740-925 MBq) of Tc99m MDP. Flow studies of the region of interest were obtained followed by blood pool images of the whole body and the regions of interest. Delayed whole body images were obtained 3 to 4 hours post injection followed by spot views of the regions of interest. All cases were imaged using large-field of view, dual-head gamma camera equipped with low energy, high resolution, parallel-hole collimator. The whole body and spot images of the feet were obtained. Flow images were obtained for 3 sec/frame for 60 seconds using 128×128 matrix. Spot blood pool image for the region of interest was acquired for 500 kcounts using 128×128 matrix. Whole body blood pool image was acquired using 256×1024 matrix with speed of 2.2 min/meter. Delayed whole body imaging was performed using 256×1024 matrix with speed of 8min/meter while spot images of the feet were obtained for 300 k using a matrix of 256×526. Energy window of 20% centered at 140 keV was used for all studies.

## RESULT

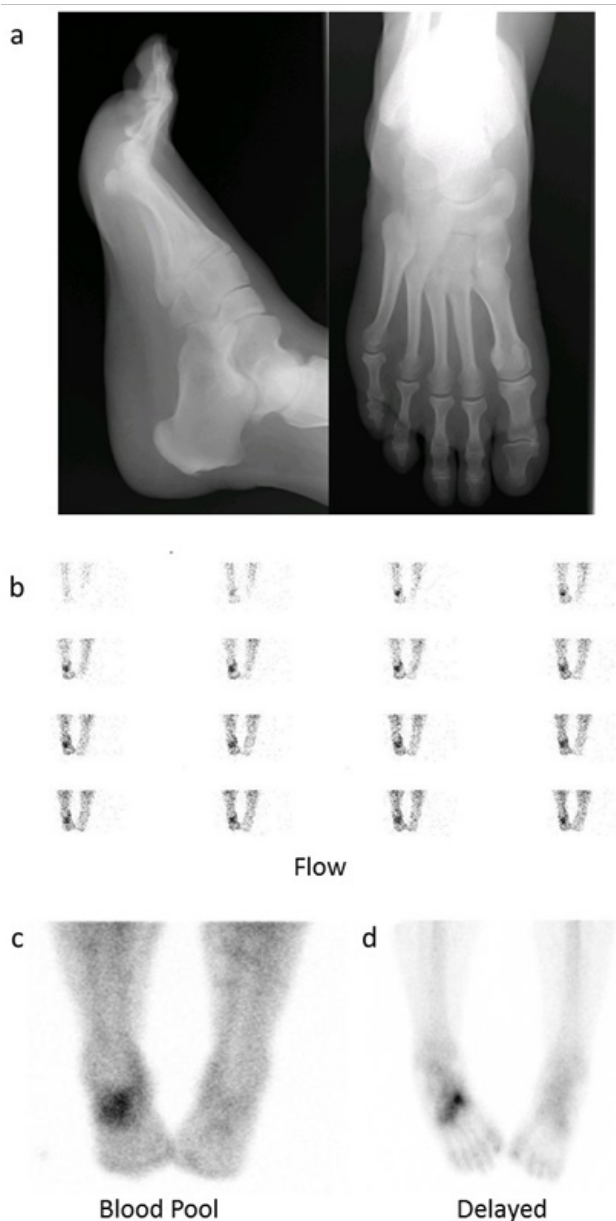
The 13 cases showed the pattern of Lisfranc fracture. Among the 13 cases, 11 were referred for bone scintigraphy for suspected Lisfranc fractures or pain in a foot and two were referred for pain elsewhere other than feet, one in the hip and the other in the knee. The 11 patients referred for foot pain were not diagnosed by radiographs; 10 of them had normal radiographs and one was reported to have suspected reflex sympathetic dystrophy.

All the patients showed increased flow, blood pool and delayed uptake in the region of tarso-metatarsal joints of the affected foot (Figure 2). It was noted that in the two patients who were complaining of pain in an area away from the feet (hip and knee), the site of pain did not correspond to site of the scintigraphic findings which were typical of Lisfranc injury.

## DISCUSSION

Injuries to the tarsometatarsal joint present a challenge as they are difficult to diagnose and outcomes worsen as diagnosis is delayed. Therefore, imaging specialists and clinicians must have a clear understanding of the relevant nomenclature, anatomy, injury mechanisms, and imaging findings<sup>[14]</sup>. Lisfranc injuries were found to be the second most common injury in malpractice litigation against radiologists and emergency physicians<sup>[15]</sup>.

Numerous authors have emphasized the importance of prompt diagnosis in minimizing the risk of long-term complications, such as residual ligamentous instability or posttraumatic degenerative arthritis<sup>[16-18]</sup>. It was shown that poor patient outcomes are associated with a delay in diagnosis of more than 6 months<sup>[19]</sup>. Delays in diagnosis may be related to multiple factors, including a low index of



**Figure 2** Plain X ray (a) of a 63 year old man referred for bone scan due to right foot pain and normal X-ray. Tc99m MDP blood flow (b) blood pool and (c) delayed (d) images show focal hyperemia in the right mid foot corresponding to focally increased delayed uptake in the region of the tarsometatarsal joints predominantly in right second tarsometatarsal joint. The pattern illustrates typical scintigraphic features of Lisfranc injury.

suspicion and distracting injuries in patients with polytrauma<sup>[19-20]</sup>.

Early diagnosis of Lisfranc joint injury is known to be frequently missed<sup>[21-23]</sup> clinically as well as by imaging. Radionuclide bone scintigraphy may show a specific pattern and help in making the diagnosis when the X-rays are normal as shown by our study and reported earlier in a case report<sup>[24]</sup>.

Scintigraphy is not routinely indicated for the diagnosis of Lisfranc fractures but is performed in suspected radiologically occult fractures or the condition is identified incidentally. Typically, acute fracture shows focally increased flow, blood pool activity and delayed uptake. In our study, bone scintigraphy was used successfully in diagnosis of the Lisfranc fractures in the studied 13 patients that were not diagnosed on plain X-ray. In two cases pain was not in the feet. These two cases illustrated the value of obtaining the whole body

blood pool which helped make the diagnosis because if spot view(s) of the painful region alone had been taken, it would not have shown hyperemic changes of the foot. These two cases also identified the referred pain which is common and can be misleading since the metatarso-phalangeal joint injury caused the pain in the hip and knee with no symptoms or signs to suggest the feet problem.

A Lisfranc fracture-dislocation typically occurs in the setting of axial loading of the plantar-flexed foot. Causes of the injuries vary and include direct crush injury or an indirect load onto a plantar flexed foot. Indirect injuries may be associated with high-energy trauma, such as motor vehicle collisions or may result from low-energy or minimal trauma, including leisure activities or elite athletic activity<sup>[25]</sup>. Examples of such minimal trauma include missing a step when coming down stairs or foot entrapment on an automobile brake pedal and a sports injury when the individual falls on the heel of a plantar-flexed foot.

With such injury, stability of the tarsal-metatarsal articulations is disrupted and lateral subluxation of the second through fifth metatarsals ensues. There is usually dorsal subluxation or dislocation of the tarsal-metatarsal joints, which may appear quite subtle on lateral views of radiographs<sup>[26]</sup>. It is this subtle appearance that shows clearly in a bone scintigraphy due to fact that scintigraphy is based on physiology. Apparently disability and deformity may develop even when initial radiographs appear normal<sup>[2]</sup>. Tarsometatarsal dislocation may also occur in the diabetic neuropathic joint.

The dorsoplantar radiograph is often the first radiological examination performed, after initial history and physical examination. Computed tomography is particularly helpful in the delineation of anatomy and identification of small fractures. The strength of magnetic resonance lies in its ability to show isolated ligamentous injury and bone marrow edema<sup>[13,15,27]</sup>. The ultrasound imaging can also be a fast, inexpensive addition to the standard Lisfranc complex injury assessment.

It is important to diagnose and manage these injuries early to avoid complications<sup>[28]</sup>. Weight bearing radiographs and bone scintigrams are sensitive, reproducible, and relatively inexpensive methods of investigation of these injuries<sup>[8]</sup>. Nunley and Vertullo in 2002<sup>[8]</sup> classified subtle Lisfranc injuries into 3 types based on clinical findings, weight-bearing radiographs, and bone scintigraphy of 15 athletes. In stage I injury, there was pain at the Lisfranc complex and increased uptake on bone scan, with negative radiographic findings. In stage II injuries, radiographic diastasis of 1 to 5 mm greater than the contralateral foot was observed, with no loss of midfoot arch height. A stage III injury was classified as diastasis and an associated loss of midfoot arch height.

Our study has illustrated the value of bone scintigraphy in reaching the diagnosis of Lisfranc fracture when radiographs were non-diagnostic. It also showed the value of awareness of the conditions and its scintigraphic pattern by nuclear medicine physician to identify and properly diagnose the condition since it may exist as an incidental finding when pain originating from the condition may be referred to a different site in some cases contributing further to miss the diagnosis of this scintigraphically probably under-diagnosed condition. A limitation of this study was the lack of SPECT/CT, which could have been particularly useful in providing scintigraphic diagnosis as well as anatomic details by the CT component.

The study further illustrated that bone scintigraphy is a sensitive and useful modality for the diagnosis of Lisfranc fracture. It also indicated that bone scintigraphy should be more utilized when X-ray is not diagnostic in mid foot injuries. Physicians should be aware of the value of bone scintigraphy in the diagnosis of Lisfranc fractures

and Nuclear medicine physicians should be highly aware of Lisfranc fracture-dislocation as a possibility when evaluating patients who have mid foot pain and swelling and be familiar with its scintigraphic patterns.

We recommend that bone scintigraphy should be utilized more when X-ray is not diagnostic of Lisfranc fracture to help decrease its under-recognition and misdiagnosis.

## CONFLICT OF INTERESTS

There are no conflicts of interest with regard to the present study.

## REFERENCES

- Hunter TB, Peltier LF, Lund PJ. Radiologic history exhibit. Musculoskeletal eponyms: who are those guys? *Radiographics* 2000; **20**: 819-836
- De Palma L, Santucci A, Sabetta SP, Rapali S. Anatomy of the Lisfranc joint complex. *Foot Ankle Int* 1997; **18**: 356-364
- Chaney DM: The Lisfranc joint. *Clin Podiatr Med Surg* 2010; **27**: 547-560
- Mantas JP, Burks RT. Lisfranc injuries in the athlete. *Clin Sports Med* 1994; **13**: 719-730
- Thompson MC, Mormino MA. Injury to the tarsometatarsal joint complex. *J Am Acad Orthop Surg* 2003; **11(4)**: 260-267
- Greenspan A. Orthopedic imaging, a practical approach. Lippincott Williams & Wilkins. Philadelphia, 2004
- Vuori JP, H.T. Aro HT. Lisfranc joint injuries: trauma mechanisms and associated injuries. *J Trauma* 1993; **35**: 40-45
- Nunley JA, Vertullo CJ. Classification, investigation, and management of midfoot sprains: Lisfranc injuries in the athlete. *Am J Sports Med* 2002; **30**: 871-878
- Rankine JJ, Nicholas CM, Wells G, Barron DA. The diagnostic accuracy of radiographs in Lisfranc injury and the potential value of a craniocaudal projection. *AJR Am J Roentgenol* 2012; **198**: W365-369
- Rosenbaum A, Dellenbaugh S, DiPreta J, Uhl R. Subtle Injuries to the Lisfranc Joint. *Orthopedics* 2011; **34**: 882-887
- Goiney RC, Connell DG, Nichols DM. CT evaluation of tarsometatarsal fracture-dislocation injuries. *AJR Am J Roentgenol* 1985; **144**: 985-990
- Woodward S, Jacobson JA, Femino JE, Morag Y, Fessell DP, Dong Q: Sonographic Evaluation of Lisfranc Ligament Injuries. *J Ultrasound Med* 2009; **28**: 351-357
- Preidler KW, Brossmann J, Daenen B, Goodwin D, Schweitzer M, Resnick D. MR imaging of the tarsometatarsal joint: analysis of injuries in 11 patients. *AJR* 1996; **167**:1217-1222
- Hatem SF. Imaging of lisfranc injury and midfoot sprain. *Radiol Clin North Am* 2008; **46(6)**: 1045-1060
- Gupta RT, Wadhwa RP, Leach TJ, Herwik SM. Lisfranc injury: imaging findings for this important but often missed diagnosis. *Curr Probl Diagn Radiol* 2008; **37**: 115-126
- Philbin T, Rosenberg G, Sferra JJ. Complications of missed or untreated Lisfranc injuries. *Foot Ankle Clin N Am* 2003; **8**: 61-71
- Aronow MS. Treatment of missed Lisfranc injury. *Foot Ankle Clin N Am* 2006; **11**: 127-142
- Hunt SA, Ropiak C, Tejwani NC. Lisfranc joint injuries: diagnosis and treatment. *Am J Orthop* 2006; **35**: 376-385
- Calder JDF, Whitehouse SL, Saxby TS. Results of isolated Lisfranc injuries and the effect of compensation claims. *J Bone Joint Surg Br* 2004; **86**: 527-530
- Sherief TI, Mucci B, Greiss M. Lisfranc injury: how frequently does it get missed? And how can we improve? *Injury* 2007; **38**: 856-860
- Burroughs KE, Reimer CD, Fields KB. Lisfranc injuries of the foot: a commonly missed diagnosis. *American Family Physician* 1998; **58**: 118-124
- Englanoff G, Angelin D, Hutson HR. Lisfranc Fracture –dislocation: a frequently missed diagnosis in the emergency department. *Ann Emerg Med* 1995; **26**: 229-233
- Perron AD, Brady WJ, Keats TE. Orthopedic pitfalls in ED: Lisfranc fracture-dislocation. *Am J Emerg Med* 2001; **19**: 71-75
- D Groshar, M Alpers, D G Mendes, V Barsky, A Liberson: Bone scintigraphy findings in Lisfranc joint injury. *Foot & Ankle International* 1995; **16**: 710-711
- DeOrto M, Erickson M, Usuelli FG, Easley M. Lisfranc injuries in sport. *Foot Ankle Clin* 2009; **14**: 169-186
- Kalia V, Fishman EK, Carrino JA, Fayad LM. Epidemiology, imaging, and treatment of Lisfranc fracture-dislocations revisited. *Skeletal Radiology* 2012; **41**: 129-136
- Castro M, Melão L, Canella C, Weber M, Negrão P, Trudell D and Resnick D: Lisfranc Joint Ligamentous Complex: MRI With Anatomic Correlation in Cadavers, *AJR Am J Roentgenol* 2010; **195(6)**: W447-455
- Buzzard BM, Briggs PJ. Surgical management of acute tarsometatarsal fracture dislocation in the adult. *Clin Orthoped* 1998; **353**: 125-133

**Peer reviewer:** Mohamed El-Sayed Abdel-Wanis, MD, PhD, Prof. of Orthopaedic Surgery, Sohag Faculty of Medicine, Sohag University, International Faculty Member of AOSpine, Member of American Academy of Orthopedic Surgeons (AAOS), Member of Japanese Orthopedic Association (JOA), Member of SICOT, Member of Asia Pacific Orthopedic Association (APOA), Sohag P.O. Number 82524, Egypt.