

Current and Evolving Concepts in Wrist Arthroscopy

Nickolaos A Darlis, MD, PhD, Panagiotis A Givissis, MD, PhD,

Nickolaos A Darlis, Metropolitan Hospital, Ethnaxou Makariou 9 & El.Venizelou 1, 18547, Neo Faliro, Athens, Greece

Panagiotis A.Givissis, Associate Professor of Orthopaedics, 1st Orthopaedic Department of Aristotle University of Thessaloniki, "G. Papanikolaou" Hospital, Thessaloniki, Greece

Correspondence to: Nickolaos A Darlis, MD, PhD, 30, 2as Maiou Street, 17121 Nea Smyrni, Athens, Greece

Email: nickdarlis@gmail.com

Telephone: +30-2109315300

Fax: +30-2109315300

Received: September 3, 2014

Revised: October 15, 2014

Accepted: October 22, 2014

Published online: December 23, 2014

ABSTRACT

Arthroscopy of the wrist and the small joints of the hand is an established surgical technique in the diagnosis and treatment of hand and wrist pathology. The purpose of this review is to highlight recent advances as well as future directions of its use in hand surgery. Current indications include carpal interosseous ligament and triangular fibrocartilage complex lesions, arthritis and selected fractures. As experience with small joint arthroscopy grows, new indications and refined surgical techniques are introduced that address wrist pathology at earlier stages, thus minimizing the need for salvage procedures in hand surgery.

© 2014 ACT. All rights reserved.

Key words: Wrist; Hand; Arthroscopy; Ligaments; Review

Darlis NA, Givissis PA. Current and Evolving Concepts in Wrist Arthroscopy. *International Journal of Orthopaedics* 2014; 1(4): 155-159 Available from: URL: <http://www.ghrnet.org/index.php/ijo/article/view/804>

INTRODUCTION

Arthroscopy of the wrist and the small joints of the hand has gained significant popularity over the past decade due to its minimally

invasive nature. The purpose of this article is to present the current and evolving uses of this technique in hand surgery. A PubMed search with the keywords wrist arthroscopy and hand arthroscopy was performed and scientific articles from the last decade were reviewed. The indications for the procedure are summarized in table 1.

Table 1 Indications for wrist and hand arthroscopy.

Diagnostic
Carpal interosseous ligament lesions (scapholunate, lunotriquetral)
Triangular Fibrocartilage Complex lesions
Fractures (selected distal radius and scaphoid)
Bony Procedures (styloidectomy, proximal hamate pole excision, proximal row carpectomy, partial wrist arthrodesis)
Dorsal wrist ganglion cyst
Septic wrist arthritis
Inflammatory wrist arthritis
Metacarpophalangeal joint lesions (inflammatory, trauma)
Thumb basal joint lesions (arthritis, instability)

DIAGNOSTIC ARTHROSCOPY

Even with advances in imaging techniques there still remains a need for diagnostic arthroscopy of the wrist. Modern 3 Tesla MRI has improved its diagnostic accuracy; however sensitivity remains in the 70-80% region for carpal interosseous ligaments and the triangular fibrocartilage complex (TFCC)^[1] and can be further enhanced with magnetic resonance arthrography. Classic triple arthrograms^[2] are more invasive without improving accuracy and with a significant percentage of false positive results. An important number of patients still present with persistent pain to the wrist, despite conservative treatment and negative or unequivocal imaging studies. When the history, symptoms and clinical examination are consistent with intra-articular pathology there is an indication for diagnostic arthroscopy.

PORTALS

In recent years classic arthroscopic wrist portals (1-2, 3-4, 4-5, 6R, 6U, Radial and Ulnar mid-carpal) have been supplemented by new

portals in order to assess and address specific pathology. The Distal RadioUlnar Joint (DRUJ)^[3] and the ulnar fovea portals^[4] require using a 1.9 mm arthroscope for viewing and are specific to ulnar sided pathology. The volar radial portal^[5] requires a mini open approach through the sheath of the Flexor Carpi Radialis for safety reasons, can assess dorsal ligaments and capsule pathology and is also used in some reconstructive procedures.

CARPAL INTEROSSEOUS LIGAMENTS LESIONS

Current concepts in wrist instability increasingly recognize the significant contribution of extrinsic carpal ligaments in this pathology^[6,7], however, addressing the interosseous (usually Scapholunate (SL) or Lunotriquetral (LT) ligaments) lesion is considered the essential element of treatment^[8]. Wrist arthroscopy is a valuable tool in diagnosing, staging and treatment of these lesions.

SL ligaments lesions are categorized as acute (within 3 months from injury) or chronic and the Geissler^[9] or the Dreant/Dautel^[10] staging systems are usually used. The resultant instability can be dynamic (observed only with loading of the wrist in grip view radiographs) or static^[11].

Acute partial tears of the membranous portion of the SL ligament (Geissler type I) are thought to be amenable to immobilization alone. There may be a biomechanical advantage in immobilizing in supination^[7]. In more extensive lesions involving the dorsal part of the ligament the chances of chronic instability become greater. In such lesions (Geissler type II and III) scapholunate interval stability should be assessed from a midcarpal portal as well. Reduction and temporary pinning of the SL interval is the treatment of choice of these lesions and is supplemented with mechanical debridement or radiofrequency probe thermal shrinkage of the ligament^[12] (Figure 1). However, overzealous use of radiofrequency probes in the wrist is to be avoided^[13]. When a patient presents with gross SL instability (Geissler type IV, positive "drive through" sign) there usually is a complete SL ligament tear and consideration should be given to open repair with suture anchors. There have been reports of arthroscopic assisted complete SL ligament tear repair (either dorsal^[14,15] or volar^[5]) but at this point open repair is considered the gold standard.

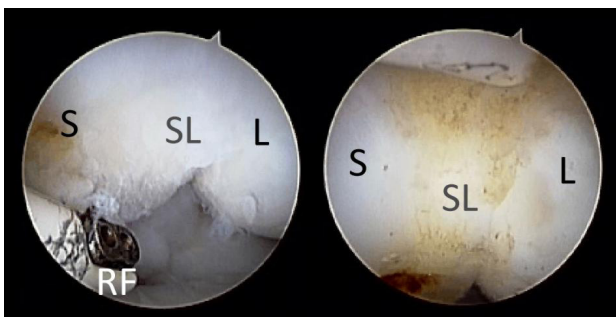

Figure 1 Partial scapholunate (SL) ligament tear before (left) and after (right) debridement and thermal shrinkage with a radiofrequency probe (RF). S: scaphoid; L: lunate.

In chronic SL lesions pronated grip view radiographs are essential to diagnose dynamic instability. Chronic symptomatic partial tears without instability respond well to arthroscopic debridement or thermal shrinkage^[12]. In cases with partial lesions and dynamic instability several open techniques have been described (capsulodesis, tenodesis, partial arthrodesis) with suboptimal results^[8]. Another

option is an aggressive arthroscopic debridement and pinning of the SL interval^[16]. With results with this technique being suboptimal as well, it remains an option for patients that prefer a less invasive treatment. When faced with static instability the aforementioned open techniques are usually utilized. New techniques and modifications of older ones keep appearing in the literature demonstrating the complexity of this problem. The RASL technique involves placing a compression screw between the scaphoid and the lunate and arthroscopic assistance has been reported^[17] with this technique. More recently, an SL tenodesis using an interference screw and arthroscopic assistance (the SLAM procedure) has been reported^[18] but clinical experience is limited.

LT ligament lesions are less common and can be treated with the same principles but the possibility of their being a result of ulnocarpal impingement syndrome must be kept in mind^[8].

TRIANGULAR FIBROCARILAGE COMPLEX (TFCC) LESIONS

The long recognized role of the TFCC in load transmission across the ulnar side of the wrist and distal radioulnar joint (DRUJ) stability^[19] has been revisited in recent years. The main structures responsible for DRUJ stability have been shown to be the Volar and Dorsal Radioulnar Ligaments (VRUL, DRUL) and more importantly the firm attachment of the TFCC to the fovea of the ulnar head^[20]. Nakamura's biomechanical "hammock" paradigm^[19] has evolved into the "iceberg" paradigm^[20] in which the biomechanically important foveal attachment is below the surface of what we can see in classic radiocarpal arthroscopy. Repair of the foveal attachment of the TFCC is considered essential in young active patients.

Similarly, the traditional Palmer classification^[21] has been challenged in recent years by newer classifications^[20,21] which incorporate the new biomechanical concepts and arthroscopic findings. However the basic distinction between type I (traumatic) and type II (degenerative) lesions of the Palmer classification still stands, as the later (degenerative) are frequently observed in ulnocarpal impingement syndrome and consideration must be given to an ulnar recession procedure. A more practical classification approach is based on the location of the tear with central, radial and peripheral (ulnar) tears being described. Ulnar tears can involve tear of the foveal attachment of the TFCC.

Central TFCC lesions are often degenerative and can be treated with arthroscopic debridement of as much as two thirds of the central disc^[22]. In these patients consideration must be given to the coexistence of ulnocarpal impingement (using pronated grip view radiographs and/or MRI). If that diagnosis is established ulnar shortening by a few millimeters must be performed. This can be done in an intrarticular arthroscopic manner (Wafer procedure)^[23] in modest shortenings or extrarticular open using one of several described techniques^[24].

Tears of the radial attachment of the TFCC are uncommon and their treatment remains controversial^[25]. It seems that they should be repaired using transosseous techniques if they involve the insertion of the VRUL or the DRUL and they cause DRUJ instability. All other tears can be debrided.

Peripheral (ulnar) tears usually involve the dorso-ulnar attachment of the TFCC, have adequate vascular perfusion and are considered repairable within an optimal 3 to 6 month time frame from the original injury^[25]. With these lesions it is important to recognize possible detachment of the deep fibers to the ulnar fovea. MRI and arthroscopic findings (positive probe test, arthroscopy of the

undersurface of the TFCC) can be helpful in that respect. If the foveal attachment is intact the tear can be repaired to the capsule using arthroscopic techniques similar to meniscal repair in the knee^[26] (Figure 2). If the foveal attachment is ruptured it must be repaired especially in young active patients. This can be done open using suture anchors^[26]. In recent years arthroscopic assisted^[27,41] or full arthroscopic techniques (Geissler technique^[28] using knotless suture anchors- Figure 3) have gained significant popularity.

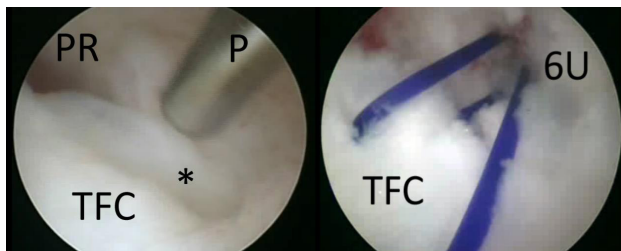


Figure 2 Ulnar triangular fibrocartilage (TFC) tear (star) before (left) and after (right) arthroscopic repair with sutures to the dorsal wrist capsule. PR: prestyloid recess; P: probe; 6U: portal.

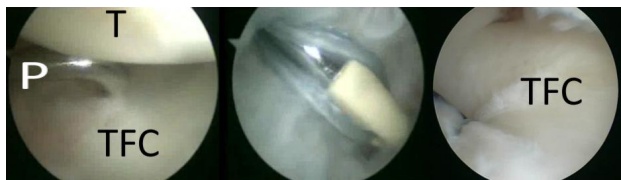

Figure 3 Ulnar triangular fibrocartilage (TFC) tear with detachment from the ulnar fovea. Arthroscopic repair using a knotless suture anchor (middle) and final result (right). P:probe; T:triquetrum.

ARTHROSCOPIC ASSISTANCE IN FRACTURE REDUCTION

Wrist arthroscopy alone or in conjunction with fluoroscopy can be helpfully in accurately reducing selected distal radius (Figure 4) and scaphoid fractures. Arthroscopy is advantageous over fluoroscopy in articular reduction assessment and in diagnosing concomitant chondral and ligamentous lesions^[29,30]. The contribution of these factors to the final functional result, however, seems to be greater for younger patients with high functional requirements^[31].

Arthroscopically assisted reduction of distal radius fractures is usually accompanied by Kirschner wire fixation and/or external fixation. In recent literature there are also reports of wrist arthroscopy

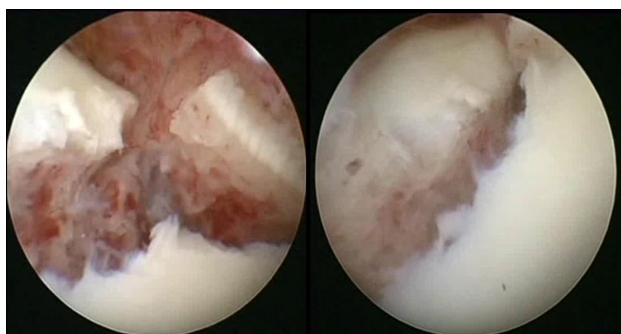


Figure 4 Arthroscopic view of an intrarticular distal radius fracture before (left) and after (right) arthroscopic assisted reduction.

after provisional fixation with locked distal radius plates or after plating in order to assess the quality of the reduction and to diagnose and treat concomitant lesions^[30,32].

Current indications for arthroscopically assisted reduction include radial styloid, die punch and selected three and four part fractures. Other indications include DRUJ instability and suspected wrist interosseous ligament tears. Young age and high functional expectations are taken into consideration as well.

Results of arthroscopically treated fractures are superior to fluoroscopic assistance or classic open reduction in the midterm, however, the impact on long term post traumatic arthritis prevention is still unknown^[33,34].

Percutaneous scaphoid fracture fixation is essentially a fluoroscopically assisted technique. The addition of wrist arthroscopy is beneficial in fracture reduction assessment and concomitant ligamentous lesion treatment^[35].

OTHER INDICATIONS

Arthroscopic lavage is the treatment of choice in septic wrist arthritis^[36]. Arthroscopic synovectomy^[37] and biopsy are helpful in the early stages of inflammatory arthritis of the wrist and fingers. Loose body removal and synovectomy may be used in synovial chondromatosis of the wrist^[38]. Arthroscopic arthrolysis the symptomatic stiff wrist yields significant pain relief but only modest gains in range of motion^[39].

Dorsal wrist ganglia are considered an established indication for arthroscopic treatment. The rate of recurrence was similar to open methods in large published series^[40,41].

Arthroscopy is used for bone procedures as well. Arthroscopic styloidectomy, proximal hamate pole excision^[42] and distal ulnar shortening (wafer procedure^[23]) are widely used. Arthroscopic proximal row carpectomy^[43] and arthroscopic assisted four-bone-fusion^[44] can be time consuming and are performed by experienced surgeons.

Arthroscopy of the fingers is used mostly in the metacarpophalangeal joints and the basal joint of the thumb using 1.9 mm arthroscopes. Synovectomy and biopsy in inflammatory arthritis and arthroscopic assistance in intrarticular fracture fixation are the main indications. In early stages of basal joint arthritis, arthroscopic synovectomy and thermal beak ligament shrinkage is used^[45]. In more advanced stages arthroscopic partial trapeziectomy and interposition arthroplasty^[46] offer an alternative to classic open methods of treatment.

The rate of complications was in the 6% region in large series^[47,48] (including inability to complete the procedure intended). The majority of complications were transient in nature and many were associated with positioning and traction during the procedure.

The expanding role of wrist arthroscopy in recent years has helped us diagnose, classify and treat ligamentous lesions of the wrist and perform a variety of procedures in a minimally invasive manner. As experience with this method grows we will have less need for salvage procedures in wrist pathology.

ACKNOWLEDGMENTS

The authors wish to thank Ms Foteini G. Mane MSc, PhD for proofreading and correcting the manuscript.

CONFLICT OF INTERESTS

There are no conflicts of interest with regard to the present study.

REFERENCES

- 1 Ringler MD. MRI of wrist ligaments. *J Hand Surg* 2013; **38**: 2034-2046
- 2 Smith TO, Drew BT, Toms AP, Chojnowski AJ. The diagnostic accuracy of X-ray arthrography for triangular fibrocartilaginous complex injury: a systematic review and meta-analysis. *J Hand Surg Eur* 2012; **37**: 879-887
- 3 Slutsky DJ. Distal radioulnar joint arthroscopy and the volar ulnar portal. *Tech Hand Up Extrem Surg* 2007; **11**: 38-44
- 4 Atzei A, Rizzo A, Luchetti R, Fairplay T. Arthroscopic foveal repair of triangular fibrocartilage complex peripheral lesion with distal radioulnar joint instability. *Tech Hand Up Extrem Surg* 2008; **12**: 226-235
- 5 Del Piñal F. Arthroscopic volar capsuloligamentous repair. *J Wrist Surg* 2013; **2**: 126-128
- 6 Pappou IP, Basel J, Deal DN. Scapholunate ligament injuries: a review of current concepts. *Hand* 2013; **8**: 146-156
- 7 Salva-Coll G, Garcia-Elias M, Hager E. Scapholunate instability: proprioception and neuromuscular control. *J. Wrist Surg* 2013; **2**: 136-140
- 8 Slutsky DJ, Trevare J. Scapholunate and lunotriquetral injuries: arthroscopic and open management. *Sports Med Arthrosc Rev* 2014; **22**: 12-21
- 9 Geissler WB. [Arthroscopic management of scapholunate instability]. *Chir. Main* 2006; **25**: S187-196
- 10 Dreant N, Dautel G. [Development of a arthroscopic severity score for scapholunate instability]. *Chir. Main* 2003; **22**: 90-94
- 11 Messina JC, Van Overstraeten L, Luchetti R, Fairplay T, Mathoulin, CL. The EWAS Classification of Scapholunate Tears: An Anatomical Arthroscopic Study. *J Wrist Surg* 2013; **2**: 105-109
- 12 Darlis NA, Weiser RW, Sotereanos DG. Partial scapholunate ligament injuries treated with arthroscopic debridement and thermal shrinkage. *J Hand Surg* 2005; **30**: 908-914
- 13 Sotereanos DG, Darlis NA, Kokkalis ZT, Zanos G, Altman GT, Miller MC. Effects of radiofrequency probe application on irrigation fluid temperature in the wrist joint. *J Hand Surg* 2009; **34**: 1832-1837
- 14 Caloia M, Caloia H, Pereira, E. Arthroscopic scapholunate joint reduction. Is an effective treatment for irreparable scapholunate ligament tears? *Clin Orthop* 2012; **470**: 972-978
- 15 Wahegaonkar AL, Mathoulin CL. Arthroscopic dorsal capsuloligamentous repair in the treatment of chronic scapho-lunate ligament tears. *J Wrist Surg* 2013; **2**: 141-148
- 16 Darlis NA, Kaufmann RA, Giannoulis F & Sotereanos DG. Arthroscopic debridement and closed pinning for chronic dynamic scapholunate instability. *J Hand Surg* 2006; **31**: 418-424
- 17 Aviles AJ, Lee SK, Hausman MR. Arthroscopic reduction-association of the scapholunate. *Arthroscopy* 2007; **23**: 105.e1-5
- 18 Lee SK, Zlotolow DA, Sapienza A, Karia R, Yao J. Biomechanical comparison of 3 methods of scapholunate ligament reconstruction. *J Hand Surg* 2014; **39**: 643-650
- 19 Nakamura T, Yabe Y, Horiuchi Y. Functional anatomy of the triangular fibrocartilage complex. *J Hand Surg Br* 1996; **21**: 581-586
- 20 Atzei A, Luchetti R. Foveal TFCC tear classification and treatment. *Hand Clin* 2011; **27**: 263-272
- 21 Palmer AK, Werner FW. The triangular fibrocartilage complex of the wrist--anatomy and function. *J Hand Surg* 1981; **6**: 153-162
- 22 Darlis NA, Weiser RW, Sotereanos DG. Arthroscopic triangular fibrocartilage complex debridement using radiofrequency probes. *J Hand Surg Br* 2005; **30**: 638-642
- 23 Bickel KD. Arthroscopic treatment of ulnar impaction syndrome. *J Hand Surg* 2008; **33**: 1420-1423
- 24 Darlis NA, Ferraz IC, Kaufmann RW, Sotereanos DG. Step-cut distal ulnar-shortening osteotomy. *J Hand Surg* 2005; **30**: 943-948
- 25 Kovachevich R, Elhassan BT. Arthroscopic and open repair of the TFCC. *Hand Clin* 2010; **26**: 485-494
- 26 Chou KH, Sarris IK, Sotereanos DG. Suture anchor repair of ulnar-sided triangular fibrocartilage complex tears. *J Hand Surg Br* 2003; **28**: 546-550
- 27 Nakamura T, Sato K, Okazaki M, Toyama Y, Ikegami H. Repair of foveal detachment of the triangular fibrocartilage complex: open and arthroscopic transosseous techniques. *Hand Clin* 2011; **27**: 281-290
- 28 Geissler WB. Arthroscopic knotless peripheral ulnar-sided TFCC repair. *Hand Clin* 2011; **27**: 273-279
- 29 Catalano LW, Barron OA, Glickel SZ. Assessment of articular displacement of distal radius fractures. *Clin Orthop* 2004; **423**: 79-84
- 30 Lutsky K, Boyer MI, Steffen JA, Goldfarb CA. Arthroscopic assessment of intra-articular distal radius fractures after open reduction and internal fixation from a volar approach. *J Hand Surg* 2008; **33**: 476-484
- 31 Young BT, Rayan GM. Outcome following nonoperative treatment of displaced distal radius fractures in low-demand patients older than 60 years. *J Hand Surg* 2000; **25**: 19-28
- 32 Abe Y, Tsubone T, Tominaga Y. Plate presetting arthroscopic reduction technique for the distal radius fractures. *Tech Hand Up Extrem Surg* 2008; **12**: 136-143
- 33 Ruch DS, Valle J, Poehling GG, Smith BP, Kuzma GR. Arthroscopic reduction versus fluoroscopic reduction in the management of intra-articular distal radius fractures. *Arthroscopy* 2004; **20**: 225-230
- 34 Khanchandani P, Badia A. Functional outcome of arthroscopic assisted fixation of distal radius fractures. *Indian J Orthop* 2013; **47**: 288-294
- 35 Slutsky DJ, Trevare J. Use of arthroscopy for the treatment of scaphoid fractures. *Hand Clin* 2014; **30**: 91-103
- 36 Sammer DM, Shin AY. Arthroscopic management of septic arthritis of the wrist. *Hand Clin* 2011; **27**: 331-334
- 37 Adolfsson L. Arthroscopic synovectomy of the wrist. *Hand Clin* 2011; **27**: 395-399
- 38 Reverté Vinaixa MM, Singh R, Monyart JM, Llado GD, Dominguez MP, Feliu EC, Nardi Vilardaga J, Palou EC. Wrist synovial chondromatosis: case report and literature review. *Hand Surg* 2012; **17**: 233-238
- 39 Luchetti R, Atzei A, Fairplay T. Arthroscopic wrist arthrolysis after wrist fracture. *Arthroscopy* 2007; **23**: 255-260
- 40 Gallego S, Mathoulin C. Arthroscopic resection of dorsal wrist ganglia: 114 cases with minimum follow-up of 2 years. *Arthroscopy* 2010; **26**: 1675-1682
- 41 Kim JP, Seo JB, Park HG, Park YH. Arthroscopic excision of dorsal wrist ganglion: factors related to recurrence and postoperative residual pain. *Arthroscopy* 2011; **29**: 1019-1024
- 42 Yao J, Osterman AL. Arthroscopic techniques for wrist arthritis (radial styloidectomy and proximal pole hamate excisions). *Hand Clin* 2005; **21**: 519-526
- 43 Weiss ND, Molina RA, Gwin S. Arthroscopic proximal row carpectomy. *J Hand Surg* 2011; **36**: 577-582
- 44 Del Piñal F, Klausmeyer M, Thams C, Moraleda E, Galindo C. Early experience with (dry) arthroscopic 4-corner arthrodesis: from a 4-hour operation to a tourniquet time. *J Hand Surg* 2011; **37**: 2389-2399
- 45 Slutsky DJ. The role of arthroscopy in trapeziometacarpal arthritis. *Clin Orthop* 2014; **472**: 1173-1183
- 46 Badia A. Arthroscopic indications and technique for artemon interposition arthroplasty of the thumb trapeziometacarpal joint. *Tech Hand Up Extrem Surg* 2008; **12**: 236-241
- 47 Ahsan ZS, Yao J. Complications of wrist arthroscopy. *Arthroscopy*

2012; **28**: 855-859

- 48 Roue P, Fontes D. [Complication and prevention of upper limb joints arthroscopy]. *Chir Main* 2006; **25**: S274-S279

Peer reviewer: Omar Faour Martín, Hospital Complex Of Ávila-Sacyl, Department Of Orthopaedic Surgery And Traumatology. C/ Avda. Juan Carlos I, S/N. Postal Code: 05004, Spain.

