

Functional Results after Transfer of the Pectoralis Major Muscle in Subscapularis Tears: A literature review

Gabriel da Cunha Mendes, Christiane Veratti Petrucci, Renan Lima Monteiro

Gabriel da Cunha Mendes, Christiane Veratti Petrucci, Renan Lima Monteiro, Irmandade da Santa Casa de Misericórdia, Rehabilitation Service, São Paulo, SP, Brazil

Renan Lima Monteiro, Federal University of Amapá, Macapá, AP, Brazil

Correspondence to: Gabriel da Cunha Mendes, Irmandade da Santa Casa de Misericórdia, Rehabilitation Service, Santa Casa de Misericórdia de São Paulo (SCMSP), Street Doutor Cesário Mota Junior, number 112, SP 01201-000, São Paulo, Brazil.

Email: gabrielcunha_2@hotmail.com

Telephone: +55-11-2176-1585 Fax: +55-11-2176-1585

Received: May 8, 2014 Revised: July 4, 2014

Accepted: July 9, 2014

Published online: August 23, 2014

ABSTRACT

AIM: The aim of the study was to investigate through a literature review functional outcomes after transfer of the pectoralis major muscle in irreparable tears of the subscapularis muscle.

METHODS: A systematic search was performed in electronic databases (Science Direct and Pubmed), which were reviewed only for studies who described functional results after muscle transfer. During the, based on retrospective facts, were pre-selected 455 articles and five of them met all criteria and specifications set.

RESULTS: There was an increase in range of motion in elevation, abduction and improved function

CONCLUSION: The transfer of the pectoralis major muscle in irreparable tears of the subscapularis muscle seems to be an treatment option to improve function, however, more studies with better methodological quality with emphasis on functional outcomes are needed.

© 2014 ACT. All rights reserved.

Key words: Rotator cuff; Pectoralis muscle; Tendon transfer; Shoulder

da Cunha Mendes G, Petrucci CV, Monteiro RL. Functional Results after Transfer of the Pectoralis Major Muscle in Subscapularis Tears: A literature review. *International Journal of Orthopaedics* 2014; 1(2): 43-46 Available from: URL: <http://www.ghrnet.org/index.php/ijo/article/view/827>

INTRODUCTION

The irreparable rotator cuff injuries are those which there are rupture of two or more tendons and more than five centimeters in diameter often associated with retraction of the myotendinous unit and degenerative changes of the Rotator Cuff muscles, such as fatty infiltration and atrophy which surgical repair is considered difficult, with an uncertain prognosis^[1,2,3]. The tears of the subscapularis muscle can result in an increase in external rotation, increase translation of the humeral head and a decrease in shoulder abduction^[4,5].

Muscle transfer and reverse arthroplasty are two treatment options when an irreparable rotator cuff repair is impossible to be done. The reverse prosthesis is used when there is an extensive rotator cuff injury associated with osteoarthritis and muscle transfer is used when the joint is already intact. The most frequently muscles used in the literature are the deltoid, pectoralis major, long head of the triceps and the latissimus dorsi^[2].

The transfer of the pectoralis major muscle was described in 1997 by Wirth and Rockwood for the irreparable injury of the subscapularis muscle^[6]. The pectoralis major muscle has gained favor as a suitable muscle for transfer because it contracts in-phase with subscapularis, and because of this position it may oppose the extension force of the posterior deltoid with shoulder abduction, which for example makes bringing the hand to the mouth difficult^[7].

Nevertheless there is an inconclusive functional results obtained after the transfer of the pectoralis major in irreparable lesions of the subscapularis muscle. Although there are reports that pain relief is found after repair, the same results are not found in increasing muscle strength and range of motion^[4,8,9]. Later on, literature review on the functional outcomes after transfer of the subscapularis in irreparable rotator cuff tears will assist in developing a consensus, as well as assist rehabilitation professionals to plan objectives and supplement

the functional outcomes after surgical treatment.

The aim of this study was to investigate through literature review the functional outcomes after transfer of the pectoralis major muscle in irreparable tears of the subscapularis. According to Konrad *et al.*^[10] the transfer of the pectoralis major muscle can restore normal kinematics of the glenohumeral joint, and based on these data, we believe that there is an increase in range of motion and improved function after transfer.

METHODS

We conducted a literature review based on literature search using key words in English language on SCIEDIRECT and PUBMED databases (Figure 1). According to the descriptors found in DeCS and MeSH for choosing the keywords to be used in searches, the crossed terms used were: "rotator cuff", "pectoralis muscle", "tendon transfer", "shoulder" (Table 1).

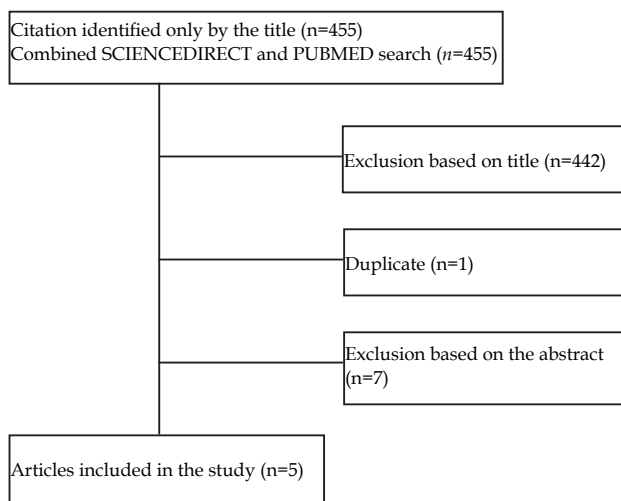


Figure 1 Flow diagram presenting the literature review process used in this study.

Table 1 Search Terms used in PUBMED and SCIENCEDIRECT databases to identify studies.

Number	Search Terms
1	Tendon transfer shoulder
2	Tendon transfer rotator cuff
5	Pectoralis muscle tendon transfer shoulder
6	Pectoralis muscle tendon transfer rotator cuff

Table 2 Demographic details of the reviewed studies.

Author(s)/Year	Type of Study	Sample	Method of Evaluation	Follow-up
Gavriilidis <i>et al</i> 2010	Retrospective	15 patients	Goniometry Dynamometry Constant and Murley	37 months
Jost <i>et al</i> 2003	Retrospective	28 patients	Goniometry Constant and Murley Goniometry	32 months
Galatz <i>et al</i> 2003	Retrospective	14 patients	VAS ASES	17.5 months
Resh <i>et al</i> 2000	Retrospective	12 patients	Constant and Murley VAS	28 months
Lederer <i>et al</i> 2011	Retrospective	54 patients	Goniometry Belly-press Lift-off VAS Constant and Murley Simple Shoulder Test	35 months

VAS: Visual analog scale; ASES: American Shoulder and Elbow Surgeons.

Articles published in English that showed the functional outcomes after transfer of the pectoralis major muscle in individuals with irreparable tears of the subscapularis muscle were included in this study. During data collection there was no restriction on the publication year of the studies, only articles describing the surgical procedure and cadaver studies were excluded.

RESULTS

Five studies met the inclusion and exclusion criteria and were included in this literature review^[11-15]. All included studies were retrospective, published in the period from 2000 to 2011 and the surgical procedure performed from 1993 to 2006; they had a total of 123 patients (mean of 24.6 individuals per study) and a follow-up made during 29.9 months (Table 2). The indication for the transfer of the pectoralis major muscle was for patients with irreparable tears of the subscapularis muscle with or without anterosuperior shoulder instability. The studies concluded that the transfer of the pectoralis major muscle technique is a treatment option, resulting in function improvements and pain relief, but Jost *et al.*^[13], adds that the injury of subscapularis muscle associated with supraspinatus has lower levels of functionality.

The functional data are shown in table 3. Five studies were included in the analysis, from which the study performed by Lederer *et al.*^[15] compared two surgical techniques of transfer of the pectoralis major muscle, while group 1 underwent a bone graft, group 2 underwent a tenotomy.

The range of motion pre and postoperative for elevation was evaluated in four studies^[11-14], with an average of 96.25 and 117.5 degrees, respectively. Only one study^[18] assessed the movement of internal rotation. Three authors^[11-13] reported the results of pre and postoperative abduction, with an average of 106.3 and 124.6 degrees, respectively. The movement of external rotation was evaluated in three studies^[12-14], with a mean of 51.3 degrees preoperatively to 36 degrees postoperatively.

The strength of pre and postoperative abduction, measured by a dynamometer, was evaluated in two studies^[12,13], with a mean of 1.3 and 2.8 kg, respectively. Only one study^[13] evaluated pre and postoperative strength of internal rotation.

Functional assessment, measured by Constant and Murley scale was applied in four studies^[11,12,13,15] the mean preoperative values were 49.5 and 79.5 postoperatively, which resulted in a difference of 30 points on the scale. (Table 3). Only one study^[14] showed the pre and postoperative visual analog pain scale.

CONCLUSION

The transfer of the pectoralis major muscle has been considered a resource to restore function and provide pain relief in patients with irreparable tears of the rotator cuff involving the subscapularis tendon in the absence of osteoarthritis at the glenohumeral joint^[2,7].

In general, the transfer of the pectoralis major led to a significant improvement of the elevation and abduction motion, but no improvement for external rotation (Table 3). On average, there was a gain of 21 degrees on elevation, 18 degrees on shoulder abduction and a decrease of 15 degrees on external rotation. Only two studies^[12,13] evaluated the strength of abduction, in which there was an increase of 125%. One study^[12] assessed the strength pre and postoperative of internal rotation with a 20% of improvement.

A study by Nelson *et al*^[16] corroborates with the data found in our study, which has concluded, through a literature review, that the transfer of the pectoralis muscle can be an effective treatment for pain reduction and improvement of function, in cases when conservative treatment and attempts to anatomical restoration failed, however it does not present a systematic methodology, with no inclusion and exclusion criteria as well as how to select articles. Furthermore, Konrad *et al*^[10] in a biomechanical cadaver study showed that the transfer of the pectoralis major muscle, specifically below the conjoint tendon in subscapularis muscle injuries, can restore normal kinematics of the glenohumeral joint.

However, patients should not expect normal function return or total improvement of pain^[13] and according to Lederer *et al*^[15], fatty degeneration of the muscle will persist even after the reinsertion of the tendon.

Another important factor for normal function return is postoperative rehabilitation. Raabet *et al*^[17] suggested in their prospective randomized study that early continuous passive motion after rotator cuff repair has a beneficial effect on range of motion and pain relief. Furthermore, Li *et al*^[18] found that the continuous passive motion in rabbits caused a fibroblast growth factor, leading to increased synthesis of type III collagen in tendon-bone interface in the earliest stages of repair after acute disruption of the tendon, thus contributing to the recovery of tendon-bone after a rotator cuff injury. Arndt *et al*^[19] through a prospective randomized study, which compared the clinical effects of early passive motion and immobilization in the postoperative repair of the rotator cuff, concluded that early passive motion should be performed, because the functional results were better than the group that maintained immobilized for a period.

Among the studies included in this review, four of them started early mobilization of external rotation after the transfer of the tendon of the pectoralis major muscle. Jost *et al*^[13] and Resh *et al*^[12] also added the elevation motion associated to internal rotation and passive mobilization in all planes, respectively. Furthermore,

Graviilidis *et al*^[11] performed the passive motion only on the third day postoperatively limited to 30 degrees of flexion and 80 degrees of internal rotation. In general, the active movement without restriction was initiated at the sixth week, while muscle strengthening began at the twelfth.

On the other hand, one analyzed study did not perform early passive mobilization, however, descriptively, resulted in no differences in range of shoulder elevation when compared to other studies^[14].

This study has a number of weaknesses. As it is typical of any literature review, the weaknesses inherent in each individual study (retrospective design and short follow-up period) brings limitations for this review. The methodologies of the reviewed studies did not provide bias controls, since the articles were mainly descriptive in nature, not having a suitable method of functional assessment, as well as the best surgical technique and postoperative rehabilitation. Just like them, our study is simply an observational analysis of observational studies in most cases, but provides an overview of the available literature. Furthermore, despite the fact we have used a systematic methodology in which we believe to be reproducible, it is possible that the terms of searches in some different databases would have provided additional studies that would have met our inclusion criteria.

The transfer of the pectoralis major muscle in irreparable tears of the subscapularis muscle seems to be an effective treatment option to improve function. However, more studies with better methodological quality with emphasis on functional outcomes are needed.

CONFLICT OF INTERESTS

There are no conflicts of interest with regard to the present study.

REFERENCES

- 1 Lech O, Piluski P, Tambani R, Castro N, Pimentel G. Integridade do músculo subescapular após cirurgia aberta para tratamento da luxação recidivante glenoumeral: Avaliação clínica e radiológica. *Rev Bras Ortop* 2009; **44**(5): 420-426.
- 2 Weening AA, Willems WP. Latissimus dorsi transfer for treatment of irreparable rotator cuff tears. *International Orthopaedics* 2010; **34**: 1239-1244.
- 3 Hawkins RJ, Misamore GW, Hobeika PE. Surgery for full thickness rotator-cuff tears. *J Bone Joint Surg Am* 1985; **67**(9): 1349-1355
- 4 Wirth MA and Rockwood CA. Operative Treatment of Irreparable Rupture of the Subscapularis. *J Bone Joint Surg Am* 1997; **79**: 722-31
- 5 Talbott JC, Limb D: The management of irreparable rotator cuff tears. *Orthopaedics and Trauma* 2012; **26**: 367-373
- 6 Omid R, Lee B. Tendon transfers for irreparable rotator cuff tears. *J Am Acad Orthop Surg* 2013; **21**: 492-501

Table 3 Functional pre and postoperative results of the transfer of the pectoralis major muscle.

Author(s)/Year	Elevation	Abduction	Internal rotation	External rotation	ASES	VAS	Constant and Murley score	Abduction Strength	Internal rotation Strength
Gavriilidis <i>et al</i> 2010	145/149	126/135	76/78	NR	NR	NR	52/68	NR	NR
Resh <i>et al</i> 2000	93/129	85/113	NR	55/30	NR	NR	22/54	0.8/2	4.5/5.6
Galatz <i>et al</i> 2003	28/60	NR	NR	33/28	27.2/47.7	6.9/3.2	NR	NR	NR
Jost <i>et al</i> 2003	119/132	108/126	NR	66/50	NR	NR	47/70	1.8/3.6	NR
Lederer <i>et al</i> 2011									
Group 1	NR/150	NR/143	NR	NR/53	NR	NR/3.9	40/64	NR	NR/8.2
Group 2	NR/133	NR/130	NR	NR/44	NR	NR/4.2	37/62	NR	NR/5.8

NR: Not recorded.

- 7 Streit JJ, Shishani Y, Gobeze R. Pectoralis Major Tendon Transfer for Subscapularis Insufficiency: A Biological Bail-Out. *Seminars in Arthroplasty* 2011; **22**: 37-41
- 8 Vidil A, Augereau B. Transfer of the clavicular portion of the pectoralis major muscle in the treatment of irreparable tears of the subscapularis muscle. *Rev Chir Orthop Reparatrice Appar Mot* 2000; **86**: 835-43
- 9 Gerber A, Warner JJ. The combined teres major-pectoralis major transfer for irreparable subscapularis lesions. A preliminary report. Presented at the Annual Meeting of the American Academy of Orthopedic Surgeons, 2002
- 10 Konrad GG, Sudkamp NP, Kreuz PC, Jolly JT, McMahon PJ, Debski RE: Pectoralis major tendon transfers above or underneath the conjoint tendon in subscapularis-deficient shoulders: An in vitro biomechanical analysis. *J Bone Joint Surg Am* 2007; **89**:2477-84.
11. Gavriilidis I, Kircher J, Magosch P, Lichtenberg S, Habermeyer P: Pectoralis major transfer for the treatment of irreparable anterosuperior rotator cuff tears. *International Orthopaedics* 2010; **34**: 689-94
- 12 Resch H, Povacz P, Ritter E, Matschi W. Transfer of the pectoralis major muscle for the treatment of irreparable rupture of the subscapularis tendon. *J Bone Joint Surg Am* 2000; **82**: 372-82
- 13 Jost B, Puskas GJ, Lustenberger A, Gerber C: Outcome of pectoralis major transfer for the treatment of irreparable subscapularis tears. *J Bone Joint Surg Am* 2003; **85**: 1944-51
- 14 Galatz LM, Connor PM, Calfee RP, Hsu JC, Yamaguchi K: Pectoralis major transfer for anterior-superior subluxation in massive rotator cuff insufficiency. *J Shoulder Elbow Surg* 2003; **12**: 1-5.
- 15 Lederer S, Auffarth A, Bogner R, Tauber M, Mayer M, Karpik S, Matis N, Resh H. Magnetic resonance imaging-controlled results of the pectoralis major tendon transfer for irreparable anterosuperior rotator cuff tears performed with standard and modified fixation techniques. *J Shoulder Elbow Surg* 2011; **20**:1155-62. Magnetic resonance imaging-controlled results of the pectoralis major tendon transfer for irreparable anterosuperior rotator cuff tears performed with standard and modified fixation techniques. *J Shoulder Elbow Surg* 2011; **20**: 1155-62
- 16 Nelson GN, Namdari S, Galatz L, Keener JD: Pectoralis major tendon transfer for irreparable subscapularis tears. *J Shoulder Elbow Surg* 2014
- 17 Raab MG, Rzeszutko D, O'Connor W, Greatting MD. Early results of continuous passive motion after rotator cuff repair: a prospective, randomized, blinded, controlled study. *Am J Orthop (Belle Mead NJ)* 1996; **25**(3): 214-220
- 18 Li S, Min SX, Zhang H, Fu GJ, Wang PC, Jin AM. Effect of continuous passive motion on basic fibroblast growth factor expression during tendon-bone repair after surgical repair of acute rupture of the supraspinatus tendon in rabbits. *Nan Fang Yi Ke Da Xue Xue Bao* 2010; **30**(5): 1020-1023
- 19 Arndt J, Clavert P, Mielcarek P, Bouchaib J, Meyer N, Kempf JF. Immediate passive motion versus immobilization after endoscopic supraspinatus tendon repair: A prospective randomized study. *Orthopaedics & Traumatology: Surgery & Research* 2012; **98S**: S131-S138

Peer reviewers: Jae-Hwa Kim, Professor, MD, PhD, Department of Orthopaedics, 59yatap-ro, Bundang-gu, Seongnam-si, Gyeonggi-do, 463-712, Korea; Maurice Balke, Department of Sportstraumatology, Cologne Merheim Medical Center, University of Witten/Herdecke, Ostmerheimer Str. 200, 51109 Köln, Germany; Javier Muñoz-Marín, Hospital MAZ, Av Academia General Militar, 74, Zaragoza, 50015, Spain; Riccardo Maria Lanzetti, MD, Orthopaedic Department, St. Andrea Hospital University of Rome, Italy.