

Achilles Tendon Infection Risks in Synthetic Augmentations-A Case Report

Antonio Vadalà, Riccardo Maria Lanzetti, Alessandro Ciompi, Andrea Gatti, Alessandro Agrò, Carlo Iorio, Domenico Lupariello, Andrea Ferretti

Antonio Vadalà, Riccardo Maria Lanzetti, Alessandro Ciompi, Andrea Gatti, Alessandro Agrò, Carlo Iorio, Domenico Lupariello, Andrea Ferretti, Department of Orthopaedic and Traumatology, University of Rome "La Sapienza", Rome, Italy

Correspondence to: Riccardo Maria Lanzetti, Department of Orthopaedic and Traumatology, University of Rome "La Sapienza", Rome, Italy

Email: riccardolanzetti@gmail.com

Telephone: +39-3475189904

Received: May 26, 2014 Revised: June 19, 2014

Accepted: June 23, 2014

Published online: August 23, 2014

Orthopaedics 2014; 1(2): 57-60 Available from: URL: <http://www.ghrnet.org/index.php/ijo/article/view/830>

INTRODUCTION

Despite achilles tendon ruptures represents one of the most common tendon disorders, there is still a great debate among authors regarding the best surgical procedure to perform, especially in young and active patients^[1-5].

Many surgical techniques have been described in literature^[6-10]. In addition to primary repair, augmentation with aponeurosis flaps, V-Y plasty^[11], tendon transfers^[12-13], allograft^[14] or synthetic grafts^[15-19] have been developed to facilitate end-to-end anastomosis and to improve positive long-term follow-up results in patients with re-rupture or with chronic ruptures of the tendon. However, these techniques require a more extensive skin incision in order to adequately debride necrotic areas around the tendon stumps and to insert the selected augmentation graft. This may cause higher rates of post-operative complications than with anatomical treatments^[10,20].

In this paper we report about a 53-year old man who has been operated on for a revision of an Achilles tendon rupture with Ligastic® synthetic graft in which an infection developed over the graft twenty years after.

CASE REPORT

S.M., a 53-year old man, presented to our Emergency Department with a one month history of left ankle and foot pain associated with tenderness, swelling and redness. He also reported recent onset of fever 2 days before.

The patient had no history of recent trauma, but he reported in 1991 surgical treatment for achilles tendon rupture with the use of the Ligastic® synthetic graft.

In 1991 he was operated in an other Orthopaedic Department after three days from the trauma. During the twenty years after the reconstruction the patient did not report any sign or symptom at the operated leg.

Clinically, he was found to have tenderness, swelling and heat along his left achilles tendon; wound dehiscence was observed at

ABSTRACT

We report the case of a 53-year old man with a history of achilles tendon suture with the use of Ligastic® synthetic graft in 1991. Twenty years after, the patients, with no history of recent trauma or other concomitant local or systemic diseases, showed up to our Orthopaedic Department because of the onset of high fever, wound dehiscence at the site of the previous surgery along with spontaneous purulent discharge. Results of bacterial cultures showed the presence of *Staphylococcus Aureus*; after a few days of antibiotic treatment, the patient underwent a new surgical treatment in order to adequately counteract and remove the cause of infection. Surgical treatment showed a massive infection surrounding the reconstructed achilles tendon coming from the synthetic graft positioned inside the tendon itself. Removal of this augmentation led to an immediate improvement of systemic and local conditions with satisfactory recovery of function of the ankle.

© 2014 ACT. All rights reserved.

Key words: Tendons; Surgery; Infection

Vadalà A, Lanzetti RM, Ciompi A, Gatti A, Agrò A, Iorio C, Lupariello D, Ferretti A. Achilles Tendon Infection Risks in Synthetic Augmentations-A Case Report. *International Journal of*

the site of the previous surgery, with spontaneous purulent discharge (Figure 1). Range of motion (ROM) of the ankle was restricted and lack of strength in both plantar or dorsal flexion was also detected. A bilateral significant calf atrophy was also described. Thompson test was negative. Routine blood tests including complete blood count and chemistry panel, along with erythrocyte sedimentation rate (ESR), C-reactive protein (CRP) and fibrinogen were performed. Before empiric antimicrobial therapy was started, samples from wound discharge were aseptically collected using a sterile swab and studied for identification of isolates by Gram stain and bacterial culture followed by *in vitro* antibiotic susceptibility testing.

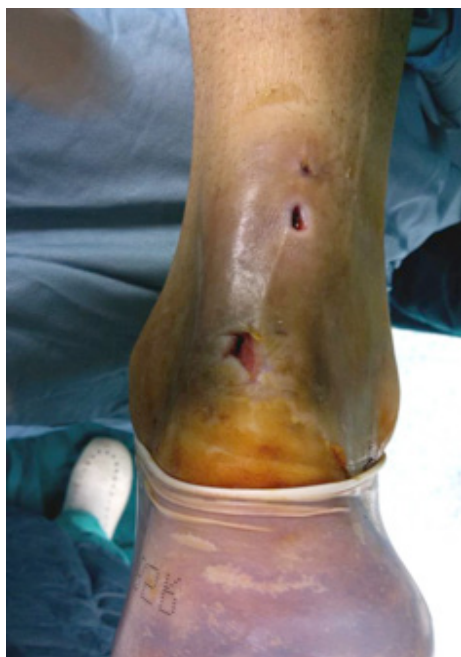

Figure 1 Multiple skin dehiscences at the level of the previous achilles tendon reconstruction.

Patient was then admitted to our Orthopedic Department and antibiotic treatment with teicoplanin (Targosid™) 400 mg every 12 hours, with a loading dose of 800 mg the first day, was started. After drug was administered, patient experienced an allergic reaction, successfully treated with a single 40 mg intravenous bolus injection of Methylprednisolone (Urbason). Laboratory test results showed an elevated WBC count (12,400 cells per cubic millimeter) with an absolute increase in neutrophils (83.7%; normal range 45-74%), an elevated ESR (86 mm/h; normal range 0-20 mm/h), and had an elevated CRP value (6.5 mg/dL; normal range 0-0.5 mg/dL).

Results for bacterial cultures became available in two days and showed growth of *Staphylococcus Aureus*.

Antibiotic therapy was then changed and Tigecycline (TYGACIL®), initial dose of 100 mg, followed by 50 mg every 12 hour) was chosen on the basis of antimicrobial susceptibility tests results.

Routine ankle MR imaging was performed in the axial, coronal, and sagittal planes. Coronal T1-weighted MRI image showed thickening of the Achilles tendon, with internal edema-fluid signal intensity. T2-weighted fat-saturated fast spin-echo (FSE) images revealed a pattern suggestive of abscess, with focally increased signal intensity in the central portion of achilles tendon along with fluid signal filling the tendon sheath and soft tissue edema extending to subcutaneous tissue and skin.

Our consultant plastic surgeon prescribed daily wound dressing changes and irrigation of the area with dilute saline solutions of 35%

hydrogen peroxide.

Eleven days after admission, the patient underwent revision of the previous tenorrhaphy. When the paratenon was incised, it revealed a liquid and copious corpuscolated exudates, mixed with residual portion of the synthetic tendon graft used. Achilles tendon was hypertrophic but intact. The Ligastic® graft was removed along with all of the surrounding infected tissue, and extensive debridement was performed (Figure 2) and a specimen was collected for the histological examination (Figure 3). After surgery, a short leg cast was applied and progressive weight bearing was allowed 10 days after surgery. No post-operative complications were registered. Histological exam of the tissue harvested during the operation showed inflammatory infiltrate in a context of connective fibrous tissue, with multiple foci of granulation tissue, foreign body giant cell reaction and fibrin. Three days after surgery the patient had no more fever and he was discharged. At the 12-month follow-up, patient reported full return to daily and work activities with no restrictions or residual pain. Physical examination showed a complete recovery of range of motion of the ankle with no local signs of infection or tissue adhesions. Plantar flexion strength was satisfactory in a side-to-side evaluation (S/S). The AOFAS ankle-hindfoot score was 98 and the patient was fully satisfied with the treatment.

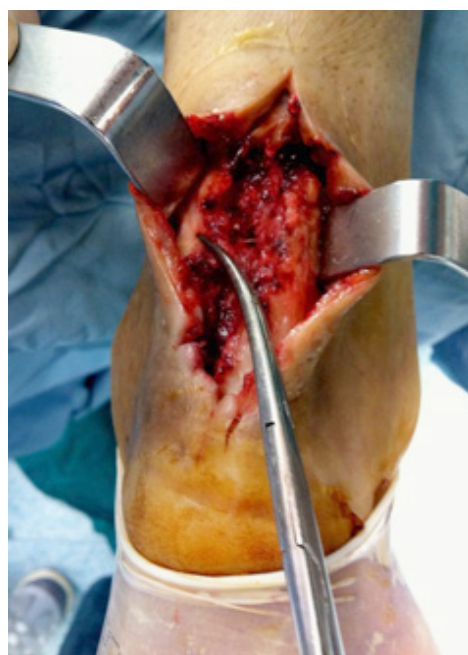

Figure 2 Harvest of the synthetic graft used to reinforce the tendon reconstruction.

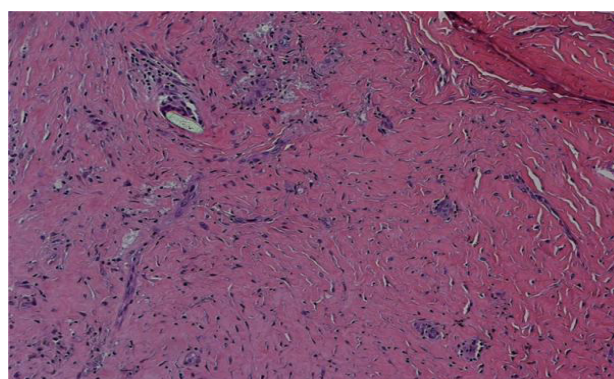


Figure 3 Histological exam of the tissue harvested during the operation showed inflammatory infiltrate in a context of connective fibrous tissue.

CONCLUSION

Many surgical techniques have been described in literature for achilles tendon repair, even though there is no agreement yet among authors regard the best type of operative technique to perform^[6-10]. In their systematic review, Kahn *et al*^[2] showed how operative treatment of acutely ruptured tendons was useful in reducing rerupture rate compared to non-operative treatment and how percutaneous repair was associated with significant lower percentage of complications. In patients with chronic ruptures, re-ruptures, or extensive degenerative changes in tendon tissue, treatment can be significantly more challenging^[21,22]; in these cases, repair with sutures is usually combined with several different tendon augmentation procedures such as tendon transfers, flaps, advancements, free flaps, allografts or the use of synthetic materials^[11-19], in order to bridge the tendon gap and lower the rate of failure. Although their precise biological mechanisms have not yet been established, various synthetic biomaterials have already been used for tendon augmentation. It has been speculated that these materials would act as scaffolds on which fibrous tissue could be induced to proliferate and form ligament-like tissues^[23-25]. The postulated advantages of this approach would be to avoid complications with donor site morbidity and to increase load to failure of repaired tendons immediately after surgery, thus allowing more aggressive early rehabilitation^[26,27].

Disadvantages of these techniques are the need of longer skin incisions, increased risk of wound healing delay and increased risk of deep infection^[3,9,28,29].

As far as we know, in this paper we describe the first case of a patient operated on for achilles tendon rupture with synthetic augmentation who experienced a massive local infection twenty years after the operation. It is a matter of fact that synthetic grafts represent a foreign body for the immune system which expose the patient to local infection even after many years. Certainly, the graft creates a fertile metabolic environment in which bacteria could grow and somehow evade immune system detection, thus avoiding evoking an immune response for a very long time. However, since the sudden onset of infection symptoms could not be related to specific events, such as a recent surgical intervention, infections, ankle trauma or immunodeficiency, we still do not know why the infection developed abruptly twenty years after the implant of this graft.

In conclusion, although some authors have reported satisfactory functional results using synthetic grafts to reinforce achilles tendon repair, the long-term effectiveness and safety of this treatment is still a arguable topic. Further research is needed to understand what type of fibers cover these scaffolds and how these grafts interact with the surrounding tissues and with the host immune system. Local and massive episodes of infection may always occur even many years after the surgery and this should be kept in mind of surgeons using such types of augmentation.

CONFLICT OF INTERESTS

There are no conflicts of interest with regard to the present study.

REFERENCES

- Józsa L, Kvist M, Bálint BJ, Reffy A, Järvinen M, Lehto M, Barzo M. The role of recreational sport activity in Achilles tendon rupture. A clinical, pathoanatomical, and sociological study of 292 cases. *Am J Sports Med* 1989 May-Jun; **17**(3): 338-343
- Khan RJ, Fick D, Keogh A, Crawford J, Brammar T, Parker M. Treatment of acute achilles tendon ruptures. A meta-analysis of ran- domized, controlled trials. *J Bone Joint Surg Am* 2005 Oct; **87**(10): 2202-2210
- Bhandari M, Guyatt GH, Siddiqui F, Morrow F, Busse J, Leighton RK, Sprague S, Schemitsch EH. Treatment of acute Achilles tendon rup-tures: a systematic overview and metaanalysis. *Clin Orthop Relat Res* 2002 Jul; **400**: 190-200
- Ajis A, Maffulli N. Management of acute tendo Achillis ruptures. *Foot. Ankle Surg* 2007; **13**: 132-135
- Maffulli N. Current concepts review: rupture of the Achilles tendon. *J Bone Joint Surg Am* 1999; **81**(7): 1019-1036
- Ma GW, Griffith TG. Percutaneous repair of acute closed ruptured Achilles tendon: a new technique. *Clin Orthop Relat Res* 1977 Oct; **128**: 247-255
- Gigante A, Moschini A, Verdenelli A, Del Torto M, Ulisse S, de Palma L. Open versus percutaneous repair in the treatment of acute Achilles tendon rupture: a randomized prospective study. *Knee Surg Sports Traumatol Arthrosc* 2008 Feb; **16**(2): 204-209
- Maffulli N, Leadbetter WB. Free gracilis tendon graft in neglected tears of the achilles tendon. *Clin J Sport Med* 2005 Mar; **15**(2): 56-61
- Nyysönen T, Saarikoski H, Kaukonen JP, Lüthje P, Hakovirta H. Simple end-to-end suture versus augmented repair in acute Achilles tendon ruptures: a retrospective comparison in 98 patients. *Acta Orthop Scand* 2003 Apr; **74**(2): 206-208.
- Aktas S, Kocaoglu B, Nalbantoglu U, Seyhan M, Guven O. End-to-end versus augmented repair in the treatment of acute Achilles tendon ruptures. *J Foot Ankle Surg* 2007 Sep-Oct; **46**(5): 336-340
- Abraham E, Pankovich AM. Neglected rupture of the Achilles tendon. Treatment by V-Y tendinous flap. *J Bone Joint Surg Am* 1975 Mar; **57**(2): 253-255
- Martin RL, Manning CM, Carcia CR, Conti SF. An outcome study of chronic Achilles tendinosis after excision of the Achilles tendon and flexor hallucis longus tendon transfer. *Foot Ankle Int* 2005 Sep; **26**(9): 691-697
- Miskulin M, Miskulin A, Klobucar H, Kuvalja S. Neglected rupture of the Achilles tendon treated with peroneus brevis transfer: a functional assessment of 5 cases. *J Foot Ankle Surg* 2005 Jan-Feb; **44**(1): 49-56
- Lepow GM, Green JB. Reconstruction of a neglected Achilles tendon rupture with an Achilles tendon allograft: a case report. *J Foot Ankle Surg* 2006 Sep-Oct; **45**(5): 351-355
- Lieberman JR, Lozman J, Czajka J, Dougherty J. Repair of Achilles tendon rupture with Dacron vascular graft. *Clin Orthop Relat Res* 1988 Sep; **234**: 204-208
- Parsons JR, Weiss AB, Schenk RS, Alexander H, Pavlisko F. Long-term follow-up of Achilles tendon repair with an absorbable polymer carbon fiber composite. *Foot Ankle* 1989 Feb; **9**(4): 179-184
- Schedl R, Fasol P. Achilles tendon repair with the plantaris tendon compared with repair using polyglycol threads. *J Trauma* 1979 Mar; **19**(3): 189-194
- Ozaki J, Fujiki J, Sugimoto K, Tamai S, Masuhara K. Reconstruction of the neglected Achilles tendon rupture with Marlex mesh. *Clin Orthop Relat Res* 1989 Jan; **238**: 204-208
- Lee DK. Achilles Tendon Repair with Acellular Tissue Graft Augmentation in Neglected Ruptures. *J Foot Ankle Surg* 2007 Nov-Dec; **46**(6): 451-455
- García-Germán D, Rubio-Quevedo R, Lopez-Goenaga J, Martín-Guinea J. Achilles tendon recurrent rupture following surgical repair: Report on two cases. *Foot Ankle Surg* 2009; **15**(3): 152-154
- Padanilam TG. Chronic Achilles tendon ruptures. *Foot Ankle Clin* 2009 Dec; **14**(4): 711-728
- Maffulli N, Ajis A. Management of chronic ruptures of the Achilles tendon. *J Bone Joint Surg Am* 2008 Jun; **90**(6): 1348-1360
- Andrish JT, Woods LD. Dacron augmentation in anterior cruciate ligament reconstruction in dogs. *Clin Orthop Relat Res* 1984 Mar; **183**: 298-302

- 24 Arnoczky SP, Warren RF, Minei JP. Replacement of the anterior cruciate ligament using a synthetic prosthesis. An evaluation of graft biology in the dog. *Am J Sports Med* 1986 Jan-Feb; **14(1)**: 1-6
- 25 Amis AA, Campbell JR, Kempson SA, Miller JH. Comparison of the structure of neotendons induced by implantation of carbon or polyester fiber. *J Bone Joint Surg Br* 1984 Jan; **66(1)**: 131-139
- 26 Giza E, Frizzell L, Farac R, Williams J, Kim S. Augmented tendon Achilles repair using a tissue reinforcement scaffold: a biomechanical study. *Foot Ankle Int* 2011 May; **32(5)**: S545-9
- 27 Magnussen RA, Glisson RR, Moorman CT 3rd. Augmentation of Achilles tendon repair with extracellular matrix xenograft: a biomechanical analysis. *Am J Sports Med* 2011 Jul; **39(7)**: 1522-1527
- 28 Lui TH, Chan KB. Achilles tendon infection due to *Mycobacterium chelonae*. *J Foot Ankle Surg* 2014 May-Jun; **53(3)**: 350-352
- 29 Ahluwalia R, Zourelidis C, Guo S, Dega R. Chronic sinus formation using non absorbable braided suture following open repair of Achilles tendon. *Foot Ankle Surg* 2013 Jun; **19(2)**: e7-9

Peer reviewers: Jon Joensen, Department of Occupational Therapy, Physiotherapy and Radiography, Bergen University College, Mollendalsveien 6, N-5009 Bergen, Norway; Hede Yan M.D., Ph.D, Department of Orthopaedics, The 2nd Affiliated Hospital of Wenzhou Medical University, 109 West Xueyuan Road, Lucheng District, Wenzhou, Zhejiang Province, 276300, China; Panagiotis K. Givissis MD, PhD, Associate Professor, 1st Orthopaedic Department, Aristotle University of Thessaloniki, 9 Papanikolaou Str, Thessaloniki, Mail Box 215, Postal Code 55210, Greece.