

## Osteochondral Talar Fracture Treated with Arthroscopic Reduction and Internal Fixation: A Case Report

Thomas A Pagonis, Panagiotis D Symeonidis, Panagiotis K Givissis, Anastasios C Christodoulou

Thomas A Pagonis, Panagiotis K Givissis, Anastasios C Christodoulou, Trauma & Orthopaedic Department, Spinal Unit, The Ipswich Hospital NHS Trust, Heath Road, Ipswich, Suffolk, IP4 5PD, the United Kingdom

Thomas A Pagonis, 1<sup>st</sup> Orthopaedic Department of Aristotle's University of Thessaloniki, G.U.H.G.Papanikolaou, Thessaloniki, Hellenic Republic, Greece

Correspondence to: Thomas A Pagonis, 1<sup>st</sup> Orthopaedic Department of Aristotle's University of Thessaloniki, G.U.H.G.Papanikolaou, Thessaloniki, Hellenic Republic, Greece

Email: [iatros1@yahoo.com](mailto:iatros1@yahoo.com)

Telephone: +44 (0)7896360517

Received: May 26, 2014

Revised: June 17, 2014

Accepted: June 23, 2014

Published online: August 23, 2014

### ABSTRACT

**INTRODUCTION:** Arthroscopic reduction and internal fixation (ARIF) is becoming a popular technique for the management of articular fractures.

**CASE REPORT:** A 41 year old is admitted following an RTA with a transverse fracture of the left fibula and an avulsed TCF of the lateral cortex of the talus.

**MANAGEMENT:** Arthroscopic intervention from the anterior portals and ORIF with LC-DCP was selected. There was a Transchondral fracture (TCF) and 4 fragments measuring from 2-5 mm. All were removed. A larger TCF fragment was found to be positioned posteriorly to the portals and inaccessible so a posterior portal was opened so that the fragment could be dislodged, grasped and removed from the anterior portal. The size of this fragment was 9×11 mm. An uneventful ORIF of the fibular fracture was performed with a 7 hole LC-DCP with combined locking and normal holes.

**DISCUSSION:** Arthroscopic reduction and internal fixation may cost more initially but in the long-term it may result in reduced costs mainly associated with chronic conditions.

**Key words:** Osteochondral fracture, Talar fracture, Ankle arthroscopis, Talus

Pagonis TA, Symeonidis PD, Givissis PK, Christodoulou AC. Osteochondral Talar Fracture Treated with Arthroscopic Reduction and Internal Fixation: A Case Report. *International Journal of Orthopaedics* 2014; 1(2): 61-63 Available from: URL: <http://www.ghrnet.org/index.php/ijo/article/view/831>

### INTRODUCTION

The use of less invasive image-guided techniques for fracture management of small and medium size joints preserves the soft-tissue envelope and improves reduction. Arthroscopic reduction and internal fixation (ARIF) is becoming a popular technique for the management of articular fractures. In selected cases the use of ankle arthroscopy in a trauma setting is beginning to gain ground. Management of fractures about the ankle requires direct visualization of intra-articular injury during the reduction. A high incidence of intra-articular lesions and chronic ankle pain has been reported after anatomic reduction<sup>[1-4]</sup>. Arthroscopy has been proposed as a means to reduce the incidence of chronic complaints related to intra-articular fracture. However, indications for ARIF remain limited, and the effectiveness of ARIF compared with ORIF has not been determined<sup>[5]</sup>.

A Transchondral fracture (TCF) is an intra-articular fracture produced by a force transmitted from a contiguous bone through the articular cartilage to the subchondral trabeculae. A high incidence of TCF is associated with ankle instability (23% to 95%)<sup>[6,7]</sup> and malleolar fracture (63% to 79%)<sup>[1,8]</sup>. The talar dome, particularly the posteromedial aspect, is the most frequently involved site. A four-stage radiographic classification of TCF by Berndt and Harty<sup>[9]</sup> is widely accepted: stage I, small compression fracture; stage II, incomplete avulsion of a fragment; stage III, complete avulsion of a fragment without displacement; and stage IV, displaced fragment.

### CASE REPORT

A patient 41 years old is admitted in the emergency trauma unit due to a RTA (motorbike driver), having suffered a rotatory force

type injury of the left ankle mortise. On radiological examination with plain X-rays, a transverse fracture (AO 43 A3.3) of the suprasyndesmotic area of the left fibula (Figure 1) was evident as well as an avulsed TCF fragment in the syndesmotic area with the suspicion of being an avulsed TCF fragment of the lateral cortex of the talus. The lower talofibular syndesmosis was suspected to be ruptured. A CT confirmed the diagnosis (Figure 2).

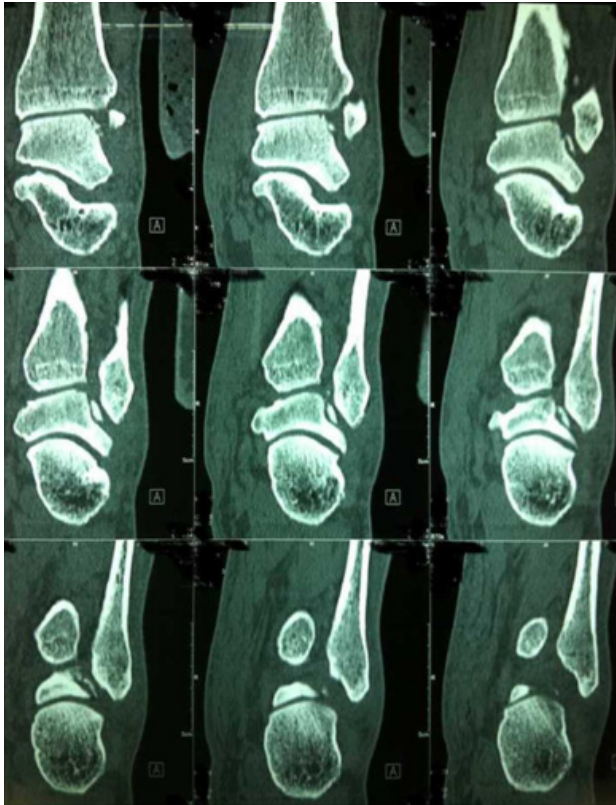


Figure 1 CT showing the TCF fracture respectively.

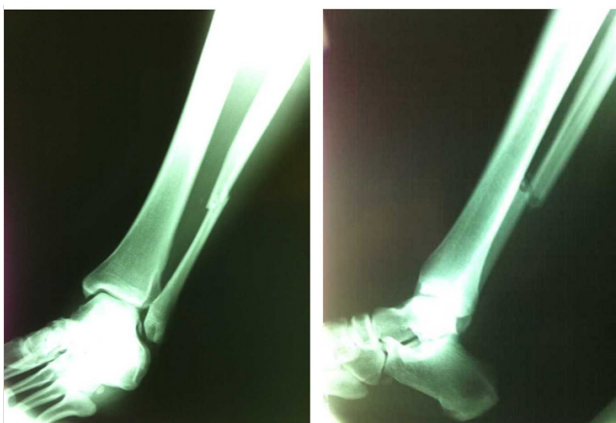

Figure 2 X-rays (AP + Lat) showing the fibula fracture.

## MANAGEMENT

The patient was scheduled for surgery the following day. Arthroscopic intervention was selected for the investigation of the talar avulsion TCF and ORIF with LC-DCP for the fibular fracture. Under general anaesthesia and on the arthroscopic supine position, the arthroscopic anterior portals were selected. There was an evidently fresh TCF of

the lateral cortex of the left talus with 4 fragments measuring from 2-5 mm present. All were removed. The syndesmosis was found to be ruptured. A larger TCF fragment (the one evident on plain radiographs) was found to be positioned posteriorly to the portals and inaccessible so a posterior portal was opened so that the fragment could be dislodged, grasped and removed from the anterior portal. The size of this fragment was 9×11 mm (Figure 3).

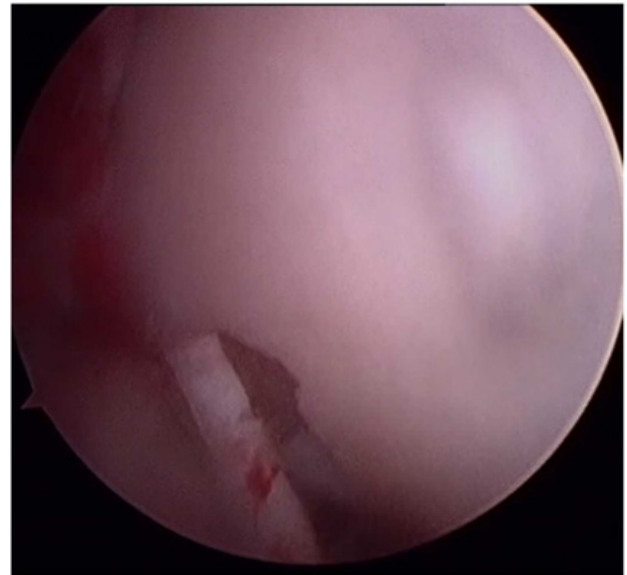


Figure 3 TCF as seen through the arthroscope.

An uneventful ORIF of the fibular fracture was performed with a 7 hole LC-DCP with combined locking and normal holes. 6 normal cortical screws were used and after that with the foot on dorsiflexion and under radiological control (mini C-arm) a syndesmosis screw was positioned (Figure 4, 5). The lower limb was supported with a posterior (backslab) splint for comfort.

Healing of the fibular fracture was uneventful and the ankle joint was checked 10 weeks post op by use of MRI. Physiotherapy was started immediately after the operation. At the post op review 8 weeks later, the patient had full range of motion on weight bearing. On the final follow up 6 months later, the healing process had completed uneventfully.

## DISCUSSION

Definite recommendation for the use of ARIF for management of ankle fractures is difficult<sup>[10]</sup>. However a general agreement regarding the high incidence of intra-articular pathology associated with an ankle fracture is present. In ankle fractures managed with ORIF, some of these fractures may be missed, resulting in chronic problems. A CT would be required to verify and detect possible fragments not visible in plain X-rays.

The main advantages of ARIF include limited exposure, blood supply preservation and improved visualization<sup>[11]</sup>. It is a minimally invasive technique of treatment in a very delicate weight bearing joint that is notorious for post operative osteoarthritis. ARIF delivers results similar to ORIF<sup>[11]</sup> while exhibiting less long term complications associated with postoperative morbidity. Moreover, the recuperation period is shortened and the postoperative mobilization is attenuated.

However, ARIF requires increased surgical time, is technically more challenging and may attenuate soft tissue swelling<sup>[12]</sup>. Nonetheless ARIF may cost more initially but in the long-term it may result in reduced costs mainly associated with circumvention of possible emergence chronic conditions like osteoarthritis.

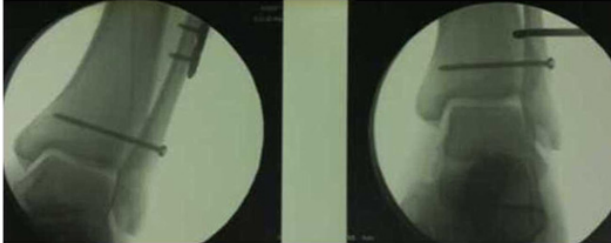


Figure 4 Intraoperative imaging of ORIF.

## CONFLICT OF INTERESTS

There are no conflicts of interest with regard to the present study.

## REFERENCES

- 1 Loren GJ, Ferkel RD. Arthroscopic assessment of occult intra-articular injury in acute ankle fractures. *Arthroscopy* 2002; **18**(4): 412-421
- 2 Thomas B, Yeo JM, Slater GL: Chronic pain after ankle fracture: An arthroscopic assessment case series. *Foot Ankle Int* 2005; **26**(12): 1012-1016
- 3 Leontaritis N, Hinojosa L, Panchbhavi VK: Arthroscopically detected intraarticular lesions associated with acute ankle fractures. *J Bone Joint Surg Am* 2009; **91**(2): 333-339
- 4 Aktas S, Kocaoglu B, Gereli A, Nalbantodlu U, Güven O: Incidence of chondral lesions of talar dome in ankle fracture types. *Foot Ankle Int* 2008; **29**(3): 287-292
- 5 Glazebrook MA, Ganapathy V, Bridge MA, Stone JW, Allard JP: Evidencebased indications for ankle arthroscopy. *Arthroscopy* 2009; **25**(12): 1478-1490
- 6 Choi WJ, Lee JW, Han SH, Kim BS, Lee SK: Chronic lateral ankle instability: The effect of intra-articular lesions on clinical outcome. *Am J Sports Med* 2008; **36**(11): 2167-2172
- 7 Taga I, Shino K, Inoue M, Nakata K, Maeda A: Articular cartilage lesions in ankles with lateral ligament injury. *Am J Sports Med* 1993; **21**(1): 120-127
- 8 Hintermann B, Regazzoni P, Lampert C, Stutz G, Gächter A: Ar-

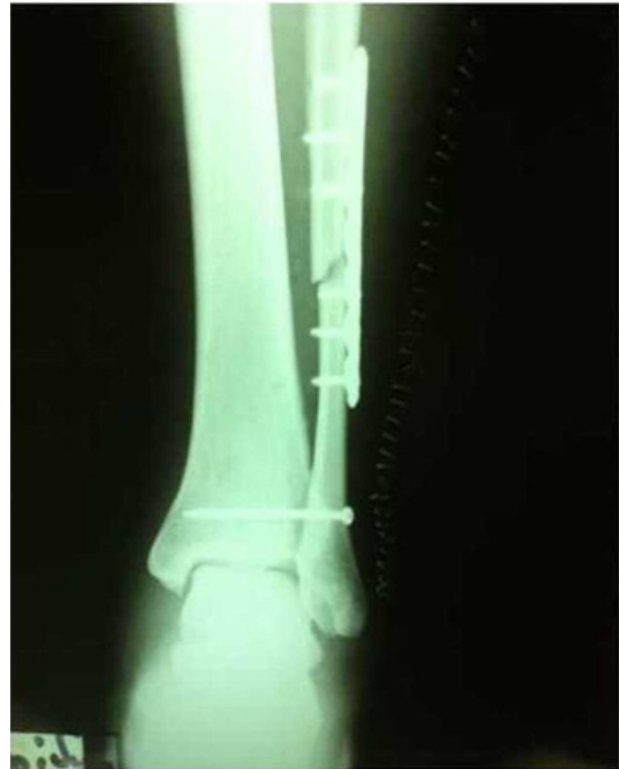

Figure 5 Final postoperative imaging of ORIF.

- throscopic findings in acute fractures of the ankle. *J Bone Joint Surg Br* 2000; **82**(3): 345-351
- 9 Berndt AL, Harty M: Transchondral fractures (osteochondritis dissecans) of the talus. *J Bone Joint Surg Am* 1959; **41**: 988-1020
- 10 O'Loughlin PF, Heyworth BE, Kennedy JG: Current concepts in the diagnosis and treatment of osteochondral lesions of the ankle. *Am J Sports Med* 2010; **38**(2): 392-404
- 11 van Dijk CN, van Bergen CJ: Advancements in ankle arthroscopy. *J Am Acad Orthop Surg* 2008; **16**(11): 635-646
- 12 Saltzman CL, Marsh JL, Tarse DS: Treatment of displaced talus fractures: An arthroscopically assisted approach. *Foot Ankle Int* 1994; **15**(11): 630-633

**Peer reviewer:** Umile Giuseppe Longo, University Campus Bio-Medico of Rome, Via Alvaro del Portillo, 200 – 00128 Rome, Italy; Rubén Daniel Arellano, Avenida Morelos 900 Oriente, Torreón Coahuila México.