

## Current Trends in the Management of Long Head of Biceps Tendon Pathology; Anatomy, Function, Origin and Interval Lesions

Achilleas Boutsiadis, Filon Agathangelidis, Dimitrios Karataglis

Achilleas Boutsiadis, Filon Agathangelidis, Dimitrios Karataglis, Department of Orthopaedics, General Clinic, Blue Cross, Euromedica Thessaloniki, Greece

Correspondence to: Dimitrios Karataglis, Department of Orthopaedics, General Clinic, Blue Cross, Euromedica Thessaloniki, Greece

Email: [dkarataglis@yahoo.gr](mailto:dkarataglis@yahoo.gr)

Telephone: +302310304442

Received: August 27, 2014

Revised: October 25, 2014

Accepted: October 30, 2014

Published online: December 23, 2014

### ABSTRACT

The tendon of the long head of the biceps is commonly involved in complex pathology of the glenohumeral joint, producing anterior shoulder pain and dysfunction. The lesions are classified according to their location and to whether they are combined with a rotator cuff tears or not. In this article we present the anatomy and function of the long head of biceps tendon and through an extensive review of the literature we report on the latest trends in the management of its pathology ranging from non-operative to the most novel arthroscopic techniques.

© 2014 ACT. All rights reserved.

**Key words:** Biceps tendon; Pathology; Treatment

Boutsiadis A, Agathangelidis F, Karataglis D. Current Trends in the Management of Long Head of Biceps Tendon Pathology; Anatomy, Function, Origin and Interval Lesions. *International Journal of Orthopaedics* 2014; 1(4): 146-154 Available from: URL: <http://www.ghrnet.org/index.php/ijo/article/view/835>

### ANATOMY

The tendon of the long head of biceps (LHBT) arises from

the superior labrum and supraglenoid tubercle of the scapula. However, the exact site of tendon origin presents several anatomic variations with more than 50% being from the posterior labrum but with unknown clinical relevance<sup>[1]</sup>. Normal variations of the anterosuperior labrum must be distinguished from pathologic conditions of the biceps anchor<sup>[2]</sup>. These mainly include a sublabral foramen, a sublabral foramen with a cord-like middle glenohumeral ligament and an absent anterosuperior labrum with a cord-like middle glenohumeral ligament (Buford complex)<sup>[3]</sup> (Figure 1).

The LHBT is divided in an intra-articular and an extra-articular portion, its normal diameter is about 5-6 mm and the total length approximately 9 cm<sup>[4]</sup>. However, newer published data show that its length is dependent on the humeral head size<sup>[5]</sup>. The LHBT exits the glenohumeral joint through the rotator interval and enters into the bicipital groove where it is held in place by the biceps reflection pulley or sling proximally and the pectoralis major distally. The biceps pulley consists of fibers of the subscapularis and supraspinatus tendons, the coracohumeral ligament (CHL) and the superior glenohumeral ligament (SGHL)<sup>[6-8]</sup> (Figure 2).

The blood supply of the tendon is mainly from branches of the brachial artery from the musculotendinous side and osteotendinous derived vessels from the insertion side. There is a consistent hypovascular area 1.2 to 3 cm from the tendon origin possibly explaining the susceptibility of this area to degenerative lesions<sup>[9]</sup>. The anterior superficial part of the tendon is better vascularized whereas the lateral, posterior and medial side especially the part of the tendon adjacent to bone appears avascular<sup>[10]</sup>. In addition a large network of sensory sympathetic fibers innervates mainly the tendon origin and may play a significant role in the pathogenesis of shoulder pain<sup>[11]</sup>.

### FUNCTION

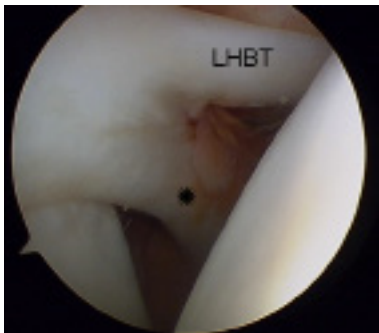
Despite numerous cadaveric biomechanical, EMG, *in vivo* biomechanical and experimental studies the actual functional role of LHBT remains controversial<sup>[4]</sup>.

Traditional knowledge from cadaveric shoulders is that the long head of the biceps presses the humeral head against the glenoid especially during abduction, contributes to stability of the glenohumeral joint in all directions or can either restrict or facilitate axial humeral rotation depending on the degree of glenohumeral elevation<sup>[4,12]</sup>. However, it is not known whether the applied loads during these studies resemble the natural forces on the LHBT and inevitably cannot confirm the *in vivo* role of the tendon<sup>[4]</sup>.

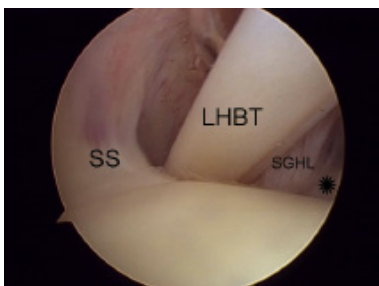
In addition, EMG studies of the function of the Long Head of Biceps (LHB) reported contradictory results. Sakurai *et al* suggested that the LHB muscle acts as an anterior stabilizer of the humeral head and is active during all shoulder motions<sup>[13]</sup>. On the other hand other researchers found that the LHB cannot actively stabilize the shoulder<sup>[14]</sup> and any active role is constrained in achieving tension with elbow and forearm activity<sup>[15]</sup>.

Even *in-vivo* studies that supported the role of head depressor, were unable to provide high quality reliable data about LHBT function<sup>[4,16,17]</sup>. Furthermore, recent rat models showed that laceration of the LHBT in massive rotator cuff tears resulted in better shoulder function and less joint destruction, putting in question its role as head depressor<sup>[18]</sup>.

In conclusion it appears that the LHBT acts as a weak active and static head depressor when it is anatomically positioned. The dynamic role of the biceps at the shoulder is difficult to evaluate in a biomechanical setting since it is affected by the associated function of the elbow.



**Figure 1** Cord-like middle glenohumeral ligament (Asterisk) without tissue at the anterosuperior labrum.



**Figure 2** Arthroscopic image of the biceps tendon pulley. Fibers of the subscapularis (asterisk) and supraspinatus (SS) tendons and the superior glenohumeral ligament (SGHL) are shown.

## BICEPS TENDON INJURIES

In the early 1950s and 60s primary biceps tendinitis was a common diagnosis in almost all painful shoulders in both younger and older patients' cases<sup>[19]</sup>. However, nowadays it is generally accepted that biceps lesions are strongly related to concomitant glenohumeral pathology as rotator cuff tears<sup>[20]</sup> or are result of direct injury or repetitive overhead

trauma<sup>[21]</sup>. Habermeyer and Walch have offered a comprehensive classification of the biceps tendon lesions according to the anatomic location and the surrounding shoulder pathology<sup>[21]</sup> (Table 1).

**Table 1** Habermeyer and Walch Classification of Biceps Lesions.

I. Origin Lesions	SLAP Lesions
	A. Biceps Tendinitis
	B. Isolated Ruptures
	C. Subluxation
II Interval Lesions	Type I: Superior
	Type II: At the groove
	Type III: Malunion- Nonunion Lesser Tuberosity
	A. Tendinitis
	B. Dislocation
III Associated with Rotator Cuff Tears (RCT)	Type IA: Extra-articular with partial subscapularis tear
	Type IB: Extra-articular with an intact subscapularis
	Type II: Intra-articular
	C. Subluxation with RCT
	D. LHBT rupture with RCT

## A. ORIGIN LESIONS

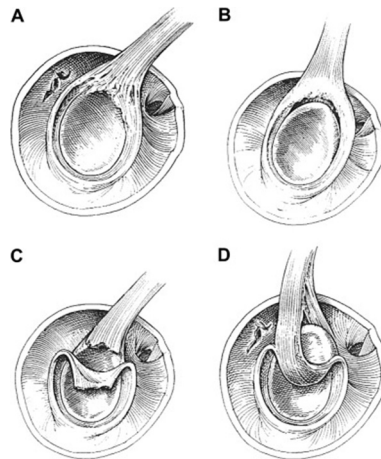
Origin lesions affect the biceps anchor and include mainly SLAP (Superior Labrum Anterior Posterior) Lesions and the complicated pathology of throwers' shoulder.

## SLAP LESIONS

Despite tears of the superior part of the labrum were first described in overhead athletes in 1985<sup>[22]</sup>, accurate arthroscopic evaluation and classification of these injuries were performed by Snyder *et al* in 1990<sup>[23]</sup>.

### Classification

The following four major variants were initially described (Figure 3).



**Figure 3** The four major variants of SLAP initially described by Snyder. (Permission Licence from Elsevier 3452920049505).

**Type I:** Intact labrum and biceps anchor but labral fraying and degeneration are present. It is commonly seen in middle-aged patients with concomitant rotator cuff tears.

**Type II:** Full detachment of the labrum and of the biceps anchor from the glenoid. It is important the differential diagnosis from the normal meniscoid appearance of the labrum. Also Type II lesions can be identified anteriorly, posteriorly or combined anterior and posterior to the biceps anchor.

**Type III:** Bucket-handle tear of the labrum with intact biceps

tendon anchor.

**Type IV:** Bucket-handle tears of the labrum but with extension to the biceps anchor.

Maffet and co-workers have expanded previous classification with 3 more types<sup>[24]</sup>.

**Type V:** Type II SLAP with concomitant Bankart lesion

**Type VI:** Separation of the biceps anchor with unstable flap tear

**Type VII:** SLAP II lesions that extend anteriorly beneath the middle glenohumeral ligament.

Finally, Nord and Ryu completed SLAP lesions classification with three more types<sup>[25]</sup>.

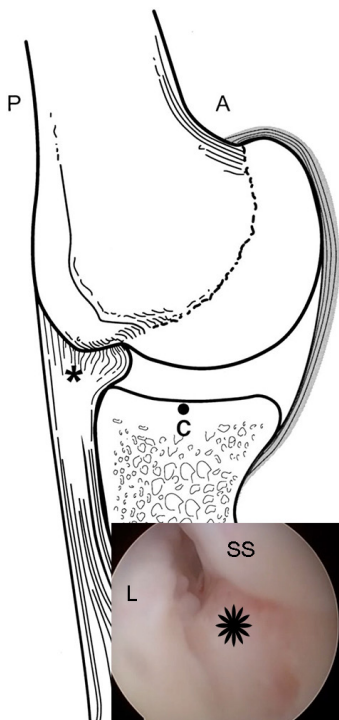
**Type VIII:** Extension of the SLAP lesion at the posterior labrum until 6 O' clock.

**Type IX:** 360° glenoid “pan-labral” injury.

**Type X:** Type II SLAP with concomitant reverse Bankart Lesion.

**Pathogenesis-Diagnosis**

Regarding the pathogenesis of SLAP lesions two main types of mechanisms have been proposed; acute or repetitive overuse injuries. Direct trauma including compression, forceful traction or even anterior shoulder dislocation or subluxation can result in SLAP lesions. On the other hand the repetitive overhead microtrauma can lead to the unique entity of “The Disabled Throwing Shoulder”<sup>[26]</sup>. It is well known that the overhead athletes have increased external rotation, decreased glenohumeral internal rotation (GIRD) [11°-18°], anterior capsuloligamentous laxity and posterior capsular contraction, resulting in postero-superior migration of the humeral head during the cocking position<sup>[27]</sup> (Figure 4). The late cocking phase of throwing is responsible for biceps root strain and possible tear in overhead athletes. Additional repetitive internal impingement in throwers and a “peel-back” phenomenon, that Burkhart reported, contributes to the pathology of this lesion<sup>[26]</sup>.



**Figure 4** Maximun abduction and external rotation in throwers causes internal impigement and leads to labrar (L) and concomitant rotator cuff tears (SS) (asterisk) (Permission licence from Elsevier 3452891245310 for the drawing).

The history of patients with SLAP lesions can be quite variable and despite careful clinical examination the majority of even recently proposed tests lacks of sensitivity and specificity leading to confusing results<sup>[28]</sup>. The most important clinical finding is localized pain that usually radiates to the anterior-lateral aspect of the humerus. In addition, pain on external rotation or late cocking phase of throwing combined with symptoms of internal derangement (popping, catching) and “dead arm” feeling also indicate possible increased posterior-superior translation. Weakness may also be present due to pain or possible nerve compression from a spinoglenoid cyst. The Modified Dynamic Labral Shear test (O’Driscoll test), the Biceps Load II test (Kim II), the O’Brien test, the Supine Flexion Resistance test and the Yegarson and Speed tests can be positive (Table 2).

The algorithm of diagnosis should always include plain radiographs in order to exclude other potential sources of shoulder pain such as arthritis or avascular necrosis. Despite magnetic resonance imaging (MRI) remains the preferred imaging technique its sensitivity in detecting SLAP tears is a subject of debate. In order to achieve accurate diagnosis, authors have proposed MRI examinations in abduction and external rotation of the shoulder<sup>[2]</sup> or combination of MRI and magnetic resonance arthrography (MRA) imaging<sup>[29]</sup>.

**Current Treatment Strategies of SLAP Lesions**

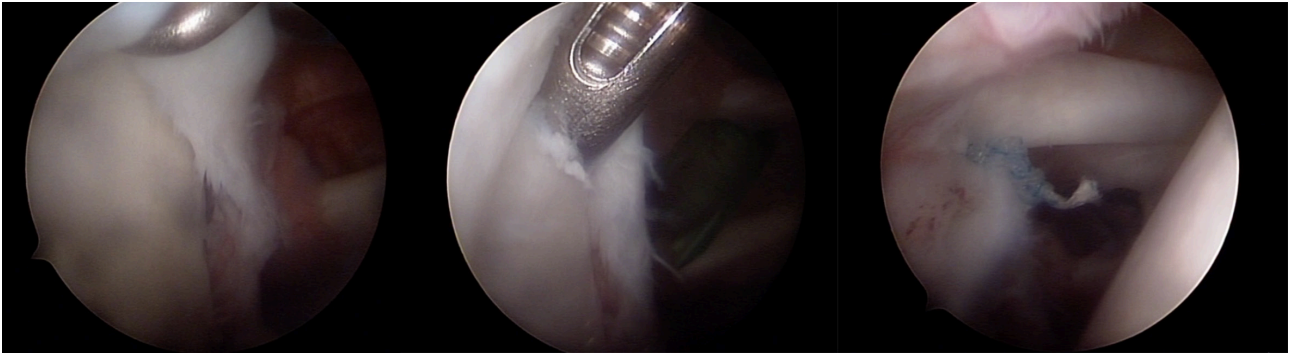
**Non-Surgical:** Nonsurgical treatment focuses on strengthening rotator cuff muscles and scapula stabilizers. Additional goals include management of associated shoulder pathology. The physical therapy focused on dealing with posterior capsule contraction (GIRD) and scapular rehabilitation in pitchers of league Baseball resulted in returning to previous activity levels in 90% of patients<sup>[27]</sup>. However, Edwards *et al* reported only 67% success of conservative treatment in overhead athletes<sup>[30]</sup>.

**Operative Treatment:** Surgical treatment is performed arthroscopically either in beach chair or lateral decubitus position. Main indications are establishment of diagnosis, failure of 3 months period of conservative treatment, inability to return to sports and evidence of suprascapular nerve compression<sup>[2]</sup>.

Regarding the surgical technique three main arthroscopic portals are usually adequate: a standard posterior viewing portal, an anterior portal at the superior border of the subscapularis tendon and the most important antero-superior rotator interval portal 1cm off the anterolateral tip of the acromion<sup>[31]</sup> (Figure 5). Trans-rotator cuff (Wilmington)<sup>[32]</sup> and Neviaser<sup>[33]</sup> portals have also been described in the international literature but the surgeon should avoid using cannulas with them. In addition, numerous stabilizing methods have been proposed including transosseous sutures, metal, peek or

**Table 2** Clinical tests positive in patients with possible SLAP Lesions.

Modified Dynamic Labral Shear Test (O’Driscoll test)	Flex the elbow to 90°, abduct the arm above 120° and externally rotated to tightness. While maintaining external rotation and horizontal abduction and lowering the arm from 120° to 60° a shear force to the labrum is produced and a painful click or catch is felt.
Biceps Load II test (Kim II)	Place the patient’s shoulder in 120° of abduction, the elbow in 90° of flexion, and the forearm in supination. Move the patient’s shoulder to end-range external rotation (apprehension position) and ask the patient to flex his elbow under resistance. A positive test is indicated as a reproduction of concordant pain during resisted elbow flexion.
The Supine Flexion Resistance Test positive	The patient performs a throwing motion against resistance in a supine position. Pain deep inside the shoulder joint or at the dorsal aspect of the shoulder is thought to be positive

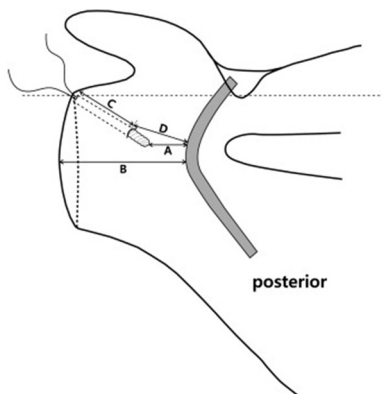


**Figure 5** SLAP V repair with suture anchors. Notice the Bankart lesion at the anterior rim of the glenoid.

bioabsorbable suture anchors, staples, tacks, screws and knotless anchors<sup>[34]</sup>. The preferred method of treatment differs and depends on the type of SLAP lesion (Table 3). However, despite the evolution of arthroscopic techniques the superior labral repair can be a demanding procedure resulting in articular cartilage damage<sup>[34]</sup> or suprascapular nerve injury either from suture passage<sup>[2]</sup> or from the anchor placement<sup>[35,36]</sup> (Figure 6).

**Table 3** SLAP Lesions Repair Algorithm.

SLAP I	Debridement
SLAP II	Re-attachment of the tear on the glenoid. Degenerative tears older patients-Biceps Tenotomy or Tenodesis
SLAP III	Resection of the unstable labrum Possible repair of the middle glenohumeral ligament
SLAP IV	a. <30% of Biceps tendon Involved-Debridement b. >30% of Biceps tendon involved -Young Patients-Tenodesis+Labral Repair -Older Patients-Labral Debridement+Tenotomy or Tenodesis



**Figure 6** Suture anchor's position can place suprascapular nerve at risk during SLAP Lesion repair. (Permission Licence from Elsevier 3452950079349)

Bioabsorbable tacks' application did not produce very promising results leading to persistent synovitis, cartilage damage or loose bodies release<sup>[37,38]</sup>. Bioabsorbable suture anchors have been widely used with better clinical results<sup>[34]</sup>, but the problems from early loosening and degradation were not totally eliminated<sup>[39]</sup>. Using poly-L-lactide (PLLA) suture anchors, authors have described up to 84% giant cell reaction<sup>[40]</sup> and statistically significant (25%) SLAP repair failure compared to non-absorbable materials<sup>[41]</sup>. Inevitably these reports boosted the effort of development of newer materials such as PEEK (polyetheretherketone) and calcium ceramics (tricalcium phosphate) anchors. However, a recent extensive review study

concluded that bioabsorbable anchors remain safe, efficient and consistent materials and the success of the operation depends mainly on the meticulous technique<sup>[42]</sup>.

Regarding suture configuration conflicting data have been published about their biomechanical behaviour. Studies support superiority of mattress sutures compared to simple ones and higher stiffness of dual than simple sutures<sup>[2]</sup>. Some authors have suggested that the bulky suture knot can be a source of pain especially in the narrow glenohumeral joint space of a thrower. For this reason the use of knotless anchors is becoming more popular<sup>[34]</sup> but their biomechanical strength has not been proven to be superior<sup>[43]</sup>. Finally, surgeons should avoid tightening the middle glenohumeral ligament (MGHL) and sublabral foramen closure that could cause significant loss of external rotation<sup>[34]</sup>. However, recently some authors suggest the use of proximal Buford MGHL to enhance repair combined with the release of the distal part of the ligament with promising results<sup>[44]</sup>.

Gorantla *et al* in a recent systematic review reported that arthroscopic repair of Type II SLAP lesions had excellent results in individuals and return to sports in up to 94% of cases. Nevertheless, non-predictable outcomes are expected in throwing or overhead athletes<sup>[45]</sup>. Again Sayde *et al* published superior results with anchor repair but lower rates of previous levels of performance in overhead athletes<sup>[46]</sup>.

Boileau *et al*<sup>[47]</sup> first compared Type II SLAP repair with suture anchors to biceps tenodesis. The authors preferred tenodesis in older (>30 y.o.) patients. In the repair group, the Constant Score was significantly improved; however 60% reported persistent pain and did not return to play. Biceps tenodesis resulted in 93% patients' satisfaction and 87% return to play. A very important factor that seems to affect final outcome is the patient's age. Alpert *et al* published similar clinical results of SLAP repair between patients over and under 40 years old<sup>[48]</sup>. Recently, Eugene *et al* reported that both biceps tenodesis and SLAP repair can provide good to excellent results if performed in appropriately selected patients. The authors focused on the age of the patient and performed suture repair in cases under 30 y.o.<sup>[49]</sup>. Finally most recent studies demonstrated higher failures rates, post-op stiffness and re-operations in older individuals<sup>[50]</sup>. These observations are in accordance with the surgical trends in the treatment of SLAP lesions in the USA where increasing numbers of tenodesis operations are performed in middle aged patients<sup>[51]</sup>.

## B. INTERVAL LESIONS AND LESIONS ASSOCIATED WITH ROTATOR CUFF TEARS

According to Habermeyer and Walch rotator interval lesions can be subdivided into three types: tendinitis, subluxation and isolated

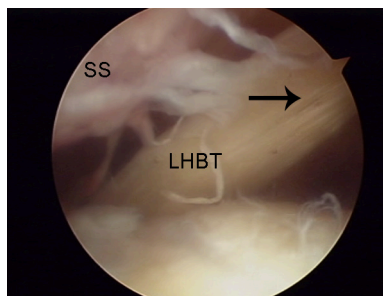
rupture (Table 1)<sup>[21]</sup>. In addition to this classification delamination, hypertrophy and hourglass deformity of the LHBT have also been described<sup>[52]</sup>.

**Pathogenesis-Diagnosis**

All previous conditions are usually part of co-existing shoulder pathology such as rotator cuff tears or impingement and have been typically characterized secondary (Figure 7). From the early ‘80s the severity of rotator cuff disease was correlated with the extent of inflammatory changes of the LHBT<sup>[53]</sup>, while later Miller and Savoie found that 74% of individuals with full-thickness rotator cuff tears had associated intraarticular lesions<sup>[54]</sup>. In an effort to understand the pathophysiology authors proposed models of cuff deficient shoulders that reproduced the degenerative changes of LHBT<sup>[55]</sup>.

Primary tendinitis has been estimated to be present in only 5% of all cases and can be diagnosed only by arthroscopy. Nevertheless, in 3-year experience Walch found “no primary lesion”<sup>[56]</sup>. Subluxation or dislocation mainly occurs when rotator interval sling or subscapularis tendon tears are present (Figure 8). Isolated ruptures are usually result of excessive tendinitis in patients over 50 years old; consequently leading to distal migration of the LHBT and to the characteristic “Popeye” deformity.

The clinical presentation of a patient is similar to a patient with rotator cuff pathology. The patients complain of progressive pain; initially during arm abduction that radiates at the anterolateral aspect of the humerus but later can be excessive during night. Beyond muscle force test examination other tests such as the Neer impingement test, the Hawkins sign, Jobe’s test and O’ Brien’s test are overlapping and can be positive in various shoulder conditions like rotator cuff tears and tendinitis, impingement and



**Figure 7** Supraspinatus tendon tear (SS) and concomitant delamination of the LHBT (arrow).

acromioclavicular arthrosis. In some cases injection in the bicipital groove with local anesthetic and corticosteroid solution can help differentiate LHBT tendinitis from other causes of anterior shoulder pain<sup>[57]</sup>.

Again imaging evaluation should start with plain radiographs of the shoulder to rule out glenohumeral degeneration, acromioclavicular arthrosis or other bony abnormalities. MRI allows visualization of the superior labral complex, the biceps tendon, the bicipital groove, the presence of any bony osteophytes and the condition of the rotator cuff tendons. Finally, ultrasound examination has high diagnostic value for the detection of tear, subluxation or dislocation of the LHBT but it is not sensitive for partial thickness tears or tendinitis and is an operator dependent technique.

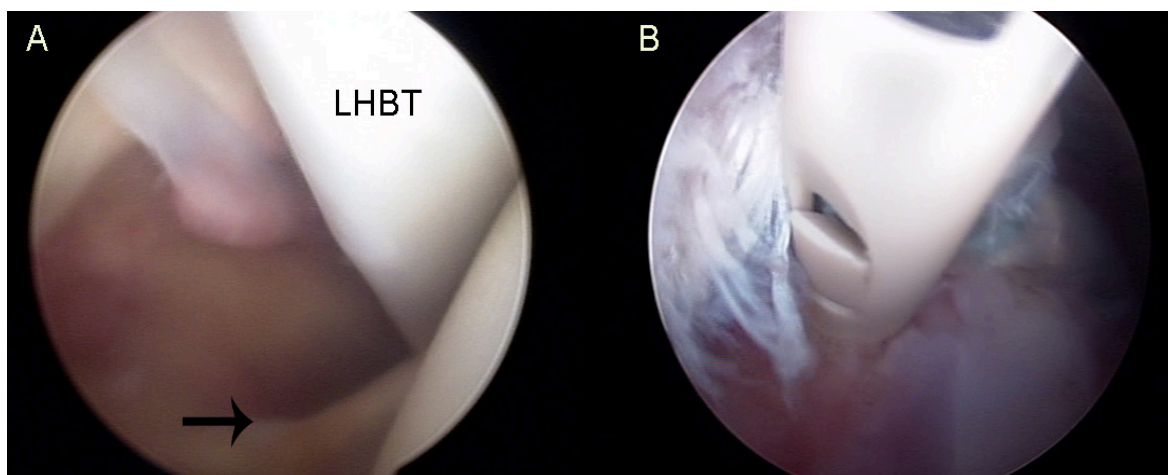
**Current Treatment Strategies of Interval Lesions-Lesions Associated with Rotator Cuff Tears**

Depending on the overall shoulder pathology, the LHBT lesions can be addressed either by nonoperative or tenotomy/tenodesis procedures.

**Non-Surgical:** Historically, biceps tendinitis was treated with weekly hydrocortisone injections under the transverse ligament<sup>[19]</sup>. However, these high frequency injections, in proximity to or inside the tendon, had in some cases adverse effects predisposing to tendon rupture<sup>[58]</sup>.

Usually patients with symptoms involving LHBT pathology should begin with conservative treatment, including oral anti-inflammatory medication, temporary immobilization, ice therapy, iontophoresis and rotator cuff strengthening exercises. Steroid injection with local anaesthetic into the groove under ultrasound guidance or in the subacromial space may have good clinical results<sup>[59]</sup>.

Non-surgical management has also been proposed in case of complete LHBT ruptures, especially in the elderly and at the non-dominant arm without significant functional impairment. Surgical treatment should be preserved only for cases with persistent muscle spasm and pain, occupations that require full supination strength, younger active patients and rarely in “unacceptable” Popeye Sign for cosmetic reasons<sup>[4,59]</sup>. However, some authors support that the LHBT ruptures may not always be benign with persistent pain and significant loss of supination, pronation and flexion being present (23%, 29% and 29% respectively)<sup>[60]</sup>. Comparative studies between conservative treatment and tenodesis in cases of spontaneous rupture of LHBT showed 78% better results in the operated group of patients<sup>[61]</sup>.



**Figure 8 A:** Subscapularis tendon tear (arrow) with complete LHBT tendon dislocation **B:** Tenodesis of the LHBT at the bicipital groove using knotless anchor and “lasso loop” stitches technique.

## Surgical Treatment

### Biceps Tenotomy

In 1990, Patte and Walch observed the analgesic effect of spontaneous rupture of the LHBT and proposed simple arthroscopic tenotomy as a palliative treatment in patients with irreparable rotator cuff tears (RCTs)<sup>[20]</sup>.

Therefore, tenotomy is a simple and easily reproducible technique that involves transection of the LHBT at its proximal insertion at the supraglenoid tubercle; this allows the tendon to retract away from the joint into the bicipital groove. In cases of hourglass deformity the biceps may not retract and approximately 1- 2 cm of the tendon has to be resected. Usually this technique provides predictable pain relief and does not alter the post-operative rehabilitation program after a combined rotator cuff tear repair. Recently, efforts are made to perform this procedure percutaneously under ultrasound guidance in cadavers<sup>[62]</sup>.

However, after simple biceps tenotomy the surgeon's major concerns are the possibility of post-operative presence of Popeye sign, cramping pain and loss of supination strength. Some authors report that biceps tenotomy during arthroscopic repair of RCTs may lead to Popeye sign in up to 70% of the cases. They also found that 37.5% of younger patients <40 years old complained of fatigue, discomfort, and soreness after resisted elbow flexion<sup>[63]</sup>. However, Karataglis *et al* evaluated with ultrasound the position and condition of the LHBT after simple tenotomy. It appeared that the natural history of the tenotomised LHBT is to tenodesis itself inside or just outside the bicipital groove, while its pre-operative condition and coexistence of subscapularis tears play a significant role in the occurrence of a Popeye sign<sup>[64]</sup>.

De Carli *et al* compared two groups of patients with concomitant rotator cuff tears that underwent tenotomy or tenodesis. Ultrasound evaluation revealed that in both groups the tendon was inside the groove in 80% and signs of vascularization were more evident after tenotomy<sup>[65]</sup>. The Popeye sign was more frequent in the tenotomy group but the overall functional results were equal. In general, authors did not confirm the superiority of LHBT tenodesis<sup>[66]</sup>.

In order to avoid previous complications Bradbury *et al* described a T-shaped tenotomy of the root of the LHBT (Figure 9). Biomechanical testing in cadavers showed that increased force was required in order to pull the created bulbous stump through the bicipital groove<sup>[67]</sup>. Finally, most recently Cho *et al* and Narvani *et al*<sup>[68]</sup> suggested the prevention of distal tendon retraction by performing a funnel-shaped or an anchor shaped tenotomy respectively<sup>[69]</sup>.

**Biceps Tenodesis:** Biceps tenodesis is performed in order to maintain the length-tension relationship of the biceps muscle and consequently prevent the muscle atrophy and preserve the normal contour. For this reason many authors believe that tenodesis should be used in younger, active patients, athletes and laborers with combined LHBT

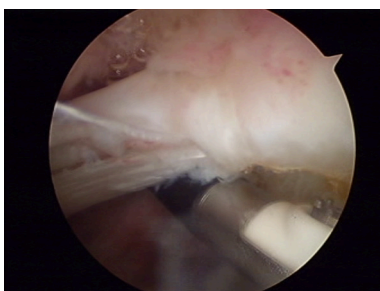


Figure 9 "Anchor-shaped like" tenotomy of the LHBT.

and rotator cuff pathology<sup>[10,20]</sup>. However, controversy remains about the method and location of fixation. Interference screws, suture anchors or soft tissue fixation method have been proposed for biceps tenodesis<sup>[10]</sup>.

Arthroscopic fixation with bioabsorbable screw at the proximal aspect of the bicipital groove has been described by Boileau *et al*<sup>[70]</sup>. The authors support that the strength averaged 90% of the contralateral arm and the biceps contour-shape was maintained in 95% of the cases. Further biomechanical studies enhanced the advantages of the screw fixation as they proved that it has the highest ultimate load to failure and the least amount of displacement on cyclic loading<sup>[71]</sup>.

All-arthroscopic proximal fixation with suture anchors is usually performed using the lasso loop technique within the bicipital groove<sup>[72]</sup> (Figure 8). It is a simple-safe technique, no additional portals are needed and it accurately restores length-tension relation. However this type and location of fixation may increase the rates of potential residual postoperative pain due to tenosynovitis within the biceps sheath. Despite good clinical results it offers low healing power perhaps due to side-to-side contact between tendon and bone<sup>[73]</sup>.

Recently some authors advocate the soft tissue tenodesis-LHBT transfer to the rotator cuff associated with a Roman Bridge (double pulley-suture bridges) repair<sup>[74]</sup>. Lafosse *et al* describe it as a "pulvertaft" like construct that also can maintain humeral head depression and compression<sup>[75]</sup>. Also, newer intra-cuff LHBT transfers have been described with very good final clinical results<sup>[69]</sup>. Further studies are needed to evaluate this method.

In 2005 Mazzocca *et al* supported that a positive "subpectoral biceps tendon test" indicates pathology inside the bicipital groove<sup>[76]</sup> and predisposes to premature failure of tenodesis within the groove. The authors also describe the technique of mini-open subpectoral biceps tenodesis using interference screw fixation (Figure 10). Short-term follow up showed excellent and promising long lasting results. Freedman *et al*<sup>[59]</sup> also supported that the location of tenodesis is more important than the method of fixation. Using suture anchor fixation of the LHBT with "lasso-loop" locking stitches the revision rates for the proximal arthroscopic and distal mini-open tenodesis were 35.7% and 2.7% respectively.

Cadaveric studies compared the stiffness and the ultimate load to failure of alternate fixation methods of the LHBT at the subpectoral region. Due to biomechanical measurements the interference screws and the newest intramedullary cortical button showed better resistance in cyclic loading and less fixation displacement compared

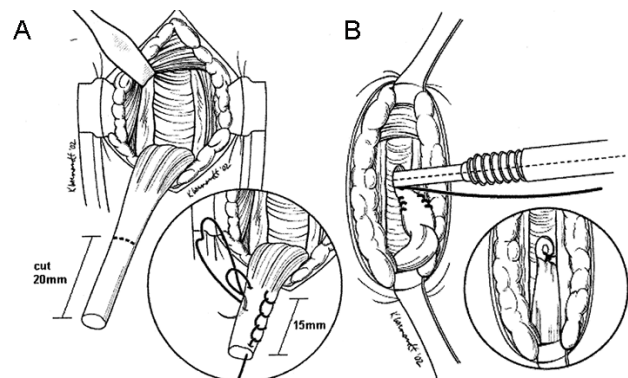


Figure 10 Open subpectoral biceps tenodesis using interference screw as described by Mazzocca (Permission Licence from Elsevier 3452601348925).

to cortical suture anchors<sup>[71,77,78]</sup>.

In accordance with previous publications, Nho *et al.*<sup>[79]</sup> reported significant low rates of complications (2.0%) after open subpectoral biceps tenodesis with absorbable interference screw in 353 patients and over a 3-year period of follow up. The advantages of the method are its simplicity, the maintenance of muscle tendon and soft tissue units, the preservation of the length-tension relationship, the distal removal of the tendon from the bicipital groove and the biomechanical strength advantages of having an interference screw.

#### Authors' Preferred Methods of Treatment

Origin-SLAP lesions are mainly treated with arthroscopic root restoration with anchors in young patients while biceps tenotomy and subsequent tenodesis is preferred in middle-aged population. Interval lesions are usually associated with concomitant rotator cuff tears and apart from conservative therapeutic protocols, the variance of operative treatment choices is quite large. The authors' preferred method of treatment is "anchor shaped like" tenotomy in older patients and in the presence of LHBT hypertrophy but always with intact subscapularis tendon. Proximal arthroscopic biceps tenodesis with anchors and "lasso loop" technique is preferred in younger patients or in cases with subscapularis tears.

## SUMMARY

LHBT lesions are common source of shoulder pain and often occur in combination with other shoulder pathology. A very useful classification, that also influences treatment strategy, is according to the anatomic location and the surrounding shoulder pathology. However, despite different treatment modalities from root restoration or simple tenotomy to tenodesis at the bicipital groove, subpectoral region or surrounding tissues using sutures, anchors or screws, the literature does not provide strong evidence to support one technique over the other.

## CONFLICT OF INTERESTS

There are no conflicts of interest with regard to the present study.

## REFERENCES

- Tuoheti Y, Itoi E, Minagawa H, Yamamoto N, Saito H, Seki N, Okada K, Shimada Y, Abe H. Attachment Types of the Long Head of the Biceps Tendon to the Glenoid Labrum and Their Relationships with the Glenohumeral Ligaments. *Arthrosc J Arthrosc Relat Surg* 2005; **21**(10): 1242-9
- Keener JD, Brophy RH. Superior labral tears of the shoulder: pathogenesis, evaluation, and treatment. *J Am Acad Orthop Surg* 2009; **17**(10): 627-37
- Rao AG, Kim TK, Chronopoulos E, McFarland EG. Anatomical variants in the anterosuperior aspect of the glenoid labrum: a statistical analysis of seventy-three cases. *J Bone Joint Surg Am* 2003; **85-A**(4): 653-9
- Elser F, Braun S, Dewing CB, Giphart JE, Millett PJ. Anatomy, Function, Injuries, and Treatment of the Long Head of the Biceps Brachii Tendon. *Arthrosc J Arthrosc Relat Surg* 2011; **27**(4): 581-92
- Hussain WM, Reddy D, Atanda A, Jones M, Schickendantz M, Terry MA. The longitudinal anatomy of the long head of the biceps tendon and implications on tenodesis. *Knee Surg Sports Traumatol Arthrosc* 2014; : 1-6
- Werner A, Mueller T, Boehm D, Gohlke F. The Stabilizing Sling for the Long Head of the Biceps Tendon in the Rotator Cuff Interval A Histoanatomic Study. *Am J Sports Med* 2000; **28**(1): 28-31
- Gleason PD, Beall DP, Sanders TG, Bond JL, Ly JQ, Holland LL, Pasque CB. The Transverse Humeral Ligament A Separate Anatomical Structure or a Continuation of the Osseous Attachment of the Rotator Cuff? *Am J Sports Med* 2006; **34**(1): 72-7
- Arai R, Mochizuki T, Yamaguchi K, Sugaya H, Kobayashi M, Nakamura T, Akita K. Functional anatomy of the superior glenohumeral and coracohumeral ligaments and the subscapularis tendon in view of stabilization of the long head of the biceps tendon. *J Shoulder Elbow Surg* 2010; **19**(1): 58-64
- Bicos J. Biomechanics and anatomy of the proximal biceps tendon. *Sports Med Arthrosc Rev* 2008; **16**(3): 111-7
- Nho SJ, Strauss EJ, Lenart BA, Provencher MT, Mazzocca AD, Verma NN, Romeo AA. Long head of the biceps tendinopathy: diagnosis and management. *J Am Acad Orthop Surg* 2010; **18**(11): 645-56
- Alpantaki K, McLaughlin D, Karagogeos D, Hadjipavlou A, Kontakis G. Sympathetic and sensory neural elements in the tendon of the long head of the biceps. *J Bone Joint Surg Am* 2005; **87**(7): 1580-3
- Eshuis R, De Gast A. Role of the long head of the biceps brachii muscle in axial humeral rotation control. *Clin Anat N Y N* 2012; **25**(6): 737-45
- Sakurai G, Ozaki J, Tomita Y, Nishimoto K, Tamai S. Electromyographic analysis of shoulder joint function of the biceps brachii muscle during isometric contraction. *Clin Orthop* 1998; **(354)**: 123-31
- Yamaguchi K, Riew KD, Galatz LM, Syme JA, Neviaser RJ. Biceps activity during shoulder motion: an electromyographic analysis. *Clin Orthop* 1997; **336**: 122-9
- Levy AS, Kelly BT, Lintner SA, Osbahr DC, Speer KP. Function of the long head of the biceps at the shoulder: electromyographic analysis. *J Shoulder Elb Surg Am Shoulder Elb Surg AI* 2001; **10**(3): 250-5
- Warner JJ, McMahon PJ. The role of the long head of the biceps brachii in superior stability of the glenohumeral joint. *J Bone Joint Surg Am* 1995; **77**(3): 366-72
- Kido T, Itoi E, Konno N, Sano A, Urayama M, Sato K. The depressor function of biceps on the head of the humerus in shoulders with tears of the rotator cuff. *J Bone Joint Surg Br* 2000; **82**(3): 416-9
- Thomas SJ, Reuther KE, Tucker JJ, Sarver JJ, Yannascoli SM, Caro AC, Voleti PB, Rooney SI, Glaser DL, Soslowsky LJ. Biceps Detachment Decreases Joint Damage in a Rotator Cuff Tear Rat Model. *Clin Orthop Relat Res* 2014; **472**(8): 2404-12
- Depalma AF. SURGICAL ANATOMY OF THE ROTATOR CUFF AND THE NATURAL HISTORY OF DEGENERATIVE PERIARTHRITIS. *Surg Clin North Am* 1963; **43**: 1507-20
- Ditsios K, Agathangelidis F, Boutsiadis A, Karataglis D, Papadopoulos P. Long head of the biceps pathology combined with rotator cuff tears. *Adv Orthop* 2012; **2012**: 405472
- Rockwood CA, Matsen FA, Wirth MA, Lippitt SB. The Shoulder, 2-Volume Set: Expert Consult: Online, Print, and DVD. 4 edition. Philadelphia, PA: Saunders; 2009
- Andrews JR, Carson WG, McLeod WD. Glenoid labrum tears related to the long head of the biceps. *Am J Sports Med* 1985; **13**(5): 337-41
- Snyder SJ, Karzel RP, Del Pizzo W, Ferkel RD, Friedman MJ. SLAP lesions of the shoulder. *Arthrosc J Arthrosc Relat Surg Off Publ Arthrosc Assoc N Am Int Arthrosc Assoc* 1990; **6**(4): 274-9
- Maffett MW, Gartsman GM, Moseley B. Superior labrum-biceps tendon complex lesions of the shoulder. *Am J Sports Med* 1995; **23**(1): 93-8
- Powell SE, Nord KD, Ryu RKN. The Diagnosis, Classification, and Treatment of SLAP Lesions. *Oper Tech Sports Med* 2012; **20**(1): 46-56
- Burkhart SS, Morgan CD, Kibler WB. The disabled throwing

- shoulder: Spectrum of pathology part I: Pathoanatomy and biomechanics. *Arthrosc J Arthrosc Relat Surg* 2003; **19(4)**: 404-20
- 27 Kibler WB, Kuhn JE, Wilk K, Sciascia A, Moore S, Laudner K, Ellenbecker T, Thigpen C, Uhl T. The Disabled Throwing Shoulder: Spectrum of Pathology-10-Year Update. *Arthrosc J Arthrosc Relat Surg* 2013; **29(1)**: 141-161.e26
- 28 Cook C, Beaty S, Kissenberth MJ, Siffri P, Pill SG, Hawkins RJ. Diagnostic accuracy of five orthopedic clinical tests for diagnosis of superior labrum anterior posterior (SLAP) lesions. *J Shoulder Elbow Surg* 2012; **21(1)**: 13-22
- 29 Amin MF, Youssef AO. The diagnostic value of magnetic resonance arthrography of the shoulder in detection and grading of SLAP lesions: Comparison with arthroscopic findings. *Eur J Radiol* 2012; **81(9)**: 2343-7
- 30 Edwards SL, Lee JA, Bell J-E, Packer JD, Ahmad CS, Levine WN, Bigliani LU, Blaine TA. Nonoperative Treatment of Superior Labrum Anterior Posterior Tears Improvements in Pain, Function, and Quality of Life. *Am J Sports Med* 2010; **38(7)**: 1456-61
- 31 Burkhart SS, Morgan CD, Kibler WB. The disabled throwing shoulder: Spectrum of Pathology Part II: Evaluation and treatment of SLAP lesions in throwers. *Arthrosc J Arthrosc Relat Surg* 2003; **19(5)**: 531-9
- 32 O'Brien SJ, Allen AA, Coleman SH, Drakos MC. The transrotator cuff approach to SLAP lesions: Technical aspects for repair and a clinical follow-up of 31 patients at a minimum of 2 years. *Arthrosc J Arthrosc Relat Surg* 2002; **18(4)**: 372-7
- 33 Selby RM, Altchek DW, Di Giacomo G. The Di Giacomo Technique: Simplified Suture Passing in SLAP Repair. *Arthrosc J Arthrosc Relat Surg* 2007; **23(4)**: 439.e1-439.e2
- 34 Knesek M, Skendzel JG, Dines JS, Altchek DW, Allen AA, Bedi A. Diagnosis and Management of Superior Labral Anterior Posterior Tears in Throwing Athletes. *Am J Sports Med* 2013; **41(2)**: 444-60.
- 35 Kim S-H, Koh Y-G, Sung C-H, Moon H-K, Park Y-S. Iatrogenic Suprascapular Nerve Injury After Repair of Type II SLAP Lesion. *Arthrosc J Arthrosc Relat Surg* 2010; **26(7)**: 1005-8
- 36 Koh KH, Park WH, Lim TK, Yoo JC. Medial perforation of the glenoid neck following SLAP repair places the suprascapular nerve at risk: a cadaveric study. *J Shoulder Elbow Surg* 2011; **20(2)**: 245-50
- 37 Sassmannshausen G, Sukay M, Mair SD. Broken or Dislodged Poly-L-Lactic Acid Bioabsorbable Tacks in Patients After SLAP Lesion Surgery. *Arthrosc J Arthrosc Relat Surg* 2006; **22(6)**: 615-9
- 38 Wilkerson JP, Zvijac JE, Uribe JW, Schürhoff MR, Green JB. Failure of polymerized lactic acid tacks in shoulder surgery. *J Shoulder Elbow Surg* 2003; **12(2)**: 117-21
- 39 Nho SJ, Provencher MT, Seroyer ST, Romeo AA. Bioabsorbable Anchors in Glenohumeral Shoulder Surgery. *Arthrosc J Arthrosc Relat Surg* 2009; **25(7)**: 788-93
- 40 McCarty LP, Buss DD, Datta MW, Freehill MQ, Giveans MR. Complications observed following labral or rotator cuff repair with use of poly-L-lactic acid implants. *J Bone Joint Surg Am* 2013; **95(6)**: 507-11
- 41 Park MJ, Hsu JE, Harper C, Sennett BJ, Huffman GR. Poly-L/D-Lactic Acid Anchors Are Associated With Reoperation and Failure of SLAP Repairs. *Arthrosc J Arthrosc Relat Surg* 2011; **27(10)**: 1335-40
- 42 Dhawan A, Ghodadra N, Karas V, Salata MJ, Cole BJ. Complications of Bioabsorbable Suture Anchors in the Shoulder. *Am J Sports Med* 2012; **40(6)**: 1424-30
- 43 Sileo MJ, Lee SJ, Kremenic IJ, Orishimo K, Ben-Avi S, McHugh M, Nicholas SJ. Biomechanical Comparison of a Knotless Suture Anchor With Standard Suture Anchor in the Repair of Type II SLAP Tears. *Arthrosc J Arthrosc Relat Surg* 2009; **25(4)**: 348-54
- 44 Crockett HC, Wingert NC, Wright JM, Bonner KF. Repair of SLAP Lesions Associated With a Buford Complex: A Novel Surgical Technique. *Arthrosc J Arthrosc Relat Surg* 2011; **27(3)**: 314-21
- 45 Gorantla K, Gill C, Wright RW. The Outcome of Type II SLAP Repair: A Systematic Review. *Arthrosc J Arthrosc Relat Surg* 2010; **26(4)**: 537-45
- 46 Sayde WM, Cohen SB, Ciccotti MG, Dodson CC. Return to Play After Type II Superior Labral Anterior-Posterior Lesion Repairs in Athletes: A Systematic Review. *Clin Orthop Relat Res* 2012; **470(6)**: 1595-600
- 47 Boileau P, Parratte S, Chuinard C, Roussanne Y, Shia D, Bicknell R. Arthroscopic Treatment of Isolated Type II SLAP Lesions Biceps Tenodesis as an Alternative to Reinsertion. *Am J Sports Med* 2009; **37(5)**: 929-36
- 48 Alpert JM, Wuerz TH, O'Donnell TFX, Carroll KM, Brucker NN, Gill TJ. The effect of age on the outcomes of arthroscopic repair of type II superior labral anterior and posterior lesions. *Am J Sports Med* 2010; **38(11)**: 2299-303
- 49 Ek ETH, Shi LL, Tompson JD, Freehill MT, Warner JJP. Surgical treatment of isolated type II superior labrum anterior-posterior (SLAP) lesions: repair versus biceps tenodesis. *J Shoulder Elbow Surg* 2014; **23(7)**: 1059-65
- 50 Erickson J, Lavery K, Monica J, Gatt C, Dhawan A. Surgical Treatment of Symptomatic Superior Labrum Anterior-Posterior Tears in Patients Older Than 40 Years A Systematic Review. *Am J Sports Med* 2014; : 0363546514536874
- 51 Patterson BM, Creighton RA, Spang JT, Roberson JR, Kamath GV. Surgical Trends in the Treatment of Superior Labrum Anterior and Posterior Lesions of the Shoulder Analysis of Data From the American Board of Orthopaedic Surgery Certification Examination Database. *Am J Sports Med* 2014; : 0363546514534939
- 52 Boileau P, Ahrens PM, Hatzidakis AM. Entrapment of the long head of the biceps tendon: the hourglass biceps-a cause of pain and locking of the shoulder. *J Shoulder Elbow Surg* 2004; **13(3)**: 249-57
- 53 Neviasser TJ, Neviasser RJ, Neviasser JS, Neviasser JS. The four-in-one arthroplasty for the painful arc syndrome. *Clin Orthop* 1982; **163**: 107-12
- 54 Miller C, Savoie FH. Glenohumeral abnormalities associated with full-thickness tears of the rotator cuff. *Orthop Rev* 1994; **23(2)**: 159-62
- 55 Refior HJ, Sowa D. Long tendon of the biceps brachii: sites of predilection for degenerative lesions. *J Shoulder Elb Surg Am Shoulder Elb Surg* 1995; **4(6)**: 436-40
- 56 Walch G, Edwards TB, Boulahia A, Nové-Josserand L, Neyton L, Szabo I. Arthroscopic tenotomy of the long head of the biceps in the treatment of rotator cuff tears: Clinical and radiographic results of 307 cases. *J Shoulder Elbow Surg* 2005; **14(3)**: 238-46.
- 57 Khazzam M, George MS, Churchill RS, Kuhn JE. Disorders of the long head of biceps tendon. *J Shoulder Elbow Surg* 2012; **21(1)**: 136-45
- 58 Kennedy JC, Willis RB. The effects of local steroid injections on tendons: a biomechanical and microscopic correlative study. *Am J Sports Med* 1976; **4(1)**: 11-21
- 59 Friedman DJM\*, Dunn JC, Higgins LD, Warner JJP. Proximal Biceps Tendon: Injuries and Management. *Sports Med Arthrosc Rev Sept* 2008 2008; **16(3)**: 162-9
- 60 Deutch SR, Gelineck J, Johannsen HV, Sneppen O. Permanent disabilities in the displaced muscle from rupture of the long head tendon of the biceps. *Scand J Med Sci Sports* 2005; **15(3)**: 159-62
- 61 Mariani EM, Cofield RH, Askew LJ, Li GP, Chao EY. Rupture of the tendon of the long head of the biceps brachii. Surgical versus nonsurgical treatment. *Clin Orthop* 1988; **228**: 233-9
- 62 Aly A-R, Rajasekaran S, Mohamed A, Beavis C, Obaid H. Feasibility of ultrasound-guided percutaneous tenotomy of the long head of the biceps tendon-A pilot cadaveric study. *J Clin Ultrasound* 2014; : n/a-n/a



- 63 Kelly AM, Drakos MC, Fealy S, Taylor SA, O'Brien SJ. Arthroscopic release of the long head of the biceps tendon: functional outcome and clinical results. *Am J Sports Med* 2005; **33**(2): 208-13
- 64 Karataglis D, Papadopoulos P, Boutsiadis A, Fotiadou A, Ditsios K, Hatzokos I, Christodoulou A. Ultrasound evaluation of the distal migration of the long head of biceps tendon following tenotomy in patients undergoing arthroscopic repair of tears of the rotator cuff. *J Bone Joint Surg Br* 2012; **94**(11): 1534-9
- 65 Carli AD, Vadalà A, Zanzotto E, Zampar G, Vetrano M, Iorio R, Ferretti A. Reparable rotator cuff tears with concomitant long-head biceps lesions: tenotomy or tenotomy/tenodesis? *Knee Surg Sports Traumatol Arthrosc* 2012; **20**(12): 2553-8
- 66 Hsu AR, Ghodadra NS, Provencher CMT, Lewis PB, Bach BR. Biceps tenotomy versus tenodesis: a review of clinical outcomes and biomechanical results. *J Shoulder Elbow Surg* 2011; **20**(2): 326-32
- 67 Bradbury T, Dunn WR, Kuhn JE. Preventing the Popeye Deformity After Release of the Long Head of the Biceps Tendon: An Alternative Technique and Biomechanical Evaluation. *Arthrosc J Arthrosc Relat Surg* 2008; **24**(10): 1099-102
- 68 Narvani AA, Atoun E, Van Tongel A, Sforza G, Levy O. The "Anchor Shape" Technique for Long Head of the Biceps Tenotomy to Avoid the Popeye Deformity. *Arthrosc Tech* 2013; **2**(2): e167-e170
- 69 Cho NS, Cha SW, Rhee YG. Funnel Tenotomy Versus Intracuff Tenodesis for Lesions of the Long Head of the Biceps Tendon Associated With Rotator Cuff Tears. *Am J Sports Med* 2014; **42**(5): 1161-8
- 70 Boileau P, Krishnan SG, Coste J-S, Walch G. Arthroscopic biceps tenodesis: a new technique using bioabsorbable interference screw fixation. *Arthrosc J Arthrosc Relat Surg Off Publ Arthrosc Assoc N Am Int Arthrosc Assoc* 2002; **18**(9): 1002-12
- 71 Golish SR, Caldwell III PE, Miller MD, Singanamala N, Ranawat AS, Treme G, Pearson SE, Costic R, Sekiya JK. Interference Screw Versus Suture Anchor Fixation for Subpectoral Tenodesis of the Proximal Biceps Tendon: A Cadaveric Study. *Arthrosc J Arthrosc Relat Surg* 2008; **24**(10): 1103-8
- 72 Lafosse L, Van Raebroeckx A, Brzoska R. A New Technique to Improve Tissue Grip: "The Lasso-Loop Stitch." *Arthrosc J Arthrosc Relat Surg* 2006; **22**(11): 1246.e1-1246.e3
- 73 Shon MS, Koh KH, Lim TK, Lee SW, Park YE, Yoo JC. Arthroscopic Suture Anchor Tenodesis: Loop-Suture Technique. *Arthrosc Tech* 2013; **2**(2): e105-e110
- 74 Franceschi F, Longo UG, Ruzzini L, Rizzello G, Maffulli N, Denaro V. Soft tissue tenodesis of the long head of the biceps tendon associated to the Roman Bridge repair. *BMC Musculoskelet Disord* 2008; **9**: 78
- 75 Lafosse L, Shah AA, Butler RB, Fowler RL. Arthroscopic biceps tenodesis to supraspinatus tendon: technical note. *Am J Orthop Belle Mead NJ* 2011; **40**(7): 345-7
- 76 Mazzocca AD, Rios CG, Romeo AA, Arciero RA. Subpectoral Biceps Tenodesis With Interference Screw Fixation. *Arthrosc J Arthrosc Relat Surg* 2005; **21**(7): 896.e1-896.e7
- 77 Patzer T, Santo G, Olender GD, Wellmann M, Hurschler C, Schofer MD. Suprapectoral or subpectoral position for biceps tenodesis: biomechanical comparison of four different techniques in both positions. *J Shoulder Elbow Surg* 2012; **21**(1): 116-25
- 78 Buchholz A, Martetschläger F, Siebenlist S, Sandmann GH, Hapfelmeier A, Lenich A, Millett PJ, Stöckle U, Elser F. Biomechanical Comparison of Intramedullary Cortical Button Fixation and Interference Screw Technique for Subpectoral Biceps Tenodesis. *Arthrosc J Arthrosc Relat Surg* 2013; **29**(5): 845-53
- 79 Nho SJ, Reiff SN, Verma NN, Slabaugh MA, Mazzocca AD, Romeo AA. Complications associated with subpectoral biceps tenodesis: Low rates of incidence following surgery. *J Shoulder Elbow Surg* 2010; **19**(5): 764-8

**Peer reviewers:** Thomas Nau, Ludwig Boltzmann Institute for Experimental and Clinical Traumatology, Austrian Cluster for Tissue Engineering, Donaueschingenstrasse, 1200 Vienna, Austria; Mattia Loppini, MD, Orthopaedic and Traumatology, Campus Bio-Medico University, Via Alvaro del Portillo 200, 00128 Rome, Italy; Hede Yan M.D., Ph.D, Department of Orthopaedics, The 2nd Affiliated Hospital of Wenzhou Medical University, 109 West Xueyuan Road, Lucheng District, Wenzhou, Zhejiang Province, 276300, China; Pauline Siew Mei Lai, Senior Lecturer, Department of Primary Care Medicine, Faculty of Medicine, University of Malaya, 50603 Kuala Lumpur, Malaysia.