

Adult Spinal Deformity: Sagittal Imbalance

Cavanilles-Walker JM, Ballester C, Iborra M, Ubierna MT, Tomasi SO

Cavanilles-Walker JM, Ballester C, Iborra M, Ubierna MT, Hospital Universitari Germans Trias i Pujol, Badalona (Barcelona) Spain, Department of Orthopaedic Surgery and Traumatology, Spine Unit, Crta Canyet s/n 08916, Badalona, Spain

Tomasi SO, Department of Neurosurgery, Christian Doppler medical Center, Paracelsus Medical University, Salzburg, Austria

Correspondence to: Tomasi SO, MD, Department of Neurosurgery, Christian Doppler medical Center, Paracelsus Medical University, Salzburg, Austria

Email: ottavio.tomasi@gmail.com

Telephone: +34-934978927

Received: June 13, 2014

Revised: August 4, 2014

Accepted: August 9, 2014

Published online: October 5, 2014

ABSTRACT

Spinal sagittal imbalance, deformity of the spine in the sagittal plane, is nowadays a major cause of pain and disability among patients presenting to the spine clinic in daily practice. Normal sagittal spinal balance is a result of mutual articulation of the pelvis and the spine in the sagittal plane. Sagittal imbalance of the spine could be related to many spinal pathologies interesting primarily the spine or could appear after an instrumentation spinal surgery. Variations in the spine sagittal alignment can be compensated by compensatory mechanisms occurring in the spine, pelvis and lower limb areas. The main objective of these mechanisms is to allow the patient to keep an erect position within the cone of economy in an energy-efficient way. Once a spinal deformity surpasses these compensatory mechanisms surgical intervention is often requested. In this paper the Authors performed comprehensive a critical analysis of the rigidity of the deformity, including the spinal and pelvic parameters. The compensatory mechanisms are paramount in order to be able to offer a tailored solution to these patients. Since conservative measures fail in most patients, successful management of these patients requires achieving fusion of a balanced spine. Appropriate preoperative optimization as well as appropriate surgical preoperative planning are critical in order to avoid potential complications. Selecting the appropriate surgical

technique to achieve spinal balance is crucial to success.

© 2014 ACT. All rights reserved.

Key words: Sagittal balance; Imbalance; Adult spinal deformity; Pelvic parameters

Cavanilles-Walker JM, Ballester C, Iborra M, Ubierna MT, Tomasi SO. Adult Spinal Deformity: Sagittal Imbalance. *International Journal of Orthopaedics* 2014; 1(3): 64-72 Available from: URL: <http://www.ghrnet.org/index.php/ijo/article/view/889>

INTRODUCTION

Spinal sagittal imbalance, deformity of the spine in the sagittal plane, is nowadays a major cause of pain and disability among patients presenting to the spine clinic in daily practice. Normal sagittal spinal balance is a result of mutual articulation of the pelvis and the spine in the sagittal plane. A normal thoracic spine should exhibit between 10° and 40° of kyphosis while the lumbar spine should be in 40° to 60° of lordosis (Figure 1)^[1,2], although these figures may vary significantly in the healthy population making it difficult to assign normative values. The main purpose of these lordotic and kyphotic spine segments is to balance the head over the pelvis in an energy-efficient position^[3,4] allowing the C7 plumb line, a vertical line drawn from the center of the C7 vertebral body, to pass within a few millimeters of the posterior-superior corner of S1^[5,6].

By convention, positive sagittal balance occurs when the C7 plumb line falls anterior to the posterior-superior corner of the S1 endplate. Negative sagittal balance occurs when the C7 plumb line falls posterior to this point^[7,8]. Recent studies have shown sagittal balance to be the most important and reliable radiographic predictor of clinical health status in the adult patient presenting with spinal deformity. Positive sagittal balance is the radiographic parameter that is most highly correlated with adverse health status outcome^[9].

The notion of energy-efficient position is closely correlated to the concept of “cone of economy” introduced by Dubousset^[3] (Figure 2). When in the center of this cone the body may remain in an

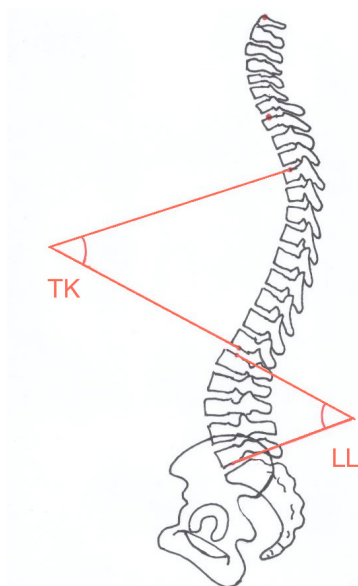


Figure 1 Normal thoracic kyphosis (T4-T12) should be between 10° and 40° while the lumbar lordosis should range between 40° to 60° (L1-S1).

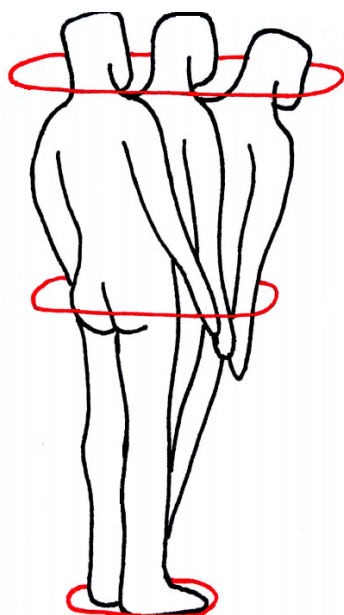


Figure 2 Head in the center of this “cone of economy” the body may remain in an ergonomically favorable erect position. Larger deviations outside this cone will require external support to be rebalanced.

ergonomically favorable erect position. However, larger deviations will require greater energy use to maintain a standing position and can be rebalanced without external support. When the trunk extends past this cone, external support is required to retain the head over the pelvis. Most patients with symptomatic sagittal plane deformity present with a sagittal balance at the periphery of this cone leading to an increased effort of accessory musculature to maintain the head over the pelvis leading to fatigue and pain especially with prolonged activity^[10-12].

As sagittal imbalance progresses different compensatory mechanisms such as the pelvic retroversion, hip extension and knee flexion are used in order to restore and maintain sagittal balance. Once a spinal deformity surpasses these compensatory mechanisms surgical intervention is often requested.

CAUSES

Sagittal imbalance of the spine is mainly related to any underlying pathology causing loss of lumbar lordosis (LL) such as multilevel degenerative disk disease, ankylosing spondylitis, diffuse idiopathic skeletal hyperostosis, osteoporosis, tumor, trauma, or infection (Figure 3)^[13]. Secondary causes include iatrogenic flat back syndrome being attributed to the use in the past of distraction instrumentations such as the Harrington rods^[14,15]. Nowadays iatrogenic flat back syndrome is more frequent due to lack of recreating the appropriate LL accordingly to the patient’s PI. In other cases loss of LL appears following spinal fusion surgery through an area of pseudarthrosis or through a degenerated segment adjacent to a previous fusion.

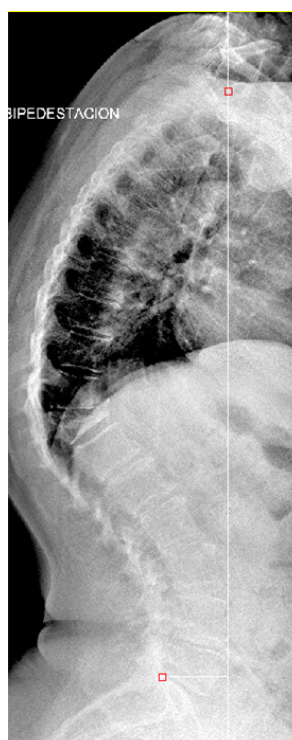

Figure 3 Sagittal imbalance in a 63 year-old woman secondary to a T11 fracture.

IMAGING STUDIES

Standard full-length 36-inch anteroposterior and lateral radiographs should be performed in all patients with suspected sagittal imbalance. Horton *et al*^[16] reported the clavicle position; in which the patient stands with both hips and knees fully extended, the elbows fully flexed, the wrists flexed with the hands in a relaxed fist placed into the supraclavicular fossa without any external support as the best patient position for the study of sagittal and coronal deformity resulting in the most accurate measurements and minimized repeated radiographic exposures. Sagittal balance is basically determined by the C7 plumb line. The mean C7 plumb line offset from the posterior-superior corner of S1 has been found to be 0.5 cm (Figure 4). An offset >2.5 cm anteriorly or posteriorly is considered to be abnormal^[17]. Different components such as the thoracic kyphosis (TK), the LL and the pelvis help to define the overall sagittal balance. TK is measured from the superior endplate of T4 to the inferior endplate of T12 ranging between 10° to 40°. LL is measured from the superior end plate of L1 to the end plate of S1 usually ranging from 40° to

60^[18]. A significant chain of interdependence exists between the pelvic and spinal parameters^[19]. The influence of the pelvis on spinal sagittal alignment has been described, among others, by Duval-Beaupère and Legaye *et al*^[20] introducing the pelvic incidence (PI), pelvic tilt^[PT], and sacral slope (SS) angles to describe the shape and orientation of the pelvis (Figure 5).

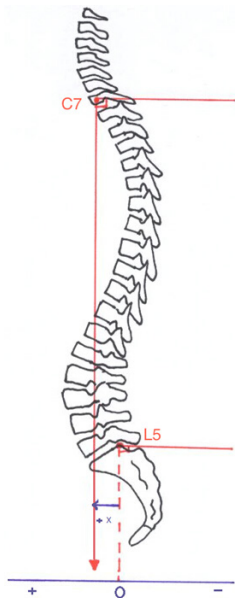


Figure 4 Sagittal balance is determined by the C7 plumb line which is a vertical line drawn from the center of the C7 vertebral body running parallel to the edge of the radiograph. The normal C7 plumb line passes within a few millimeters of the posterior-superior corner of S1. Positive sagittal balance occurs when the C7 plumb line falls anterior to the posterior-superior corner of the S1 endplate. Negative sagittal balance occurs when the C7 plumb line falls posterior to this point.

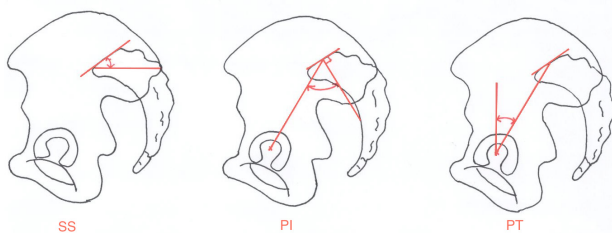


Figure 5 The pelvic incidence (PI), pelvic tilt (PT), and sacral slope (SS) angles are parameters used to describe the shape and orientation of the pelvis conditioning spinal sagittal balance.

The PI is a non-positional anatomical parameter defined as the angle between the line perpendicular to the sacral plate at its midpoint and the line connecting this point to the axis of rotation of the femoral head^[20]. The PI angle determines the relative position of the sacral plate in relation to the femoral heads and determines the remaining variable parameters being equal to the sum of SS+PT^[19, 20].

Patients with a low PI present a pelvis with a very short pelvic ring on the anterior–posterior (AP) diameter with the femoral heads placed just below the sacral plate. Inversely, a pelvis with a high PI has a large AP axis. The femoral heads are placed ahead the midpoint of the sacral plate. The PI angle is unique to each individual and becomes set at the end of growth. There is, thus, no such thing as good or bad pelvic incidence angle^[21]. LL is closely related to the orientation of the pelvis as determined by the PI angle^[20].

The SS is a positional parameter defined as the angle between

the superior endplate of S1 and a horizontal line extending from the anterior-inferior corner of the S1 endplate. The degree of the sacral slope determines the position of the lumbar spine, since the sacral plateau forms the base of the spine^[20,22].

PT is a positional parameter defined as the angle between the line connecting the midpoint of the superior sacral end plate to the femoral rotational axis and the line extending vertically from the femoral rotational axis. It denotes the spatial orientation of the pelvis, which varies according to position, with a greater or lesser degree of tilt forwards (pelvic anteversion) or backwards (pelvic retroversion) in relation to a transverse axis passing through the two femoral heads. The greater the angle of pelvic tilt, the further the center of gravity is projected behind the femoral heads^[23,24].

The correlation between radiographic parameters and self-reported pain and disability [Health Related Quality of Life (HRQL)] tools is well documented. In a review of 352 sagittal deformity patients, with and without previous arthrodesis, Glassman *et al*^[9] studied the effect of C7 plumb line offset on HRQL measures reporting adverse HRQL scores to be significantly correlated with increasing positive C7 plumb line offset. Lafage *et al*^[25] analyzed the coronal and sagittal radiographs of 125 patients presenting sagittal deformity with and without previous arthrodesis in order to identify the parameters most correlated to HRQL measures using the ODI, Scoliosis Research Society questionnaire, and SF-12. Results revealed that C7 plumb line offset and PT had a strong correlation with each outcome measure.

SAGITTAL IMBALANCE CASCADE

Variations in the spine sagittal alignment can be compensated by compensatory mechanisms occurring in the spine, pelvis and lower limb areas. The main objective of these mechanisms is to allow the patient to keep an erect position within the cone of economy in an energy-efficient way.

Once sagittal imbalance has started the pelvis tilts backwards (pelvic retroversion)^[26-28] bringing the C7 plumb line backwards resulting in extension of the hips. This pelvic retroversion makes PT increase putting the femoral heads forward and the sacrum and the spine backwards allowing the C7 plumb line to stay behind the femoral heads. Pelvic incidence determines the global capacity of pelvic retroversion. Considering that $PI=PT+SS$ and that SS cannot be a negative number in standing position, the pelvis can tilt more with a high PI than with a low PI, since there is a much wider range through which adaptation can occur^[29]. The full body is now balanced but it is a compensated balance^[30], which is less efficient. At the same time the posterior spine muscles act as a posterior tension band trying to restore some LL. The adjacent segments of the kyphotic spine are hyperextended allowing for the compensation of anterior translation of the C7 plumb line. This hyperextension leads to reduction of TK in the young patients with flexible spines. (Figure 6) Spine hyperextension is an energy consuming process that generates increase of stresses on posterior structures resulting in risk of retrolisthesis, facet joints overstress and even sometimes isthmic lysis^[30]. When pelvis backward rotation and spine hyperextension are not enough to keep the C7 plumb line behind the femoral heads, the only solution to keep the gravity line between the two feet is to bend the knees. This process needs good psoas and quadriceps muscles activity, which is energy consuming again and not an efficient situation. When knee flexion fails to put the C7 plumb line behind femoral heads, the full body is now in a decompensated balance, the use of external support (e.g., crutches, walker) is often the only way to keep the balance^[30].

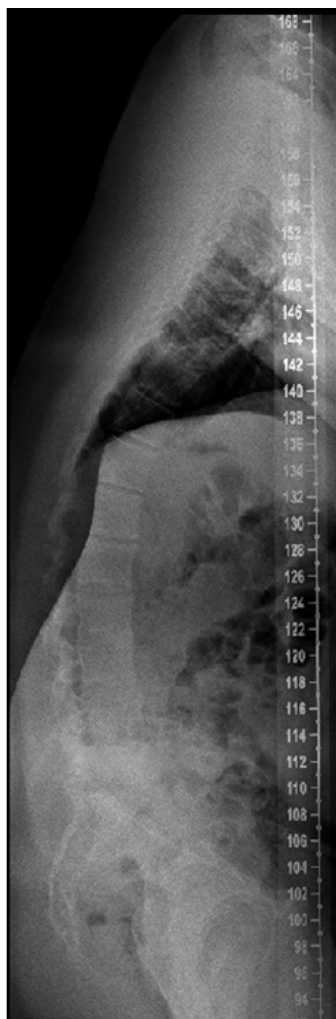

Figure 6 Sagittal imbalance in a 17 year-old boy. The patient had a severe lumbar canal stenosis at L3-4 and L4-5. In order to increase the canal area at this level the patient straightened the lumbar spine losing lumbar lordosis (7°) thus falling into sagittal imbalance. Note that all compensatory mechanisms are present: diminished SS (3°), increased PT (41°) for a PI of 45° , hip extension and hyperextension of the thoracic spine leading to a thoracic lordosis.

Thus, in the most severely imbalanced cases, the patients will present with all signs previously described: trunk tilted forward, retroversion of the pelvis, extension of the hips and flexion of the knees.

MANAGEMENT

Nonsurgical Management

Symptomatic deformity is often unresponsive to nonsurgical treatment. Patients with back pain and sagittal imbalance may show little or only temporary improvement with physical therapy programs, selective nerve root blocks, facet joint injections, epidural steroid injections or bracing^[31,32].

Surgical Management

Surgery is the mainstay of treatment for patients with sagittal deformity. Indications include failure of nonsurgical treatment, curve progression, back pain, radicular symptoms and significant cosmetic deformity. The goals of surgery are to achieve a solid fusion with a balanced spine in both sagittal and coronal planes, relieve pain, and prevent progression. Several studies have shown that adequate

restoration of sagittal plane alignment is necessary to significantly improve clinical outcome and avoid subsequent pseudarthrosis^[33-35].

Prior to surgery, the patient should be evaluated for risk factors such as pulmonary and cardiac disease, osteoporosis, smoking, and malnutrition. Careful consideration should be given to especially older patients due to the high incidence of pseudarthrosis and complications^[25,36]. The overall prevalence of pseudarthrosis following long-construct adult spinal deformity instrumentation and fusion to S1 has been reported to be 24%^[35]. Relative contraindications to major spinal reconstructive surgery include psychiatric disease, diabetes, osteoporosis, substantial cardiopulmonary disease, and poor family or social support^[37]. Another risk factor is hip osteoarthritis, which has been associated with a significantly higher overall rate of pseudarthrosis^[35].

Flexibility of the spine should be assessed clinically and radiologically. Patients' standing coronal and/or sagittal deformity may decrease in supine or prone position due to mobile segments. Standing long-cassette anteroposterior and lateral radiographs, supine bending, lateral fulcrum and lateral flexion and extension radiographs may demonstrate the flexibility of the deformity. Consideration of the spinopelvic parameters is critical in the surgical planning. Bridwell^[38] classified spinal deformities into three categories based on curve flexibility: totally flexible, partially through mobile segments, and fixed deformity with no correction in the recumbent position.

Flexible deformities can be addressed with anterior-posterior or posterior only surgery not requiring any osteotomy^[14]. Sagittal balance is improved by lengthening the anterior column, either through an anterior or a posterior approach, using cages, structural allograft or structural autograft. The posterior column is then addressed with laminectomies when there is evidence of stenosis, facetectomies, and fusion with instrumentation.

Fixed deformities can be managed by anterior-only, anterior and posterior combined and posterior-only approaches. With recent advances in instrumentation and techniques posterior-only approaches became very popular in recent years. Numerous studies supporting the safety and efficacy of a posterior-only approach for the treatment of all spinal deformities have been published. A recent radiographic analysis comparing posterior-only and combined anterior-posterior approaches has shown equally effective correction with the posterior-only approach^[39].

In adults with spinal deformity, fusion across the L5-S1 junction is recommended in the presence of lumbosacral pathology, such as postlaminectomy defects, lumbar spinal stenosis, oblique take-off of L5, and severe L5-S1 degenerative disk disease^[40]. To avoid complications leading to failure of the S1 pedicle screws the use of bilateral iliac screw fixation and anterior interbody support is recommended.

Posterior-only approaches include the Smith-Petersen osteotomy, pedicle subtraction osteotomy, and vertebral column resection. The amount of correction needed to correct the deformity determines the surgical procedure and should be measured preoperatively (Figure 7).

SMITH-PETERSEN OSTEOTOMY [SPO]

The first description of an SPO was by Smith-Petersen^[41] as a one- or two-level osteotomy for ankylosing spondylitis. Ponte^[42] described the Ponte procedure as, which included multiple chevron osteotomies with spinal instrumentation in Scheuermann's disease. The use of this osteotomy for the treatment of flat back deformity was first reported by Moe and Denis in 1977^[43].

The surgical technique involves removal of the all posterior

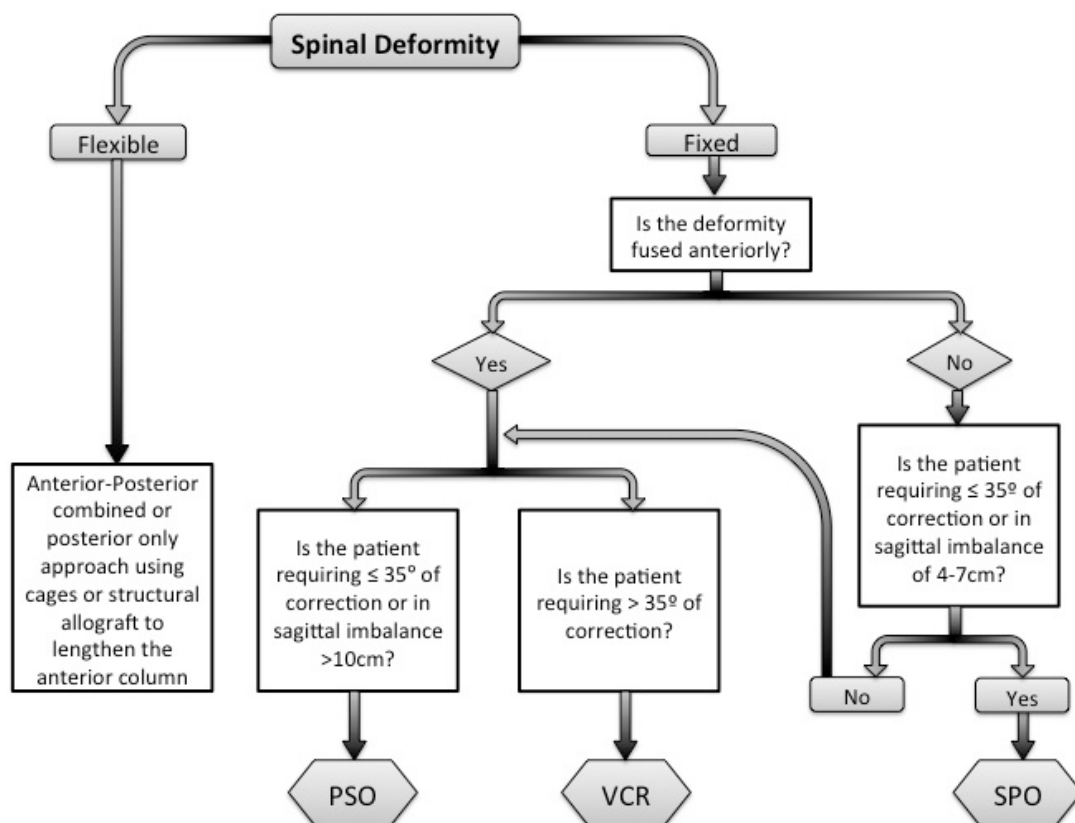


Figure 7 Deformity flexibility, spinopelvic parameters and the amount of correction needed are critical aspects that determine the surgical procedure needed. Authors’ proposed flow chart for the surgical management of adult sagittal imbalance.

ligaments (supraspinous, interspinous, and ligamentum flavum) and facets to produce a posterior release. Dissection is then performed laterally with decompression of the nerve roots. The fusion mass or lamina is beveled to allow sufficient room for the dura and nerve roots after closure of the osteotomy. The osteotomy hinges providing coronal correction and sagittal plane realignment. Posterior segmental pedicle screw instrumentation is used to maintain closure of the osteotomy (Figure 8). It should be remarked that mobile disk or a previously osteotomized anterior fusion mass is required to allow lengthening of the anterior column; otherwise the SPO is not indicated. The SPO should be considered for patients with C7 plumb line that is in the range of 6-8 cm positive^[44]. Amount of correction provided by the SPO is in the range of 9.3-10.7 degrees per level. One degree of correction is achieved per millimeter of bone resected. For the patient requiring 10° to 20° of lordosis or 6-8 cm of correction of the C7 plumb line, it is more appropriate to perform a limited number of SPOs than one pedicle subtraction osteotomy, unless the fixed deformity is fused anteriorly^[44]. The SPO is technically easier and safer than other osteotomies offering a reduction in operative time, blood loss and risk of neurological complications, although rupture of the great vessels has been reported following anterior-column lengthening^[41].

PEDICLE SUBTRACTION OSTEOTOMY [PSO]

First described by Thomassen^[45] in 1985, pedicle subtraction osteotomy [PSO] consists in a transpedicular V shaped wedge osteotomy. In the same year, Heining *et al*^[46] described an eggshell osteotomy as a variant of the PSO, which was also a transpedicular

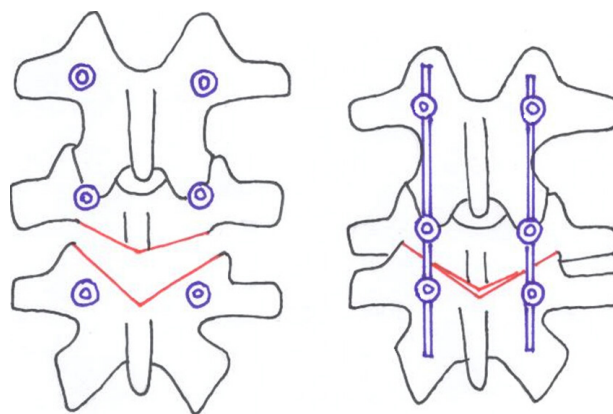


Figure 8 SPO: The surgical technique involves removal of the all posterior ligaments (supraspinous, interspinous, and ligamentum flavum) and facets to produce a posterior release. The fusion mass or lamina is beveled to allow sufficient room for the dura and nerve roots after closure of the osteotomy. Posterior segmental pedicle screw instrumentation is used to maintain closure of the osteotomy.

decancellation closed wedge osteotomy. The PSO is performed by removing the posterior elements and both pedicles, performing a transpedicular V shaped wedge osteotomy of the vertebral body, and closing the osteotomy by hinging on the anterior cortex (Figures 9 and 10) achieving bone-on-bone contact in the posterior, middle, and anterior columns^[47]. Central canal enlargement is critical to avoid neurologic injury during closure of the osteotomy. Posterior segmental pedicle screw instrumentation is used to maintain the correction. Instrumentation of at least three vertebral levels above

and below the osteotomy is recommended^[48].

The PSO has the advantage of obtaining correction through all three columns, while the posterior and middle columns shorten, this osteotomy does not lengthen the anterior column avoiding stretch on the major vessels and viscera anterior to the spine^[49].

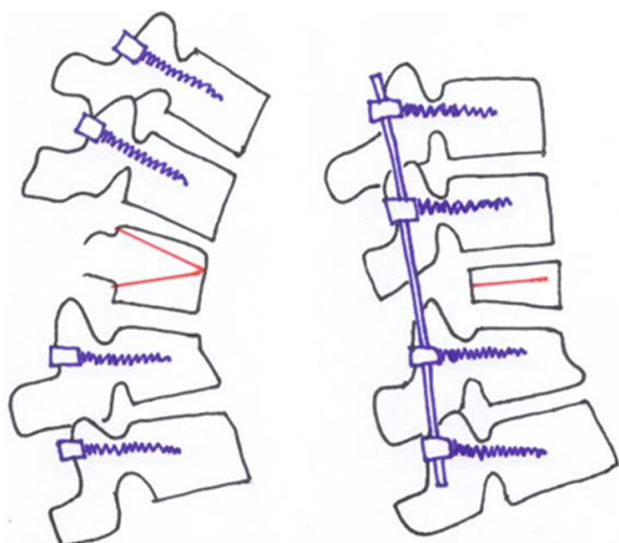


Figure 9 The PSO is performed by removing the posterior elements and both pedicles, performing a transpedicular V shaped wedge osteotomy of the vertebral body, and closing the osteotomy by hinging on the anterior cortex achieving bone-on-bone contact in the posterior, middle, and anterior columns. Posterior segmental pedicle screw instrumentation is used to maintain the correction.

An average of 30° to 40° correction can be achieved with one level PSO^[49]. The ideal candidates for a PSO are patients with a fixed sagittal imbalance of more than 12 cm and those patients who have circumferential fusion along multiple segments, which would preclude performing SPOs^[44].

Although PSOs are more technically demanding and more prone to complications than SPOs; PSOs provide satisfactory clinical and radiologic outcomes in long-term follow-up. Kim *et al*^[49] reported their results in a series of 35 PSOs with 5 to 8 years follow-up; observing no significant regional radiological changes between the postoperative second year and final follow-up. Pseudarthrosis was reported in 10 cases (29%). Patient satisfaction (87%) and function (69%) were high after more than 5 years of follow-up.

Cho *et al*^[50] compared one level of PSO with three levels of SPOs in their study and reported an average total correction as 31.7° for PSO in a group of 41 patients with fixed sagittal imbalance. Improvement in the sagittal imbalance (11.2±7.2 cm) and correction of the coronal plane (0.48±1.4 cm) were higher when compared to three levels of SPO group. Blood loss was significantly higher in PSO group. There was no statistical difference between one level PSO and three levels of SPO groups with respect to operating times. Regarding neurological complications, Buchowski *et al*^[51] reported a postoperative neurological deficit rate of 11.1 %, but only 2.8 % of deficits were permanent over a 10-year period. Deficits were always unilateral and never proximal to osteotomy, often did not correspond to the level of osteotomy, and surprisingly were not detected by neuromonitoring. Other authors report an incidence of neurological complications ranging between 3.6 and 12%^[52,53].

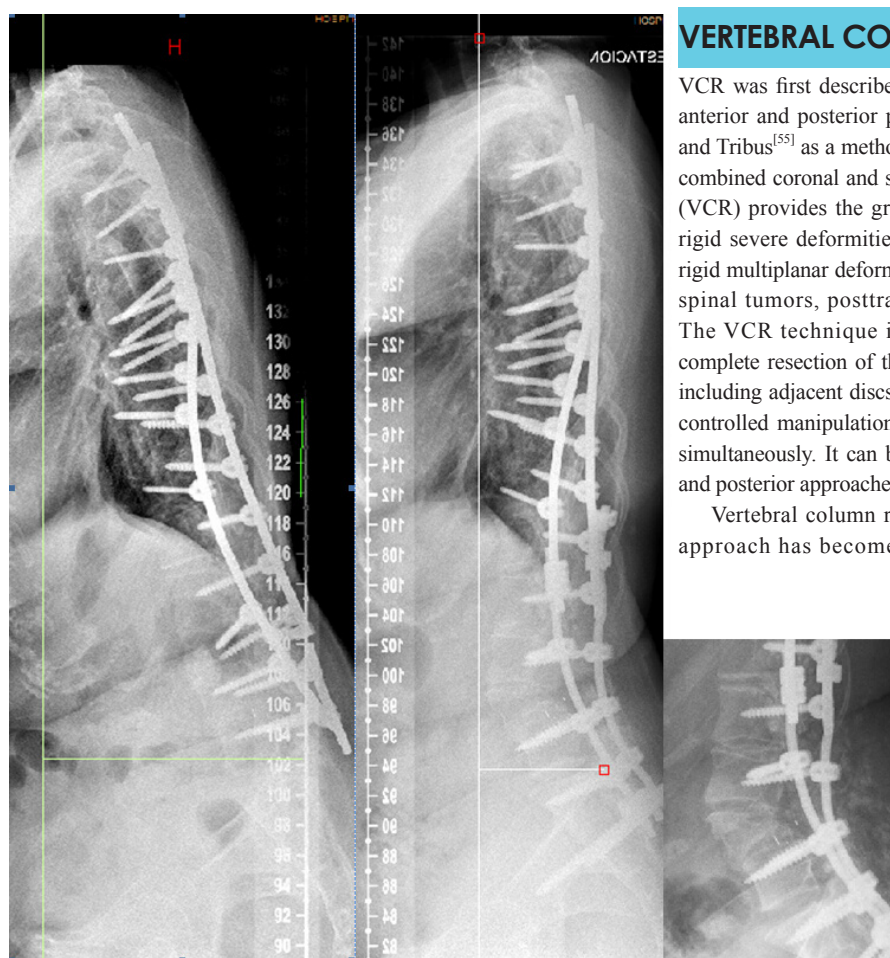


Figure 10 Sagittal imbalance in a 42 year-old woman. Although only suboptimal spinopelvic alignment was achieved the patient presented a significant clinical improvement after undergoing PSO at L4.

VERTEBRAL COLUMN RESECTION

VCR was first described in 1922 by MacLennan^[54] as a combined anterior and posterior procedure and was popularized by Bradford and Tribus^[55] as a method of correcting severe coronal deformity and combined coronal and sagittal deformity. Vertebral column resection (VCR) provides the greatest amount of correction. Is indicated in rigid severe deformities of the spine such as congenital kyphosis, rigid multiplanar deformities, sharp angulated deformities, resectable spinal tumors, posttraumatic deformities, and spondyloptosis. The VCR technique is a challenging procedure involving the complete resection of the posterior elements and the vertebral body including adjacent discs of one or more levels (Figure 11) providing controlled manipulation of both the anterior and posterior columns simultaneously. It can be performed using either combined anterior and posterior approaches or a posterior-only approach^[56].

Vertebral column resection through a posterior-only [PVCR] approach has become popular in the recent years. First been

introduced by Suk *et al*^[57] and popularized in the last years by Lenke^[58] for severe deformities of the spinal column although it is technically demanding procedure with a high neurological complication rate^[44].

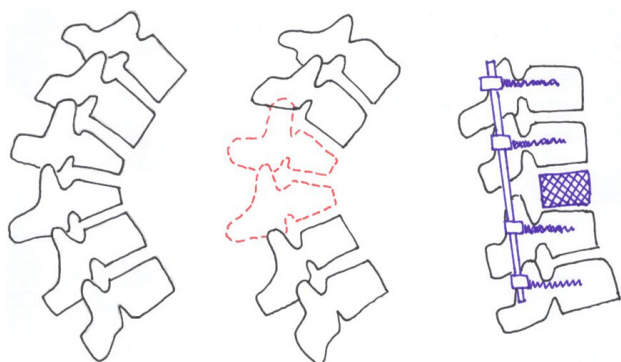


Figure 11 VCR involves the complete resection of the posterior elements and the vertebral body including adjacent discs of one or more levels.

There are several advantages of PVCR for correction of rigid severe deformity. It enables manipulation in every direction under a simultaneous control of both anterior and posterior sites of the spinal column and provides better correction than the other types of osteotomies. It is a single procedure compared to combined anterior and posterior VCR reducing the total operating time and the amount of blood loss and also avoiding opening of the thoracic cage and pleura. Avoiding anterior surgery may be very beneficial for patients with severe pulmonary function compromise because of severe thoracic deformity^[44].

Hamzaoglu *et al*^[56] reported an average correction rate of 62% in coronal and 72% in sagittal plane in their series of 102 severe adult deformity patients. Suk *et al*^[57] reported a correction of 61.9 degrees in the coronal plane and 45.2 degrees in the sagittal plane in their series of 70 patients. In a series of 35 children, Lenke^[58] noted major curve improvements as 51% in scoliosis cases, 55% in global kyphosis cases, 58% in angular kyphosis cases, 54% in kyphoscoliosis cases, and 60% in congenital scoliosis cases after PVCR. The same authors reported another series of PVCR including a slightly larger number of adults and children with severe deformity. Correction rates were 69% for scoliosis, 54% for global kyphosis, 63% for angular kyphosis, and 56% for kyphoscoliosis^[56-58].

One major concern with PVCR is the potential for neurologic complications, which may result from direct neurologic injury during bone resection or deformity correction. Neurologic complications may also result from subluxation of the spinal column, dural buckling and compression of the spinal cord by residual bone or soft tissues in the canal after correction^[44]. Suk^[57] reported a 34.3% overall rate of complications and a 17.1% rate of neurologic complications. Lenke^[58] reported a similar 40% overall rate of complications and an 11.4% rate for neurological complications. Hamzaoglu^[56] reported a 7.84% overall complication rate including transient nerve palsies in 1.96% of patients.

SUMMARY

The number of patients seeking consultation due to pain and spinal deformity presenting with sagittal imbalance is expected to rise in the next years. A comprehensive analysis of the rigidity of the deformity, the spinal and pelvic (PI, PT and SS) parameters, and

the compensatory mechanisms are paramount in order to be able to offer a tailored solution to these patients. Since conservative measures fail in most patients, successful management of these patients requires achieving fusion of a balanced spine. Selecting the appropriate surgical technique to achieve spinal balance is crucial to success. Smith-Petersen osteotomy, pedicle subtraction osteotomy, and vertebral column resection all play an important role in the armamentarium of the spine deformity surgeon. However, each of these procedures carries a certain risk and are technically demanding. Appropriate preoperative optimization as well as appropriate surgical preoperative planning is critical in order to avoid potential complications. Surgical achievement of the ideal spinopelvic alignment parameters cannot be obtained in all cases. Nevertheless, even partial improvement in these parameters is very likely to translate into clinical benefits. Ideal global spinal realignment should attempt to obtain at least a postoperative C7 plumb line offset of less than 50 mm, a postoperative PT of less than 25° and a LL in the range of PI +/-9°^[59] although regarding this last point other authors advocate that a postoperative LL ≤45°-TK-PI can accurately predict clinical success following PSO^[60].

CONFLICT OF INTERESTS

There are no conflicts of interest with regard to the present study.

REFERENCES

- Berthonnaud E, Dimnet J, Labelle HB, Kuklo TR, O'Brien MF, Roussouly P. Spondylolisthesis, in O'Brien MF (ed): Radiographic Measurement Manual. Medtronic Sofamor Danek USA, Inc, 2004, pp 95-108.
- Bernhardt M, Bridwell KH. Segmental analysis of the sagittal plane alignment of the normal thoracic and lumbar spines and thoracolumbar junction. *Spine* 1989; **14**: 717-721
- Dubouset J. Three-dimensional analysis of the scoliotic deformity, in Weinstein SL (ed): The Pediatric Spine: Principles and Practice. New York, NY: Raven Press, 1994, pp 479-496.
- Schwab F, Lafage V, Boyce R, Skalli W, Farcy JP: Gravity line analysis in adult volunteers. Age-related correlation with spinal parameters, pelvic parameters, and foot position. *Spine* 2006; **31**: E959-E967
- Jackson RP, Kanemura T, Kawakami N, Hales C. Lumbopelvic lordosis and pelvic balance on repeated standing lateral radiographs of adult volunteers and untreated patients with constant low back pain. *Spine* 2000; **25**: 575-586
- Boulay C, Tardieu C, Hecquet J, et al. Sagittal alignment of spine and pelvis regulated by pelvic incidence: Standard values and prediction of lordosis. *Eur Spine J* 2006; **15**: 415-422
- Vedantam R, Lenke LG, Keeney JA, et al. Comparison of standing sagittal spinal alignment in asymptomatic adolescents and adults. *Spine* 1998; **23**: 211-225
- Gelb DE, Lenke LG, Bridwell KH, et al. An analysis of sagittal spinal alignment in 100 asymptomatic middle and older aged volunteers. *Spine* 1995; **20**: 1351-1358
- Glassman SD, Bridwell KH, Dimar JR, Horton W, Berven S, Schwab F. The impact of positive sagittal balance in adult spinal deformity. *Spine* 2005; **30**: 2024-2029
- Doherty JH. Complications of fusion in lumbar scoliosis. *J Bone Joint Surg Am* 1973; **55**: 438
- Grobler LJ, Moe JH, Winter RB. Loss of lumbar lordosis following surgical correction of thoracolumbar deformities. *Orthopaedic Transactions* 1978; **239**: 2
- Farcy JP, Schwab FJ. Management of flatback and related kyphotic decompensation syndromes. *Spine* 1997; **22**: 2452-245

- 13 Kim KT, Lee SH, Suk KS, Lee JH, Im YJ. Spinal pseudarthrosis in advanced ankylosing spondylitis with sagittal plane deformity: Clinical characteristics and outcome analysis. *Spine* 2007; **32**: 1641-1647
- 14 Bridwell KH, Lenke LG, Lewis SJ. Treatment of spinal stenosis and fixed sagittal imbalance. *Clin Orthop Relat Res* 2001; **384**: 35-44
- 15 Smith J. Adult deformity. Management of sagittal plane deformity in revision adult spine surgery. *Current Opinion in Orthopaedics* 2001; **12**: 206-215
- 16 Horton WC, Brown CW, Bridwell KH, Glassman SD, Suk SI, Cha CW. Is there an optimal patient stance for obtaining a lateral 36° radiograph? A critical comparison of three techniques. *Spine* 2005; **30**: 427-433
- 17 Jackson RP, McManus AC. Radiographic analysis of sagittal plane alignment and balance in standing volunteers and patients with low back pain matched for age, sex, and size: A prospective controlled clinical study. *Spine* 1994; **19**: 1611-1618
- 18 Hammerberg EM, Wood KB. Sagittal profile of the elderly. *J Spinal Disord Tech* 2003; **16**: 44-50
- 19 Vaz G, Roussouly P, Berthonnaud E, Dimnet J. Sagittal morphology and equilibrium of pelvis and spine. *Eur Spine J* 2002; **11**: 80-87
- 20 Legaye J, Duval-Beaupère G, Hecquet J, Marty C. Pelvic incidence: A fundamental pelvic parameter for three-dimensional regulation of spinal sagittal curves. *Eur Spine J* 1998; **7**: 99-103
- 21 Le Huec JC, Aunoble S, Philippe L, Nicolas P. Pelvic parameters: origin and significance. *Eur Spine J* 2011 Sep; **20 Suppl 5**: 564-571
- 22 Boulay C, Tardieu C, Hecquet J, Benaïm C, Mitulescu A, Marty C, Prat-Pradal D, Legaye J, Duval-Beaupère G, Pélissier J. Anatomical reliability of two fundamental radiological and clinical pelvic parameters: incidence and thickness. *Eur J Orthop Surg Traumatol* 2005; **15**: 197-204
- 23 Lazennec JY, Riwan A, Gravez F *et al.* Hip spine relationships: application to total hip arthroplasty. *Hip Int* 2007; **17**: 91-104
- 24 Vaz G, Roussouly P, Berthonnaud E, Dimnet J. Sagittal morphology and equilibrium of pelvis and spine. *Eur Spine J* 2002; **11(11)**: 80-87
- 25 Lafage V, Schwab F, Patel A, *et al.* Pelvic tilt and truncal inclination: two key radiographic parameters in the setting of adults with spinal deformity. *Spine (Phila Pa 1976)* 2009; **34**: E599-606
- 26 Barrey C, Jund J, Noseda O, Roussouly P. Sagittal balance of the pelvis-spine complex and lumbar degenerative diseases. A comparative study about 85 cases. *Eur Spine J* 2007; **16**: 1459-1467
- 27 Barrey C, Jund J, Perrin G, Roussouly P. Spinopelvic alignment of patients with degenerative spondylolisthesis. *Neurosurg* 2007; **61**: 981-986
- 28 Berthonnaud E, Dimnet J, Roussouly P, Labelle H. Analysis of the sagittal spine and pelvis using shape and orientation parameters. *J Spinal Disord Tech* 2005; **18**: 40-47
- 29 Barrey C, Roussouly P, Perrin G, Le Huec JC. Sagittal balance disorders in severe degenerative spine. Can we identify the compensatory mechanisms? *Eur Spine J* 2011 Sep; **20 Suppl 5**: 626-633
- 30 Le Huec JC, Charosky S, Barrey C, Rigal J, Aunoble S. Sagittal imbalance cascade for simple degenerative spine and consequences: algorithm of decision for appropriate treatment. *Eur Spine J* 2011 Sep; **20 Suppl 5**: 699-703
- 31 Glassman SD, Berven S, Bridwell K, Horton W, Dimar JR. Correlation of radiographic parameters and clinical symptoms in adult scoliosis. *Spine* 2005; **30**: 682-688
- 32 Bradford DS, Tay BK, Hu SS. Adult scoliosis. Surgical indications, operative management, complications, and outcomes. *Spine* 1999; **24**: 2617-2629
- 33 Booth KC, Bridwell KH, Lenke LG, Baldus CR, Blanke KM. Complications and predictive factors for the successful treatment of flatback deformity (fixed sagittal imbalance). *Spine* 1999; **24**: 1712-1720
- 34 Bridwell KH, Lewis SJ, Lenke LG, Baldus C, Blanke K. Pedicle subtraction osteotomy for the treatment of fixed sagittal imbalance. *J Bone Joint Surg Am* 2003; **85**: 454-463
- 35 Kim YJ, Bridwell KH, Lenke LG, Rhim S, Cheh G. Pseudarthrosis in long adult spinal deformity instrumentation and fusion to the sacrum: Prevalence and risk factor analysis of 144 cases. *Spine* 2006; **31**: 2329-2336
- 36 Dorward GI, Lenke GL. Osteotomies in the posterior only treatment of complex adult spinal deformity: a comparative review. *Neurosurg Focus* 2010; **28(3)**: 1-10
- 37 Hu SS, Berven SH. Preparing the adult deformity patient for spinal surgery. *Spine* 2006; **31(19 suppl)**: S126-S131
- 38 Bridwell KH. Decision making regarding Smith-Petersen vs. pedicle subtraction osteotomy vs. vertebral column resection for spinal deformity. *Spine* 2006; **31(19 suppl)**: S171-S178
- 39 Pateder DB, Kebaish KM, Cascio BM, Neubaer P, Matusz DM, Kostuik JP. Posterior only versus combined anterior and posterior approaches to lumbar scoliosis in adults: A radiographic analysis. *Spine* 2007; **32**: 1551-1554
- 40 Tsuchiya K, Bridwell KH, Kuklo TR, Lenke LG, Baldus C. Minimum 5-year analysis of L5-S1 fusion using sacropelvic fixation (bilateral S1 and iliac screws) for spinal deformity. *Spine* 2006; **31**: 303-308
- 41 Smith-Petersen MN, Larson CB, Aufranc OE. Osteotomy of the spine for correction of flexion deformity in rheumatoid arthritis. *Clin Orthop Relat Res* 1969; **66**: 6-9
- 42 Ponte A, Vero B, Siccardi GL. Surgical treatment of Scheuermann's kyphosis. In: Winter RB (ed) *Progress in spinal pathology: kyphosis*. Aulo Gaggi 1984 Bologna, pp 75-80
- 43 Moe JH, Denis F. Abstract: The iatrogenic loss of lumbar lordosis. *Orthopedic Transactions* 1977; **1**: 131
- 44 Enercan M, Ozturk C, Kahraman S, Sarier M, Hamzaoglu A, Alanay A. Osteotomies/spinal column resections in adult deformity. *Eur Spine J* 2013 Mar; **22 Suppl 2**: S254-64
- 45 Thomasen E. Vertebral osteotomy for correction of kyphosis in ankylosing spondylitis. *Clin Orthop Relat Res* 1985 **194**: 142-152
- 46 Heining CA. Eggshell procedure. In: Luque ER (ed) *Segmental spinal instrumentation*. Thorofare, Slack, pp 221-230
- 47 Bridwell KH, Lewis SJ, Rinella A, Lenke LG, Baldus C, Blanke K. Pedicle subtraction osteotomy for the treatment of fixed sagittal imbalance: Surgical technique. *J Bone Joint Surg Am* 2004; **86(suppl 1)**: 44-50
- 48 Kim KT, Lee SH, Suk KS, Lee JH, Im YJ. Spinal pseudarthrosis in advanced ankylosing spondylitis with sagittal plane deformity: Clinical characteristics and outcome analysis. *Spine* 2007; **32**: 1641-1647
- 49 Kim JY, Bridwell KH, Lenke GL, Cheh GE, Baldus C. Results of lumbar pedicle subtraction osteotomies of fixed sagittal imbalance: a minimum 5-year follow-up study. *Spine* 2007; **32(20)**: 2189-2197
- 50 Cho KJ, Bridwell KH, Lenke GL, Berra A, Baldus C. Comparison of Smith-Petersen versus pedicle subtraction osteotomy for correction of fixed sagittal imbalance. *Spine* 2005; **30(18)**: 2030-2037
- 51 Buchowski JM, Bridwell KH, Lenke LG, Kuhns CA, Lehman RA, Kim JY, Stewart D, Baldus C. Neurologic complications of lumbar pedicle subtraction osteotomy: a 10-year assessment. *Spine* 2007; **32(20)**: 2245-2252
- 52 Yang BP, Ondra SL, Chen LA *et al.* Clinical and radiographic outcomes of thoracic and lumbar pedicle subtraction osteotomy for fixed sagittal imbalance. *J Neurosurg Spine* 2006; **5**: 9-17
- 53 Ahn UM, Ahn NU, Buchowski JM *et al.* Functional outcome and radiographic correction after spinal osteotomy. *Spine* 2002; **27**: 1303-1311
- 54 MacLennan A. Scoliosis. *BMJ* 1922; **2**: 865-866
- 55 Bradford DS, Tribus CB. Vertebral column resection for the treat-

- ment of rigid coronal decompensation. *Spine* 1997; **22**: 1590-1599
- 56 Hamzaoglu A, Alanay A, Ozturk C, Sarier M, Karadereler S, Ganiyusufoglu K. Posterior vertebral column resection in severe spinal deformities. *Spine* 2011; **36(5)**: 340-344
- 57 Suk SI, Chung ER, Kim JH et al. Posterior vertebral column resection for severe rigid scoliosis. *Spine* 2005; **30(14)**: 1682-1687
- 58 Lenke LG, O'Leary PT, Bridwell KH, Sides BA, Koester LA, Blanke KM. Posterior vertebral column resection for severe pediatric deformity: minimum two-year follow-up of thirty-five consecutive patients. *Spine* 2009; **34**: 2213-2221
- 59 Schwab F, Patel A, Ungar B, Farcy JP, Lafage V. Adult spinal deformity-postoperative standing imbalance: how much can you tolerate? An overview of key parameters in assessing alignment and planning corrective surgery. *Spine (Phila Pa 1976)*. 2010 Dec 15; **35(25)**: 2224-31
- 60 Rose PS, Bridwell KH, Lenke LG, Cronen GA, Mulconrey DS, Buchowski JM, Kim YJ. Role of pelvic incidence, thoracic kyphosis, and patient factors on sagittal plane correction following pedicle subtraction osteotomy. *Spine (Phila Pa 1976)*. 2009 Apr 15; **34(8)**: 785-91
- Peer reviewers:** Hiroshi Kuroki, MD, Head physician in Department of Orthopaedic Surgery, National Hospital Organization, Miyazaki Higashi National Hospital, 4374-1 Tayoshi Ooaza Miyazaki, 880-0911, Japan; Daniel K. Park, MD, Michigan Orthopedic Institute, 26025 Lahser Rd, Southfield MI 48033 the Unites States.