

Acetabular Cup Abduction Angle Determined by Digital Radiographic Software as Compared to CT-Based Measurement

Eytan M Debbi, MSc, Omri Lubovsky, MD, Selcuk Frik, MD, Gurion Rivkin, MD, Ronen Debi, MD, Ehud Atoun, MD

Eytan M Debbi, Biorobotics and Biomechanics Lab, Faculty of Mechanical Engineering, Technion-Israel Institute of Technology, Haifa, Israel

Omri Lubovsky, Ronen Debi, Ehud Atoun, Department of Orthopedic Surgery, Barzilai Medical Center, Ashkelon, Israel

Selcuk Frik, Gurion Rivkin, Department of Orthopedic Surgery, Hadassah Medical Center, Jerusalem, Israel

Correspondence to: Ehud Atoun, MD, 2 Hahistadrut Street, Department of Orthopedic Surgery, Barzilai Medical Center, 78278 Ashkelon, Israel

Email: dratoun@gmail.com

Telephone: +972-8-6745631

Fax: +972-8-6745631

Received: October 7, 2014

Revised: December 1, 2014

Accepted: December 2, 2014

Published online: December 23, 2014

© 2014 ACT. All rights reserved.

Key words: Acetabulum; Cup; Orientation; Total hip arthroplasty; Radiography; X-Ray; CT

Debbi EM, Lubovsky O, Frik S, Rivkin G, Debi R, Atoun E. Acetabular Cup Abduction Angle Determined by Digital Radiographic Software as Compared to CT-Based Measurement. *International Journal of Orthopaedics* 2014; 1(4): 173-176 Available from: URL: <http://www.ghrnet.org/index.php/ijo/article/view/893>

INTRODUCTION

Measurement of the acetabular cup orientation is critical in patients after total hip arthroplasty (THA). Poor cup orientation was found to correlate with pain, excessive wear and instability^[1-4]. Cup abduction angle (CAA) is an important aspect of cup orientation that can be measured using either radiographs or computed tomography scans (CT).

Traditionally, CAA measurement has been carried out manually using a goniometer on printed radiographic images^[1,5-7]. CT scans can also be used to determine acetabular orientations^[1,5,15-17]. CT methods have been shown to have high precision, and, although not a gold standard, are considered to be the most accurate method to date of determining cup orientation postoperatively^[1,5,6]. Nevertheless, there are several downsides to CT, such as the greater complexity of the analysis, high cost, low availability and time needed for the analysis^[5,18].

In recent years, digital imaging software for the analysis of radiographs has been developed and has gained tremendous support due to its success in precise preoperative planning for THA^[8-14]. Such software incorporates dedicated tools for the measurement of CAA. The accuracy of the software in measuring the CAA, however, has not yet been thoroughly examined.

The purpose of the present study was to compare the accuracy of

ABSTRACT

AIM: Measurement of the acetabular cup orientation is critical in patients after total hip arthroplasty (THA). One important measurement is the acetabular abduction angle. The purpose of the present study was to compare the measurements of the acetabular abduction angle using radiographic analysis software with the measurements made by computed tomography (CT) analysis software.

METHODS: CT scans and radiograph exams were performed on 150 patients after THA. The acetabular abduction angle was measured from CT using CT-based image analysis software and from radiographs using the dedicated measurement tools of digital radiographic software.

RESULTS: The two measurement systems showed no significant difference in the calculation of the acetabular abduction angle ($0.35 \pm 5.41^\circ$; $p=0.425$) and a moderate correlation was found between the two methods ($r=0.619$; $p<0.001$).

DISCUSSION: Digital radiographic software provides an accurate and precise measurement of the acetabular abduction angle.

digital imaging software tools for determining CAA in comparison to CT-based measurements.

METHODS

This was a retrospective study on consecutive patients that underwent THA between the years 2002 to 2006 at the Hadassah Mount Scopus Hospital. The study was approved by the local ethical committee (IRB No. 0385-11). We identified patients that underwent a postoperative CT scan containing the pelvis as well as a postoperative pelvic AP radiographic image. CT scans were performed due to a variety of reasons in the days, months or years after surgery. Most of them are carried out due to non-orthopedic indications (i.e. suspected pulmonary embolism, pelvic and abdominal pathologies and other). Only patients with CT scans that provided enough data to enable analysis of the acetabular cup orientation were chosen.

The CT scans were carried out using a GE Light Speed VCT (GE Corp, Fairfield, CT, USA). CT image data for each patient were analyzed using the Amira[®] visualization and analysis software (Amira, Visualization Sciences Group, Burlington, MA, USA). The software allows for the calculation of the abduction angle of the acetabulum in each patient by a method described previously by Lubovsky *et al*^[19] (Figure 1).

Anteroposterior radiograph projections were taken with a film-focus distance of 1,000 mm. The central beam was directed at the pubis. All radiographs were processed using the TraumaCAD[®] digital software system (TraumaCad, Voyant Health, Petah Tikva, Israel). The software was used to measure the CAA in each patient by calculating the angle between the horizontal inter-teardrop line and the cup with a dedicated tool (Figure 2).

Statistics

Data distributions were examined using Kolmogorov-Smirnov tests for normality. T-tests were used to examine the difference between digital radiographic measurements and CT-based measurements. Pearson correlation coefficients were determined for the relationship between system measurements. Additionally, the angle differences were measured as a function of angle size using a correlation and regression analysis. Significance was set at $p < 0.05$. All statistical tests were performed using SPSS[®] v. 17 (SPSS Inc, Chicago, IL, USA).

RESULT

A total of 980 underwent THA during the study period. We identified 62 patients that had both postoperative a CT scan and a digital radiograph of the pelvis. This study cohort consisted of 47 females and 15 males, with a mean age of 67.2 ± 12.8 years.

The average angles and angle differences between digital radiographic and CT-based measurements are presented in table 1. There was a non-significant average difference of $0.35 \pm 5.41^\circ$ between radiographic and CT-based abduction angle measurements ($p = 0.425$; Figure 3). There was a significant moderate correlation between angle measurements of both systems ($r = 0.619$; $p < 0.001$; Figure 4). The difference in abduction angles between systems showed a low correlation with angle size ($r = -0.391$; $p < 0.001$; Figure 5), with a regression slope of -0.35 .

DISCUSSION

In our study, the digital radiographic measurements of CAA with dedicated software were not significantly different from CT-based measurements. The range of error was also relatively small,

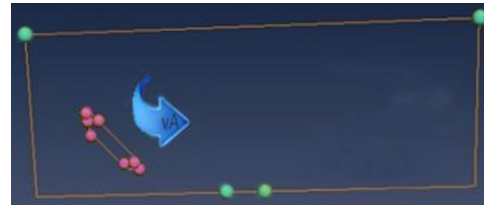


Figure 1 CT-based image analysis software (Amira[®]) measurement of acetabular cup abduction angle.

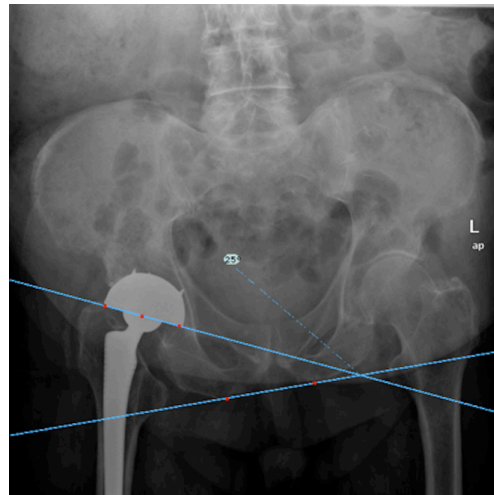


Figure 2 LegendDigital radiographic software (TraumaCAD[®]) measurement of acetabular cup abduction angle.

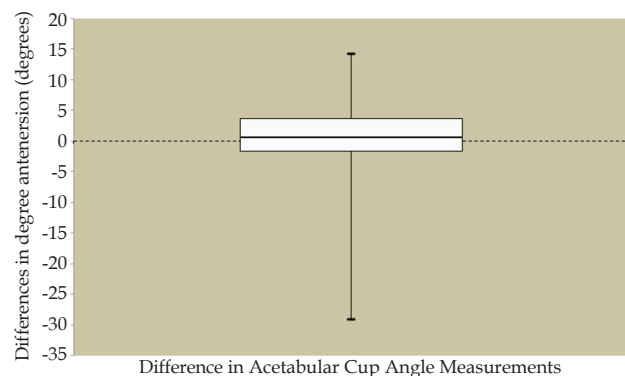


Figure 3 legendBox plots of the differences between radiological and CT-based acetabular cup abduction angles (Difference: Digital radiographic measurement - CT-based measurement). Box boundaries represent the 25th and 75th percentiles, respectively. The lines within the box represent median values, and the whiskers above and below the boxes represent the 90th and 10th percentiles, respectively.

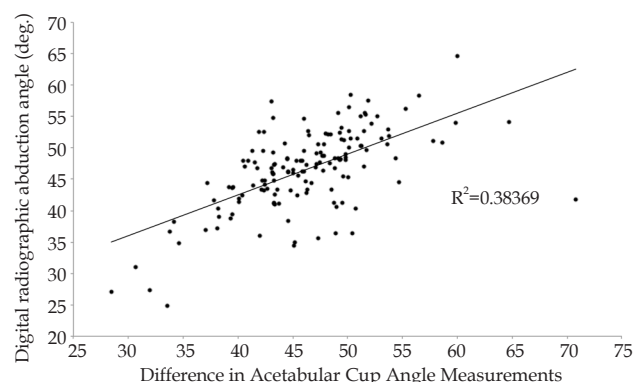


Figure 4 Correlation between digital radiographic measurements and CT-based measurements of acetabular abduction angle

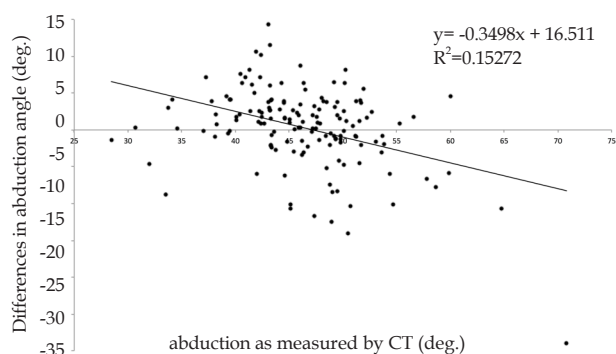


Figure 5 LegendCorrelation between differences between system measurements and CT-based measurements of acetabular abduction angle.

suggesting a high degree of precision. These findings are supported by the moderate correlation observed between the measurement systems. A previous study by Kalteis *et al* measuring abduction angle on printed radiographs showed a non-significant difference error of $0.54 \pm 2.94^\circ$ in abduction angle compared to CT^[5]. This is a very similar finding to that in the present study.

The present study also examined the correlation between angle difference and the CT-based angle measurements. A low correlation and regression slope were found for abduction angle. Considering the results shown in figure 4a, it appears that the greatest precision occurred at abduction angles of approximately 45° . This is noteworthy, since the technique for measuring acetabular abduction angle is similar in most centers and has been considered relatively robust. This should be examined using other tools to determine if this trend in error in radiographic abduction angle measurements is universal. As a whole, however, the digital radiographic measurements of acetabular abduction angle compare well to CT-based measurements. This is a good indication that measuring the abduction angle using digital radiographs will provide a relatively accurate measure of the true angle.

There are several limitations to the present study. Firstly, the acetabular cup orientation has a variety of other measurements in the three-dimensional space. Secondly, CT-based calculations of CAA were used for comparison with the radiographic calculations. CT-based calculations are not true measurements of CAA, but have been shown in previous studies to be of high accuracy^[5,6,20]. Thus, the CT scan was assumed to be a valid reference tool for determining the accuracy and precision of the digital radiographic measurements. Thirdly, the study was limited to one type of prosthetic and one type of digital imaging software tool for radiographic analysis (TraumaCad[®]), and therefore we cannot be sure if our observations are generalizable to all radiographic digital imaging software.

CONCLUSIONS

The study results are noteworthy, considering the ubiquity of radiographic digital imaging software analysis in the medical workplace. Digital radiographic software provides an accurate and precise measurement of the acetabular abduction angle. Clinicians employing these tools must be aware of their accuracy and precision.

CONFLICT OF INTERESTS

There are no conflicts of interest with regard to the present study.

REFERENCES

- Ghelman B, Kepler CK, Lyman S, Della Valle AG. CT outperforms radiography for determination of acetabular cup version after THA. *Clin Orthop Relat Res* 2009; **467(9)**: 2362
- Biedermann R, Tonin A, Krismer M, Rachbauer F, Eibl G, Stöckl B. Reducing the risk of dislocation after total hip arthroplasty - The effect of orientation of the acetabular component. *Journal of Bone and Joint Surgery-British Volume* 2005; **87B(6)**: 762
- Kennedy JG, Rogers WB, Soffe KE, Sullivan RJ, Griffen DG, Sheehan LJ. Effect of acetabular component orientation on recurrent dislocation, pelvic osteolysis, polyethylene wear, and component migration. *J Arthroplasty* 1998; **13(5)**: 530
- McCollum DE, Gray WJ. Dislocation after total hip arthroplasty. Causes and prevention. *Clin Orthop Relat Res* 1990; (261):159.
- Kalteis T, Handel M, Herold T, Perlick L, Paetzel C, Grifka J. Position of the acetabular cup -- accuracy of radiographic calculation compared to CT-based measurement. *Eur J Radiol* 2006; **58(2)**: 294
- Marx A, von Knoch M, Pfortner J, Wiese M, Saxler G. Misinterpretation of cup anteversion in total hip arthroplasty using planar radiography. *Arch Orthop Trauma Surg* 2006; **126(7)**: 487
- Varghese B, Muthukumar N, Balasubramaniam M, Scally A. Reliability of measurements with digital radiographs--a myth. *Acta Orthop Belg* 2011; **77(5)**: 622
- Steinberg EL, Shasha N, Menahem A, Dekel S. Preoperative planning of total hip replacement using the TraumaCad system. *Arch Orthop Trauma Surg* 2010; **130(12)**: 1429
- Kumar PG, Kirmani SJ, Humberg H, Kavarthapu V, Li P. Reproducibility and accuracy of templating uncemented THA with digital radiographic and digital TraumaCad templating software. *Orthopedics* 2009; **32(11)**: 815
- Bertz A, Indrekvam K, Ahmed M, Englund E, Sayed-Noor AS. Validity and reliability of preoperative templating in total hip arthroplasty using a digital templating system. *Skeletal Radiol* 2012; **41(10)**: 1245
- Schmidutz F, Steinbruck A, Wanke-Jellinek L, Pietschmann M, Jansson V, Fottner A. The accuracy of digital templating: a comparison of short-stem total hip arthroplasty and conventional total hip arthroplasty. *Int Orthop* 2012; **36(9)**: 1767
- Efe T, El Zayat BF, Heyse TJ, Timmesfeld N, Fuchs-Winkelmann S, Schmitt J. Precision of preoperative digital templating in total hip arthroplasty. *Acta Orthop Belg* 2011; **77(5)**: 616
- Whiddon DR, Bono JV, Lang JE, Smith EL, Salyapongse AK. Accuracy of digital templating in total hip arthroplasty. *Am J Orthop (Belle Mead NJ)* 2011; **40(8)**: 395
- Brew CJ, Simpson PM, Whitehouse SL, Donnelly W, Crawford RW, Hubble MJ. Scaling digital radiographs for templating in total hip arthroplasty using conventional acetate templates independent of calibration markers. *J Arthroplasty* 2012; **27(4)**: 643
- Olivecrona H, Weidenhielm L, Olivecrona L, Beckman MO, Stark A, Noz ME, Maguire GQ Jr, Zeleznik MP, Svensson L, Jonson T. A new CT method for measuring cup orientation after total hip arthroplasty: a study of 10 patients. *Acta Orthop Scand* 2004; **75(3)**: 252
- Blendea S, Eckman K, Jaramaz B, Levison TJ, Digioia AM 3rd. Measurements of acetabular cup position and pelvic spatial orientation after total hip arthroplasty using computed tomography/radiography matching. *Comput Aided Surg* 2005; **10(1)**: 37
- Steppacher SD, Tannast M, Zheng G, Zhang X, Kowal J, Anderson SE, Siebenrock KA, Murphy SB. Validation of a new method for determination of cup orientation in THA. *J Orthop Res* 2009; **27(12)**: 1583.
- Widmer KH. A simplified method to determine acetabular cup anteversion from plain radiographs. *J Arthroplasty* 2004; **19(3)**: 387
- Lubovsky O, Peleg E, Joskowicz L, Liebergall M, Khoury A. Ac-

- etabular orientation variability and symmetry based on CT scans of adults. *Int J Comput Assist Radiol Surg* 2010; **5(5)**: 449
- 20 Bernsmann K, Langlotz U, Ansari B, Wiese M. [Computer-assisted navigated cup placement of different cup types in hip arthroplasty-a randomised controlled trial]. *Z Orthop Ihre Grenzgeb* 2001; **139(6)**: 512.

Peer reviewers: Geert Meermans, MD, Department of Orthopaedics, Lievensberg Hospital, Boerhaaveplein 1, 4624VT Bergen op Zoom, The Netherlands, Mohd Yusof Baharuddin, Research Fellow, Centre for Biomedical Engineering Transportation Research Alliance, Universiti Teknologi Malaysia, 81310 Skudai, Johor, Malaysia.