

Treatment Strategy for Cervical Myelopathy in Patients with Athetoid Cerebral Palsy

Hiroshi Kuroki, Shinichiro Kubo, Hideaki Hamanaka, Naoki Inomata, Kiyoshi Higa, Etsuo Chosa

Hiroshi Kuroki, Department of Orthopaedic Surgery, National Hospital Organization Miyazaki Higashi Hospital, Japan

Shinichiro Kubo, Department of Orthopaedic Surgery, Nozaki Higashi Hospital, Japan

Hideaki Hamanaka, Naoki Inomata, Kiyoshi Higa, Etsuo Chosa, Department of Orthopaedic Surgery, University of Miyazaki Faculty of Medicine, Japan

Correspondence to: Hiroshi Kuroki, MD, Department of Orthopaedic Surgery, National Hospital Organization Miyazaki Higashi Hospital, 4374-1 Tayoshi Ooaza Miyazaki, 880-0911 Japan.

Email: hiroshik@med.miyazaki-u.ac.jp

Telephone: +81-985-56-2311 Fax: +81-985-56-2257

Received: December 6, 2014 Revised: January 5, 2015

Accepted: January 11, 2015

Published online: April 23, 2015

ABSTRACT

AIM: In athetoid cerebral palsy (ACP) patients, severe and progressive cervical myelopathy (CM) often develops at a young age for the reason that involuntary movement due to ACP facilitates degeneration of cervical spine. The purpose of this retrospective study was to explore the optimal management of CM due to ACP.

MATERIALS AND METHODS: From 2004 through 2013, 16 consecutive cases of CM in ACP who were surgically treated were studied. They included 7 males and 9 females with a mean age of 55 years. Mean duration of postoperative follow-up was 3 years and 6 months. We clinically and radiographically evaluated in these cases.

RESULTS: Posterior decompression and fusion was employed in 10 cases, posterior fusion in 4 cases, and laminoplasty in 2 cases. In 13 cases, botulinum toxin injection, selective muscle release, or both were additionally performed. As to clinical outcome evaluated by Fujii's scale, 4 cases had excellent, 8 cases had good, 3 cases had fair, and 1 case had poor results. Perioperative complication was observed in 8 cases. Lordosis of cervical spine increased in 6 cases, decreased in 4 cases, and unchanged in 6 cases after surgery. Bone union was

obtained in all 14 cases who were performed fusion surgery.

CONCLUSIONS: For the treatment of CM in ACP, evaluations of the intensity and the pattern of athetoid movement are important features for selection of the proper surgical method. Strong cervical fixation accompanied with various athetoid movement control procedures to achieve solid bone union may warrant long-term acceptable clinical results.

© 2015 ACT. All rights reserved.

Key words: Athetoid cerebral palsy; Cervical myelopathy; Spinal instrumentation; Surgical treatment; Botulinum toxin

Kuroki H, Kubo S, Hamanaka H, Inomata N, Higa K, Chosa E. Treatment Strategy for Cervical Myelopathy in Patients with Athetoid Cerebral Palsy. *International Journal of Orthopaedics* 2015; 2(2): 243-249 Available from: URL: <http://www.ghrnet.org/index.php/ijo/article/view/949>

INTRODUCTION

In athetoid cerebral palsy (ACP) patients, severe and progressive cervical myelopathy (CM) often develops at a younger age for the reason that involuntary cervical movement accelerates disc degeneration of the cervical spine^[1-3]. However, the diagnosis is frequently overlooked due to the insidious progression of neurologic disorders and the pre-existent neurological handicap^[1]. Because the conservative treatment is not effective, the surgical treatment must be required in most of the patients^[4]. Whereas, the pathophysiology of this disorder is complex and multifactorial, therefore the standard surgical strategies have not been established yet. In principle, we usually decide the surgical method on the basis of both the physical status and the intensity of athetoid movement in each patient. The purpose of the current study was to investigate the clinical and radiographical results of surgical treatments for 16 patients suffering from CM in ACP.

MATERIALS AND METHODS

From 2004 through 2013, 16 consecutive patients of CM in ACP who underwent surgical treatments were studied. They included 7 males and 9 females ranging in age from 40 years to 72 years, with a mean age of 55 years. Duration of postoperative follow-up was from 1 year to 9 years, with a mean period of 3 years and 6 months. The intensity of athetoid cervical movements assessed by Mihara’s grading system^[5] (Table 1) was Grade 1 in 1 case, Grade 2 in 1 case, Grade 3 in 12 cases, and Grade 4 in 2 case. There was no case of Grade 5. We clinically investigated about the pathological level of CM indicated by intramedullar high signal on MRI in T2 sequence, surgical procedures, treatment outcomes evaluated by Japanese Orthopaedic Association (JOA) score (Table 2) and Fuji’s scale^[6] (Table 3), and perioperative complications. Recovery rate (%) of JOA score was calculated by a formula of “{(postoperative score-preoperative score) / (17- preoperative score)} × 100”.

Further, radiographical studies about the cervical alignment, range of motion (ROM) of the cervical spine between C2 and C7, and bone union were conducted. Cervical alignment was divided into three types according to lordotic angle that was measured by an angle between lower end plates of C2 and C7. “Lordotic type” was defined that lordotic angle was more than 10°, “kyphotic type” was defined that lordotic angle was less than 0°, and “straight type” defined that lordotic angle was between 0 and 10°. With regard to bone union, if no motion was confirmed on dynamic lateral flexion-extension radiographs and radiolucent zone around the screws was not observed at 6 months after surgery, we judged bone union had reached completion.

Written informed consent was obtained from the patients for publication of this report. And all procedures were in accordance with the Helsinki declaration.

RESULTS

The pathological level of CM was C1/2 in 3cases, C2/3 in 2 cases, C3/4 in 5cases, C4/5 in 1 case, C5/6 in 2 cases, and multiple in 3 cases. Posterior decompression and fusion was employed in 10 cases, posterior fusion in 4 cases, and laminoplasty in 2 cases. In 13 cases, botulinum toxin (Botox[®]) injection, selective muscle release, or both were supplementally performed. Additional surgeries were needed in 2 cases (case 2 and 4). In case 2, removal of spinal instrument due to dislodgement and extended posterior decompression and fusion were sequentially performed at 6 months and 10months after first surgery, respectively. In case 4, posterior fusion was extended to T2 because of recurrent myelopathy at the lower adjacent level at 5 years 10 months after first surgery. JOA score improved in 13 cases, worsened in 1 case, and unchanged in 2 cases. As to clinical outcome evaluated

Table 1 Grading system for intensity of athetoid cervical movement proposed by Mihara *et al.*

Grade 1:	Mild involuntary movement of head and neck induced by speech or mental strain
Grade 2:	Moderate and frequent involuntary movement of head and neck that is clearly observed on the body surface
Grade 3:	Involuntary movement of head and neck accompanied with asymmetric movement and deviation of the scapula and the trunk
Grade 4:	Strong involuntary movement of head and neck enough to overcome manual restraint
Grade 5:	Strong and rapid involuntary movement of head and neck, that is, full range of motion at one time

by Fuji’s scale, 4 cases had excellent, 8 cases had good, 3 cases had fair, and 1 case had poor results. Perioperative complications were observed in 8 cases; transient renal failure in 1 case, dislodgement of spinal implant in 1 case, surgical site infection at the left posterior iliac crest where bone grafts were harvested in 1 case, transient paralysis of upper arm in 4 cases, and respiratory failure of temporary duration in 1 case. With respect to cervical alignment, lordosis of cervical spine increased in 6 cases (from straight type to lordotic type in 2 cases, from kyphotic type to straight type in 4 cases), decreased in 4 cases (from lordotic type to straight type in 2 cases, from straight type to kyphotic type in 1 case, from lordotic type to kyphotic type in 1 case), and unchanged in 6 cases after surgery. Bone union was obtained in all 14 cases who underwent fusion surgery. ROM between C2 and C7 became 0 degrees in 13 cases with C0-T1 or T2 fusion and decreased in the other 3 cases who received C0-2 fusion or laminoplasty (Table 4).

Table 2 Scoring system for cervical myelopathy (Japanese Orthopaedic Association).

Motor function
<i>Fingers</i>
0 = unable to feed oneself with any tableware including chopsticks, a spoon, or a fork and/or unable to fasten buttons of any size
1 = can manage to feed oneself with a spoon and/or a fork but not with chopsticks
2 = either chopsticks-feeding or writing is possible but not practical and/or large buttons can be fastened
3 = either chopsticks-feeding or writing is clumsy but practical and/or cuff buttons can be fastened
4 = normal
<i>Shoulder and elbow</i>
Evaluated by MMT score for the deltoid or biceps muscles, whichever is weaker
-2 = MMT 2 or below
-1 = MMT 3
-0.5 = MMT 4
0 = MMT 5
<i>Lower extremity</i>
0 = unable to stand up and walk by any means
0.5 = able to stand up but unable to walk
1 = unable to walk without a cane or other support on a level
1.5 = able to walk without a support but with a clumsy gait
2 = walks independently on a level surface but needs support on stairs
2.5 = walks independently when going upstairs but needs support when going downstairs
3 = capable of fast walking but clumsily
4 = normal
Sensory function
Upper extremity, trunk, lower extremity
0 = complete loss of touch sensation
0.5 = 50% or below normal sensation and/or severe pain of numbness
1 = more than 60% of normal sensation and/or moderate pain or numbness
1.5 = subjective numbness of slight degree without any objective sensory deficit
2 = normal
Bladder function
0 = urinary retention and/or incontinence
1 = sense of retention and/or dribbling and/or thin stream and/or incomplete continence
2 = urinary retardation and/or pollakiuria
3 = normal

Table 3 Fuji’s scale.

Excellent: improvement to the extent that the patient could resume the former level of activity
Good: improvement with a minimum decrease in activity
Fair: improvement with an increase need for help
Poor: no improvement or worsening

Table 4 Clinical data of each patient.

Case	Age	Sex	Operation	Pathological level	Mihara's grading	Botox@ injection	Muscle release	JOA score (pre.op.)	JOA score (post.op.)
1	50	F	post decomp (C3-7) and fusion (C2-T1)	C4/5	Grade 3	-	-	2-(-0)-3, 0.5-1-0.5, 1 = 8	3-(-0)-2, 0.5-2-0.5, 2 = 10
2	40	F	post fusion (C2-C7)	multiple	Grade 3	-	+	0-(-1)-0, 1-2-1, 3 = 6	0-(-2)-0, 1-2-1, 0 = 2
3	51	M	post decomp (C3-7) and fusion (C2-T2)	C5/6	Grade 3	+	-	3-(-0.5)-4, 1-2-2, 3 = 14.5	3-(-0)-3, 1.5-2-2, 3 = 14.5
4	64	M	post fusion (C0-C2)	C1/2	Grade 3	+	+	1-(-0)-1, 0.5-2-0.5, 2 = 7	1-(-0)-1, 0.5-2-0.5, 2 = 7
5	58	M	laminoplasty (C3-7)	C3/4	Grade 1	-	-	2-(-2)-0.5, 1-2-2, 2 = 7.5	3-(-0.5)-0, 2-2-2, 2 = 10.5
6	69	F	post decomp (C3-6) and fusion (C2-T2)	C2/3	Grade 2	-	-	1-(-0.5)-0, 0.5-2-0.5, 1 = 4.5	2-(-0)-1.5, 1.5-2-2, 1 = 10
7	56	F	post decomp (C3-6) and fusion (C2-T1)	C3/4/5	Grade 3	+	-	0-(-2)-0, 1-2-1, 3 = 5	1-(-1)-1, 1.5-2-2, 3 = 9.5
8	61	F	post decomp (C3-7) and fusion (C0-T1)	C1/2	Grade 3	+	+	1-(-1)-0, 0.5-0.5-0.5, 3 = 4.5	3-(-0)-3, 1-1-1, 3 = 12
9	72	M	post decomp (C3-5) and fusion (C0-T1)	C3/4	Grade 3	+	+	2-(-0.5)-0, 1-1-0.5, 0 = 4	3-(-0)-1, 1-1-1, 0 = 7
10	52	M	post fusion (C2-T1)	C5/6	Grade 3	+	+	1-(-2)-2, 0.5-2-2.3 = 8.5	3-(-1)-2.5, 1-2-2.3 = 12.5
11	54	M	laminoplasty (C3-5)	C2/3	Grade 3	+	+	0-(-2)-0, 0-0-0, 0 = -2	1-(-2)-0.5, 0-0-0, 3 = 2.5
12	45	F	post decomp (C2-5) and fusion (C0-T1)	C2/3	Grade 4	+	+	0-(-2)-0, 0-0-0, 0 = -2	0-(-2)-0, 0.5-0.5-0.5, 0 = -0.5
13	62	F	post decomp (C1) and fusion (C0-T1)	C1/2	Grade 3	+	+	1-(-2)-1, 0-2-0.5, 3 = 5.5	1-(-1)-0.5, 1.5-2-1.5, 2 = 7.5
14	44	F	post decomp (C3-6) and fusion (C0-T1)	C3/4	Grade 3	+	+	0-(-2)-0, 0-0-2, 3 = 3	1-(-2)-1.5, 1-1-2, 3 = 8.5
15	57	M	post fusion (C0-T2)	C1/2,6/7	Grade 3	+	+	2-(-2)-1, 1-2-2, 3 = 9	3-(-0.5)-2, 1-2-2, 3 = 12.5
16	50	F	post decomp (C3-6) and fusion (C0-T1)	C3/4	Grade 4	+	+	1-(-0)-1, 0.5-2-1, 3 = 8.5	2-(-0)-1.5, 1-2-2, 3 = 11.5

Table 4 Continued.

Case	Recovery rate	Fuji's scale	Alignment (pre.op.)	Alignment (post.op.)	Complication	Additional operation
1	22.2%	excellent	+11° (lordotic)	+4° (straight)	-	-
2	-36.4%	poor	-14° (kyphotic)	+6° (straight)	transient paralysis of upper arm, dislodgement of spinal implant	implant removal, post decomp (C3-5) and fusion (C0-T2)
3	0.0%	good	-2° (kyphotic)	+9° (straight)	-	-
4	0.0%	good	-23° (kyphotic)	-3° (straight)	-	post fusion (C2-T2)
5	31.2%	good	+30° (lordotic)	+20° (lordotic)	transient renal failure	-
6	44.0%	fair	+7° (straight)	+25° (lordotic)	-	-
7	37.5%	good	+16° (lordotic)	+2° (straight)	transient paralysis of upper arm	-
8	60.0%	excellent	+8° (straight)	-8° (kyphotic)	transient paralysis of upper arm	-
9	23.1%	excellent	+20° (lordotic)	+20° (lordotic)	surgical site infection at the left posterior iliac crest	-
10	47.1%	good	+9° (straight)	+9° (straight)	transient paralysis of upper arm	-
11	23.7%	good	+15° (lordotic)	-14° (kyphotic)	-	-
12	7.9%	fair	+37° (lordotic)	+17° (lordotic)	respiratory failure of temporary duration	-
13	47.8%	fair	-35° (kyphotic)	-11° (kyphotic)	-	-
14	39.3%	good	-53° (kyphotic)	-15° (kyphotic)	-	-
15	43.8%	good	-30° (kyphotic)	-5° (straight)	-	-
16	35.3%	excellent	+1° (straight)	+10° (lordotic)	-	-

Illustrative cases

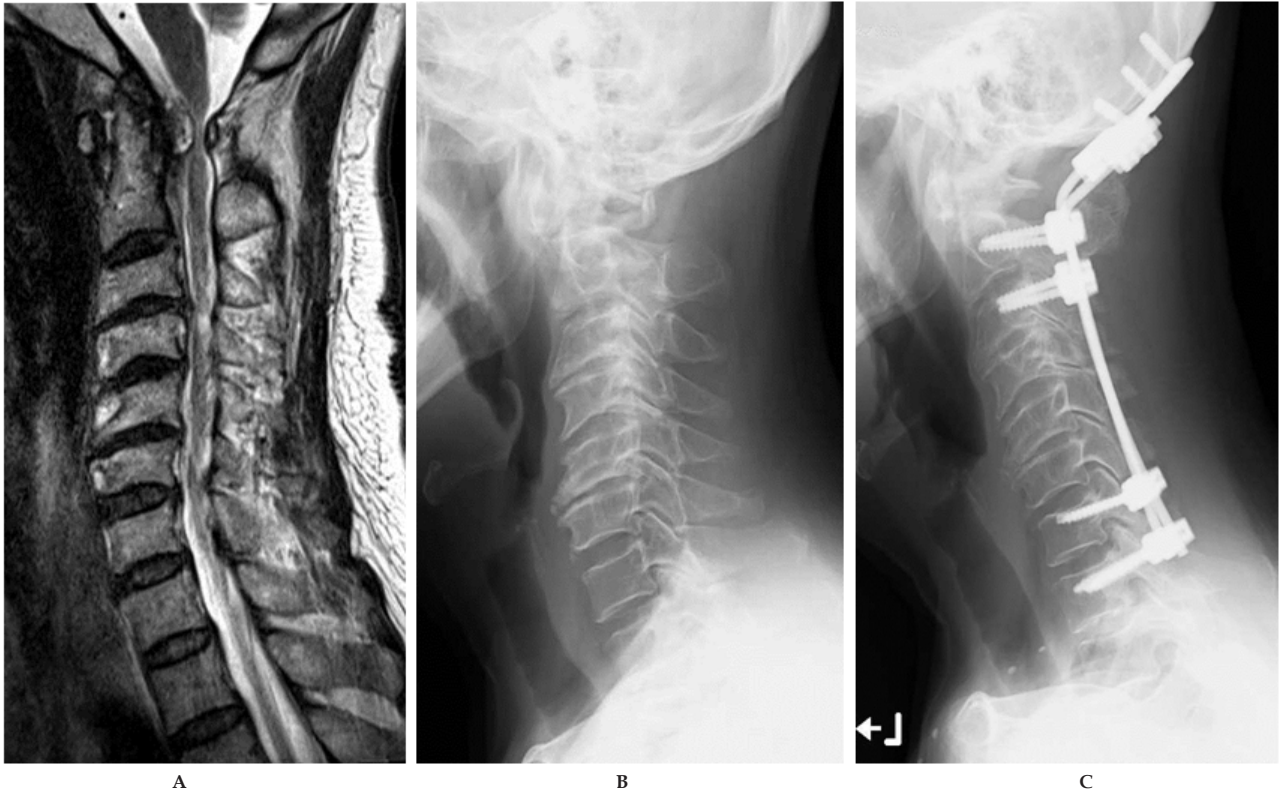
Case 8 (Figure 1): A 61-year-old woman had ACP with grade 3 athetoid cervical movement. She was hospitalized for clumsiness in both hands and inability to walk. On preoperative MRI evaluation, severe cord compression with high intensity change of the spinal cord in T2WI by both pseudo tumor at C2 level and spinal canal stenosis at C3/4 level were confirmed. We performed posterior decompression from C3 to C7 and fusion from C0 to T1 with selective muscle release after botulinum toxin injection. Bone union was confirmed at 1 year after surgery and cervical alignment was also maintained in neutral position. At 3 years after surgery, her physical function was extremely recovered and she became completely independent. Fuji's scale was excellent.

Case 11 (Figure 2): A 54-year-old man had ACP with grade 3 athetoid cervical movement. He usually used a self-controlled electrical wheel chair for move, however, he could walk short distance with any support. At 1 year before hospitalization, his gait disturbance was gradually worsened. He could not walk and his hand function was lost at 2 months before hospitalization. On preoperative MRI evaluation, severe cord compression by spinal canal stenosis at C2/3 level with high intensity change in T2WI was observed. Because he had already had severe physical disability, we performed laminoplasty from C3 to C5 with selective muscle release after botulinum toxin injection to sustain cervical motion. Postoperatively, cervical alignment was maintained just same as preoperative status. His function of extremities was gradually improved after surgery. He could stand up and control an electrical wheel chair by himself again

at 1 year 6 months postoperatively. Fuji's scale was good.

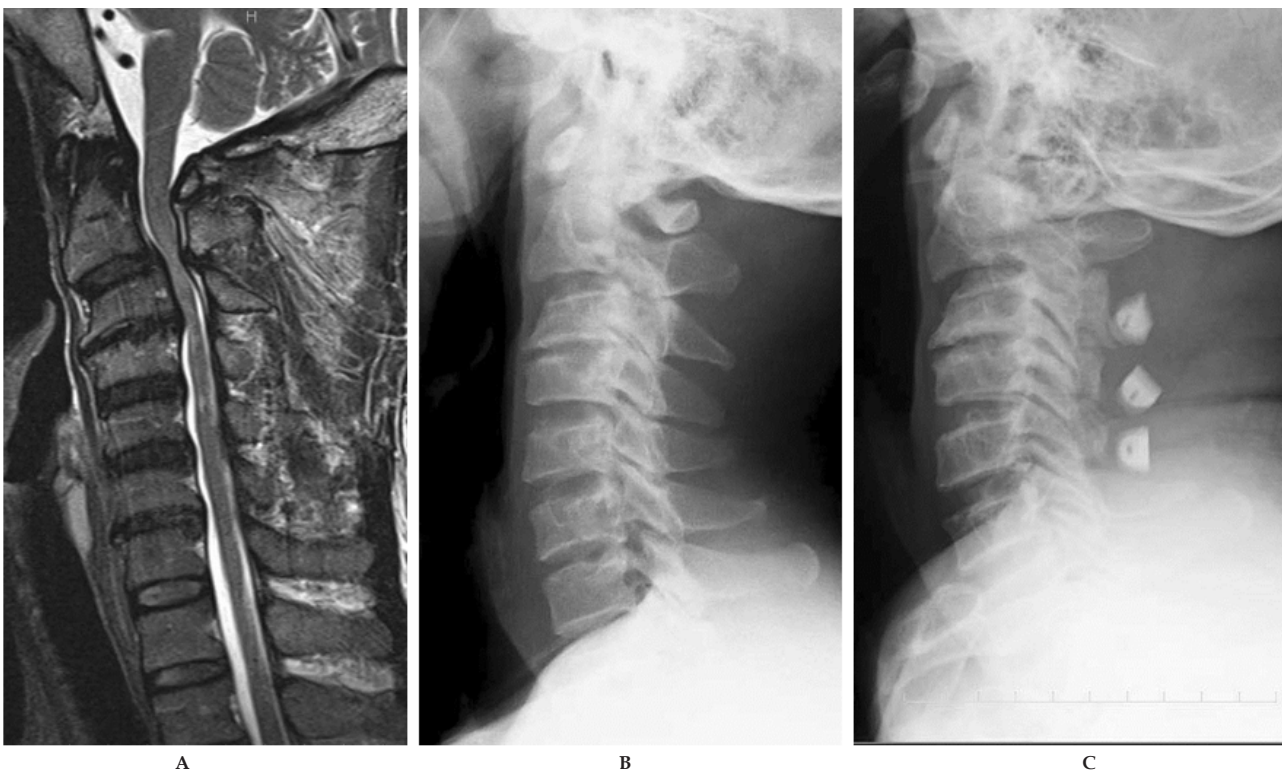
Case 14 (Figure 3): A 44-year-old woman suffering from ACP with grade 3 athetoid cervical movement was referred to our hospital for clumsiness with motor problems in both hands and gait disturbance that acutely happened after falling down. On x-ray radiograph, the cervical spine presented kyphosis with severe destructive change. MRI showed atrophy of the spinal cord from C3 to C6 with high intensity change in T2WI. We performed posterior decompression from C3 to C6 and fusion from C0 to T1 with selective muscle release after botulinum toxin injection. At 6 months after surgery, bone union was confirmed and cervical alignment was improved. In parallel, her physical function has been slowly getting better. She could walk short distance with any supports and care for herself at 1 year 6 months postoperatively. She is now keeping on rehabilitation to expect further restoration. Fuji's scale was good.

Case 16 (Figure 4): A 50-year-old woman had ACP with grade 4 athetoid cervical movement. At hospitalization, she could neither use chopsticks nor walk on a level surface without any support. On preoperative MRI evaluation, severe cord compression by spinal canal stenosis at C3/4 level with high intensity change of the spinal cord in T2WI was confirmed. We performed posterior decompression from C3 to C6 and fusion from C0 to T1 with selective muscle release after botulinum toxin injection. Bone union was confirmed at 7 months after surgery and cervical alignment was also maintained in neutral position. At 1 year after surgery, her physical function was extremely recovered just same as the former level of activity. Fuji's scale was excellent.



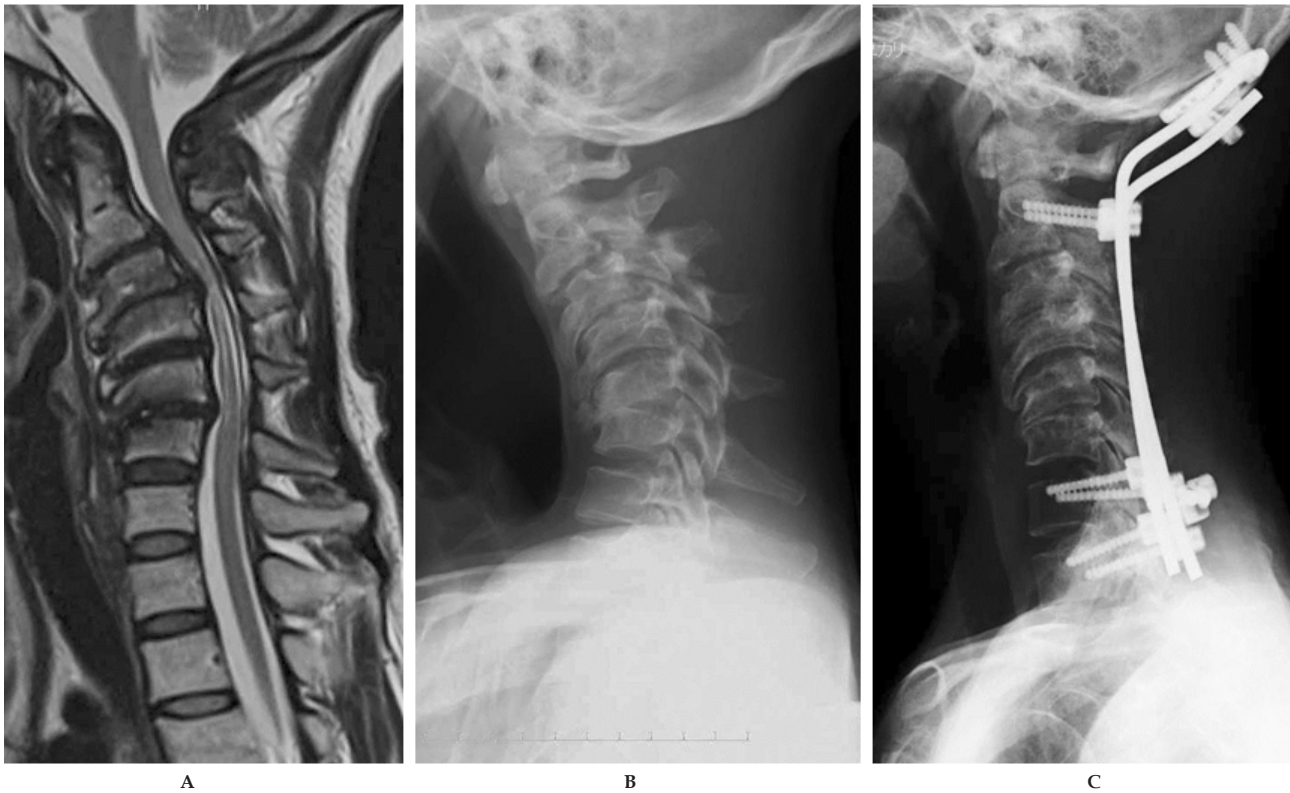Case 8

Figure 1 Case 8. A 61-year-old woman who underwent posterior decompression and fusion. A: preoperative MRI T2 WI sagittal, severe cord compression with high intensity change of the spinal cord in T2WI by both pseudo tumor at C2 level and spinal canal stenosis at C3/4 level were confirmed; B: preoperative x-ray, destructive change was seen in cervical spine with straight alignment; C: postoperative x-ray at 3 years after surgery, bone union was obtained and cervical alignment was mostly maintained in neutral position.



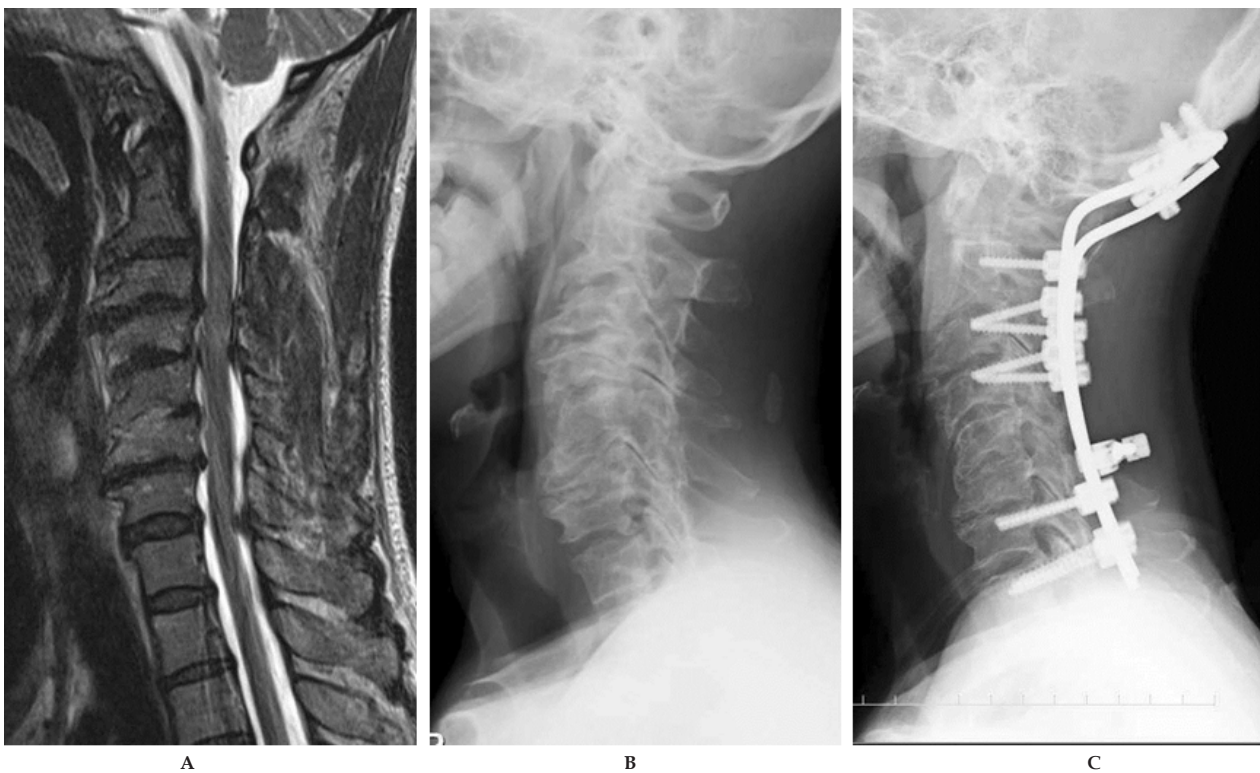Case 11

Figure 2 Case 11. A 54-year-old man who underwent laminoplasty. A: preoperative MRI T2 WI sagittal, severe cord compression with high intensity change at C2/3 level by spinal canal stenosis in T2WI was observed; B: preoperative x-ray, destructive change and developmental canal stenosis was seen in cervical spine with straight alignment; C: postoperative x-ray at 2 years after surgery, postoperative alignment of the cervical spine was maintained just same as preoperative alignment.



Case 14

Figure 3 Case 14. A 44-year-old woman who underwent posterior decompression and fusion. A: preoperative MRI T2 WI sagittal, atrophy of the spinal cord with high intensity change in T2WI from C3 to C6 was observed; B: preoperative x-ray, kyphotic change with severe deformity was indicated; C: postoperative x-ray at 6 months after surgery, cervical alignment was improved and bone union was obtained.



Case 16

Figure 4 Case 16. A 50-year-old woman who underwent posterior decompression and fusion. A: preoperative MRI T2 WI sagittal, severe cord compression with high intensity change of the spinal cord at C3/4 level by spinal canal stenosis was confirmed; B: preoperative x-ray, cervical spine had severe deformity but lordosis was normally remained; C: postoperative x-ray at 7 months after surgery, bone union was confirmed and cervical alignment was also maintained in neutral position.

DISCUSSION

Anderson *et al*^[7] firstly described two cases of CM in patients with ACP in 1962. They suggested that prolonged athetosis does not increase the incidence or the severity of cervical spondylosis, but continuous cervical movement may initiate or aggravate the associated myelopathy. Indeed, the pathophysiology of CM in ACP is much different from other CM without ACP. CM without ACP commonly seen in the elderly patients is usually affected by static factors (e.g., developmental canal stenosis, thickness of yellow ligament, disc degeneration, spur formation). Meanwhile, CM in ACP is seen in the earlier ages and affected more by dynamic factors (e.g., repetitive involuntary athetoid movement) rather than static factors.

Because patients with CM in ACP cannot maintain neck immobilization by themselves, conservative treatments, such as cervical orthosis, cervical halter traction, medication, are usually not effective^[4]. Therefore, surgical treatments accompanied with any procedure to control involuntary cervical movement must be desirable for most patients with CM in ACP.

Levine *et al*^[8] firstly performed surgery for the patients with CM in ACP. They reported that laminectomy temporally improved symptoms but frequently caused greater instability that could exacerbate symptoms in the long-term. After that, various surgical procedures, for example, laminoplasty alone^[9], laminoplasty accompanied with selective muscle release, botulinum toxin injection, ligamentoplasty, or bone graft, anterior fusion^[10-13], posterior fusion, and combined anterior and posterior fusion^[14,15], have been attempted. However, none has produced satisfying long-term results. Single surgical method that promises absolutely stable clinical course has not been established, so it is important to combine some of surgical procedures with respect to each patient. Haro *et al*^[2] indicated the surgical plan for patients with CM associated with ACP based on findings of cervical X-ray. But we feel certain that the physical status and the intensity of athetoid movement are more important than X-ray findings when deciding desirable surgical procedures.

We primarily select posterior spinal fusion fundamentally utilizing pedicle screw system from occipital bone or upper cervical spine to upper thoracic spine and decompressive procedure by laminoplasty is simultaneously performed if necessary. In the case who has severe cervical kyphosis that cannot be corrected by posterior approach solely, combined anterior and posterior instrumentation and fusion must be employed to achieve the bone union with a favorable cervical alignment. However, laminoplasty is performed alone on the patients with mild athetoid movement (grade I) or severe physical disability (unable to not only walk but also feed oneself). This is because degenerative changes must be slow over time in the cases of grade I athetoid movement, and capability of own activities may diminish in the cases of severe physical disability, especially in elderly, if cervical mobility will be completely lost by the long fusion from occipital bone to upper thoracic spine. Also, botulinum toxin injection combined with selective muscle release is basically afforded for the muscles generating involuntary cervical movements irrespective of surgical procedure in these days. Although botulinum toxin has some side effects (e.g. dysphagia, respiratory disorder, allergy), it seems to be beneficial to facilitate the bone union and inhibit the progression of disc degeneration because of its strong muscle relaxant effect^[16-19]. Further, postoperative external fixation with a halo-vest is routinely adopted for a couple of months after fusion surgery. Haro *et al*^[2] stated that a halo-vest is not sufficient

to prevent involuntary cervical movement to stabilize a strut graft, but Lee *et al*^[20] recommend application of a halo-vest during 2.5 to 6 months for the patients with anterior decompression and fusion surgery. Recently, Furuya *et al*^[21] reported no inferiority in clinical outcomes was seen at 1 year follow-up after surgery if postoperative halo-vest use was omitted because of strong instrumented anchors and injection of botulinum toxin. We need more research to decide exact indications of halo-vest application for CM in ACP after cervical fusion surgery. In this regard, Ueda *et al*^[10] presented a patient with skull fracture due to involuntary cervical movement, so greater caution has to be taken when utilizing a halo-vest in these specific patients.

In the long run, clinical relapse can develop secondary to the degradation of adjacent levels. Therefore, prolonged follow-up must be absolutely needed in order to detect possible recurrences. Onari *et al*^[15] reported that recurrence of the disease was rare after an average of 8.6 years follow-up in the cases of combined anterior and posterior fusion, and Wong *et al*^[22] also stated that none of their patients who performed laminectomy with lateral mass fixation showed deterioration at a mean follow-up of 21 months. In contrast, Azuma *et al*^[9] suggested that the possibility of recurrence symptoms after any operative treatment for CM is greater in ACP patients than in nonathetoid patients, and long-term follow-up evaluation is essential in any type of operation for ACP patients. Seichi *et al*^[23] similarly demonstrated 3 cases of CM in ACP with whom neurologic deterioration happened at 8 to 13 years after laminoplasty owing to the adjacent segment's kyphosis and instability. In most of our cases, effects of surgical treatment have been obtained by posterior decompression and fusion combined with some procedures to control athetoid movement in short-term outcomes although long-term outcomes must be fully verified hereafter.

Another major issue of CM in ACP is difficulty in early diagnosis. Most patients have various neurological symptoms due to pre-existing cerebral palsy. They interfere with the identification of neurological signs produced by CM. Dysarthria that disrupts taking medical information is also often present. Further, MRI may be difficult to perform because of relentless neck movement and sometimes has to be conducted under general anesthesia^[1]. In our clinical series, 10 of 16 patients have been already unable to walk by themselves when they firstly visited of our outpatient clinic. For these reasons, aid of the entourage is necessary to detect early neurological changes and to perform an accurate clinical evaluation. Jameson *et al*^[24] pointed out decrease in involuntary cervical movement must be considered as an alarming sign even though it could be interpreted as an improvement. They also proposed that screening of CM in ACP could rely on oriented examination, on therapeutic education of the patients, and on the distribution of information to the concerned associations^[24]. Because early detection and prompt treatment of CM is one of the most important conditions for favorable prognosis, we never neglect making these enlightenment activities to find patients of CM in ACP.

Unfortunately, the number of cases enrolled in current study was small and follow-up periods were short. Therefore, further long-term investigation using much more patients must be necessary to confirm the validity of our strategies. But we believe that our study will contribute to some improvement of the management of CM in patients with ACP because accumulation of these minor data based on clinical experiences from a great number of institutions may be essential to the future solution of issues around such kind of uncommon challenging spinal disorders.

CONCLUSIONS

For the treatment of CM in ACP, evaluations of the pattern and the intensity of athetoid movement are important features for selection of the proper surgical method. Strong fixation from occipital bone to upper thoracic spine accompanied with various athetoid movement control procedures to achieve solid bone union seems to warrant acceptable clinical results for the patients with severe involuntary cervical movement. However, long-term follow-up evaluation is necessary in any type of operation because these patients who undergo operation at a relatively younger age have a potential risk of late cervical deformity or neurological deterioration by their athetoid movement for the entire lifetime.

ACKNOWLEDGMENTS

Author's contributions: Hiroshi Kuroki: conception and design, acquisition of data, analysis and interpretation data; Shinichiro Kubo: acquisition of data; Hideaki Hamanaka: acquisition of data; Naoki Inomata: acquisition of data; Kiyoshi Higa: acquisition of data; Etsuo Chosa: analysis and interpretation data.

CONFLICT OF INTERESTS

There are no conflicts of interest with regard to the present study.

REFERENCES

- Durullé A, Pétrilli S, Le Guiet JL, Brassier G, Nicolas B, Le Tallec H, Gallien P. Cervical spondylotic myelopathy in athetoid cerebral palsy patients: about five cases. *Joint Bone Spine* 2005; **72**: 270-274
- Haro H, Komori H, Okawa A, Shinomiya K. Surgical treatment of cervical spondylotic myelopathy associated with athetoid cerebral palsy. *J Orthop Sci* 2002; **7**: 629-636
- Harada T, Ebara S, Anwar MM, Okawa A, Kajiuira I, Hiroshima K, Ono K. The cervical spine in athetoid cerebral palsy: a radiological study of 180 patients. *J Bone Joint Surg Br* 1996; **78**: 613-619
- Onari K, Kondo S, Mihara H, Iwamura Y. Combined anterior-posterior fusion for cervical spondylotic myelopathy in patients with athetoid cerebral palsy. *J Neurosurg (Spine 1)* 2002; **97**: 13-19
- Mihara H, Kondo S, Kohno M, Niimura T, Onari K, Hachiya M. Clinical analysis of reoperation following surgical treatments for cervical spondylotic myelopathy accompanied with athetoid cerebral palsy. *Rinshoseikeigena* 2008; **43**: 465-472 (in Japanese)
- Fuji T, Yonenobu K, Fujikawa K, Yamashita K, Ebara S, Ono K, Okada K. Cervical radiculopathy or myelopathy secondary to athetoid cerebral palsy. *J Bone Joint Surg Am* 1987; **69**: 815-821
- Anderson WW, Wise BL, Itabashi HH, Jones M. Cervical spondylosis in patients with athetosis. *Neurology* 1962; **12**: 410-412
- Levine RA, Rosenbaum AE, Waltz JM, Scheinberg LC. Cervical spondylosis and dyskinesias. *Neurology* 1970; **20**: 1194-1199
- Azuma S, Seichi A, Ohnishi I, Kawaguchi H, Kitagawa T, Nakamura K. Long-term results of operative treatment for cervical spondylotic myelopathy in patients with athetoid cerebral palsy: an over 10-year follow-up study. *Spine* 2002; **27**: 943-948
- Ueda Y, Yoshikawa T, Koizumi M, Iida J, Miyazaki K, Nishiyama S, Matsuyama E, Kugai A, Takeshima T, Takakura Y. Cervical laminoplasty combined with muscle release in patients with athetoid cerebral palsy. *Spine* 2005; **30**: 2420-2423
- Hirose G, Kadoya S. Cervical spondylotic radiculo-myelopathy in patients with athetoid-dystonic cerebral palsy: clinical evaluation and surgical treatment. *J Neurol Neurosurg Psychiatry* 1984; **47**: 775-780
- Nishihara N, Tanabe G, Nakahara S, Imai T, Murakawa H. Surgical treatment of cervical spondylotic myelopathy complicating athetoid cerebral palsy. *J Bone Joint Surg Br* 1984; **66**: 504-508
- Ito K, Kato F, Yukawa Y. Surgical treatment for cervical spondylotic myelopathy with cervical palsy. *Seikeisaigageka* 2009; **52**: 417-420 (in Japanese)
- Mikawa Y, Watanabe R, Shikata J. Cervical myelo-radiculopathy in athetoid cerebral palsy. *Arch Orthop Trauma Surg* 1997; **116**: 116-118
- Onari K. Surgical treatment for cervical spondylotic myelopathy associated with athetoid cerebral palsy. *J Orthop Sci* 2000; **5**: 439-448
- Racette BA, Laurysen C, Perlmutter JS. Preoperative treatment with botulinum toxin to facilitate cervical fusion in dystonic cerebral palsy. *J Neurosurg* 1998; **88**: 328-330
- Traynelis VC, Ryken T, Rodnitzky RL, Menezes AH. Botulinum toxin enhancement of postoperative immobilization in patients with cervical dystonia: technical note. *J Neurosurg* 1992; **77**: 808-809
- Basciani M, Intiso D, Cioffi RP, Tonali P. Preoperative treatment with botulinum A toxin in patients with cervical disc herniation secondary to dystonic cerebral palsy. *Neuro Sci* 2000; **21**: 63
- Anderson CH, Zimmermann RS, Lyons MK, Simeone F, Brin MF. Perioperative use of botulinum toxin for movement disorder-induced cervical spine disease. *Mov Disord* 1996; **11**: 79-81
- Lee YJ, Chung DS, Kim JT, Bong HJ, Han YM, Park YS. Surgical treatments for cervical spondylotic myelopathy associated with athetoid cerebral palsy. *J Korean Neurosurg Soc* 2008; **43**: 294-299
- Furuya T, Yamazaki M, Okawa A, Misawa S, Sakuma T, Takahashi H, Kato K, Kuwabara S, Takahashi K. Cervical myelopathy in patients with athetoid cerebral palsy. *Spine* 2013; **38**: E151-E157
- Wong AS, Massicotte EM, Fehlings MG. Surgical treatment of cervical myelomyloradiculopathy associated with movement disorders: indications, technique, and clinical outcome. *J Spinal Disord Tech* 2005; **18** (Suppl 1): S107-S114
- Seichi A, Takeshita K, Ohishi I, Kawaguchi H, Akune T, Anamizu Y, Kitagawa T, Nakamura K. Long-term results of double-door laminoplasty for cervical stenotic myelopathy. *Spine* 2001; **26**: 479-487
- Jameson R, Rech C, Garreau de Loubresse C. Cervical myelopathy in athetoid and dystonic cerebral palsy: retrospective study and literature review. *Eur Spine J* 2010; **19**: 706-712

Peer reviewer: Santino Ottavio Tomasi, MD, Department of Neurosurgery, Christian-Doppler-Medical Center, Laboratory for Microsurgical Neuroanatomy, Paracelsus Medical University, Ignaz-Harrer-Str. 79, 020 Salzburg, Austria.