

Spinal Tuberculosis

Thomas Apostolou, Panagiotis Givissis, Ioanna Chatziprodromidou, Iosafat Pinto, Lazaros Tagalidis, Panagiotis Savvidis

Thomas Apostolou, Panagiotis Givissis, Iosafat Pinto, Lazaros Tagalidis, Panagiotis Savvidis, First Orthopaedic Department of Aristotele University of Thessaloniki, Hospital, Greece

Ioanna Chatziprodromidou, Department of Hygiene and Public Health, University of Patras, Greece

Correspondence to: Thomas Apostolou, First Orthopaedic Department of Aristotele University of Thessaloniki, Hospital, Greece

Email: apostolouthomas@hotmail.com

Telephone: +306973213000

Received: October 10, 2014 Revised: December 12, 2014

Accepted: December 19, 2014

Published online: April 23, 2015

Apostolou T, Givissis P, Chatziprodromidou I, Pinto I, Tagalidis L, Savvidis P. Spinal Tuberculosis. *International Journal of Orthopaedics* 2015; 2(2): 232-237 Available from: URL: <http://www.ghrnet.org/index.php/ijo/article/view/971>

INTRODUCTION

Mycobacterium tuberculosis is the cause factor of one of the oldest disease in the world^[1]. This infectious disease has been described in most ancient civilizations while tuberculous bacilli have been detected in Egyptian mummies^[2-4] Iron Age remains from Asia^[5,6] and European skeletons from the Middle Ages^[7] by histological or polymerase chain reaction (PCR) studies^[4,8].

Musculoskeletal involvement of tuberculosis is estimated in 1-13% of patients and spinal tuberculosis, also known as "Pott's disease", represents the most common type of extrapulmonary TB^[9].

Pott described in 1776 the cold abscess as a result of hematogenous dissemination from a primary focus. The infection reaches the vertebral body through the arteries after bacilleemia or rarely through the Batson's plexus of veins^[1]. The disease spreads to the adjacent vertebral bodies under the longitudinal ligament. The abscess tends to remain localized under anterior longitudinal ligament and enters the spinal canal through intervertebral foramina. This results in narrowing of the spinal canal and the normal thoracic kyphosis forces the pathological tissue inside the spinal canal causing cord compression, unlike in lumbar spine where it trickles down in psoas muscle^[10,11].

The incidence of neurological involvement in Pott's disease is 10-20% in highly developed nations and 20-41% in underdeveloped countries. Thoracic spine is the most commonly associated with neurological complications, while paraplegia rarely occurs in a tuberculous affection below lumbar one vertebra, where the spinal canal is capacious and contains only cauda equina.

EPIDEMIOLOGY

Despite a marked improvement in the socioeconomic status of many countries and the availability of effective antitubercular

ABSTRACT

Tuberculosis of the spine is a challenging disease to treat because of the prolonged time of conservative treatment and the technical difficulties of surgical intervention. The disease remains an important public health issue in developing countries, but is also returning in developed countries due to immigration and especially in the immune compromised patients. The most common symptom reported is back pain and the most frequent segment involved is the thoracic spine. The early diagnosis and treatment is mandatory in order to avoid neurological complications (Pott's paraplegia) and grotesque spinal deformity. Medical treatment or combined medical and surgical strategies can control the disease in most patients. Conservative treatment with a combination of anti-TB drugs yields similar long term results when compared to surgery in patients with no neurological deficit or instability. If indicated radical debridement and instrumentation of the involved spine combined with prolonged chemotherapy result in improvement in quality of life of patients, better functional and cosmetic outcomes and closer to normal-like spine.

© 2015 ACT. All rights reserved.

Key words: Pott's Disease; Mycobacterium Tuberculosis; Kyphosis; Neurological Deficit; Review

drugs, the disease still remains an important public health issue, having serious medical, social and financial impacts, especially in developing countries^[12]. The impact of acquired immunodeficiency syndrome (AIDS) pandemic and immigration have increased the rate of TB between 1980 and 1990, causing 2-3 million deaths annually worldwide^[13]. In some African countries, the number of reported TB cases have doubled or even tripled from 2001 to 2003 because of the spread of HIV/AIDS^[14,15].

The World Health Organization (WHO) has estimated that every year 10 million people are newly infected with about 95% of cases being in developing countries. China alone has 1.4 million new cases every year and there are 1.81 million deaths from the disease in Asia each year.

The USA Center for Disease Control (CDC) has predicted that the number of new diagnosis of active TB worldwide would increase from 7.5 to 11.8 million per year. The incidence of TB would rise from 143 to 173 per 100,000 and deaths due to disease would climb from 2.5 to 3.5 million or more per year^[14,15].

PATHOPHYSIOLOGY

Spinal tuberculosis is a potentially life-threatening infection caused by an aerobic, weakly Gram-positive bacillus, the *Mycobacterium tuberculosis*. The spondylitis is the result of hematogenous spread of the disease. The phagocytosis of the bacteria by the macrophages leads to hypersensitivity immune response, producing cytokines and with the contribution of other inflammatory cells results in the formation of a granuloma and the macrophages differentiate into foam cells, giant cells and epithelioid cells. The center of the granuloma becomes necrotic and finally the lytic lesion leads to vertebra body collapse and kyphotic deformity. The expansion of the cold abscess follows the path of the least resistance, containing necrotic debris. The spread of the disease occurs beneath the anterior and the posterior longitudinal ligament to the adjacent levels. Spontaneously, skin sinuses and drain may be observed. Sometimes, compression of the nerve roots due to vertebrae collapse causes radiculopathy, but more commonly spinal cord or cauda equina compression may lead to myelopathy or paraplegia which is divided in two types: (1) paraplegia of early onset, usually within first 2 years with active disease, inflammatory edema of the spinal cord and myelomalacia; (2) paraplegia of the late onset, commonly due to kyphotic formation from non-union, with chronic spinal cord compression and atrophy with or without active disease^[16]. No study so far has conclusively correlated the severity of paraplegia with the degree of kyphosis. However, with concomitant vascular cause or mechanical instability the neural deficit may develop at lesser canal compromise^[17].

Mild cord atrophy was observed in all patients who had excellent neural recovery after non-operative/operative treatment. In paraplegia with healed disease, spinal cord showed edema and severe reduction in cord volume in patients with negligible neural deficit. In a patient with severe neural deficit, cord atrophy was associated with myelomalacia/syringomyelia^[14,18,20].

CLINICAL FEATURES

The mean age of patients with spinal tuberculosis is 45-60 years with no sex predominance^[21,22]. However, there are some studies reporting an age distribution with two peaks, one between 20 and 30 years concerning immigrants or HIV infected patients (up to 60% of cases) and a second between 60 and 70 years^[23].

The progression of the disease is slow and the duration of the symptoms ranges from 2 weeks to several years. Unfortunately, in developing countries, the appearance of weakness, in a significant percentage, brings the patient to the clinician (Table 1a). Rarely when cervical spine is effected, quadriplegia may exist, as well as hoarseness because of recurrent laryngeal nerve paralysis, dysphagia and respiratory stridor ("Millar asthma") due to anterior abscess formation. Sudden death has been reported in cervical disease after erosion into the great vessels. Thoracic spine involvement with neurological deficit is the result of spinal cord compression due to severe kyphosis (Pott's paraplegia) (Table 1b).

In diseased lumbar spine, the paraplegia is of lower motor neuron (LMN) type. Thoracolumbar segment is affected in around half of cases. General constitutional symptoms present in the early stages of the disease, including weakness, malaise, night sweats, some times fever and weight loss. Pain is the most predominant symptom in more than 80% of the patients, while neurological deficit reported in a range from 12.5% to 100%^[23-25].

Table 1a Clinical Features of Spinal TB depending on the infected segment.

General Symptoms	Cervical	Thoracic	Lumbar
Weakness	Dysphagia	Kyphosis	LMN Paraplegia
Malaise	Hoarseness	Pott's Paraplegia	Iliac fossa abscess
Night sweats	Respiratory Stridor		Gluteus abscess
Weight Loss	Stiffness		
Back pain	Retropharyngeal Abscess		
Fever	Supraclavicular fossa Abscess		
	Quadriplegia		

Table 1b Pott's Paraplegia.

Pott's Paraplegia	
Symptoms	Reflexes
Weakness	Increased tendon reflexes
Paresthesia or Numbness	Babinski
Disturbance of bladder control	Clonus

DIAGNOSIS

Considered as a chronic infection TB spondylitis has similar findings with such diseases from the laboratory tests, as anemia, hypoproteinemia, erythrocyte sedimentation rate (ESR) and C-reactive protein (CRP) elevation. Mantoux test (tuberculin skin test) may be helpful, but is not diagnostic, especially in patients who have been exposed subclinically to the disease or have received BCG vaccination. It is also not sensitive in immune-compromised patients^[26].

A relatively new method for detecting T cells specific for *Mycobacterium Tuberculosis* antigens is the interferon gamma – release assays (IGRA), with sensitivity of 83-90%. The method is more specific than the Mantoux test and the sensitivity remains high in immune-compromised patients, while is not confounded by the BCG vaccination. The main disadvantage of the test is that it cannot differentiate active from treated infections^[27]. Various laboratory methods have been developed for earlier and more effective diagnosis. Polymerase chain reaction (PCR) is one of them, with sensitivity 95-98% for diagnosis TB from smear-positive and culture-positive cases, but it has lower sensitivity 57-78% for smear negative and culture-positive cases^[30]. It is a non-culture, molecular diagnostic test, which amplifies the DNA of the TB bacillus for

identification. The amplified segment of the TB DNA is subsequently detected with the southern blot hybridization technique. In extra pulmonary tuberculosis, where preoperative sample collection for any microbiological diagnostic procedure is almost not possible, PCR as a diagnostic tool is very useful. Sample required is relatively small and can be from any part of diseased tissue. Even as little as 1 to 10 bacilli in the sample are sufficient for diagnosis.

Radiographic findings, in early stages, reveal localized osteopenia and sometimes decrease of one or more disc spaces. A fusiform radiopaque shadow against a radiolucent background of the lungs is frequently the typical appearance of a paraspinal abscess. Vertebral collapse, described by Seddon as “concertina collapse” is found during the progression of the disease, as well as soft tissue swelling and its late calcification^[28].

Computed tomography (CT) scanning with contrast evaluates better the bone destruction, vertebral columns involvement and possible instability. Magnetic resonance imaging (MRI) allows further delineation of the soft tissue components, activity of the disease and status of the spinal cord^[29] (Figures 1 and 2). However, none of the above tests help to confirm TB disease.

Percutaneous biopsy of the lesion may give positive culture up to 80%, while open biopsy may be necessary if the fine needle biopsy is unsuccessful or if it could be done during a scheduled open procedure^[19].

Nevertheless, TB bacillus is difficult to be cultured due to its fastidious growth requirements and slow growth rate.

The differential diagnosis includes metastatic disease, which usually affects the vertebral body and spaces the intervertebral disc, lymphoma, pyogenic and fungal infections, like brucellar spondylitis especially in endemic areas, inflammatory and neuropathic spondyloarthropathies, sarcoidosis and other granulomatous diseases, deposition diseases and degenerative disc disease^[9,31-35].

TREATMENT

The objectives of treatment are to control the infection and achieve a bacteriological use of the disease, decompress the neural elements and treat the instability and spinal deformity. Chemotherapy leads to a favorable outcome and is the main state of treatment for TB infection. Multi drug prolonged and uninterrupted drug administration is important for optimal results. Several treatment regimes have been described and British Medical Research Council has assessed the optimal duration of chemotherapy from six to 18 months, in series of international studies conducted in India, Korea and Hong Kong^[36]. The first-line anti-tuberculous drugs are the following five: streptomycin, rifampicin, pyrazinamide, isoniazid and ethambutol (Table 2a, 2b). The above adequate, appropriate and supervised chemotherapy can lead to favorable outcome and prevent the hazards of drug resistance. Failure of chemotherapy is frequently due to failure of compliance, as well as to the increasing incidence of drug-resistant TB worldwide. Therefore, it is very important to know bacterial sensitivities before starting chemotherapy, and sufficient care must be taken to educate the patient on the need or compliance. Although several second-line anti-TB drugs exist, one should have in mind that these chemotherapeutic agents are less efficacious but more toxic than the first-line drugs (Table 3).

The indications for operative treatment include failed conservative treatment, presence of a large abscess, progressive neurologic deficit, instability and deformity. The radical surgery, known as “the Hong Kong operation”, was published in 1956 by Hodgson and Stock^[37]. The authors described a thorough debridement of the tuberculous

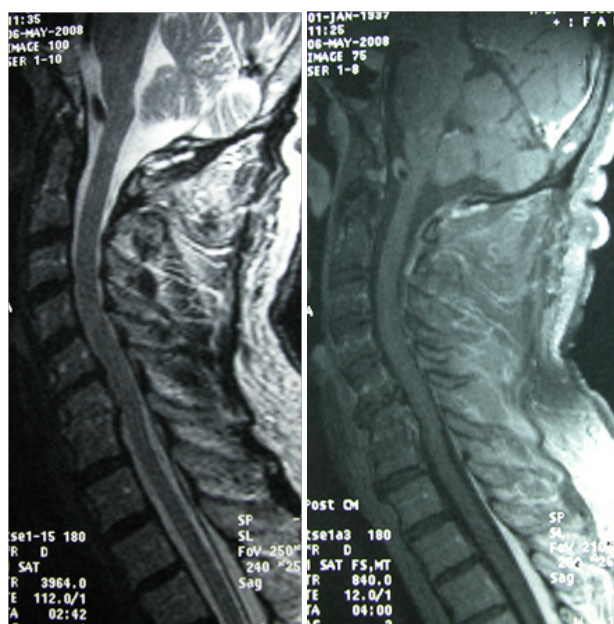


Figure 1 MRI of cervical spine imaging C5-C6 and C6-C7 lesion.

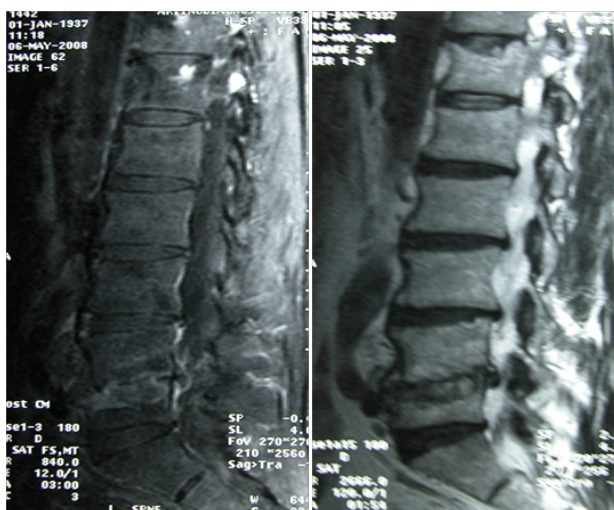


Figure 2 MRI of lumbar spine imaging L4-L5 lesion.

Table 2a First Line anti-TB drugs.

First Line anti-TB Drugs	Mechanism of Action	Administration	Dosing
Isoniazid	Bactericidal	GI Absorption	300 mg/day
Rifampicin	Bacteriostatic or Bactericidal	GI Absorption	600 mg/day
Pyrazinamide	Bactericidal in an acid environment	GI Absorption	15-30 mg/kg/day (<2 g/day)
Streptomycin	Bactericidal in an alkaline environment	Parenterally	15 mg/kg/12 h (<1 g/day)
Ethambutol	Bacteriostatic	GI Absorption	40-55kg: 800 mg/day; 56-75kg: 1.2g/day; >75kg: 1.6 g/day.

focus until the complete decompression of the cord, excising of the pus, caseous tissue and necrotic bone. When bleeding cancellous bone was exposed from the cephalad and caudal vertebrae, a strut graft from a cut rib or a tricortical iliac crest bone graft was used for fusion. Biomechanically, the environment was less stable and

Table 2b Adverse Effects of first line anti-TB drugs.

Adverse Effects	Isoniazid	Rifampicin	Pyrazinamide	Streptomycin	Ethambutol
	Peripheral Neuropathy	Increase of LFT's	Malaise	Neurotoxicity	Acute gout
	Mild increase of LFT's	Rash	Nausea	Nephrotoxicity	Abdominal Pain
	Loss of appetite	Epigastric Distress	Vomiting	Ototoxicity	Anaphylaxis
	Nausea	Anorexia	Anorexia	Fever	Anorexia
	Vomiting	Nausea	Arthralgia	Headache	Disorientation
	Stomach Pain	Vomiting	Myalgia	Paresthesia	Fever
	Weakness	Diarrhea		Rash	Headache
	Lethargy	Cramps		Anemia	Nausea
	Thrombocytopenia	Pancreatitis		Tremor	LFT abnormalities
	Anemia	Pseudomembranous colitis		Drowsiness	Malaise

Table 3 Second line anti-TB Drugs.

Second Line anti-TB Drugs	Dosing
Cycloserine	Initial: 250mg per Day Maintenance: 500mg-1g per Day per os
Ethionamide	15-20mg/kg/Day per os
Kanamycin	5-7,5mg/kg/dose divided 8-12h IM or IV
Capreomycin	Initial:1g/Day (60-120 days) Maintenance:1g two or three times a week IM or IV
P-aminosalicylic(PAS)	4g/Day per os

frequently patients required prolonged immobilization or additional posterior instrumentation.

An appealing alternative would be to perform someone radical debridement, combined with instrumented anterior stabilization (Figures 3, 4 and 5). The use of a cage and bone grafts instead of a structural bone graft alone allows for more secure, accurate and dependable deformity correction. The cage provides a more rigid fixation construct and minimizes the risk of graft subsidence or dislodgement, that are well-documented complications when structural bone graft alone is used^[38,42] (Figure 6).

The use of implants in the presence of TB spondylitis is considered nowadays, to be safe although, in the past, number of authors treated spondylitis in two stages, initially performing debridement and bone grafting followed by delayed instrumented fusion^[43-46]. Experimental studies have shown that mycobacteria form scanty biofilm to stainless steel, while pyogenic organisms, as Staphylococcus, heavily colonize on stainless steel. Moreover, titanium alloys generally are considered relatively friendly toward the host bone and are reported to have lower infection risk^[47].

Several approaches to the tubercular spine have been described as anterior, posterior, combined, anterolateral (extrapleural) or posterior transforaminal^[48-51]. The surgical approach depends on the nature of cage, the availability of appropriate facilities and trained personnel.

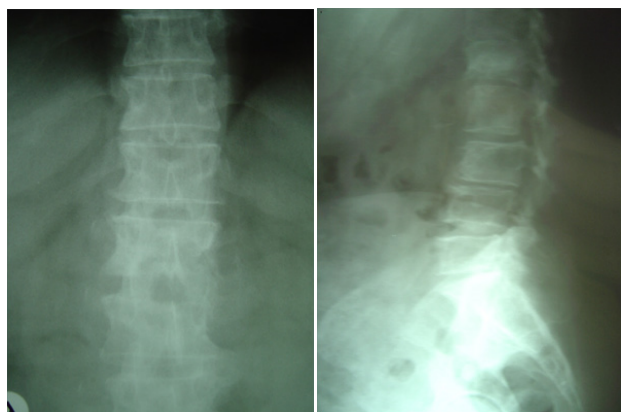


Figure 3 Plain X-rays (F-P) of L1-L2 lesion.

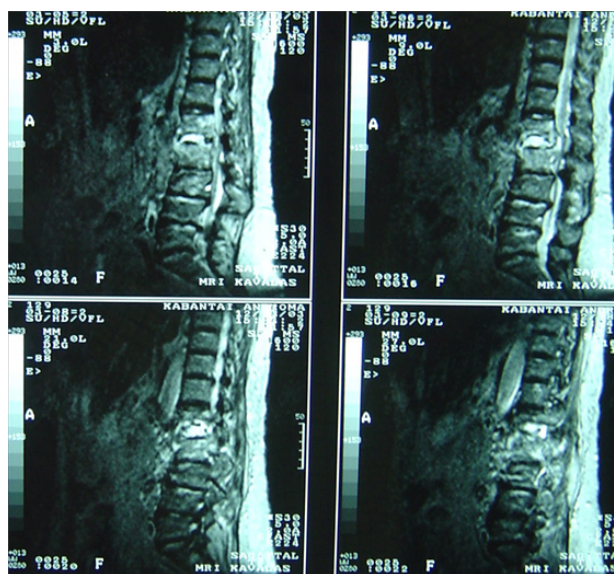


Figure 4 MRI (Sagittal View) of L1-L2 lesion (same patient).

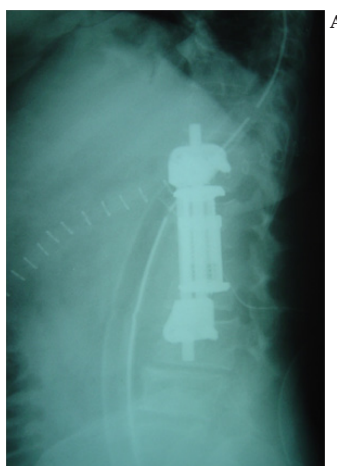
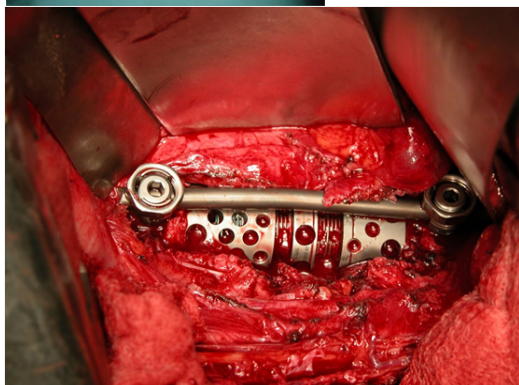


Figure 5 A: Post-operative X-ray imaging a titanium cage and T12-L3 anterior stabilization; **B:** Intraoperative picture during fixation with an expandable cage (same patient).



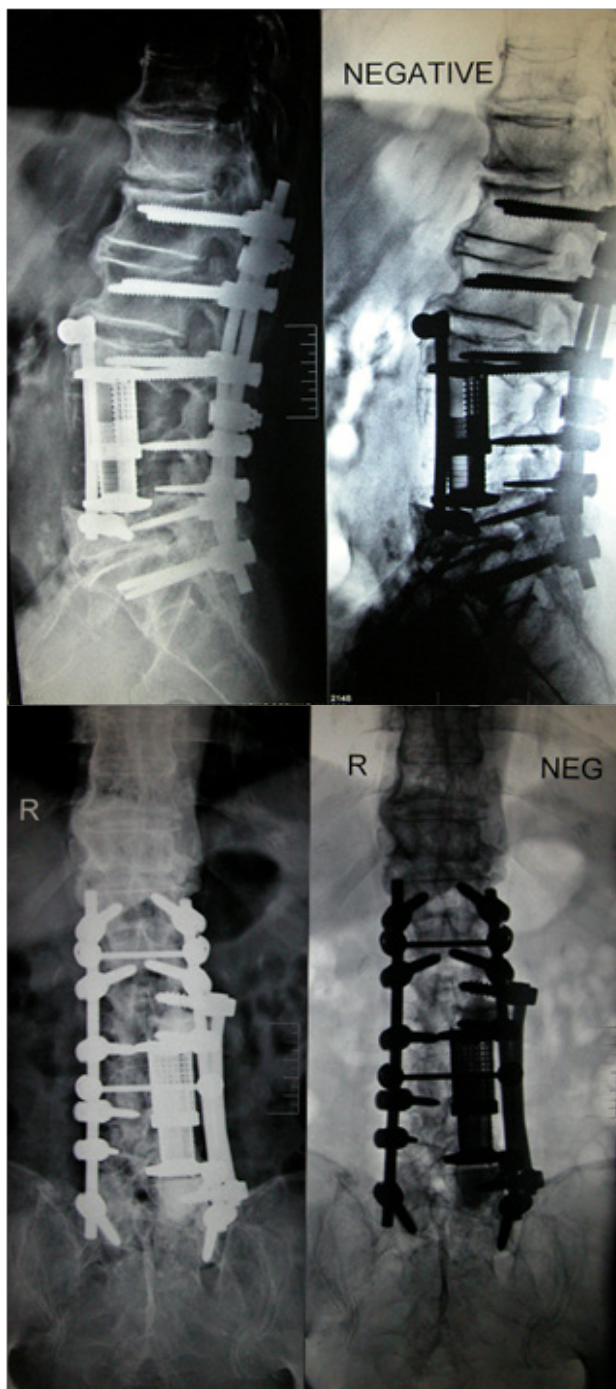


Figure 6 Postoperative X-rays (F-P) imaging 360° lumbar fusion.

CONCLUSION

Tuberculous spondylitis is a destructive infection of the spine. Though anti-TB chemotherapy is the mainstay of treatment, large abscess, instability and deformity may compromise the vertebral column and canal, resulting in late-onset paraplegia with consequent poor changes of neural recovery postoperatively. Radical debridement forms the basis for surgical intervention and supplemental instrumentation gives even more promising results.

CONFLICT OF INTERESTS

There are no conflicts of interest with regard to the present study.

REFERENCES

- 1 Tuli SM. Tuberculosis of the spine: a historical review. *Clin Orthop Relat Res* 2007; **460**: 29-38
- 2 Chastel C. When the Egyptian mummies are speaking about the infections that have made them ill. *Hist Sci Med* 2004; **38**: 147-155
- 3 Gardam M, Lim S. Mycobacterial osteomyelitis and arthritis. *Infect Dis Clin N Am* 2005; **19**: 819-830
- 4 Zink A, Chass CJ, Reisch U, Szeimies U, Nerlich AG. Molecular analysis of skeletal tuberculosis in an ancient Egyptian population. *J Med Microbiol* 2001; **50**: 355-566
- 5 Sharief HS, Clarc DC, Ashbed MY, Haddad MC, alDeeb SM, Yaqub B, alMoutaery KR. Granulomatous spinal infections. MR imaging. *Radiology* 1990; **177**: 101-107
- 6 Tayles N, Buckley HR. Leprosy and tuberculosis in Iron Age Southeast Asia. *Am J Phys Anthropol* 2004; **125**: 239-256
- 7 Good RC, Snide DE. Isolation of nontuberculous mycobacteria in the United States 1980. *J Infect Dis* 1982; **146**: 829-833
- 8 Zink AR, Grabner W, Nerlich AG. Molecular identification of human tuberculosis in recent and historic bone tissue samples. The role of molecular techniques for the study of historic tuberculosis. *Am J Phys Anthropol* 2005; **126**: 32-47
- 9 Jevtic V. Vertebral infection. *Eur Radiol* 2004; **14**: E43-E52
- 10 Jain AK. Treatment of tuberculosis of the spine with neurologic complications in symposium on Osteo-articular tuberculosis. *Clin Orthop Rel Res* 2002; **398**: 75-84
- 11 Crenshaw AH (ed), Tuberculosis of spine, Campbell's operative orthopaedics, vol 4, 7th edn. CV Mosby, St. Louis.1987; pp 3326-3342
- 12 Mulleman D, Mammou S, Griffoul I, Avimadje A, Goupille P, Valat JP. Characteristics of patients with spinal tuberculosis in a French teaching hospital. *Joint Bone Spine* 2006; **73**: 424-427
- 13 Ruiz Manzano. J Tuberculosis and immigration. *Med Clin (Barc)* 2000; **114**: 257-258
- 14 Moon MS. Tuberculosis of the spine; controversies and new challenges. *Spine* 1997; **22(15)**: 1791-1797
- 15 Moon MS. Tuberculosis of the spine-contemporary thoughts on current issues and perspective views. *Curr Orthop* 2007; **21**: 364-379
- 16 Luk KD, Krishna M. Spinal stenosis above a healed tuberculosis kyphosis. A case report. *Spine* 1996; **21(9)**: 1098-1101
- 17 Camillo FX. Infection of the Spine. In: Canale ST (ed) Campbell's Operative Orthopaedics, 11th edn. Mosby, Philadelphia. 2008; pp 2237-2271
- 18 Rattan A. PCR for diagnosis of tuberculosis: where are we now? *Indian J Tuberc* 2000; **47**: 79-82
- 19 Christodoulou A, Zidrou C, Savvidou OD, Givivissis P, Apostolou T, Mavrogenis AF, Papagelopoulos PJ, Pournaras J. Percutaneous Harlow Wood needle biopsy of the spine: A retrospective analysis of 238 spinal lesions. *Orthopedics*. 2005; **28**: 784-789.
- 20 Medical Research Council Working Party on Tuberculosis of the Spine, Controlled trial of short-course regimens of chemotherapy in ambulatory treatment of spinal tuberculosis. *J Bone Joint Surg* 1993; **75**: 240-248
- 21 Ousehal A, Gharbi A, Zamiaty W, Saidi A, Kadiri R. Imagerie di Mal de Pott. *Neurochirurgie*. 2002; **48(5)**: 409-418
- 22 Smith A, Weinstein MA, Mizushima A, Coughin B, Hayden SP, Lakin MM, Lanzieri CF. MR imaging characteristics of tuberculous spondylitis vs vertebral osteomyelitis. *AJR* 1989; **153**: 399-405
- 23 Colmenero JD, Jime'nez-Mejí'as ME, Reguera JM, Palomino-Nica's J, Ruiz-Mesa JD, Ma'rquez-Rivas J, Lozano A, Pacho'n J. Tuberculous vertebral osteomyelitis in the new millennium: still a diagnostic and therapeutic challenge. *Eur J Clin Microbiol Infect Dis* 2004; **23**: 477-483
- 24 Barriere V, Gepner P, Bricaire F, Blety O, Caumes E. Current as-

- pects of spinal tuberculosis: apropos of 16 case reports. *Ann Med Interne (Paris)* 1999; **150**: 363-369
- 25 Rasit AH, Razak M, Ting FS. The pattern of spinal tuberculosis in Sarawak General Hospital. *Med J Malaysia* 2001; **56**: 143-150
 - 26 Marques CDL, Duarte A, LBP, de Lorena VMB, Souza JR, Souza WV, de Miranda Gomes Y, de Carvalho EMF. Evaluation of an interferon gamma assay in the diagnosis of latent tuberculosis infection in patients with rheumatoid arthritis. *Rheumatol* 2009; Int **30**: 57-62
 - 27 Herrera Victor, Perry Sharon, Parsonnet Julie, Banaei Niaz. Clinical application and limitations of interferon-g release assays for the diagnosis of latent tuberculosis infection. *Clin Pract* 2011; **52**: 1031-1037
 - 28 Seddon HJ. Pott's paraplegia, prognosis and treatment. *Br J Surg* 1935; **22**: 769-799
 - 29 Gupta RK, Agarwal P, Rastogi H, Kumar S, Phadke RV, Krishnani N. Problems in distinguishing spinal tuberculosis from neoplasia on MRI. *Neuroradiology* 1996; **38**: S97-S104
 - 30 Rattan A. PCR for diagnosis of tuberculosis: where are we now? *Indian J Tuberc* 2000; **47**: 79-82
 - 31 Moore SL, Rafii M. Imaging of musculoskeletal and spinal tuberculosis. *Radiol Clin North Am* 2001; **39(2)**: 329-342
 - 32 Moorthy S, Prabhu N. Spectrum of MR imaging findings in spinal tuberculosis. *AJR* 2002; **179**: 979-983
 - 33 Hatem SF, Schils JP. Imaging of infections and inflammatory conditions of the spine. *Semin Musculoskelet Radiol* 2000; **4(3)**: 329-347
 - 34 Burrill J, Williams C, Bains G, Conder G, Hine A, Misra R. Tuberculosis: a radiologic review. *Radiographics*. 2007; **27**: 1255-1273
 - 35 Forrester DM. Infectious spondylitis. *Semin Ultrasound CT MRI* 2004; **25**: 461-473
 - 36 Medical Research Council Working Party on Tuberculosis of the Spine, A controlled trial of six-month and nine-month regimens of chemotherapy in patients undergoing radical surgery for tuberculosis of the spine in Hong Kong. Tenth report of the Medical Research Council Working Party on Tuberculosis of the Spine. 1986; *Tubercle* **67**: 243-259
 - 37 Hodgson AR, Stock FE. Anterior spinal fusion a preliminary communication on the radical treatment of Pott's disease and Pott's paraplegia. *The British journal of surgery* 1956; **44(185)**: 266-275
 - 38 Faraj AA, Webb JK. Spinal instrumentation for primary pyogenic infection: Report of 31 patients. *Acta Orthop Belg* 2000; **66**: 242-247
 - 39 Gurr KR, McAfee PC, Shih CM. Biomechanical analysis of anterior and posterior instrumentation systems following corpectomy: A calf spine model. *J Bone Joint Surg* 1988; **70**: 1182-1191
 - 40 Upadhyay SS, Sell P, Saji M, Hsu LC. Surgical management of spinal tuberculosis in adults: Hong Kong operation compared with debridement surgery for short and long term outcome of deformity. *Clin Orthop Relat Res* 1994; **302**: 173-182
 - 41 Upadhyay SS, Sell P, Saji MJ, Sell B, Yau C, Leong JCY. 17-year prospective study of surgical management of spinal tuberculosis in children: Hong Kong operation combined with debridement surgery for short- and long-term outcome of deformity. *Spine* 1993; **18**: 1704-1711
 - 42 Yilmaz G, Selek HY, Gurkan I, Erdemli B, Korkusuz Z. Anterior instrumentation for the spinal tuberculosis. *J Bone Joint Surg* 1999; **81**: 1261-1267
 - 43 Carragee EJ. The clinical use of magnetic resonance imaging in pyogenic vertebral osteomyelitis. *Spine* 1997; **22**: 780-785
 - 44 Dimar JR, Carreon RY, Glassman SD, Campbell MJ, Hartman MJ, Johnson JR. Treatment of pyogenic vertebral osteomyelitis with anterior debridement and fusion followed by delayed posterior spinal fusion. *Spine* 2004; **29**: 326-332
 - 45 Fukuta S, Miyamoto K, Masuda T, Hosoe H, Kodama H, Nishimoto H, Sakaeda H, Shimizu K. Two stage (posterior and anterior) surgical Treatment using posterior spinal instrumentation for pyogenic and tuberculous spondylitis. *Spine* 2003; **28**: E302-E308
 - 46 Safran O, Rand N, Kaplan L, Sagiv S, Floman Y. Sequential or simultaneous, same-day anterior decompression and posterior stabilization in the management of vertebral osteomyelitis in the lumbar spine. *Spine* 1998; **23**: 1885-1890
 - 47 Soutanis K, Mantelos G, Pagiatakis A, Soucacos PN. Late infection in patients with scoliosis treated with spinal instrumentation. *Clin Orthop Relat Res* 2003; **411**: 116-123
 - 48 Louw JA. Spinal tuberculosis with neurological deficit. Treatment with anterior vascularised rib grafts, posterior osteotomies and fusion. *J Bone Joint Surg* 1990; **Br 72(4)**: 686-693
 - 49 Moon MS, Woo YK, Lee KS, Ha KY, Kim SS, Sun DH. Posterior instrumentation and anterior interbody fusion for tuberculous kyphosis of dorsal and lumbar spines. *Spine (Phila Pa 1976)* 1995; **20(17)**: 1910-1916
 - 50 Jain AK, Dhammi IK, Prashad B, Sinha S, Mishra P. Simultaneous anterior decompression and posterior instrumentation of the tuberculous spine using an anterolateral extrapleural approach. *J Bone Joint Surg* 2008; **Br 90(11)**: 1477-1481. doi: 10.1302/0301-620X.90B11.20972
 - 51 JY, Surgical management for multilevel noncontiguous thoracic spinal tuberculosis by single-stage posterior transforaminal thoracic debridement, limited decompression, interbody fusion, and posterior instrumentation (modified TTIF). *Arch Orthop Trauma Surg* 2012; **132(6)**: 751-757. doi:10.1007/s00402-012-1473-z

Peer reviewes: Xiao-Dong WU, M.D., Orthopedic department, Shanghai Changzheng Hospital, Second Military Medical University. 415 Fengyang Road, Shanghai, 200003, China
 AndreiAndrei Fernandes Joaquim, Department of Neurology, Campus Universitário Zeferino Vaz, Barão Geraldo, Campinas, Brazil.