

Inflammation and Bone Remodeling Pathologies

Marjolaine Gosset, Gael Y Rochefort

Marjolaine Gosset, Gael Y Rochefort, EA 2496, Orofacial Pathologies, Imaging and Biotherapies, Dental school University Paris Descartes, Sorbonne Paris Cité, France

Marjolaine Gosset, Department of Odontology, Groupement Hospitalier La Pitié Salpêtrière, Charles Foix, Hospital Charles Foix, AP-HP, France

Correspondence to: Gael Y Rochefort, EA 2496, Dental School University Paris Descartes, 1 rue Maurice Arnoux 92120 Montrouge, France

Email: gael.rochefort@gmail.com

Telephone: +33-0158-076-792

Fax: +33-0-158-076-724

Received: August 9, 2014

Revised: October 11, 2014

Accepted: October 16, 2014

Published online: December 23, 2014

ABSTRACT

Bone remodeling is a physiological process determined by the sequential and coordinated interaction involving osteocytes, osteoclasts and osteoblasts, as well as inflammatory cells and mediators. This balance between osteoblastic bone formation and osteoclastic resorption is disrupted during chronic inflammation, leading to local and systemic changes in bone architecture and quality. In this review, the influence of chronic inflammation is explored during physiological bone remodeling and during a set of four chronic inflammatory associated pathologies: rheumatoid arthritis, spondylarthropathies, periodontitis, and postmenopausal osteoporosis.

© 2014 ACT. All rights reserved.

Key words: Osteoblast/osteoclast balance; Rheumatoid arthritis; Spondylarthropathies; Periodontal diseases; Postmenopausal osteoporosis

Gosset M, Rochefort GY. Inflammation and Bone Remodeling Pathologies. *International Journal of Orthopaedics* 2014; 1(4): 124-129 Available from: URL: <http://www.ghrnet.org/index.php/ijo/article/view/793>

INTRODUCTION

Bone is a dynamic tissue that undergoes continual adaption to reach and preserve skeletal size, shape, and structural integrity and to regulate mineral homeostasis. At first, bone modeling is responsible for bone formation, growth and adaption to mechanical loads. Then, bone remodeling is responsible for removal and repair of damaged bone to maintain integrity of the adult skeleton and mineral homeostasis. This tightly coordinated event requires the synchronized activities of multiple cellular participants carried out by osteoblasts and osteoclasts, which respectively produce bone matrix and resorb it. Endocrine and paracrine control of these cells can be direct, but they are also exerted indirectly, either by influencing progenitor cell differentiation or by stimulating paracrine signals from local accessory cells including osteocytes, macrophages and T lymphocytes. Chronic inflammation is known for long to disrupt the balance of cell activities between osteoblasts and osteoclasts, producing both local and systemic changes in bone quality in chronic inflammatory conditions, including rheumatoid arthritis (RA), spondylarthropathies (ankylosing spondylitis, psoriatic arthritis, and inflammatory bowel disease), periodontal diseases, and even postmenopausal osteoporosis. However, if immune cells and inflammatory cytokines mediate bone catabolism, they also play pro-anabolic functions, indicating rich cross-regulations between the immune and skeletal systems.

PHYSIOLOGICAL AND PATHOLOGICAL BONE REMODELING CELLULAR PARTICIPANTS

The first phase of the bone remodeling process, the activation phase, involves the perception of an initiating remodeling signal that can take several modalities. Direct mechanical strains can be sensed by osteocytes and then transduced into a biological signal that initiates the bone remodeling process. Osteocyte apoptosis during bone matrix damage or immobilization can locally remove the osteoclastogenesis inhibition of TGF- β basally released by osteocytes, thus initiating bone removal. During the resorption phase, release of the endocrine calcitropic hormone (PTH), secreted by the parathyroid glands in

response to reduced serum calcium, acts on osteoblasts to induce the release of the chemokine MCP-1 (monocyte chemoattractant protein-1) that induces the osteoclast recruitment, differentiation and activation, and thus establishes bone resorption. Reversal phase is then characterized by the removal of the collagen remnants by mononuclear reversal cells (either monocytic phagocytes or osteomacs/osteoblastic-lineage related cells), which prepares the bone surface for subsequent osteoblast-mediated bone formation. During the formation phase, coupling molecules and factors (e.g. TGF- β , Insulin-like growth factors I and II), initially stored in the bone matrix and subsequently released during bone resorption, as well as osteoclast-released factors (e.g. sphingosine-1-phosphate, cell-anchored ephrin-B4) may then act as key signal for the recruitment of mesenchymal stem cells to sites of bone resorption. These progenitors then differentiate into osteoblasts that secrete the organic part of the replacing bone matrix, composed of collagen type I and non-collagenous proteins (proteoglycans, glycosylated proteins: alkaline phosphatase, small integrin-binding ligand proteins, matrix Gla protein and osteocalcin; and lipids). Hydroxyapatite is finally incorporated into this newly deposited osteoid matrix. Ultimately, the termination phase is achieved when an equal quantity of resorbed bone has been replaced by newly formed bone and the resting bone surface environment is reestablished. Following mineralization, mature osteoblasts involved in this remodeling process undergo apoptosis, return to a bone-lining phenotype or become embedded in the newly mineralized matrix and differentiate into osteocytes.

Bone remodeling is thus performed over several weeks by clusters of bone-resorbing osteoclasts and bone-forming osteoblasts arranged within temporary anatomical structures known as “basic multicellular units” (BMUs) that form with human bone-lining cells (or rodent osteomac cells) the canopy microenvironment^[1].

Among these cells, osteoclasts are multinuclear, terminally differentiated myeloid cells expressing tartrate-resistant acid phosphatase and the calcitonin receptor and are uniquely adapted to remove mineralized bone matrix^[2]. The survival, expansion and differentiation of osteoclast precursors require CSF-1 (colony-stimulating factor 1 factor) and RANKL (receptor activator of NF- κ B ligand) *in vitro*^[3] as well as *in vivo* since the lack of function of either CSF-1 or RANKL results in osteopetrosis (dense bones) caused by complete absence of osteoclasts^[4-5]. At the opposite, loss of functional OPG (osteoprotegerin, a receptor for RANKL that is a physiological negative regulator of osteoclastogenesis) results in mice with osteoporosis (brittle bones) due to excessive osteoclastogenesis^[6], indicating that the RANKL/OPG expression ratio determines the degree of osteoclast differentiation and function.

Osteoblastic cells represent a population of pluripotent mesenchymal stem-derived, specialized bone-forming cells expressing PTH receptors that comprises several cells, including immature osteoblast cells that act on osteoclastogenesis as well as differentiating and mature matrix-releasing osteoblasts^[7-8].

During bone formation, few osteoblasts undergo terminal differentiation to become embedded into a non-mineralized osteoid matrix. These osteoid-osteocytes are finally called osteocytes when entombed during the mineralization of this organic matrix^[9]. Whereas osteoblasts and osteoclasts have a lifespan of few days or weeks, osteocytes are able to live several decades within the bone matrix and are the most abundant cells in bone, representing 90 to 95% of all cells in the adult skeleton^[10]. These cells emit long dendritic expansions (the dendrites) through fine channels within the bone matrix (the canaliculae), thus forming a large dendritic network bathed into an interstitial fluid (the bone fluid flow) and connecting

these cells with each other and with osteoblasts, lining cells and osteoclasts^[11]. Osteocytes are able to sense and respond to mechanical loads to initiate and direct the bone remodeling process^[12].

Next to these three “classical” bone cell types, other immune cells are also involved in the physiological bone remodeling process. B-cells and activated T-cells have been implicated in the maintenance of bone homeostasis during basal physiology since mice lacking either B- or T-cells have osteoporotic bones^[13]. With half the production of the osteoclastogenesis down-regulator OPG coming from mature B-cells, the role of this immune cell in physiological bone remodeling is obvious. However, the role of the few activated T-cells that can be found in the vicinity of bone is less clear and could pass through an enhancement of B-cell OPG production via a CD40/CD40L co-stimulation. Mice having increased megakaryocyte numbers, the thrombocyte-producing hematopoietic stem cell, exhibit elevated bone volume^[14]. At last, osteomacs represent a population of resident tissue macrophages that are anatomically localized in close proximity to the bone surface. These cells are forming a canopy over mature matrix-producing osteoblasts at sites of bone (re)modeling and are may be required to maintain osteoblasts in a mature state^[1].

INFLAMMATION, PATHOLOGIES AND DISTURBED BONE REMODELING

Multiple anatomical and vascular contacts and overlapping and interacting cellular and molecular mechanisms are involved in the regulation of bone turnover and the immune system. Furthermore, patients with diseases of excessive immune activation such as RA, spondylarthropathies, or periodontal diseases, are at higher risk of experiencing concomitant osteoporosis. There is therefore accumulating evidence that chronic immune activation itself is an independent risk factor for progressive bone loss (Figure 1)^[15].

Rheumatoid arthritis (RA) is a set of chronic inflammatory autoimmune diseases of unknown etiology affecting approximately 1 to 10% of the population depending on the country^[16]. Inflammation of the synovial membrane leads to a pannus and subsequent painful cartilage and bone destruction of joints. In addition, RA is characterized by systemic inflammation and it is recognized that mortality in RA patients is increased^[17] mainly due to increased cardiovascular risk^[18] and probably interstitial lung disease^[19]. RA is also characterized by generalized bone loss and increased fracture risk mediated by the systemic pro-inflammatory state, chronic use of glucocorticoid or biotherapies and a decreased level of physical activity^[20]. RAs are categorized according to presence of anti-cyclic citrullinated peptides antibodies (ACPAs). Sixty percent of RA patients exhibit high quantity of ACPAs, which are highly specific of RA^[21] and may be relevant for the prognosis of RA^[22]. Indeed, ACPAs promote osteoclast precursor cells differentiation into bone-resorbing osteoclasts^[23]. The use of biotherapies, especially monoclonal anti-TNF α antibody, has considerably improved RA treatment, sustaining the role of inflammation in RA pathogenesis. High levels of inflammatory cytokines, including IL-1, IL-6, IL-17 and TNF- α , and increased RANKL/OPG are common features of RA. Interestingly, in RA patients treated with TNF antagonists, low levels of serum RANKL and RANKL/OPG ratio at baseline may serve to predict remission^[24]. IL-1, which highly increases inflammation and bone resorption in RA^[25], is considered as a future target in RA treatment.

The sero-negative spondylarthropathies (SpAs) are a set of pathologies that include ankylosing spondylitis (AS), reactive

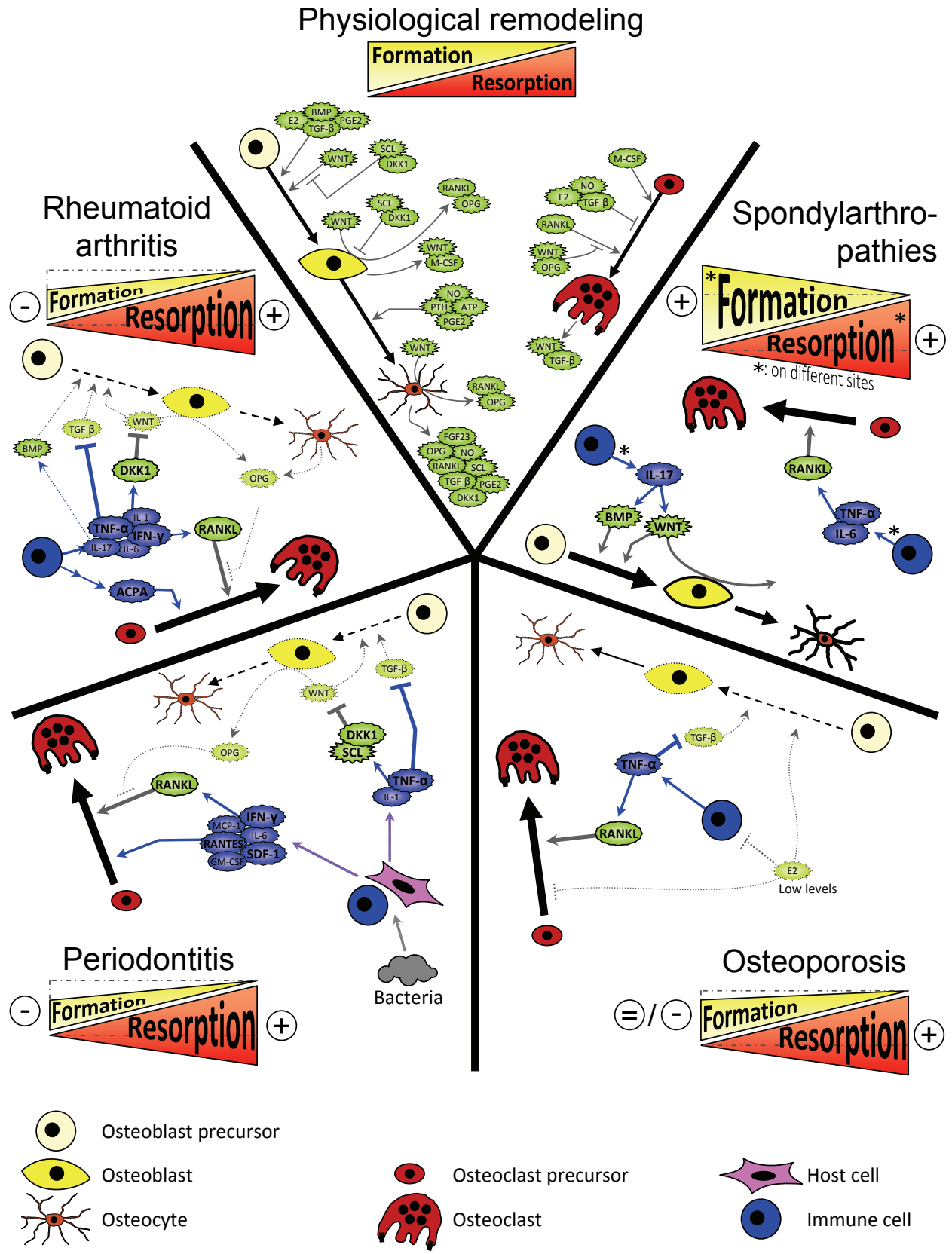


Figure 1 Overview of the main and general endocrine and paracrine pathways sustaining the physiological bone remodeling process and their modulation during chronic inflammatory conditions, including rheumatoid arthritis, spondylarthropathies, periodontal diseases, and postmenopausal osteoporosis. ACPA: Anti-citrullinated protein antibody; ATP: Adenosine triphosphate; BMP: Bone morphogenetic protein; DKK1: Dickkopf-related protein 1; E2: 17-beta-estradiol; FGF23: Fibroblast growth factor 23; GM-CSF: Granulocyte macrophage colony-stimulating factor; IFN- γ : Interferon gamma; IL-1: Interleukin-1; IL-17: Interleukin-17; IL-6: Interleukin-6; MCP-1: Monocyte chemoattractant protein-1; M-CSF: Macrophage colony-stimulating factor; NO: Nitric oxide; OPG: Osteoprotegerin; PGE2: Prostaglandin E2; PTH: Parathyroid hormone; RANKL: Receptor activator of nuclear factor kappa-B ligand; RANTES: Regulated upon activation normal T-cell expressed, and presumably secreted; SCL: Sclerostin; SDF-1: Stromal cell-derived factor 1; TGF- β : Transforming growth factor beta; TNF- α : Tumor necrosis factor alpha; WNT: Fusion of Wingless, the *Drosophila melanogaster* segment-polarity gene, and Integrase-1, the vertebrate homologue.

arthritis, and arthritis associated with psoriasis or inflammatory bowel disease^[26]. SpAs share several common articular and periarticular characteristics that differ from RA and other forms of inflammatory arthritis. Thus, in SpAs, the coupling of bone formation and resorption is de-regulated with loss of bone in enthesal insertion sites (sites of ligamentous and tendon insertion) and excess of bone formation in periosteal sites close to bone erosion sites^[27], which are not common sites of primary pathology in RA and other inflammatory arthropathies. In SpAs, the new added bone is formed by a process of endochondral ossification that recapitulates the cellular bone growth mechanisms occurring during skeletal growth and development in which an initial cartilaginous matrix is replaced by new bone^[28]. These ectopic endochondral ossifications, implying TGF- β and BMPs^[29], occur in SpAs at the margins of vertebral bodies and form syndesmophytes that are radiographically visible in SpA patients^[30-31]. There is also evidence that cytokine production and Wnt/ β -catenin pathways are dis-regulated^[29-30,32]. Inhibition of inflammation using anti-TNF therapy has shown a reduction of the progression of bone erosions at sites of inflammation, but has no impact on the enhanced bone formation observed in SpAs^[33-34]. Further studies are thus needed to explore the mechanisms involved in this apparent dissociation between bone erosion and formation during inflammation in SpAs.

Periodontitis, highly associated with systemic inflammation, represents a set of inflammatory diseases triggered by disequilibrium in the quantity and quality of dental microbiota affecting the periodontium, i.e. the tissue that surrounds and supports the teeth^[35]. It is characterized by gingival inflammation, progressive destruction of periodontal ligament and alveolar bone loss. Clinically, attachment loss leads to periodontal pocket in which active inflammatory process and bacterial invasion take place. Today, it is clearly established that periodontitis increase highly the risk of developing chronic inflammatory diseases such as cardiovascular diseases^[36], metabolic syndrome^[37], diabetes^[38] and rheumatoid arthritis^[39]. The role of periodontal bacteria such as *Porphyromonas gingivalis* in such processes is highly studied^[40-41]. Prevalence of periodontitis concerned almost 47% of the US adult population, distributed as 8.7%, 30.0%, and 8.5% with mild, moderate and severe periodontitis, respectively, according to the severity of the periodontal destruction^[42]. Alveolar bone loss occurring in periodontitis results from uncoupling bone remodeling. Indeed, a significant decrease in bone formation associated with increased bone resorption is observed in experimental periodontitis^[43] and is mainly driven by immune cells and inflammatory cytokines. For example, TH17 lymphocytes and B-lymphocytes are potent producers of RANKL^[44] leading to an increased RANKL/OPG ratio parallel to severity of periodontitis^[45]. Injection of antibodies against RANKL or OPG-Fc into an experimental model of alveolar bone destruction in response to injection of *P. gingivalis* resulted in significantly reduced periodontal bone resorption^[46]. High amounts of pro-resorptive cytokine IL-17 or pro-inflammatory cytokines such as IL-1 have been found in gingival fluid from periodontal pockets from periodontitis patients compared to healthy patients^[47-48]. Periodontium resident cells, including gingival fibroblasts, epithelial cells and vascular endothelium are also sensitive to inflammatory cytokines and bacterial agents and become major participants in the tissue destruction by increasing RANKL and cytokines production. The role of antigen-antibody complex in osteoclast activation during periodontitis is not elucidated even if it is known that OSCAR (Osteoclast-associated immunoglobulin-like receptor), an adaptation protein linked to constant fraction of immunoglobulin, is expressed by osteoclasts^[49]. Recently, increased

levels of SOST and DKK1 in the gingival tissue and in the serum of patients with chronic periodontitis has been described when compared with non-periodontitis group, highlighting the altered activity of osteoblasts in periodontitis^[50]. Today, biotherapies such as anti-DKK1 or anti-SOST, which boost osteoblast anabolic activity in osteo-inflammatory disorders, are under processed in preclinical studies^[51].

Osteoporosis are systemic skeletal disorders that are very frequent in aged populations and affect over 50% of women aged over 50 and 20% of men, with the incidence rising as people become older^[52]. Osteoporosis are characterized by low bone mass and micro-architectural deteriorations of bone tissue with compromised bone strength and increased susceptibility to typical fractures (lumbar spine, femoral neck or distal radius, vertebral fractures and any fracture resulting from a low trauma in elderly) associated with an increase in morbidity and mortality^[53-55]. According to the World Health Organization clinically definition, a patient is osteoporotic when his bone mineral density measured by DXA is 2.5 standard deviations below the typical peak bone mass of a young healthy person at the spine and hip^[56]. Osteoporosis can be separated into 3 types: (1) primary osteoporosis in which no underlying cause can be clearly identified but often follows menopause in women and occurs later in life in men; (2) secondary osteoporosis in which the underlying cause is known (e.g. hyperparathyroidism, hypophosphatasia, diabetes type I & II, alcoholism, glucocorticosteroid use...); and (3) more rare forms of the disease, such as juvenile, pregnancy-related, and postpartum osteoporosis^[57-59]. In mouse models, injections of estrogen induces an osteoclast apoptosis, inhibits the osteoclastogenesis, as well as modulates the production of several bone-resorbing cytokines, including interleukin (IL)-1, IL-6, tumor necrosis factor- α (TNF- α), M-CSF, and prostaglandins^[60-62], thus indicating direct and indirect effects of estrogen on osteoclast development through immune cells^[63-64]. It has also been shown that women with postmenopausal osteoporosis have an elevated T-cell activity with increased secretion of TNF- α and RANKL compared to healthy postmenopausal women^[65], associated with significantly higher concentrations of circulating sclerostin^[66]. Consequently, women with postmenopausal osteoporosis exhibit a higher percentage of circulating osteoclast precursors than control women^[67]. At last, it has been recently reported that IL-17 is able to promote bone loss by stimulating osteoclast formation and inhibiting osteoblast differentiation^[68], indicating once again the role of the immune system in the regulation of bone turnover.

CONCLUSION

Chronic inflammation is thus able to disrupt the balance between bone formation and resorption in several chronic inflammatory associated pathologies, such as RA, SpAs, periodontal diseases, or postmenopausal osteoporosis. Therefore, studying the cross-regulations between the immune and skeletal systems may open several opportunities to discover new molecular targets to treat these diseases.

ACKNOWLEDGMENTS

Studies performed in the authors' laboratory have been supported by University Paris Descartes, the "Fondation pour la Recherche Médicale", the "Fondation des Gueules Cassées", the "Institut Français pour la Recherche Odontologique" and the "Société Française de Rhumatologie

CONFLICT OF INTERESTS

There are no conflicts of interest with regard to the present study.

REFERENCES

- Chang MK, Raggatt LJ, Alexander KA, Kuliwaba JS, Fazzalari NL, Schroder K, Maylin ER, Ripoll VM, Hume DA, Pettit AR. Osteal tissue macrophages are intercalated throughout human and mouse bone lining tissues and regulate osteoblast function *in vitro* and *in vivo*. *J Immunol* 2008; **181**: 1232-1244
- Teitelbaum SL, Ross FP. Genetic regulation of osteoclast development and function. *Nat Rev Genet* 2003; **4**: 638-649
- Lacey DL, Timms E, Tan HL, Kelley MJ, Dunstan CR, Burgess T, Elliott R, Colombero A, Elliott G, Scully S, Hsu H, Sullivan J, Hawkins N, Davy E, Capparelli C, Eli A, Qian YX, Kaufman S, Sarosi I, Shalhoub V, Senaldi G, Guo J, Delaney J, Boyle WJ. Osteoprotegerin ligand is a cytokine that regulates osteoclast differentiation and activation. *Cell* 1998; **93**: 165-176
- Yoshida H, Hayashi S, Kunisada T, Ogawa M, Nishikawa S, Okamura H, Sudo T, Shultz LD. The murine mutation osteopetrosis is in the coding region of the macrophage colony stimulating factor gene. *Nature* 1990; **345**: 442-444
- Kong YY, Yoshida H, Sarosi I, Tan HL, Timms E, Capparelli C, Morony S, Oliveira-dos-Santos AJ, Van G, Itie A, Khoo W, Wakeham A, Dunstan CR, Lacey DL, Mak TW, Boyle WJ, Penninger JM. OPGL is a key regulator of osteoclastogenesis, lymphocyte development and lymph-node organogenesis. *Nature* 1999; **397**: 315-323
- Simonet WS, Lacey DL, Dunstan CR, Kelley M, Chang MS, Luthy R, Nguyen HQ, Wooden S, Bennett L, Boone T, Shimamoto G, DeRose M, Elliott R, Colombero A, Tan HL, Trail G, Sullivan J, Davy E, Bucay N, Renshaw-Gegg L, Hughes TM, Hill D, Pattison W, Campbell P, Sander S, Van G, Tarpley J, Derby P, Lee R, Boyle WJ. Osteoprotegerin: a novel secreted protein involved in the regulation of bone density. *Cell* 1997; **89**: 309-319
- O'Brien CA, Plotkin LI, Galli C, Goellner JJ, Gortazar AR, Allen MR, Robling AG, Boussein M, Schipani E, Turner CH, Jilka RL, Weinstein RS, Manolagas SC, Bellido T. Control of bone mass and remodeling by PTH receptor signaling in osteocytes. *PLoS One* 2008; **3**: e2942
- Bellido T, Saini V, Pajevic PD. Effects of PTH on osteocyte function. *Bone* 2013; **54**: 250-257
- Klein-Nulend J, Nijweide PJ, Burger EH. Osteocyte and bone structure. *Curr Osteoporos Rep* 2003; **1**: 5-10
- Bonewald LF. The amazing osteocyte. *J Bone Miner Res* 2011; **26**: 229-238
- Rocheffort GY, Pallu S, Benhamou CL. Osteocyte: the unrecognized side of bone tissue. *Osteoporos Int* 2010; **21**: 1457-1469
- Rocheffort GY, Benhamou CL. Osteocytes are not only mechanoreceptive cells. *Int J numer method biomed eng* 2013; **29(10)**: 1082-1088
- Li Y, Toraldo G, Li A, Yang X, Zhang H, Qian WP, Weitzmann MN. B cells and T cells are critical for the preservation of bone homeostasis and attainment of peak bone mass *in vivo*. *Blood* 2007; **109**: 3839-3848
- Kacena MA, Shivdasani RA, Wilson K, Xi Y, Troiano N, Nazarian A, Gundberg CM, Boussein ML, Lorenzo JA, Horowitz MC. Megakaryocyte-osteoblast interaction revealed in mice deficient in transcription factors GATA-1 and NF-E2. *J Bone Miner Res* 2004; **19**: 652-660
- Hardy R, Cooper MS. Bone loss in inflammatory disorders. *J Endocrinol* 2009; **201**: 309-320
- Alamanos Y, Voulgari PV, Drosos AA. Incidence and prevalence of rheumatoid arthritis, based on the 1987 American College of Rheumatology criteria: a systematic review. *Semin Arthritis Rheum* 2006; **36**: 182-188
- Dadoun S, Zeboulon-Ktorza N, Combesure C, Elhai M, Rozenberg S, Gossec L, Fautrel B. Mortality in rheumatoid arthritis over the last fifty years: systematic review and meta-analysis. *Joint Bone Spine* 2013; **80**: 29-33
- Puttevils D, De Vusser P, Geusens P, Dens J. Increased cardiovascular risk in patients with rheumatoid arthritis: an overview. *Acta Cardiol* 2014; **69**: 111-118
- O'Dwyer DN, Armstrong ME, Cooke G, Dodd JD, Veale DJ, Donnelly SC. Rheumatoid Arthritis (RA) associated interstitial lung disease (ILD). *Eur J Intern Med* 2013; **24**: 597-60
- Clayton ES, Hochberg MC. Osteoporosis and osteoarthritis, rheumatoid arthritis and spondylarthropathies. *Curr Osteoporos Rep* 2013; **11**: 257-262
- Nishimura K, Sugiyama D, Kogata Y, Tsuji G, Nakazawa T, Kawano S, Saigo K, Morinobu A, Koshiba M, Kuntz KM, Kamae I, Kumagai S. Meta-analysis: diagnostic accuracy of anti-cyclic citrullinated peptide antibody and rheumatoid factor for rheumatoid arthritis. *Ann Intern Med* 2007; **146**: 797-808
- Szodoray P, Szabo Z, Kapitany A, Gyetvai A, Lakos G, Szanto S, Szucs G, Szekanecz Z. Anti-citrullinated protein/peptide autoantibodies in association with genetic and environmental factors as indicators of disease outcome in rheumatoid arthritis. *Autoimmun Rev* 2010; **9**: 140-143
- Kocijan R, Harre U, Schett G. ACPA and bone loss in rheumatoid arthritis. *Curr Rheumatol Rep* 2013; **15**: 366
- Gonzalez-Alvaro I, Ortiz AM, Tomero EG, Balsa A, Orte J, Lafon A, Garcia-Vicuna R. Baseline serum RANKL levels may serve to predict remission in rheumatoid arthritis patients treated with TNF antagonists. *Ann Rheum Dis* 2007; **66**: 1675-1678
- Kotake S, Udagawa N, Takahashi N, Matsuzaki K, Itoh K, Ishiyama S, Saito S, Inoue K, Kamatani N, Gillespie MT, Martin TJ, Suda T. IL-17 in synovial fluids from patients with rheumatoid arthritis is a potent stimulator of osteoclastogenesis. *J Clin Invest* 1999; **103**: 1345-1352
- Wei JC. Treat-to-Target in Spondyloarthritis: Implications for Clinical Trial Designs. *Drugs* 2014; **74**: 1091-1096
- Barnabe C, Hanley DA. Effect of tumor necrosis factor alpha inhibition on bone density and turnover markers in patients with rheumatoid arthritis and spondyloarthropathy. *Semin Arthritis Rheum* 2009; **39**: 116-122
- Lories RJ, Derese I, de Bari C, Luyten FP. Evidence for uncoupling of inflammation and joint remodeling in a mouse model of spondylarthritis. *Arthritis Rheum* 2007; **56**: 489-497
- Chou CT. How to translate basic knowledge into clinical application of biologic therapy in spondyloarthritis. *Clin Dev Immunol* 2013; **2013**: 369202
- Wending D, Claudepierre P. New bone formation in axial spondyloarthritis. *Joint Bone Spine* 2013; **80**: 454-458
- Braun J, Baraliakos X. Imaging of axial spondyloarthritis including ankylosing spondylitis. *Ann Rheum Dis* 2011; **70 Suppl 1**: i97-103
- Schett G. Structural bone changes in spondyloarthritis: mechanisms, clinical impact and therapeutic considerations. *Am J Med Sci* 2011; **341**: 269-271
- Voulgari PV. Golimumab: a new anti-TNF-alpha agent for rheumatoid arthritis, psoriatic arthritis and ankylosing spondylitis. *Expert Rev Clin Immunol* 2010; **6**: 721-733
- Milia AF, Ibba-Manneschi L, Manetti M, Benelli G, Generini S, Messerini L, Matucci-Cerinic M. Evidence for the prevention of enthesitis in HLA-B27/hbeta(2)m transgenic rats treated with a monoclonal antibody against TNF-alpha. *J Cell Mol Med* 2011; **15**: 270-279
- Paraskevas S, Huizinga JD, Loos BG. A systematic review and meta-analyses on C-reactive protein in relation to periodontitis. *J*

- Clin Periodontol* 2008; **35**: 277-290
- 36 Genco RJ, Van Dyke TE. Prevention: Reducing the risk of CVD in patients with periodontitis. *Nat Rev Cardiol* 2010; **7**: 479-480
- 37 Nibali L, Tatarakis N, Needleman I, Tu YK, D'Aiuto F, Rizzo M, Donos N. Clinical review: Association between metabolic syndrome and periodontitis: a systematic review and meta-analysis. *J Clin Endocrinol Metab* 2013; **98**: 913-920
- 38 Lalla E, Papanou PN. Diabetes mellitus and periodontitis: a tale of two common interrelated diseases. *Nat Rev Endocrinol* 2011; **7**: 738-748
- 39 Detert J, Pischon N, Burmester GR, Buttgerit F. The association between rheumatoid arthritis and periodontal disease. *Arthritis Res Ther* 2010; **12**: 218
- 40 Farquharson D, Butcher JP, Culshaw S. Periodontitis, Porphyromonas, and the pathogenesis of rheumatoid arthritis. *Mucosal Immunol* 2012; **5**: 112-120
- 41 Hayashi C, Gudino CV, Gibson FC, 3rd, Genco CA. Review: Pathogen-induced inflammation at sites distant from oral infection: bacterial persistence and induction of cell-specific innate immune inflammatory pathways. *Mol Oral Microbiol* 2010; **25**: 305-316
- 42 Eke PI, Dye BA, Wei L, Thornton-Evans GO, Genco RJ. Prevalence of periodontitis in adults in the United States: 2009 and 2010. *J Dent Res* 2012; **91**: 914-920
- 43 Baron R, Saffar JL. A quantitative study of bone remodeling during experimental periodontal disease in the golden hamster. *J Periodontol* 1978; **13**: 309-315
- 44 Kawai T, Matsuyama T, Hosokawa Y, Makihira S, Seki M, Karimbox NY, Goncalves RB, Valverde P, Dibart S, Li YP, Miranda LA, Ernst CW, Izumi Y, Taubman MA. B and T lymphocytes are the primary sources of RANKL in the bone resorptive lesion of periodontal disease. *Am J Pathol* 2006; **169**: 987-998
- 45 Mogi M, Ootogoto J, Ota N, Togari A. Differential expression of RANKL and osteoprotegerin in gingival crevicular fluid of patients with periodontitis. *J Dent Res* 2004; **83**: 166-169
- 46 Han X, Lin X, Yu X, Lin J, Kawai T, LaRosa KB, Taubman MA. *Porphyromonas gingivalis* infection-associated periodontal bone resorption is dependent on receptor activator of NF-kappaB ligand. *Infect Immun* 2013; **81**: 1502-1509
- 47 Vernal R, Dutzan N, Chaparro A, Puente J, Antonieta Valenzuela M, Gamonal J. Levels of interleukin-17 in gingival crevicular fluid and in supernatants of cellular cultures of gingival tissue from patients with chronic periodontitis. *J Clin Periodontol* 2005; **32**: 383-389
- 48 Barksby HE, Lea SR, Preshaw PM, Taylor JJ. The expanding family of interleukin-1 cytokines and their role in destructive inflammatory disorders. *Clin Exp Immunol* 2007; **149**: 217-225
- 49 Kajjya M, Giro G, Taubman MA, Han X, Mayer MP, Kawai T. Role of periodontal pathogenic bacteria in RANKL-mediated bone destruction in periodontal disease. *J Oral Microbiol* 2010; **2**: 1-10
- 50 Napimoga MH, Nametala C, da Silva FL, Miranda TS, Bossonaro JP, Demasi AP, Duarte PM. Involvement of the Wnt-beta-catenin signalling antagonists, sclerostin and dickkopf-related protein 1, in chronic periodontitis. *J Clin Periodontol* 2014; **41**: 550-557
- 51 Rauner M, Sipos W, Thiele S, Pietschmann P. Advances in osteoimmunology: pathophysiologic concepts and treatment opportunities. *Int Arch Allergy Immunol* 2013; **160**: 114-125
- 52 Mosley JR. Osteoporosis and bone functional adaptation: mechanobiological regulation of bone architecture in growing and adult bone, a review. *J Rehabil Res Dev* 2000; **37**: 189-199
- 53 Lindsay R. The menopause and osteoporosis. *Obstet Gynecol* 1996; **87**: 16S-19S
- 54 Garnero P. Biomarkers for osteoporosis management: utility in diagnosis, fracture risk prediction and therapy monitoring. *Mol Diagn Ther* 2008; **12**: 157-170
- 55 Hopkins RB, Tarride JE, Leslie WD, Metge C, Lix LM, Morin S, Finlayson G, Azimae M, Pullenayegum E, Goeree R, Adachi JD, Papaioannou A, Thabane L. Estimating the excess costs for patients with incident fractures, prevalent fractures, and nonfracture osteoporosis. *Osteoporos Int* 2013; **24**: 581-593
- 56 Blake GM, Fogelman I. Role of dual-energy X-ray absorptiometry in the diagnosis and treatment of osteoporosis. *J Clin Densitom* 2007; **10**: 102-110
- 57 Cook FJ, Mumm S, Whyte MP, Wenkert D. Pregnancy-associated osteoporosis with a heterozygous deactivating LDL receptor-related protein 5 (LRP5) mutation and a homozygous methylenetetrahydrofolate reductase (MTHFR) polymorphism. *J Bone Miner Res* 2013; **29**(4): 922-928
- 58 Schnatz PF, Marakovits KA, O'Sullivan DM. Assessment of postmenopausal women and significant risk factors for osteoporosis. *Obstet Gynecol Surv* 2010; **65**: 591-596
- 59 Taxel P, Kenny A. Differential diagnosis and secondary causes of osteoporosis. *Clin Cornerstone* 2000; **2**: 11-21
- 60 Manolagas SC, Jilka RL. Bone marrow, cytokines, and bone remodeling. Emerging insights into the pathophysiology of osteoporosis. *N Engl J Med* 1995; **332**: 305-311
- 61 Ammann P, Rizzoli R, Bonjour JP, Bourrin S, Meyer JM, Vassalli P, Garcia I. Transgenic mice expressing soluble tumor necrosis factor-receptor are protected against bone loss caused by estrogen deficiency. *J Clin Invest* 1997; **99**: 1699-1703
- 62 Kimble RB, Srivastava S, Ross FP, Matayoshi A, Pacifici R. Estrogen deficiency increases the ability of stromal cells to support murine osteoclastogenesis via an interleukin-1 and tumor necrosis factor-mediated stimulation of macrophage colony-stimulating factor production. *J Biol Chem* 1996; **271**: 28890-28897
- 63 Kosa JP, Balla B, Kiss J, Podani J, Takacs I, Lazary A, Nagy Z, Bacsi K, Karsai A, Speer G, Lakatos P. Postmenopausal expression changes of immune system-related genes in human bone tissue. *J Clin Immunol* 2009; **29**: 761-768
- 64 Breuil V, Ticchioni M, Testa J, Roux CH, Ferrari P, Breittmayer JP, Albert-Sabonnadiere C, Durant J, De Perreti F, Bernard A, Euller-Ziegler L, Carle GF. Immune changes in post-menopausal osteoporosis: the Immunos study. *Osteoporos Int* 2010; **21**: 805-814
- 65 D'Amelio P, Grimaldi A, Di Bella S, Brianza SZ, Cristoforo MA, Tamone C, Giribaldi G, Ulliers D, Pescarmona GP, Isaia G. Estrogen deficiency increases osteoclastogenesis up-regulating T cells activity: a key mechanism in osteoporosis. *Bone* 2008; **43**: 92-100
- 66 Mirza FS, Padhi ID, Raisz LG, Lorenzo JA. Serum sclerostin levels negatively correlate with parathyroid hormone levels and free estrogen index in postmenopausal women. *J Clin Endocrinol Metab* 2010; **95**: 1991-1997
- 67 Kim BJ, Bae SJ, Lee SY, Lee YS, Baek JE, Park SY, Lee SH, Koh JM, Kim GS. TNF-alpha mediates the stimulation of sclerostin expression in an estrogen-deficient condition. *Biochem Biophys Res Commun* 2012; **424**: 170-175
- 68 Tyagi AM, Srivastava K, Mansoori MN, Trivedi R, Chattopadhyay N, Singh D. Estrogen deficiency induces the differentiation of IL-17 secreting Th17 cells: a new candidate in the pathogenesis of osteoporosis. *PLoS One* 2012; **7**: e44552

Peer reviewer: Nobuyuki Udagawa, Department of Biochemistry, Matsumoto Dental University, 1780 Hirooka Gobara, Shiojiri, agano, 399-0781, Japan.