

Radiographic Assessment of Lower Limb Lengthening in Achondroplastic Patients, Using the Ilizarov Frame: A 5-19 Year Follow up Study

Maria A Stefanou, MD, MS, Dimitrios Pasparakis, MD, PhD, Dimitrios Mastrokalos, MD, PhD, Chrisa Tzoumaka-Bakoula, MD, PhD, Nikolaos Papandreou, MD, PhD, Panayiotis J Papagelopoulos, MD, PhD

Maria A Stefanou, Dimitrios Pasparakis, Chrisa Tzoumaka-Bakoula, Nikolaos Papandreou, 2nd Orthopaedic Department 'Panayiotis & Aglaia Kyriakou' Children's Hospital, Athens, Greece
Dimitrios Mastrokalos, Panayiotis J Papagelopoulos, 1st Orthopaedic Department, University General Hospital 'Attikon', Athens, Greece

Correspondence to: Maria A. Stefanou, MD, MS, 2nd Orthopaedic Department 'Panayiotis & Aglaia Kyriakou' Children's Hospital, 9, Gelonos st, 11521, Athens, Greece

Email: maria_stefanou@hotmail.com

Telephone: +30-6937-888-030

Received: September 30, 2014 Revised: October 25, 2014

Accepted: October 30, 2014

Published online: December 23, 2014

ABSTRACT

AIM: The effectiveness of the Ilizarov ring fixator in correcting achondroplasia's lower limb deformities is known. However, whether the long term postoperative result is comparable to normal population standards, has not been analyzed.

MATERIALS AND METHODS: Nineteen (19) achondroplastic patients, 12 males and 7 females, aged 19-38 years, who at the age of 9-19 years, had undergone both tibia and femur lengthening, using the Ilizarov method, were included in the study. Patients were evaluated 5-19 years after their last surgery, using standardized long lower limb anteroposterior and lateral standing radiographs. Tibial and femoral lengthening gain was measured. A comparison between the achondroplastic patients at follow up and comparative radiographic parameters of the normal population was made, concerning— at the frontal plane- LPFA (lateral proximal femoral angle), LDFA (lateral distal femoral angle), MPTA (medial proximal tibial angle), LDTA (lateral distal tibial angle) and MAD (mechanical axis deviation) and – at the sagittal plane- PDFA (posterior distal femoral angle), PPTA (posterior proximal tibial angle) and ADTA (anterior distal tibial angle).

RESULTS: Mean angle values at follow up were: LPFA 118, LDFA 95.5, MPTA 87.8, LDTA 93, PDFA 85.1, PPTA 84, ADTA 88.3 while MAD mean value was 28. LPFA, LDFA, LDTA, PPTA, ADTA and MAD values were statistically significantly different ($p<0.001$) between achondroplastic patients and normal population.

CONCLUSIONS: The use of the Ilizarov method for lower limb deformity correction, in achondroplastic patients, provides a functional length gain. It substantially corrects the three-dimensional deformities of the disease but, it does not restore the radiological image within normal standards. Level of Evidence Level II, Retrospective Prognostic study.

© 2014 ACT. All rights reserved.

Key words: Achondroplasia; Lower limb lengthening; Deformity; Ilizarov

Stefanou MA, Pasparakis D, Mastrokalos D, Tzoumaka-Bakoula C, Papandreou N, Papagelopoulos PJ. Radiographic Assessment of Lower Limb Lengthening in Achondroplastic Patients, Using the Ilizarov Frame: A 5-19 Year Follow up Study. *International Journal of Orthopaedics* 2014; 1(4): 140-145 Available from: URL: <http://www.ghrnet.org/index.php/ijo/article/view/975>

INTRODUCTION

Achondroplasia, the most common form of dwarfism, is characterized by defective endochondral ossification, due to defect in the gene located at the end of the short arm of chromosome 4- that encodes for fibroblast growth factor receptor-3^[1]. The disease's prevalence in the US is 0.36-0.6/10.000 live births^[2] and no satisfactory pharmaceutical causal form of treatment has been found.

The patients are characterized by rhizomelic short-limbed stature, lumbar lordosis, forehead prominence and a low nasal bridge^[3]. Achondroplastic patients have a normal life expectancy^[4].

Daily activities such as climbing stairs, conducting business at counters, using the toilet or public transportation and driving become affected^[5] restricting quality of life and leading to an inferiority complex^[6], since buildings, furniture, vehicles and many everyday objects are standardized in size and adapted to physiological growth^[7].

Lower limbs are disproportionately short and present a complex 3-D deformity, consisting of tibial varus, tibial intorsion and genu recurvatum^[8-15]. Although the exact incidence of clinically significant bowlegs, in achondroplasia is unknown, it is accepted that it is developmental, common, and often progressive^[16].

The effectiveness of the Ilizarov ring fixator in correcting deformity is known^[17-19]. The ability to simultaneously address short stature and the angular and torsional deformity of achondroplasia makes the Ilizarov ring fixator a preferred option for the management of complex lower limb deformities in achondroplasia and many studies confirm the efficacy of this technique in this patient group^[16,20-22]. However, long term follow up after this technique in achondroplastic patients is lacking.

Most studies have focused on magnitude of lengthening, treatment time required, type of fixator, and complications. Some studies evaluate postoperative deformity correction but no study analyzes whether the long term postoperative result is comparable to normal population values.

We analyze the long term radiological image of 19 achondroplastic patients (38 femurs, 38 tibias) who have undergone both femur and tibia lengthening and compare it to normal population radiographic parameters, hoping to provide guidelines for the application of the method to this patient group.

MATERIALS AND METHODS

Sample

Nineteen (19) achondroplastic patients, 12 males and 7 females, diagnosed based on distinctive clinical and radiological features^[23], who had undergone lower limb lengthening with gradual deformity correction by application of the Ilizarov ring fixator in both tibias and femurs, were included in the study (Figure 1). The mean age of the sample at follow-up was 27.3 years and the mean follow up time was 10.1 years after the last surgery (Table 1).

Table 1 Patients' characteristics.

	Mean \pm SD	Range
Age at 1st system application (19/19)	12.6 \pm 2.8	9-19
Age at 2nd system application (3/19)	19.3 \pm 4.2	16-24
Age at follow-up	27.3 \pm 4.9	19-38
Follow-up (years)	10.1 \pm 3.8	5-19

We excluded any patient presenting neurological symptoms and signs or who has sustained a fracture throughout the process.

All patients signed an informed consent form at follow up and the study protocol was approved by the ethics committees of both hospitals involved in the study.

Surgery description

All operations were performed by the same team (DP & NP).

In seventeen (17) patients the system was first applied to the tibias (Figure 2) followed by application to the femurs (transverse parallel way) with an interval of 2-3 years between the tibial and femoral surgeries. In two (2) patients the system was applied in a cross- leg way (femur to opposite tibia) followed by the other side.

A preconstructed 4- ring Ilizarov frame was first applied to the

tibias. The pins were fixed perpendicular to the tibias anatomical axis. All tibial rings were fixed with two wires each. One wire each, in the tibial proximal and distal rings transfixed the proximal and distal tibiofibular joints, respectively. A preconstructed 3-ring Ilizarov frame was applied to the femurs with the pins perpendicular to its mechanical axis. The distal femoral rings were fixed with 2 wires, while the proximal with 3 half pin.

Corrective osteotomies were performed at the metaphyseal regions (distal femur, below the tibial tubercle and distal fibula) with care to preserve the periosteal sleeve^[17].

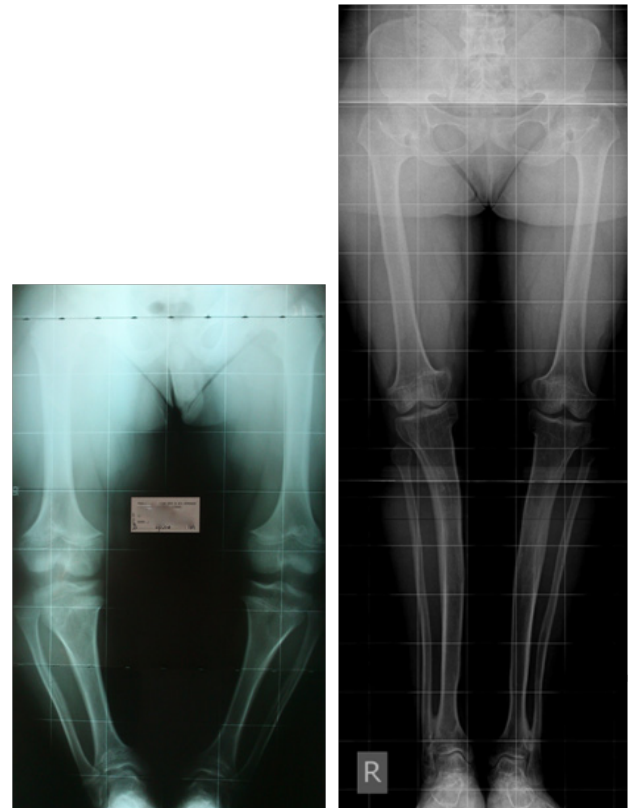


Figure 1 a. Pre- operation and b. post-operation X-rays of achondroplastic patient undergone lower limb lengthening with the Ilizarov frame.




Figure 2 Ilizarov frame on the tibias of an achondroplastic patient.

The elongation took place at a 1 mm/day pace after the seventh (7) post-surgical day. The first 7 days no elongation takes place because it is mandatory to allow for new vessels and primary callous to form.

Achilles tendon elongation was performed in all patients when exceeding 8 cm of tibial length gain, because of soft tissue contracture and muscular hypertension.

Aftercare

Physical therapy program was followed to prevent joint contracture and maintain range of motion.

In tibial elongation partial weight bearing was allowed both at elongation period and during callous formation. In femur elongation weight bearing was allowed, only after the final length had been achieved, thus, during callous formation. After satisfactory corticalization was seen at 3 cortices^[24] in two views (anteroposterior and lateral), the fixator was removed and a long leg cast was applied for 4 to 6 weeks.

Radiological assessment

Standardized, standing, lower limb anteroposterior and lateral radiographs were used. In order to obtain true anteroposterior view the patella was facing forward, irrespective of the foot position and for a clear lateral view, the pelvis was rotated posteriorly in a 30° - 45° angle, with a fully extended and neutrally rotated knee on the study side^[25]. The radiography tube was at a 305 cm distance from the film since the magnification at this distance is 4-5% and the beam was centered on the knee^[25]. In cases of leg length discrepancy a block, adjusted to the approximate discrepancy, was used under the shorter limb^[25]. Standing anteroposterior and lateral lower extremity radiographs provide accurate alignment evaluation while weight bearing^[26].

At the frontal plane- LPFA (lateral proximal femoral angle), LDFA (lateral distal femoral angle), MPTA (medial proximal tibial angle), LDTA (lateral distal tibial angle) and MAD (mechanical axis deviation) and – at the sagittal plane- PDFA (posterior distal femoral angle), PPTA (posterior proximal tibial angle) and ADTA (anterior distal tibial angle) were measured (Figure 3). In addition, tibial and femoral lengthening gain as an absolute value, as well as a percentage of initial length, was documented.

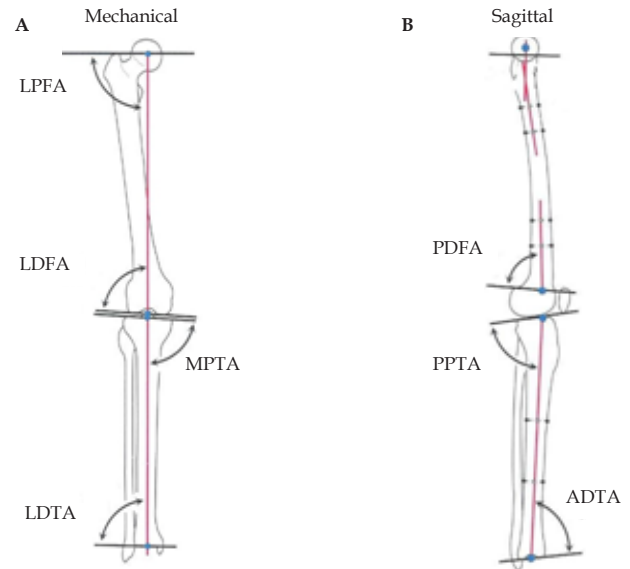


Figure 3 Joint orientation angles with Paley nomenclature for deformity assessment. A: Frontal plane joint orientation angles to the mechanical axis of the femur : LPFA (lateral proximal femoral angle), LDFA (lateral distal femoral angle). Frontal plane joint orientation angles to the anatomic axis of the tibia: MPTA (medial proximal tibial angle), LDTA (lateral distal tibial angle). B: Sagittal plane orientation angles to the anatomic axis of the femur: PDFA (posterior distal femoral angle). Sagittal plane orientation angles to the anatomic axis of the tibia: PPTA (posterior proximal tibial angle) and ADTA (anterior distal tibial angle).

Software

For an accurate measurement of the above described angles, axis and lengths the TraumacadTM 2.4 (Brainlab, Voyant Health Inc.) software was used (Figure 4). Digital measurements with the Traumacad system are reliable in terms of intra- and interobserver variability, making it a useful method for the analysis of pathology on radiographs in pediatric orthopaedics^[27]. The measurements were made by two experienced users (MS & DP).

Comparison was made between the values of achondroplastic patients and normal values which have been well established in literature^[26,28-35] (Table 2).

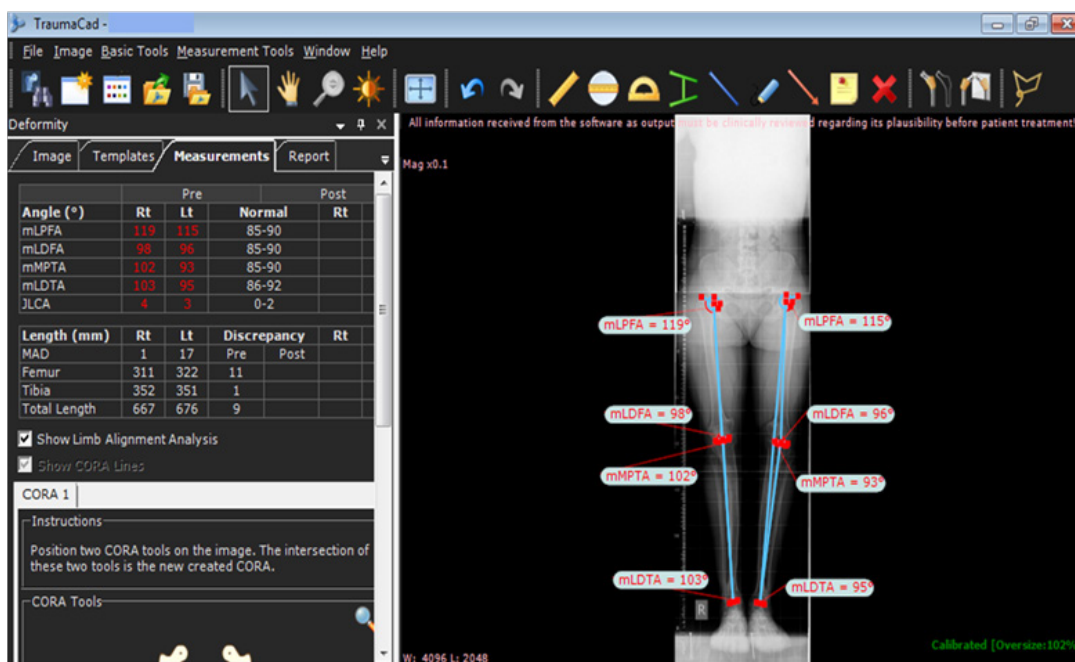


Figure 4 Traumacad software report of joint orientation angles.

Table 2 Comparison of Radiological Angles between Patients at Follow- up and Normal Population Standards.

Coronal plane	Achondroplastic patients				Normal subjects					p value
	patients at follow-up	Chao '94 young ♂	Chao '94 young ♀	Paley '90, '94	Cooke '87, '94	Moreland '87	Chiu '00	Matsuda '99	Meister '98	
LPFA (°)	118 ± 8.2	89.2 ± 5	91.5 ± 4.6	89.9 ± 5.2						<0.001
LDFA (°)	95.5 ± 7.1	88.1 ± 3.2	88.1 ± 3.2	87.8 ± 1.6	86 ± 2.1					<0.001
MPTA (°)	87.8 ± 5.7	85.5 ± 2.9	87.2 ± 2.1	87.2 ± 1.5	86.7 ± 2.3	87.2 ± 1.5				>0.05
LDTA (°)	93 ± 7.4	87.1 ± 3.3	87.1 ± 3.3	88.6 ± 3.8		89.8 ± 2.7				<0.01
MAD (mm)	28 ± 13			9.7 ± 6.8						<0.001
Sagittal plane										
PDFA (°)	85.1 ± 6.8			83.1 ± 3.6						>0.05
PPTA (°)	84 ± 7			80 ± 3.5			78.5	79.3 ± 5	79.7 ± 1.8	<0.001
ADTA (°)	88.3 ± 6			79.8 ± 1.6						<0.001

Statistical analysis

The SPSS 16.0 software was used for statistical analysis. Statistical comparison of deformity parameters between achondroplastic patients and normal population was done using the student *t*-test. A level of $p < 0.05$ was considered statistically significant.

RESULTS

Tibial length gain was 14.1 cm with an 80.64% length increase and femoral length gain was 9.8 cm with a 40.3% length increase. Mean total length gain was 24.91 cm (Table 3). Mean final height, at follow up, for all sample was 148.9 cm, for men 151.8 cm and for women 143.9 cm.

Table 3 Absolute Values and Percentages of Tibial and Femoral Lengthening.

	Mean ± SD	Range
Tibial lengthening (cm)	14.1 ± 1.1	11.5 - 16
Percentage tibial lengthening (%)	80.64 ± 10.5	63.7 - 97.5
Second (2nd) tibial lengthening (cm)	6.82 ± 1	5.8 - 7.9
Percentage 2nd tibial lengthening (%)	24.78 ± 4.1	19.4 - 27.6
Femoral lengthening (cm)	9.8 ± 2	6.4 - 13.3
Percentage femoral lengthening (%)	40.3 ± 11.2	24.1 - 60.7
Total lengthening (tibias once) (cm)	23.32 ± 1.34	21 - 26.4
Total lengthening (tibias twice) (cm)	29.67 ± 2.61	27.1 - 34.5
Total lengthening (all patients) (cm)	24.91 ± 3.3	21 - 34.5

Mean angle values at follow up were: LPFA 118° (103-136), LDFA 95.5° (69-109), MPTA 87.8° (80-102), LDTA 93° (81-108), PDFA 85.1° (72-104), PPTA 84° (61-100), ADTA 88.3° (77-99) while MAD mean value was 28 mm (1-54).

LPFA, LDFA, LDTA, PPTA, ADTA and MAD were statistically significantly different ($p < 0.001$) between achondroplastic patients and normal population (Table 2).

DISCUSSION

Lower limb deformity correction and lengthening in achondroplasia offer the advantages of prevention of early degenerative changes of the knee joint and improvement of lower limb function^[39]. Although unilateral fixator can be used for this purpose, accurate realignment of the mechanical axis and correction of rotational deformity is difficult. Hence, the Ilizarov ring fixator is preferred by many surgeons^[19,24,36].

Despite the fact that many studies report results on lengthening magnitude, treatment time and complications of lower limb elongation in achondroplastic patients, studies reporting long follow up of sizeable series of these patients are lacking^[16]. Radiological long term follow up with an accurate method is even rarer and, to our knowledge, no study has evaluated whether the radiological image at follow up is restored to the normal population values.

Our study combines long term follow up, beyond skeletal maturity, with a sizeable homogenous group operated on both tibias

and femurs, measured with an accurate software^[27] and compares the follow up measurements to normal population values. To our knowledge, our study has the longest mean follow up in this patient group (mean & median 10.1 years, range 5-19 years).

This study has a number of limitations. Firstly, a small sample size, although, given the disease's rarity it is acceptable. Many authors have reported on even smaller achondroplastic sample sizes^[37-40]. Secondly, we've decided to compare, with well established in the literature, normal joint orientation angles values instead of comparing with our own controls. The reason for doing so was firstly, for ethical reasons; we did not wish to submit healthy individuals to the radiation and especially since the series, reported in literature, are sizeable and well documented. To augment the accuracy we compared our results with many published normal series^[26,28-32,34-35].

In our sample, mean tibial length gain was 14.1 cm with an 80.64% length increase and femoral length gain was 9.8 cm with a 40.3% length increase. Factors limiting the amount of lengthening during callus distraction are related to soft tissues rather than bones. With excess lengthening, the gastrocnemius- soleus is unable to keep pace with the lengthening, resulting in equinus contracture. Although there are no objective criteria to determine when to discontinue distraction, the extent of limitation of range-of-ankle movements correlates with the percentage of distraction^[41] and distraction should be stopped when it is thought that joint function may be compromised, no matter how well bone regeneration is proceeding^[4]. Yasui reports a mean femur and tibia length gain of 7.2 and 7.1 cm respectively^[4] while Vaidya reports a mean tibia length gain of 6.84 cm with a 41.3% length increase^[15].

Although it is stated by other authors that beginning of elongation can be at a fairly young age^[21], we chose to start at a mean age of 12.6 years placing the maturity on our side and attempting to gain maximum elongation of each bone on one attempt.

Some studies report on extremely heterogeneous patient groups and due to methodologically weak definition of them, it is not fully clear to what extent the outcome was related to bone lengthening in each of the groups^[5]. We report only on achondroplastic patients who have undergone both tibia and femur elongation.

Pre- and post- operative comparison, reporting correction after surgery, has been performed by many authors, but none has addressed the question as to whether this correction is good enough to restore joint orientation angles to normal subjects' values, hence, provide the achondroplastic patients with a more normal appearance.

One study evaluated achondroplastic patients who have undergone lower limb lengthening up to 5.8 years postoperatively using physical strength tests (quadriceps femoris muscle force, vertical jump, lap time to go up and down 24 stairs)^[4].

Another study tested 24 patients (47 tibias) who have undergone tibial osteotomy only and made comparison preoperatively, at removal of the elongation system, and at last follow up (up to 4 years,

mean 2.4 y) of MPTA, LDTA, MAD, PPTA, ADTA. They reported statistically significant difference of MPTA, LDTA, MAD but not of sagittal plane angles post-operatively and at last follow up. For the 14 femurs they operated on, they do not report statistical analysis^[15].

Beals *et al* followed up the patients to skeletal maturity but operated on tibias only for correction of bowlegs and not for elongation^[16].

We found a statistically significant difference between LPFA, LDFA, MPTA, LDTA, PDFA, PPTA and ADTA of achondroplastic patients and normal subjects' values.

The proposed explanation of the fact that the radiologic image at follow up was not restored to normal range is multifold. Primarily due to the learning curve, the later years the correction was more accurate. Secondly, we did not use a computer software when performing the preoperative design of the operation, which would enable us to more accurately perform the procedure. In addition we speculate that a certain degree of recurrence may have occurred in some cases since our follow up is quite long.

Other studies also report recurrence. Vaidya reported recurrence of distal tibial varus in two out of eleven (2/11) tibias that underwent a lengthening with the Ilizarov method and proposed the residual abnormal MAD due to femoral deformity, as an explanation^[15].

In addition, our sample's mean MAD at follow up was 28 mm, a value not within the normal range. Our finding is similar to others. Yasui reported a MAD that was not necessarily in correct alignment in 35 achondroplastic patients that underwent lower limb lengthening and were followed up for a mean time of 3.2 years^[4]. Beals reported an average MAD of 7 mm in 22 achondroplastic patients that underwent varus correction but not lengthening^[16].

All our patients were pleased with the result, felt normal and no longer handicapped, in their own opinions. All, but one, would have no hesitation undergoing the same procedure again if they could turn back time. Therefore, the method can help improve their life even though they still have a different appearance.

Other authors have reported on the psychological aspects of lower limb elongation in achondroplastic patients as well. They noted increase of self esteem scores^[42] and substantial improvement of body image after the procedure^[43].

Future research with additional accurate computer systems, such as gait analysis, is needed to examine whether these radiographic results reflect a functional disability as well.

In conclusion, the use of the Ilizarov method for lower limb deformity correction, in achondroplastic patients, provides a functional length gain, it is substantially correcting the three-dimensional deformities of the disease but, it does not restore the radiological image within normal standards.

CONFLICT OF INTERESTS

There are no conflicts of interest with regard to the present study.

REFERENCES

- Matsui Y, Kimura T, Tsumaki N. A common FGFR3 mutation functions as a diagnostic marker for achondroplasia- group disorders in the Japanese population. *J Orthop Sci* 1966; **1**: 130-135
- Waller DK, Correa A, Vo TM, Wang Y, Hobbs C, Langlois PH, Pearson K, Romitti PA, Shaw GM, Hecht JM. The population-based prevalence of achondroplasia and thanatophoric dysplasia in selected regions of the US. *Am J Med Genet A* 2008; **146A(18)**: 2385-2389
- Winne- Davies R, Hall CM, Apley AG. Atlas of skeletal dysplasias. Edinburgh, Churchill Livingstone 1985; 181-212
- Yasui N, Kawabata H, Kojimoto H, Ohno H, Matsuda S, Araki N, Shimomura Y, Ochi T. Lengthening of the lower limb in patients with achondroplasia and hypochondroplasia. *Clin Orthop Relat Res* 1997 Nov; **344**: 298-306
- Schiedel F, Rödl R. Lower limb lengthening in patients with disproportionate short stature with achondroplasia: a systematic review of the last 20 years. *Disabil Rehabil* 2012; **34(12)**: 982-987
- Molinari E, Sartorio A. Psiche e bassa statura. Raffaello Cortina, 1999
- Karlberg P, Taranger J, Engström I, Karlberg J, Landström T, Lichtenstein H, Lindstrom B, Svennberg-Redegren I. I.Physical growth from birth to 16 years and longitudinal outcome of the study during the same age period. *Acta Paediatr Scand Suppl* 1976; **258**: 7-76
- Correll J. Surgical correction of short stature in skeletal dysplasias. *Acta Paediatr Scand Suppl* 1991; **377**: 143-148
- Ganel A, Horoszowski H, Kamhin M, Farine I. Leg lengthening in achondroplastic children. *Clin Orthop* 1979; **144**: 194-197
- Inan M, Thacker M, Church C, Miller F, Mackenzie WG, Conklin D. Dynamic lower extremity alignment in children with achondroplasia. *J Pediatr Orthop* 2006 Jul-Aug; **26(4)**: 526-529
- Laurencin CT, Ferriter PJ, Millis MB. Oblique proximal tibial osteotomy for the correction of tibia vara in the young. *Clin Orthop Relat Res* 1996; **327**: 218-224
- Nehme AM, Riseborough EJ, Tredwell SJ. Skeletal growth and development of the achondroplastic dwarf. *Clin Orthop Relat Res* 1976; **116**: 8-23
- Saleh M, Burton M. Leg lengthening: patient selection and management in achondroplasia. *Orthop Clin North Am* 1991; **22(4)**: 589-599
- Trivella G, Aldegheri R. Surgical correction of short stature. *Acta Paediatr Scand Suppl* 1988; **347**: 141-146
- Vaidya SV, Song HR, Lee SH, Suh SW, Keny SM, Telang SS. Bifocal tibial corrective osteotomy with lengthening in achondroplasia: an analysis of results and complications. *J Pediatr Orthop*. 2006 Nov-Dec; **26(6)**: 788-793
- Beals RK, Stanley G. Surgical correction of bowlegs in achondroplasia. *J Pediatr Orthop B* 2005; **14(4)**: 245-249
- De Bastiani G, Aldegheri R, Renzi-Brivio L, Trivella G. Limb lengthening by callus distraction (callotaxis). *J Pediatr Orthop* 1987; **7**: 129-34
- Ilizarov GA. Theoretical and Clinical Aspects of the Regulation and Growth of Tissue. In: Transosseous Osteosynthesis. *Springer-Verlag*, 1991
- Tsuchiya H. Deformity correction followed by lengthening with the Ilizarov method. *Clin Orthop* 2002; **402**: 176-183
- Cattaneo R, Villa A, Catagni M. Limb lengthening in achondroplasia by the Ilizarov method. *Int Orthop* 1988; **12**: 173-179
- Peretti G, Memeo A, Paronzini A, Marzorati S. Staged lengthening in the prevention of dwarfism in achondroplastic children: a preliminary report. *J Pediatr Orthop B* 1995; **4**: 58-64
- Saleh M, Hamer AJ. Bifocal limb lengthening: a preliminary report. *J Pediatr Orthop B* 1993; **2**: 42-48
- Langer LO, Baumann PA, Gorlin RJ. Achondroplasia. *Am J Roentgenol Radium Ther Nucl Med* 1967 May; **100(1)**: 12-26
- Paley D. Hardware and osteotomy considerations. In: Paley D, Herzenberg JE, eds. Principles of deformity correction. *Springer*; 2003: 383-387
- Paley D. Radiographic assessment of lower limb deformities. In: Principles of deformity correction. *Springer* 2005: 31-37
- Paley D, Herzenberg JE, Tetsworth K, McKie J, Bhava A. Deformity planning for frontal and sagittal plane corrective osteotomies. *Orthop Clin North Am*. 1994 Jul; **25(3)**: 425-65
- Segev E, Hemo Y, Wientroub S, Ovadia D, Fishkin M, Steinberg DM, Hayek S. Intra- and interobserver reliability analysis of digi-

- tal radiographic measurements for pediatric orthopedic parameters using a novel PACS integrated computer software program. *J Child Orthop* 2010 Aug; **4**(4): 331-341
- 28 Chao EY, Neluhani EV, Hsu RW, Paley D. Biomechanics of malalignment. *Orthop Clin North Am* 1994; **25**: 379-386
- 29 Chiu KY, Zhang SD, Zhang GH. Posterior slope of tibial plateau in Chinese. *J Athroplasty* 2000; **15**: 224-227
- 30 Cooke TD, Li J, Scudamore RA. Radiographic assessment of bony contributions to knee deformity. *Orthop Clin North Am* 1994; **25**: 387-393
- 31 Cooke TD, Siu D, Fisher B. The use of standardized radiographs to identify the deformities associated with osteoarthritis. In: Noble J, Galasko CSB (eds) Recent developments in orthopaedic surgery. Manchester University Press, 1987
- 32 Matsuda S, Miura H, Nagamine R, Urabe K, Ikenoue T, Okazaki K, Iwamoto Y. Posterior tibial slope in the normal and varus knee. *Am J Knee Surg* 1999; **12**: 165-168
- 33 Meister K, Talley MC, Horodyski MB, Indelicato PA, Hartzel JS, Batts J. Caudal slope of the tibia and its relationship to noncontact injuries to the ACL. *Am J Knee Surg* 1998; **11**(4): 217-219
- 34 Moreland JR, Bassett LW, Hanker GJ. Radiographic analysis of the axial alignment of the lower extremity. *J Bone Joint Surg Am* 1987; **69**: 745-749
- 35 Paley D, Chaudray M, Pirone AM, Lentz P, Kautz D. Treatment of malunions and mal-nonunions of the femur and tibia by detailed preoperative planning and the Ilizarov techniques. *Orthop Clin North Am* 1990; **21**(4): 667-691
- 36 Kamegaya M, Shinohara Y, Shinada Y. Limb lengthening and correction of angular deformity: immediate correction by using a unilateral fixator. *J Pediatr Orthop* 1996; **16**: 477-479
- 37 Blondel B, Launay F, Glard Y, Jacopin S, Jouve J-L, Bollini G. Limb lengthening and deformity correction in children using hexapodal external fixation: Preliminary results for 36 cases. *Orthop Traumatol Surg Res* 2009 Oct; **95**(6): 425-430
- 38 Bridgman SA, Bennet GC, Evans GA, Stirling J. Leg lengthening. *J R Coll Surg Edinb* 1993 Apr; **38**(2): 101-104
- 39 Ganel A, Horoszowski H. Limb lengthening in children with achondroplasia. Differences based on gender. *Clin Orthop Relat Res* 1996 Nov; **332**: 179-183
- 40 Lie CW, Chow W. Limb lengthening in short-stature patients using monolateral and circular external fixators. *Hong Kong Med J* 2009 Aug; **15**(4): 280-284
- 41 Windhager R, Tsuboyama T, Siegl H, Groszschmidt K, Seidl G, Schneider B, Plenk H Jr. Effect of bone cylinder length on distraction osteogenesis in the rabbit tibia. *J Orthop Res* 1995; **13**: 620-628
- 42 Kim SJ, Bake GC, Agashe MV, Song SH, Song HR. Is bilateral lower limb lengthening appropriate for achondroplasia?: midterm analysis of the complications and quality of life. *Clin Orthop Relat Res* 2012 Feb; **470**(2): 616-621
- 43 Fennig-Naisberg S, Fennig S, Ganel A, Sack T, Tyano S. Body image of achondroplastic children before and after leg elongation. *Isr J Psychiatry Relat Sci* 1993; **30**(1): 33-39

Peer reviewers: Manuel Bondi, Carlo Poma Hospital, Department of Orthopaedic and Traumatology, Strada Lago Paiolo 10, 46100 Mantova, Italy; Linghui Dai, Institute of Sports Medicine, Peking University Third Hospital, 49 North Huayuan Road, Haidian District, Beijing 100191, P.R China; Rubén Daniel Arellano, Avenida Morelos 900 Oriente, Torreón, Coahuila, México.