

## Philos Plate in Proximal Humerus Fracture—Its Functional Outcome and Complications

Vivek Bansal, H.S Sohal, R.S Bhoparai

Vivek Bansal, Senior Resident MS Orthopedics, Post graduate institute of medical sciences, Haryana, India

H.S Sohal, Professor and Head MS Orthopedics, Government medical college, Amritsar, Punjab, India

R.S Bhoparai, Professor MS Orthopedics, Government medical college, Amritsar, Punjab, India

Correspondence to: Vivek Bansal, Bansal hospital old bus stand rania, Sirsa, 125076 India.

Email: [bansalvivek1985@gmail.com](mailto:bansalvivek1985@gmail.com)

Telephone: +91-08750008350

Received: December 21, 2014

Revised: January 18, 2015

Accepted: January 21, 2015

Published online: June 23, 2015

### ABSTRACT

**AIM:** Technique for the fixation of two, three, and four part proximal humerus fractures has rapidly shifted towards the use of locking plates. The objective of this prospective study was to evaluate functional outcome and complications of proximal humeral fractures managed with proximal humerus internal locking system (PHILOS).

**METHODS:** 16 men and 9 women aged 19 to 82 (mean, 49.24) with an acute proximal humerus fracture were treated with PHILOS plate by using deltopectoral approach. Outcome measurements included Constant score, complications, and radiographic assessment.

**RESULTS:** 11 patients had 2-part fractures, 11 patients had 3-part fractures, and 3 patients had 4-part fractures. After 6 month follow up, a mean Constant score 57.4 was achieved. Outcomes were excellent in 16%, good in 44%, fair in 16% while poor in 24%. The Constant score was poorer for Neer type IV fractures as compared to other types. The most frequently occurring complications in our patients were malreduction 20%, screw perforation 16%, infection 12%, avascular necrosis 8%, frozen shoulder 8%, impingement 4% and plate pull out 4%.

**CONCLUSION:** Fixation of proximal humerus fractures with

proximal humerus locking plates is associated with satisfactory functional outcomes in 2-part and 3-part fracture. The incidence of complications and subsequent re-operation is relatively high. Advanced surgical skills and surgeon's experience are considered to be more critical for successful operative treatment.

© 2015 ACT. All rights reserved.

**Key words:** Proximal humerus fracture; PHILOS; Constant score; Deltopectora; Neer type; Locking plate

Bansal V, Sohal HS, Bhoparai RS. Philos Plate in Proximal Humerus Fracture—Its Functional Outcome and Complications. *International Journal of Orthopaedics* 2015; 2(3): 317-322 Available from: URL: <http://www.ghrnet.org/index.php/ijo/article/view/985>

### INTRODUCTION

Proximal humeral fractures are now recognized as an increasingly common fracture, accounting for 4%–5% of all fractures and 45% of all humeral fractures<sup>[1,2]</sup>. It is the third most common fracture, in people above 65 years of age, after fractures of the hip and distal radius<sup>[3]</sup>. These fractures have a bimodal distribution occurring either in young people following high energy trauma or in those older than 50 years with low velocity injuries like simple fall<sup>[3]</sup>. 85% of these fractures are minimally displaced and are effectively treated with immobilization followed by early motion. The remaining 15% of these are either displaced or unstable<sup>[4]</sup>. These fare poorly with non-operative treatment and are better treated with surgical intervention. Surgical treatment is necessary especially in young patients and active elderly people in order to prevent minimal dislocations of tuberosity or articular surface from compromising the long-term articular function.

The aim of treatment in proximal humeral fractures is to achieve a painless and simultaneously functional shoulder. This result depends on the age, medical condition, bone quality and expectations of the patient as well as a good evaluation of the current fixation

techniques. Traditional treatment techniques include open reduction and internal fixation with proximal humeral plates, hemiarthroplasty, and percutaneous or minimally invasive techniques such as pinning, screw osteosynthesis, and the use of intramedullary nails. Loosening or failure of the implant and nonunion are possible complications of surgery in humeral fractures. There is still no treatment that can be the golden standard in this fractures<sup>[5-8]</sup>.

In order to decrease the high complication rates of proximal humeral fractures, the AO/ASIF group developed the PHILOS (The Proximal Humeral Internal Locking Osteosynthesis) plate (Synthes, Stratec Medical Ltd, Mezzovico Switzerland); an internal fixation system that enables angled stabilization with multiple interlocking screws. However, there are few prospective studies available that actually evaluate the results of this technique or report on the treatment-related complications<sup>[9-17]</sup>. This study was planned to evaluate the outcome of proximal humerus fractures managed with PHILOS plate after approval by the Institutional Ethical Board.

## MATERIALS AND METHODS

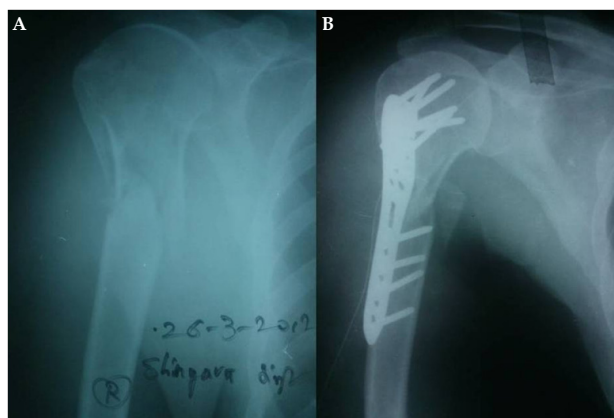
This prospective interventional study was conducted in the department of orthopedics at a tertiary care centre, Amritsar from July 2011 to May 2013. Total 25 consecutive adult patients of either sex with displaced proximal humerus fractures that met the criteria for operative treatment as outlined by Neer<sup>[18]</sup> i.e. an angulation of articular surface of more than 45 degrees, a displacement between the major fracture fragments more than 1 cm or a fracture with valgus impaction were included in the study. Exclusion criteria included nondisplaced proximal humerus fractures, fracture dislocations and head splitting fractures, infection at the site of fracture, patients below age 18 years and pathologic fractures. All the cases were assessed clinically, resuscitated (if required) and treated accordingly. All routine investigations and preoperative X rays were sent. Classification of fracture was done using Neer's classification system. Surgery was performed in supine position on a radiolucent table under general anaesthesia using the anterior deltopectoral approach. The cephalic vein was retracted laterally or ligated to prevent inadvertent injury during retractor placement. The greater and lesser tuberosity fragments were tagged with non-absorbable sutures. The tuberosity fragments were reduced to the lateral cortex of the shaft. Reduction of the tuberosities may indirectly reduce the head fragment; alternatively, to restore the medial calcar of the proximal humerus, an elevator was inserted to disimpact the head fragment. If required, the fracture was reduced and provisionally fixed into position using 1.5 mm Kirschner wires, sutures were passed through the rotator cuff and attached to the plate through the suture eyelets before permanent fixation with the contoured proximal humerus locking plate will be performed. On the anteroposterior view, the plate was ideally placed 8-10 mm distal to the superior tip of the greater tuberosity; from the lateral view, the plate was centred against the lateral aspect of the greater tuberosity. An adequate gap was left between the plate and the biceps tendon to prevent disruption of the anterior humeral circumflex artery or entrapment of the tendon. The initial screw was then placed in the elongated hole in the humeral shaft (in classic 3 or 4 part fractures), so that the height of the plate could be adjusted. After achieving the appropriate fracture reduction and plate position, the locked screws were inserted into the humeral head using the insertion guide and sleeve assembly. At least three distal shaft screws were inserted. A final fluoroscopic image was taken to ensure adequate reduction and proper medial support. Rotator cuff, capsule and subscapularis muscle tears/avulsions were

repaired meticulously. The wound was closed in layers and a suction drain will be inserted.

Active assisted and passive exercises were used during the first two weeks, and 3 weeks later active motion was started. On the 8th postoperative week, daily activities were allowed. Patients were followed up on OPD basis at 2 weeks at first postoperatively then after every month till 6 months then every 3 months till 2 years. At every follow up, patients were assessed clinically for shoulder stability and range of motion and radiographically checked for the progress of fracture healing. Radiographic union was defined as bridging trabeculation across the fracture site in the absence of hardware breakage or cut-out. The complications were also documented. Evaluation of results were done on basis of scoring system given by Constant and Murley score, the scoring system of which comprises four parts: pain, power, activities of daily living and range of movement. The Constant score was graded as poor (0-39 points), fair (40-59), good (60-79) or excellent (80-100).

## RESULTS

The mean age of our twenty-five patients was 49.24 (19-82), with a male: female ratio of 1.7:1 (16:9). 10 patients belong to age group more than 50 years suggesting a strong relation of proximal humerus with age related osteoporosis. Majority of patients sustained injury due to road traffic accident (68%) followed by fall on out stretched hand (20%) and other causes (12%). Twelve cases involved the dominant side. 11 (44%) had 2-part fractures (Figure 1), 11 (44%) had 3-part fractures and 3 (12%) had 4-part fractures according to Neer.



**Figure 1** (A) 2 part proximal humerus fracture (Neer's classification); (B) union with PHILOS plate after 3 months.

### Function

Fractures united at an average of 11.2 weeks (range, 8-17 weeks). Three patients developed nonunion due to avascular necrosis in two patients and plate pulled out in one patient. Table 1 and table 2 shows Constant scores of the patients at the final follow up visit according to fracture types and age respectively. Overall the functional outcome was found to be good to excellent in 60% of our patients however almost 24% patients had poor outcome. The mean Constant score achieved was 57.4 (range, 17-80). We found that patients with Neer type III fractures had the highest Constant scores while patients with Type IV had the lowest Constant scores. Patients less than 60 years of age group showed better response (Table 2).

**Complications**

Various complications seen in our study have been shown in table 3 (Figure 2). In this study, we found 11 (44%) patients with a total of 15 complications (Figure 3, 4), requiring a total of 6 (24%) revision surgeries. Complications like suprascapular or axillary nerve injury or deltoid weakness were not encountered.

**DISCUSSION**

In our study men suffered more complex fractures because they are venerable to more high-energy trauma. Western literature has shown proximal humerus fractures to be more common in elderly females<sup>[19]</sup>. In contrast to majority of studies in western literature that consider low energy falls as a more common cause for proximal humerus fractures, our study had 56% patients with history of road traffic accident. The ratio of high energy to low energy injury in our study was 1.27:1. India, as reported by world health organization, has the worst road traffic accident rate worldwide because of no traffic sense, which could be a reason for such a difference. Moreover our hospital being a tertiary care hospital had a greater proportion of patients with high-energy polytrauma as compared to low energy isolated fractures of the proximal humerus.

**Table 1** Functional outcome on the basis of Constant score at the last follow up visit.

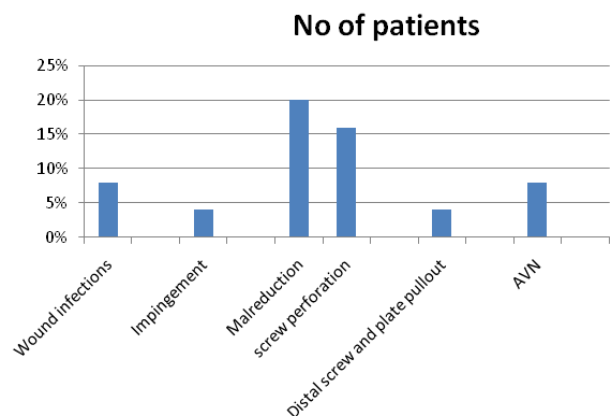
Type of fracture	Mean Constant score	Excellent	Good	Fair	Poor
II part fracture (11)	57.7	3	4	1	3
III part fracture (11)	60	1	6	2	2
IV part fracture (3)	48.3	0	1	1	1
Total (25)	57.4	4	11	4	6

**Table 2** Constant score at follow up visits according to the age of patient.

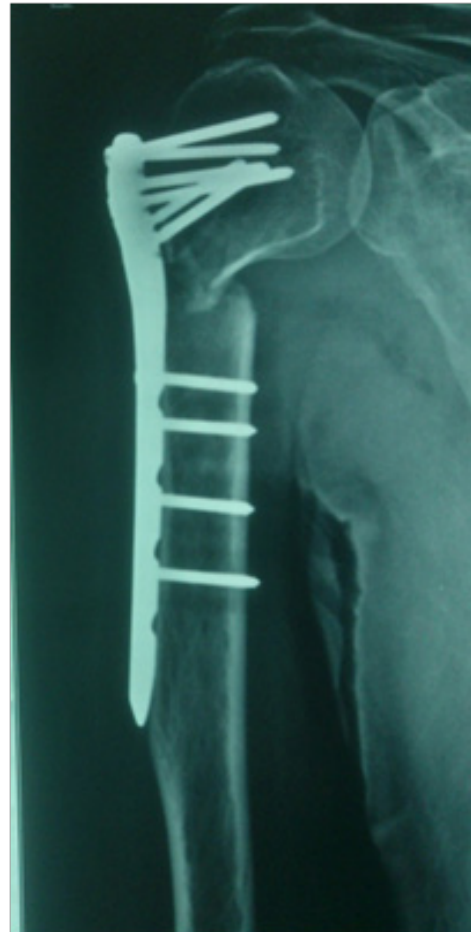Age group	Mean constant score
< 60 years (18)	59.5
≥ 60 years (7)	51

**Table 3** Postoperative complications after treatment with PHILOS plate.

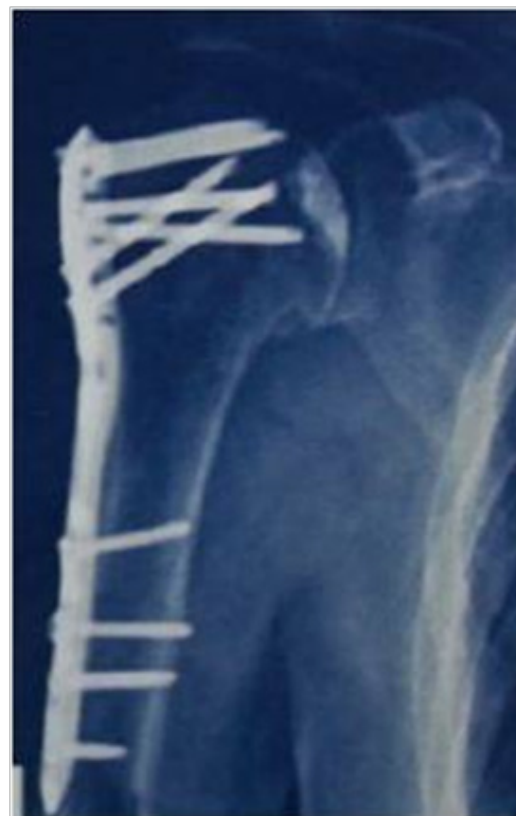Complication	No of patients
Wound infections	2 (8%)
Impingement	1 (4%)
Malreduction	5 (20%)
screw perforation	4 (16%)
Distal screw and plate pullout	1 (4%)
AVN	2 (8%)



**Figure 2** Postoperative complications after treatment with PHILOS plate.



**Figure 3** Varus malunion in a patient with 4-part fracture.



**Figure 4** Avascular necrosis in a patient with 4-part fracture.

Operative treatment of comminuted and displaced proximal humeral fractures, especially in osteoporotic bone, has been a complex and challenging problem. The PHILOS plate is locked compression plate that can also be used with minimally invasive technique. It permits indirect fracture reduction thus lowering the possibility of AVN and by reducing the need of immobilization time helps diminishing the possibility of frozen shoulder<sup>[20]</sup>. Furthermore, it is a low profile plate with the proximal fixed angled screws thus making it a fixating device with a high stability in osteoporotic bones. We could achieve a mean Constant Murley score of 57.4 due to various complications encountered with plates. Our results were somehow inferior to those reported in the western literature. Various studies had reported varying results. Thyagarajan et al in their study on 30 patients showed an overall average Constant score of 57.5. The mean age in this series was 58 years (range 19-92 years) and fractures were Neer's 2-part, 3-part, and 4-part fractures<sup>[21]</sup>. In one prospective study, mean constant score was 68.31 in 19 patients<sup>[13]</sup>. Kettler *et al*<sup>[11]</sup> reported a Constant-Murley score between 52 to 72 points after ORIF with the PHILOS plate. Hente *et al*<sup>[22]</sup> reached a mean Constant-Murley score of 55 points in these specific fracture types, which was lower than for fractures without dislocation. These results match ours, knowing that the Constant-Murley score of different studies are difficult to compare. However, the systematic review by Thanasis et al reported an overall Constant score of 74.3<sup>[23]</sup>. and most of other studies have reported good functional outcomes and recommended the use of locking plates for proximal humerus fractures especially in elderly patients with poor bone quality. This leads us to believe that application of locking plate technology for proximal humerus fractures has a steep learning curve and appropriate surgical technique is very important for achieve good functional outcome.

In our study also the mean Constant score for 4-part fractures was 48.3 which were inferior as compared to 2-part and 3-part fractures (57.60 and 60 respectively). This result is comparable to the one prospective study in which the mean Constant score for 4-part fractures was significantly inferior to other types<sup>[13]</sup>. The results of two studies indicated an advantage in functional outcomes favoring shoulder hemiarthroplasty compared with ORIF with a locking plate in 4-part fracture<sup>[24,25]</sup>. These results are expected as these fractures are more complex and open reduction and internal fixation is tougher. We found difference in outcome between patients of age group less than or more than 60 years of age. Patients less than 60 years of age group showed better response. Similar findings have been reported by Aggarwal et al who found the Constant scores to be higher in younger patients as compared to older patients (>65)<sup>[13]</sup>.

Post operatively, various complications were observed. A varus malunion was observed in 5 patients (20%) and was found to be the commonest complication in our study. Varus malunion was found in five out of 47 patients in one study<sup>[13]</sup>. Two patients had only malreduction who had fair outcome in one patient and poor outcome in other patient which lost to follow up after that. Two of these patients had also screw perforation leading to implant loosening. These patients had been fixed in a varus position and had an insufficient medial buttressing leading to poor outcome. Later on these patients underwent reoperation with implant removal and new proximal humerus locking plate. One patient had associated avascular necrosis of humerus head leading to poor outcome. This patient underwent hemiarthroplasty after 8 months leading to improvement in outcome. Re-operation rate was 31% found in published data<sup>[23]</sup>. We did not observe any valgus malunion in our study. We thus found that a varus malalignment was causing loss of fixation with poor outcome in four patients in similar to one prospective study<sup>[13]</sup> and

must be avoided intra-operatively at any cost. We in our patients attempted to achieve correct anatomic reduction of the fragments but still had a high percentage of patients with this complication.

Within our patient population, screw perforation occurred in 4 patients (16%). An early implant removal was done in two of these patients who had poor outcome while two of the patients underwent a repeat surgery to exchange the screws for shorter screws which lead to fair to good outcome later on. Yang *et al*<sup>[15]</sup> found an overall complication rate of 35.9 with a screw cut-out rate of 7.6%. Helwig *et al*<sup>[16]</sup> reported screw penetration of the humeral head in 11 of 87 patients (12.6%) and Thanasis et al. showed a screw cut-out rate of 11.6% in their review of 791 patients<sup>[23]</sup>. These previous studies agree that screw perforation of fixed-angle implants has replaced the complications of secondary displacement and implant loosening as the main implant related complication of non-fixed-angle implants.

All our cases with screw penetration in the joint were those from the early cases when we started using this implant. The locking mechanism was found to give inadequate evaluation of the bone quality and screw fixation. We always checked the correct proximal position of every single screw separately by rotating the arm using an image intensifier. We preferred to put a smaller sized screw whenever the length measured fell between two screw sizes. In our patients, the screw size is measured with the help of depth gauge under image intensifier. We used 2-3 mm shorter screw sizes than the measured length.

Postoperatively, impingement was observed in 1 patient (4%). This patient with impingement had severe limitation of overhead abduction initially associated with severe pain in his operated shoulder. He got his plate removed at 5 months post operatively and good functional score was seen. The systematic review of twelve studies by Thanasis et al reported an impingement rate of 5.5%<sup>[23]</sup>. We in our patients placed the plate in such a way that, proximal most part of the plate was in line with the tip of the greater tuberosity. Plate was fix with k-wires through the proximal most hole and check under C-arm throughout the arc of abduction.

Avascular necrosis (AVN) is one of the most dramatic complications requiring re-operation. 2 patients (8%) in our study were reported to have developed osteonecrosis of the humeral head and poor results. One patient (4%) was of two part fractures and one patient (4%) was of four part fractures. Both of them were later operated with hemiarthroplasty after the removal of implant and the result was found to be good. As per the published literature, the chances of AVN of the shoulder are directly proportional to the severity of the injury. The risk of osteonecrosis increases if the anterolateral branch of the anterior humeral circumflex artery is damaged. Utmost care should be taken while exposing the biceps tendon in the bicipital groove.

Deep wound infection was seen in 1 patient (4%). Implant removal was done in this patient who was reoperated later; repeat plating being done 7 months after the infection had settled. However superficial wound infection, not requiring a formal debridement, was seen in 1 of our patients. The patients with superficial infection were treated with oral antibiotics.

Postoperatively, 6 patients (24%) in our study got their plate removed. One patient got his plate removed because of deep infection with distal screw and plate pullout, two patients (8%) got his plate removed because of AVN and implant loosening, two patients got his plate removed due to screw perforation, malreduction and implant loosening. These 5 patients had poor outcome. One patient (4%) got his plate removed due to impingement at 5 months leading to fair outcome. In our study, we did not encounter any implant breakage



consistent with systematic review who reported this complication to be rare with an incidence of 0.7%<sup>[23]</sup>. It has been declared that for patients having low Constant - Murley scores removal of the plate may lead to a better performance.

A high rate of complications was found in our study in early cases but later on with surgeon's experience, further less complications were encountered. In one recent systematic review the overall rate of complications was 49% including varus malunion, 33% excluding varus malunion, and reoperation rate was 14%. The most common complications included varus malunion 16%, AVN 10%, screw perforation of the humeral head into the joint 8%, subacromial impingement 6%, and infection 4%<sup>[26]</sup>. Various studies have stressed out the association of high rate of complications and need for reoperation<sup>[23,26,27]</sup>.

The limitation of this study is lack of a control group and less follow up period and we do not evaluate any patient characteristics which can be risk factors for failure of this now common fixation technique.

## CONCLUSION

Fixation of proximal humerus fractures with proximal humerus locking plates is associated with satisfactory functional outcomes in 2-part and 3-part fracture. The incidence of complications and subsequent re-operation is relatively high. Based on our observations, inadequate positioning of the implant resulted in reduced functional outcome. Hence, to improve functional results, we consider plate positioning to be of utmost importance when using PHILOS plate fixation. Adequate surgical skills and surgeon's experiences with the surgical technique are necessary to achieve correct implant fixation and avoid these intraoperative errors. Moreover patient's risk for complications should be evaluated more individually and taken into consideration for the concept of treatment.

## ACKNOWLEDGEMENTS

All patients gave written informed consent to be included in this study, and the study was authorized by the local ethical committee and performed in accordance with the ethical standards of the 1964 Declaration of Helsinki as revised in 2000.

## CONFLICT OF INTERESTS

There are no conflicts of interest with regard to the present study.

## REFERENCES

- Palvanen M, Kannus P, Niemi S, Parkkari J. Update in the epidemiology of proximal humeral fractures. *Clin Orthop* 2006;442:87-92.
- Spence RJ. Fractures of the proximal humerus. *Curr Opin Orthop* 2003;14:269-80.
- Baron JA, Barrett JA, Karagas MR. The epidemiology of peripheral fractures. *Bone* 1996;18(3):209S-13S.
- Court-Brown CM, Garg A, McQueen MM. The epidemiology of proximal humeral fractures. *Acta Orthop Scand* 2001;72:365-71.
- Robinson CM, Page RS. Severely impacted valgus proximal humeral fractures: Results of operative treatment. *J Bone Joint Surg Am* 2003, 85:1647-55.
- Wanner GA, Wanner-Schmid E, Romero J, Hersche O, von Smeal A, Trentz O, Ertel W. Internal fixation of displaced proximal humeral fractures with two one-third tubular plates. *J Trauma* 2003, 54:536-44.
- Park MC, Murthi AM, Roth NS, Blaine TA, Levine WN, Bigliani LU. Two-part and three-part fractures of the proximal humerus treated with suture fixation. *J Orthop Trauma* 2003, 17:319-25.
- Schmal H, Klemm C, Sudkamp NP. [Evaluation of shoulder arthroplasty in treatment of four-fragment fractures of the proximal humerus]. *Unfallchirurg German* 2004, 107:575-82.
- Fankhauser F, Boldin C, Schippinger G, Haunschmid C, Syzskowitz R. A new locking plate for unstable fractures of the proximal humerus. *Clin Orthop Relat Res* 2005, 430:176-81.
- Koukakis A, Apostolou CD, Taneja T, Korres DS, Amini A. Fixation of proximal humerus fractures using the PHILOS plate: early experience. *Clin Orthop Relat Res* 2006, 442:115-20.
- Kettler M, Biberthaler P, Braunstein V, Zeiler C, Kroetz M, Mutschler W. [Treatment of proximal humeral fractures with the PHILOS angular stable plate. Presentation of 225 cases of dislocated fractures]. *Unfallchirurg German* 2006, 109:1032-40.
- Südkamp N, Bayer J, Hepp J, Voigt C, Oestern H, Kabb M, Luo C, Plecko M, Wendt K, Köstler W, Konrad G. Open reduction and internal fixation of proximal humeral fractures with use of the locking proximal humerus plate. Results of a prospective, multicenter, observational study. *J Bone Joint Surg Am* 2009, 91(6):1320-8.
- Aggarwal S, Bali K, Dhillon MS, Kumar V, Mootha AK. Displaced proximal humeral fractures: an Indian experience with locking plates. *J Orthop Surg Res.* 2010;5:60.
- Bigorre N, Talha A, Cronier P, Hubert L, Toulemonde JL, Massin P. A prospective study of a new locking plate for proximal humeral fracture. *Injury* 2009, 40(2):192-6.
- Yang H, Li Z, Zhou F, Wang D, Zhong B. A prospective clinical study of proximal humerus fractures treated with a locking proximal humerus plate. *J Orthop Trauma* 2011;25:11-7.
- Helwig P, Bahrs C, Epple B, Oehm J, Eingartner C, Weise K. Does fixed-angle plate osteosynthesis solve the problems of a fractured proximal humerus? A prospective series of 87 patients. *Acta Orthop* 2009;80:92-6.
- Shahid R, Mushtaq A, Northover J, Maqsood M. Outcome of proximal humerus fractures treated by PHILOS plate internal fixation. Experience of a district general hospital. *Acta Orthop Belg* 2008;74:602-8.
- Neer CS. Displaced proximal humeral fractures-II. Treatment of three-part and four-part displacement. *J Bone Joint Surg Am* 1970, 52(6):1090-103.
- Chu SP, Kelsey JL, Keegan TH, Sternfeld B, Prill M, Quesenberry CP, Sidney S. Risk factors for proximal humerus fracture. *Am J Epidemiol* 2004, 15(160):360-7.
- Thyagarajan DS, Haridas SJ, Jones D, Dent C, Evans R, Williams R. Functional outcome following proximal humeral interlocking system plating for displaced proximal humeral fractures. *Int J Shoulder Surg.* 2009;3(3):57-62.
- Hente R, Kampshoff J, Kinner B, Fuchtmeier B, Nerlich M. [Treatment of dislocated 3- and 4-part fractures of the proximal humerus with an angle-stabilizing fixation plate][in German]. *Unfallchirurg.* 2004;107:769-82.
- Thanasas C, Kontakis G, Angoules A, Limb D, Giannoudis P. Treatment of proximal humerus fractures with locking plates: a systematic review. *J Shoulder Elbow Surg.* 2009;18(6):837-44.
- Cai M, Tao K, Yang C, Li S. Internal fixation versus shoulder hemiarthroplasty for displaced 4-part proximal humeral fractures in elderly patients. *Orthopedics.*2012;35(9):e1340-6.
- Spross C, Platz A, Erschbamer M, Lattmann T, Dietrich M. Surgical treatment of Neer Group VI proximal humeral fractures: retrospective comparison of PHILOS® and hemiarthroplasty. *Clin Orthop Relat Res* 2012;470(7):2035-42.
- Sproul RC, Iyengar JJ, Devic Z, Feeley BT. A systematic review of locking plate fixation of proximal humerus fractures. *Injury.* 2011;42(4):408-13.

Bansal V *et al.* Philos plate in proximal humerus fractures

26. Spross C, Platz A, Rufibach K, Lattmann T, Forberger J, Dietrich M. The PHILOS plate for proximal humeral fractures--risk factors for complications at one year. *J Trauma Acute Care Surg.* 2012;72(3):783-92.

**Peer reviewers:** Jun Iwamoto, Institute for Integrated Sports Medicine, Keio University School of Medicine, 35 Shinanomachi, Shinjuku-ku, Tokyo 160-8582, Japan; Marcello Castiglia, Rua Manoel Achê, 920 – Ap 1003, Ribeirão Preto/SP, 14020-590, Brazil.