

Cytotoxic Effects of Contrast Media on Renal Tubular Cells. Pathogenesis of Contrast-induced Acute Kidney Injury and Prevention

Michele Andreucci, Teresa Faga, Ashour Michael

Michele Andreucci, Teresa Faga, Ashour Michael, Nephrology Unit, Department of "Health Sciences", Campus "Salvatore Venuta", "Magna Graecia" University, Viale Europa, loc. Germaneto, I-88100 Catanzaro, Italy

Correspondence to: Michele Andreucci, MD, PhD, Associate Professor of Nephrology, Magna Graecia" University, I-88100 Catanzaro, Italy

Email: andreucci@unicz.it

Telephone: +39-339-6814750

Received: January 8, 2015

Revised: January 30, 2015

Accepted: February 4, 2015

Published online: March 30, 2015

ABSTRACT

The continued growth in radiographic procedures for diagnostic or therapeutic purposes is leading to an increasing number of cases of contrast-induced Acute Kidney Injury (CI-AKI) secondary to Iodinated RadioContrast Agents (IRCA). In this review, following a brief description of IRCA and CI-AKI, the pathogenesis of CI-AKI is discussed in detail, particularly focusing on the direct toxic effects by IRCA on endothelial cells, red blood cells and mainly on renal tubular epithelial cells. *In vitro* studies of the effects of different IRCA on various signalling pathways known to play a role in cellular survival, growth and proliferation are reported, demonstrating that IRCA cause several and significant changes in a variety of cell signalling molecules that play important roles in cellular homeostasis. Factors favouring toxic effects by IRCA on renal tubular epithelial cells and protection of tubular cells against IRCA toxicity (by e.g. asialoerythropoietin, human serum albumin-Thioredoxin, extracellular volume expansion) are discussed. Measures to prevent IRCA nephrotoxicity by antioxidants and recent studies demonstrating reversal of IRCA toxicity on human renal proximal tubular cells by white grape juice extract conclude the review.

© 2015 ACT. All rights reserved.

Key words: Contrast induced nephropathy; Nephrotoxicity; Cell death, Kinase; Cell signalling

Andreucci M, Faga T, Michael A. Cytotoxic Effects of Contrast Media on Renal Tubular Cells. Pathogenesis of Contrast-induced Acute Kidney Injury and Prevention. *Journal of Biochemistry and Molecular Biology Research* 2015; 1(1): 1-13 Available from: URL: <http://www.ghrnet.org/index.php/jbmr/article/view/1012>

INTRODUCTION

The continued growth in radiographic procedures for either diagnostic or therapeutic purposes (coronary angiography and percutaneous coronary interventions) is leading to an increasing number of cases of contrast-induced Acute Kidney Injury (CI-AKI) secondary to Iodinated RadioContrast Agents (IRCA)^[1-3]. This is in part due to the type of patients undergoing these procedures, usually being of advanced age, with one or more comorbid conditions, such as advanced vascular disease, severe long-standing hypertension, diabetes and some renal function impairment^[4-7].

THE IODINATED RADIOCONTRAST AGENTS (IRCA)

In the last few decades, attempts have been made by many investigators to reduce the nephrotoxicity of IRCA making them more soluble, while at the same time allowing more opacity by increasing the content of iodine atoms per molecule. Thus, IRCA have undergone a series of chemical modifications. Firstly, hydrogen atoms on the benzene ring have been substituted in order to reduce protein binding: acetizoates and diatrizoates were obtained in this way. These compounds are ionic and are known as high-osmolar contrast media. The next step was to replace the carboxyl groups with non-polar groups giving non-ionic soluble molecules with lower osmolality (low-osmolar contrast media); these were further improved by the addition of more hydroxyl groups for increased

hydrophilicity, followed by a more even distribution of the hydroxyl groups on the molecule. Finally, the dimerization of two molecules via side chains on the benzene ring resulted in the non-ionic and iso-osmolar group of contrast media with increased iodine atoms per molecule^[8,9]. Thus, these chemical modifications have resulted in the availability of newer low-osmolar and iso-osmolar IRCA immediately used in clinical practice, and it is acknowledged that the low-osmolar IRCA and iso-osmolar IRCA are less nephrotoxic than high-osmolar IRCA^[10]. Despite this, *in vitro* cell culture studies have suggested that all of these types of IRCA still have a direct toxic effects on many different types of cells and may cause CI-AKI. Modern IRCA are based on the triiodinated benzene ring^[9]. The most common IRCA used in clinical practice are listed in table 1^[11,12].

CONTRAST-INDUCED ACUTE KIDNEY INJURY (CI-AKI)

The most important adverse effect of IRCA is undoubtedly CI-AKI, frequently called Contrast-Induced Nephropathy (CIN). It is an asymptomatic transient impairment of renal function, usually non-oliguric, occurring 24-72 hours after exposure to intravascular injection of IRCA that cannot be attributed to other causes^[13-15]. The KDIGO Group^[16] “proposes that the term Contrast Induced-Acute Kidney Injury (CI-AKI) (rather than CIN) be used for patients developing AKI secondary to intravascular radiocontrast media exposure”.

The decline of renal function is mirrored by the rise in serum Creatinine (SCr) that reaches its peak on the third to fifth day after the injection of IRCA and returns to baseline within 10-14 days^[17]. The extent of the rise in SCr for defining CI-AKI following the intravascular injection of IRCA is an increase in either its absolute value (by 0.5 mg/dL or greater) or its relative value (by 25% or greater on the baseline value). CI-AKI may also be defined as a decrease (to 30-60 mL/min/1.73m² - renal insufficiency-or less) in the estimated glomerular filtration rate (eGFR), i.e. the creatinine clearance calculated by using either the MDRD (Modification of Diet in Renal Disease) calculation^[18] or the CKD-EPI (Chronic Kidney Disease Epidemiology Collaboration) equation^[19], or the very simple Cockcroft-Gault formula^[20].

Some Authors have suggested that an evaluation of renal function by serum Cystatin C (or the CKD-EPI cystatin C equation) is better than SCr. Undoubtedly, since the relationship between SCr and GFR is exponential, small SCr differences will greatly impact the GFR values at low SCr values (corresponding to high GFR values), but the same difference will have minimal impact at high SCr values (corresponding to low GFR values)^[21]. Therefore, to detect the early impairment of renal function due to nephrotoxic radiographic contrast media, it is important to have a marker which is sensitive to

small changes of GFR when GFR is high. It has been thought that estimates of small changes of renal function based on a rise in serum cystatin C to be more accurate than those based on a rise in SCr when the GFR is near to the normal range. Thus, the behaviour of SCr has been compared to that of cystatin C, although unfortunately, it has turned out that the relationship between serum cystatin C and GFR was also exponential^[22]. Equations based on standardized cystatin C (CKD-EPI cystatin C equation) or cystatin C and creatinine (combined CKD-EPI equation) were then proposed by the CKD-EPI consortium in 2012^[23]. The better suitability of these equations (and especially the combined CKD-EPI equation) has been shown in different populations^[24-26]. It has been recently observed that eGFRcr-cys, but not eGFRcys, is more accurate than eGFRcr in measuring small changes in renal function^[27]. Even the recent KIDGO guidelines on CKD^[28] recommended using eGFRcr for the initial evaluation and using eGFRcys or eGFRcr-cys for confirmation in the clinical settings in which eGFRcr is less accurate. But other Authors^[29,30] found that estimates of GFR based on cystatin C were not superior to those based on SCr in the general population. In other words, there is no evidence that equations based on cystatin C alone or in combination with creatinine provide better GFR estimates in middle-aged members of the general population than the commonly used MDRD and CKD-EPI equations.

Sometimes CI-AKI may cause a severe impairment of renal function with oliguria (<400 mL/24 hrs), requiring dialysis. In such circumstances, according to the KDIGO Group^[16], it is reasonable to talk of Acute Renal Failure (ARF). In these cases the mortality is high. The clinical feature and the management of ARF caused by IRCA are the same as that for ARF due to other causes^[31-37].

CI-AKI is uncommon in patients with normal pre-existing renal function. It occurs more frequently in patients with renal impairment, particularly if associated with diabetes mellitus^[38].

PATHOGENESIS OF CONTRAST-INDUCED ACUTE KIDNEY INJURY (CI-AKI)

The pathogenesis of Acute Kidney Injury (AKI) secondary to Iodinated RadioContrast Agents (IRCA) is not fully understood. Many factors are involved (Figure 1):

(1) Hemodynamic changes: after intravascular injection, IRCA cause immediate and transient vasodilatation followed by prolonged vasoconstriction, leading to renal ischemia, especially in the outer renal medulla; the consequence will be a decrease of Renal Blood Flow (RBF), thereby leading to a decrease in the GFR^[13,39].

(2) Renal medullary hypoxia: resulting from (a) the vasoconstriction of vasa recta^[40,41], (b) changes in erythrocyte membrane skeleton^[40] (see later), (c) increase in tubular reabsorption in the thick ascending limb of Henle’s loops (see later).

Table 1 Iodinated Contrast Media Commonly Used in Clinical Practice.

Name	Type	Iodine content (mg/mL)	Osmolality mOsm/kg	Osmolality type	Viscosity, cps at 37°C
Ionic					
Diatrizoate (Hypaque 50)	Monomer	300	1550	HOCM	10.50
Metrizoate Isopaque (Conray 370)	Monomer	370	2100	HOCM	3.40
Ioxaglate (Hexabrix)	Dimer	320	580	LOCM	7.50
Nonionic					
Iopamidol (Isovist-370)	Monomer	370	796	LOCM	9.40
Iohexol (Omnipaque 350)	Monomer	350	884	LOCM	10.40
Iodixanol (Visipaque 320)	Dimer	320	290	IOCM	11.80

The osmolality of contrast media is compared with the osmolality of plasma; HOCM: High Osmotic Contrast Media have the highest osmolality, i.e. 5–8 times the osmolality of plasma; LOCM: Low Osmotic Contrast Media have an osmolality still higher than plasma, i.e. 2–3 times the osmolality of plasma; IOCM: Iso Osmotic Contrast Media have the same osmolality as plasma. Cps: Viscosity in Centipoise; (Reproduced from ref. [12] with permission; Data of viscosity from ref. [173].)

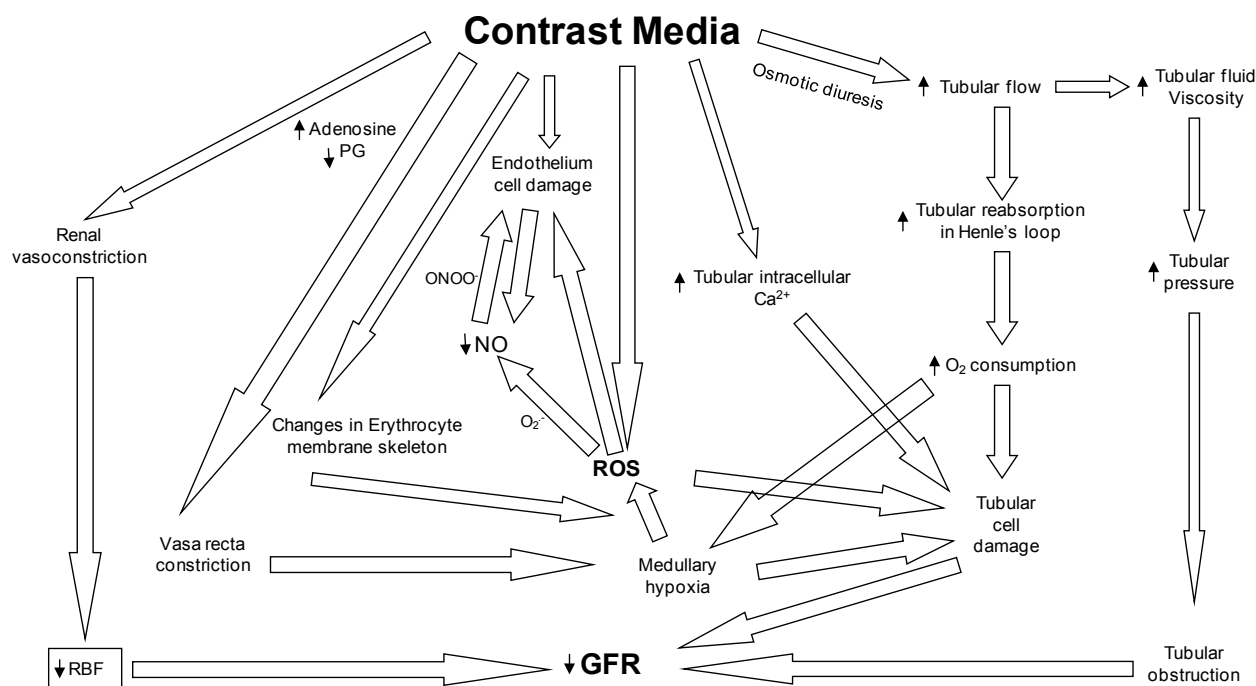


Figure 1 The complex mechanisms by which iodinated radiographic contrast media cause the fall of GFR (Reproduced from ref. [40] with permission).

(3) Tubular obstruction due to the increase in intratubular pressure due to the increased viscosity of the renal tubular fluid, thereby contributing to the decrease in the GFR^[39].

(4) Formation of reactive oxygen species (ROS)^[42-44], caused both directly by IRCA and by renal medullary hypoxia; they are responsible for (a) endothelial and tubular epithelial cell damage, (b) increase of renal parenchymal hypoxia by virtue of endothelial dysfunction and dysregulation of tubular transport^[45,46] (c) decrease of NO synthesis that is believed to be due to its reaction with ROS, in particular superoxide anions (O_2^-)^[47,48], leading to the formation of the more powerful oxidant detrimental peroxynitrite anion (ONOO⁻)^[49].

(5) Direct cytotoxicity, which has been suggested to be due, at least in part, to the free iodine present in solutions of IRCA that may lead to apoptosis and cell death of both endothelial and tubular cells^[47].

Many *in vitro* studies have investigated the toxicity of IRCA using different types of cultured cells: renal epithelial cells, mesangial cells, endothelial cells, smooth muscle cells, hepatic cells, human fibroblasts, pulmonary mast cells, human embryonic kidney cells and human neutrophils.

DIRECT TOXIC EFFECTS BY IRCA ON ENDOTHELIAL CELLS

All IRCA exhibit a more or less strong effect on endothelial cells^[50-53].

The endothelial cells are the first to come in contact with intravascular-injected IRCA. The endothelial damage, represented by nuclear protrusion, cell shrinkage, fenestration of the endothelial layer and formation of microvilli ('blebbing') on the cell membrane, and cellular apoptosis have been observed by scanning electron microscopy^[54]. The damaged endothelial cell (a) may contribute to the decrease in NO in the vasa recta^[47] and (b) may release endothelin that causes vasoconstriction (Figure 1). Heyman *et al.*^[55] have, in fact, demonstrated that the *i.v.* administration of contrast media

in rats induced an increase in plasma concentration of endothelin; furthermore, contrast media stimulated endothelin release from cultured bovine endothelial cells. These results suggest a direct effect of ionic and nonionic contrast agents on vascular endothelium to release endothelin^[39].

DIRECT TOXIC EFFECTS BY IRCA ON RED BLOOD CELLS

IRCA exhibit a toxic effect also on erythrocytes^[56-63].

Human erythrocytes circulating in the body are normally biconcave discocytes. Their excess surface area and the elasticity of their membranes provide them with the flexibility needed to pass through very small capillaries, demonstrating an ability for repeated large deformation^[64].

The erythrocyte membrane consists of a phospholipid bilayer with embedded membrane proteins and is associated on the cytoplasmic side with a network of proteins, the membrane cytoskeleton^[65]. The *bicarbonate/chloride exchanger band3* is the most abundant protein in the erythrocyte membrane^[66]. It has a very important role in gas exchange, senescence and removal of cells from the circulation, and functions as a point of attachment for the cytoskeleton, maintaining the mechanical and osmotic properties of the erythrocyte, *i.e.* membrane stability and flexibility^[67,68]. An intact cytoskeleton is vital for normal cell shape.

Under the influence of various agents, human erythrocytes change their shapes from the discocytes to stomatocytes or echinocytes^[69]. Some radiographic agents induce shape changes from discocytic to echinocytic cells^[56,60,70]. The echinocyte formation is associated with a rigidification of the cells bearing the risk of a hindered capillary passage of the echinocytes^[64], thereby contributing to the outer renal medullary hypoxia (Figure 1).

It has been demonstrated that the incubation of erythrocytes in plasma supplemented with the IRCA iopromide 370 induced rounded

bubble-like protrusions from their cell membrane containing almost completely long bundles of actin fibres^[64].

Two classes of IRCA, having different iodine concentrations, were examined for their effects on erythrocytes: Iodixanol (having an iodine concentration of 320 mg Iodine/mL) and Iopromide (370 mg Iodine/mL). Both IRCA provoked echinocyte formations accompanied by a reorganization of band3 and/or spectrin filaments with exocytosis of particles. The study revealed changes in shape and aggregation of erythrocytes in contact with IRCA that coincided with changes in the structure of the membrane skeleton. Iopromide induced markedly more severe alterations of the membrane skeleton compared to iodixanol^[64].

The formation of echinocytes and stomatocytes observed upon incubation of erythrocytes with IRCA may have a negative effect on the rheology of the blood^[47], thereby impairing renal perfusion with increase of outer renal medullary ischemia (Figure 1).

DIRECT TOXIC EFFECTS BY IRCA ON RENAL TUBULAR EPITHELIAL CELLS

Thus, as we have mentioned, in the pathogenesis of CI-AKI a direct toxic effects by IRCA on renal tubular epithelial cells are believed to play an important role in causing Contrast-Induced AKI (CI-AKI)^[71,72] (Figure 1).

Once filtered by the glomeruli, IRCA are concentrated in the renal tubules, as a result of water and salt reabsorption by the proximal tubules, and are able to cause direct injury to the renal tubular cells. The consequent damage has been observed in isolated tubular segments and in cultured cells substantiated by disruption of cell integrity and apoptosis, that may be aggravated by factors, such as tissue hypoperfusion and hypoxia caused by IRCA and by clinically unfavourable conditions, such as pre-existing renal impairment, particularly if associated to diabetes, salt depletion, congestive heart failure and concurrent use of nephrotoxic drugs^[47,73-78].

In vitro cell culture studies have shown that important cell signalling pathways are affected by IRCA. These pathways may determine cell fate, such as death, survival, proliferation, release of hormone, and may be triggered by mechanical, chemical, light and thermal stimuli, and it is feasible that these signaling pathways are involved in renal injury and repair following the administration of IRCA^[9].

Characterization of some of these intracellular pathways in cells exposed *in vitro* to IRCA may shed some light on the mechanisms of toxicity of the IRCA and possibly help in future development of pharmacological therapies in order to reduce the risk of CI-AKI^[79].

Kinase-mediated intracellular signalling pathways can modulate cell growth, proliferation, death and inflammation^[80-83]. By knowing these pathways it may be possible to block a cell death pathway, thereby modifying the extent of injury and preventing renal necrosis^[84].

For example, the pro-survival and pro-proliferative kinases Akt and ERK1/2 have been shown to be dephosphorylated (deactivated) whilst pro-inflammatory/cell death molecules, such as the p38 and JNK kinases and the transcription factor NF- κ B may be activated by IRCA, accompanied by activation of apoptotic mediators such as caspases^[9].

The most important and useful cells used for evaluating the nephrotoxicity of IRCA are the immortalized human proximal tubular cell line, named HK-2, which retains the phenotypic expression and functional characteristic of human proximal tubular cells, as described by others^[85-87].

CELLULAR SIGNALLING PATHWAYS AFFECTED BY IRCA

Our *in vitro* studies have demonstrated the effects of different IRCA on various signalling pathways known to play a role in cellular survival, growth and proliferation. The incubation of human renal proximal tubular epithelial cells (HK-2 cells) with IRCA (diatrizoate, iopromide or iomeprol), in fact, caused a dramatic dephosphorylation (deactivation) of Akt, a kinase known to play a role in cell survival^[81]. This was accompanied by effects on downstream targets of Akt, such as p70S6 kinase (inactivated) which is involved in protein synthesis and the FOXO (Forkhead) family of transcription factors (dephosphorylated and hence activated)^[88]. Both diatrizoate and iopromide caused a decrease in HK-2 cell viability, as determined by the chemical reduction of MTT [3-(4,5-Dimethyl-2-thiazolyl)-2,5-diphenyl-2H-tetrazolium bromide^[89]], which was partially alleviated by the transfection with plasmids encoding the constitutively-active Akt^[88]. Transfection of HK-2 cells with plasmids encoding the constitutively active form of Akt only partially recovered cell viability. Diatrizoate also caused a dephosphorylation of mTOR and ERK1/2, kinases known to play an important role in cell proliferation and survival^[90], which was greater with respect to iopromide, iomeprol or iodixanol^[79,88]. Western blot analysis of whole lysates prepared from kidneys removed from rats treated with the IRCA iomeprol and the IRCA iodixanol also showed lowered levels of phospho-Akt and phospho-ERK1/2 compared with lysates obtained from control non-treated rats^[79].

We have also demonstrated in HK-2 cells that the high osmolar diatrizoate also caused a greater activation of the c-Jun N-terminal and p38 mitogen activated protein kinases (JNKs and p38 MAPKs respectively) together with a corresponding increase in the pro-inflammatory cytokine IL-8^[91-93] compared with low osmolar iomeprol at the same concentration of iodine^[94].

Incubation of HK-2 cells with high osmolar diatrizoate, low osmolar iomeprol or iso osmolar iodixanol at concentrations of 75 and 100 mg Iodine/mL for up to 3 h did not result in caspase-3 cleavage^[79]. However, in HK-2 cells that had been previously exposed to diatrizoate for 2-3 h and then incubated for a further 22 h (after removal of the IRCA), evidence for caspase-3 cleavage was observed^[79,94].

Since the use of large doses of IRCA represent risk for CI-AKI that is dose-dependent, these studies were carried out using IRCA doses of 75 mg Iodine/mL, based on the dosage commonly used in clinical practice of 1.5-2.5 mg Iodine/kg b.w., leading to plasma concentrations of 15-20 mg Iodine/ml. Since, in the kidney, 70-80% of the ultrafiltrate is re-absorbed in the proximal convoluted tubule, the IRCA concentration will therefore range between 75-100 mg/mL^[74,79].

DIFFERENCE BETWEEN LOW OSMOLAR IOMEPROL AND ISO OSMOLAR IODIXANOL

We have also studied the different effects of the IRCA iomeprol, iodixanol and sodium diatrizoate on renal cell cultures. Our cell viability studies indicate that iodixanol is toxic to HK-2 cells, but less so than iomeprol. Iomeprol, in fact, caused a greater decrease in phospho-Akt (at Ser 473) than iodixanol and this was dependent on the concentration of the IRCA which have been used.

As mentioned above, cell viability was measured by the ability of viable cells to reduce MTT^[89]. HK-2 cells were grown to a confluence

of approximately 90%, and incubated for 18-20 hours in serum-free medium prior to experimentation. For experiments, cells were incubated for 2 hours with the IRCA; then the IRCA was removed by replacing the culture medium with fresh serum-free medium. Whilst both IRCA caused a significant decrease in cell survival with respect to control (non-treated) cells ($p < 0.001$), diatrizoate (32% decrease in cell viability) had a significantly greater effect than iomeprol (20% decrease in cell viability) ($p < 0.001$).

Thus, we have demonstrated with diatrizoate a significantly greater phosphorylation (i.e. activation), of signalling molecules that are known to be involved in cell death, namely the JNK and p38 MAP kinases subfamilies^[82,95,96] than with iomeprol^[94]. Furthermore, the viability of these cells have been assessed after removal of the IRCA stress for up to 22 h, meanwhile determining which signalling molecules, involved in cell death/survival, are activated/deactivated. Considering the proposed role of these molecules in cell death and apoptosis^[82,95,96], the activation of these molecules by IRCA may have also contributed to the decrease in cell viability.

Other studies have also supported our findings in suggesting that the JNK and p38 MAP kinases may be involved in IRCA-induced apoptosis in HEK293T cells and in LLC-PK1 cells respectively^[97,98].

In conclusion, *in vitro* cell culture studies have demonstrated that IRCA cause several and significant changes in a variety of cell signalling molecules that play important roles in cellular homeostasis, including the deactivation of molecules such as Akt and ERK1/2 that enable cells to survive stress and to proliferate as well as to regulate the synthesis of vasoactive molecules. Furthermore, other molecular species are increased or activated: that may be detrimental; reactive oxygen species and signalling molecules such as the p38 and JNK kinases and transcription factors such as NF- κ B that may mediate cell death and inflammation^[9].

FACTORS FAVOURING TOXIC EFFECTS BY IRCA ON RENAL TUBULAR EPITHELIAL CELLS

Salt depletion (frequently indicated with the term 'dehydration') will favour the toxic effects of IRCA through several mechanisms:

(a) by increasing the direct toxic action of IRCA on renal tubular epithelial cells; salt depletion causes proximal tubular over-reabsorption that will make IRCA more concentrated within the tubular lumen meanwhile reducing the flow rate of tubular fluid, consequently increasing the contact time between IRCA and tubular epithelial cells. Thus, salt depletion will increase the toxic effect of IRCA on renal tubular epithelial cells.

(b) by increasing the renal vasoconstriction with reduction of RBF. Such vasoconstriction is particularly important in the outer renal medulla because of its peculiar anatomical reasons. The outer renal medulla, in fact, even under normal physiological conditions, receives a little amount of blood because of its distance from the descending *vasa recta*. This hypoperfusion leads to little local oxygen (O_2) delivery despite the high local O_2 consumption due to the important active tubular reabsorption in S3 segments of proximal renal tubules and in the medullary thick ascending limb of the Henle's loops that are located there. Salt depletion and the consequent vasoconstriction will aggravate the discrepancy between low O_2 delivery and the O_2 requirement. Thus, the outer renal medullary hypoxia, a crucial point in the pathogenesis of CI-AKI (Figure 1), is made worse by salt depletion^[99].

Obviously, vasoconstrictive agents, such as adenosine and endothelins, by increasing vasoconstriction, particularly in the outer renal medulla, will aggravate outer renal medullary

hypoxia. The renal vasculature in patients with diabetes mellitus has a higher sensitivity to adenosine, a vasoconstrictive agent. Since IRCA increase the release of renal adenosine, and stimulate renal adenosine receptors, this may in part explain the particular susceptibility of diabetic patients to IRCA^[14,100]. The administration of IRCA to diabetics acutely reduces renal parenchymal oxygenation through the increased production of vasoconstrictive endothelins, a reduction that is most prominent in the renal medulla, since it already functions at low oxygen tension^[101]. Since diabetics already have increased circulating and renal endothelin levels, this also may in part explain the particular susceptibility of diabetic patients to IRCA^[14].

Outer renal medullary hypoxia leads to the formation of reactive oxygen species (ROS)^[42,43] that may exert direct tubular and vascular endothelial injury and might further intensify renal parenchymal hypoxia by virtue of endothelial dysfunction and dysregulation of tubular transport^[45,46] (Figure 1).

The decrease in Nitric Oxide (NO) may be due to its reaction with ROS, in particular with superoxide anions (O_2^-)^[47,48]. This reaction may lead to the formation of the more powerful oxidant peroxynitrite anion (ONOO⁻)^[49] that may be more detrimental to the endothelial cells. Hence, the reaction of the ROS with NO not only causes a reduction in the levels of the vasodilator NO, but also leads to the formation of a potent oxidant that exacerbates cell injury^[102] (Figure 1).

Patients with chronic renal failure (CRF) have defective antioxidant systems^[103] and increased oxidative stress associated with inflammation and endothelial dysfunction^[104]. This may explain why pre-existing renal failure represents the most common condition predisposing to the development of CI-AKI^[39].

Concomitant use of potentially nephrotoxic drugs, such as aminoglycosides, vancomycin, amphotericin B, dipyridamole, metformin and nonsteroidal anti-inflammatory drugs will potentiate the toxicity of IRCA on epithelial cells^[40,105].

Undoubtedly, the toxicity is different for different IRCA. Thus, at equal iodine concentrations (e.g. 300 mg Iodine/mL) high osmolar IRCA have greater cytotoxic effects on proximal tubular cells *in vitro* than do low or iso osmolar IRCA^[73]. IRCA cytotoxicity has been suggested to be due, at least in part, to the free iodine present in solutions of IRCA and that leads to apoptosis and cell death of both endothelial and tubular cells^[47]. It is important to choose the least nephrotoxic radiocontrast agent: the iso-osmolar iodixanol and the low-osmolar iopamidol appear, in fact, to be the IRCA of first choice to reduce the risk of CI-AKI^[106] and to use them with the lowest dosage possible.

INTRACELLULAR Ca^{2+} OVERLOAD INDUCED BY IRCA

Under physiological conditions, the Na^+/Ca^{2+} exchanger (NCX) can pump the Ca^{2+} outside the renal tubular epithelial cells using the Na^+ concentration gradient across the cell membrane to keep a low intracellular Ca^{2+} level. After IRCA injection, NCX may reversely extrude Na^+ for Ca^{2+} influx and result in intracellular Ca^{2+} overload that is considered to be an important factor in the pathogenesis of CI-AKI^[107,108] (Figure 1). The increase in intracellular calcium, in fact, provokes a vasoconstrictive response in intrarenal circulation and would be an important mediator of epithelial cell apoptosis and necrosis. On this basis, Calcium Channel Blockers have been hypothesized to have protective effects against CI-AKI. But their use has given controversial results, sometimes protective and sometimes with no benefit at all^[105].

PROTECTION OF EPITHELIAL TUBULAR CELLS AGAINST IRCA TOXICITY BY ASIALOERYTHROPOIETIN

Erythropoietin (EPO), the cytokine widely used for the treatment of anemia in patients with CRF, has been found to interact with its receptors, expressed in a great variety of nonhematopoietic cell types: neurons, endothelial cells, vascular smooth muscle cells, cardiomyocytes, mesangial cells, renal proximal tubular cells. On these cells EPO induces a cytoprotective cellular response: mitogenesis, angiogenesis, promotion of vascular repair and inhibition of apoptosis, independent of EPO's effects on erythropoiesis^[109]. Thus, EPO has been demonstrated to protect the kidney in experimental animals against the injury and dysfunction caused by ischemia-reperfusion^[110,111] and to enhance recovery after cisplatin-induced acute renal failure in the rat^[112]. But it has also been able to attenuate IRCA-induced ARF in rats^[113]. Desialylated EPO (asialoEPO), is an EPO derivative that has EPO receptor-binding affinity similar to native EPO; it has been reported to retain neuroprotective activities. It has been hypothesized that asialoEPO could also attenuate renal injury in experimental ARF. Thus, both EPO and a nonhematopoietic EPO derivative, asialoEPO, have been recently demonstrated to prevent the development of renal dysfunction as assessed by biochemical parameters in a rat model of CI-AKI. It has also been demonstrated that either EPO or asialoEPO markedly suppressed renal tubular injuries as assessed by histologic examination when administered as a single intravenous bolus injection 1 h before the injection of contrast medium. In conclusion, both can directly prevent the contrast medium-induced apoptosis of renal tubular cells observed both *in vivo* and *in vitro*^[109].

PROTECTION OF EPITHELIAL TUBULAR CELLS AGAINST IRCA TOXICITY BY HUMAN SERUM ALBUMIN-THIOREDOXIN (HSA-TRX)

Thioredoxin-1 (Trx) is a ubiquitous low-molecular-weight protein, produced in the human body in response to oxidative stress conditions, with protective effect against oxidative stress being ROS scavenger. A human serum albumin-thioredoxin fusion protein (HSA-Trx) has recently been obtained with a half-life 10 times longer than that of thioredoxin. *In vivo* (in rats) and *in vitro* (on human proximal tubular cells) studies have demonstrated its ROS scavenging activity. HSA-Trx prevented CI-AKI and renal tubular apoptosis, via its extended antioxidative action, in a rat model of ioversol-induced CI-AKI^[112,114].

THE PROTECTIVE EFFECTS OF EXTRACELLULAR VOLUME EXPANSION

Consistent with the increasing effect of salt depletion on toxicity by IRCA, the extracellular volume expansion has a protective effect. The expansion of intravascular volume, in fact, will suppress renin-angiotensin cascade and consequently will reduce renal vasoconstriction and hypoperfusion. Furthermore, the resulting increase in urine output, because of reduction of proximal tubular reabsorption (caused by volume expansion), will limit the duration of IRCA contact with renal tubules and consequently their toxicity on tubular epithelium^[99,115,116]. In clinical practice adequate protection is obtained with i.v. infusion of 0.9% saline at a rate of approximately

1 mL/kg b.w. per hour, beginning 6-12 hours before and continuing for up to 12-24 hours after the radiographic examination (if urine output is appropriate and cardiovascular conditions allow it)^[20,117]. Some Authors suggest using sodium bicarbonate hydration that has been shown to be superior to sodium chloride in some clinical studies and meta-analysis^[118-128]. It is believed that the use of bicarbonate causes the alkalization of tubular fluid leading to a reduction in the production and the neutralization of oxygen free radicals, thereby protecting the kidney from injury^[121,122,129,130]. For coronary angiography or intervention, 154-mEq/L infusion of sodium bicarbonate as a bolus of 3 mL/kg b.w./hour for 1 hour before the administration of IRCA, followed by 1 mL/kg/hour for 6 hours during and after the procedure, have been used^[119]. Unfortunately, other studies have not found any benefit with sodium bicarbonate hydration versus sodium chloride^[131-134] or have even observed an increased incidence of CI-AKI^[135].

PROTECTION OF TUBULAR DAMAGE BY STEROIDS

In the last few years, several studies investigated the significance and clinical utility of new biomarkers of kidney damage. In addition to biomarkers representing changes in renal function (e.g., serum creatinine or cystatin C), those biomarkers reflecting kidney damage also seem to be important: kidney injury molecule-1 (KIM-1), neutrophil gelatinase-associated lipocalin (NGAL). These may be present even when renal function has not been impaired as yet, thereby identifying a new category of patients, those with "subclinical AKI". KIM-1 is a transmembrane protein not expressed in normal kidney but upregulated in dedifferentiated proximal tubule cells after ischemic or nephrotoxic AKI. KIM-1 was elevated in patients with ischemic acute tubular necrosis, but increased urinary levels of KIM-1 have been reported also in patients with CI-AKI^[136]. The biomarker most investigated in CI-AKI is NGAL. NGAL is a ubiquitous 25 KDa protein, covalently bound to gelatinase from human neutrophils, and is a marker of renal tubular injury. Serum NGAL (sNGAL) and/or urine NGAL (uNGAL) levels have been shown to predict AKI in ischemic kidney injury, including CI-AKI^[136].

It has been suggested that oral prednisone given concurrently with i.v. saline may protect renal tubules against the toxicity of IRCA^[137]. This is based on the fact that steroids may have a favourable impact on inflammation and renal tubular cell apoptosis and necrosis, as observed in models of renal ischemia-reperfusion in which dexamethasone had a protective effect against injury. In rats with renal ischemia-reperfusion injury, a single dose of dexamethasone administered before ischemia, or at the onset of reperfusion, in fact, ameliorated biochemical and histologic acute kidney injury after 24 h: it reduced apoptosis and necrosis of proximal renal tubular cells^[138].

Thus, patients at risk of CI-AKI undergoing cardiovascular procedures, using either the iso-osmolar iodixanol or the low-osmolar iohexol have been treated either with prednisone + hydration or hydration alone. Oral prednisone 1 mg/kg was administered 12 hours before, at 6 am on the same day, and 24 hours following the procedure. Serum creatinine was tested immediately before and again 24-48 hours after the procedure; neutrophil gelatinase-associated lipocalin (NGAL), kidney injury molecule-1 (KIM-1), protein and albumin were assayed in spot urine before and 6 hours after the procedure. In the absence of AKI, NGAL and KIM-1 tended to rise after the procedure, but to a lesser degree in the patients treated with prednisone (delta NGAL: hydration = +128%, prednisone = +46%; $p = 0.26$; delta KIM-1: hydration = +99%, prednisone = +11%; $p = 0.02$)

^[137]. These findings suggest that tubular damage was attenuated in the steroid-treated patients.

PROTECTIVE EFFECTS OF TRIMETAZIDIN

Trimetazidine is a drug used in clinical practice for treating angina pectoris, sold under the brand name Vastarel. It is a cytoprotective anti-ischemic agent that increases cell tolerance to ischaemia by maintaining cellular homeostasis^[139]. Experimental studies demonstrated that trimetazidine prevents the deleterious effects of ischaemia-reperfusion at the mitochondrial levels in a dose-dependent manner. This protective effect appears to be the key factor through which this drug exerts its cytoprotective activity^[140]. It has been demonstrated that trimetazidine exerts also a potent antioxidant activity on various tissue preparations, protecting the epithelium from the deleterious effect of oxygen radicals^[141].

Onbasili *et al.*^[142] studied the efficacy of trimetazidine in the prevention of CI-AKI in 82 patients with high SCr undergoing coronary angiography/angioplasty. The drug was given orally, 20 mg thrice daily, for 72 hours starting 48 hours before the procedure; all patients were given i.v. isotonic saline (1 mL/kg). CI-AKI developed in only one of 40 patients who were given trimetazidine (2.5%) and in seven of 42 controls (17%).

More recently Rahman *et al.*^[143] have conducted a prospective randomized, controlled trial to evaluate the efficacy of trimetazidine in the prevention of CI-AKI in 400 patients with raised SCr undergoing coronary angiography: 200 patients were treated with Trimetazidine plus normal saline and 200 patients (control) were given only normal saline. It was found that the incidence of CI-AKI was significantly ($p < 0.05$) reduced by trimetazidine administration with saline in comparison with saline alone: 4% vs 14%.

Trimetazidine inhibits the excessive release of oxygen-free radicals, increases glucose metabolism, limits intracellular acidosis, protects ATP stores, reduces membrane lipid peroxidation and inhibits neutrophil infiltration after ischaemia-reperfusion^[142].

The effectiveness of trimetazidin for the prevention of CI-AKI has been histopathologically demonstrated in rats^[144]. The histopathological shape of kidney tissues were similar in rats treated with IRCA plus trimetazidin and in rats not treated with IRCA.

MEASURES TO DECREASE THE OUTER RENAL MEDULLARY HYPOXIA

The osmotic diuresis induced by IRCA causes an increased delivery of tubular fluid to the thick ascending limb of Henle's loops, thereby increasing the local active sodium reabsorption and consequently O₂ demand, thereby aggravating outer renal medullary hypoxia (Figure 1). Thus, it has been thought that furosemide, by decreasing sodium reabsorption in this tubular segment^[145,146], would reduce medullary O₂ consumption and decrease renal medullary hypoxia. Unfortunately, several studies have demonstrated no protection against CI-AKI when utilizing furosemide or even deleterious effects^[147-149], mainly related to the salt depletion caused by diuretics. To overcome the problem of hypovolemia caused by the diuretic, a perfect combination of hydration plus furosemide has been suggested, by delivering i.v. fluid in an amount exactly matched to the volume of urine produced by the patient under the effect of furosemide^[150,151]. This procedure is accomplished by a special device, called 'RenalGuard', that would guide the physician in achieving high urine output while simultaneously balancing urine output and venous fluid infusion to prevent hypovolemia^[99].

MEASURES TO PREVENT IRCA NEPHROTOXICITY BY ANTIOXIDANTS

Since ROS have been proven to play an important role in the renal damage caused by IRCA, it has been thought that antioxidants would prevent CI-AKI^[105].

The mostly widely used antioxidant is N-acetylcysteine that may act either as a free-radical scavenger or as a reactive sulfhydryl compound as well as a factor able to increase the vasodilating effect of NO^[152]. Despite controversial results reported in the literature^[105], it has been suggested to use N-acetylcysteine in high-risk patients either with an oral dose of 600 mg twice daily the day before and the day of procedure^[20] or, in patients unable to take the drug orally, with an IV dose of 150 mg/kg over half an hour before the procedure or 50 mg/kg administered over 4 hours^[153].

Conflicting results have been obtained with the use of the antioxidant ascorbic acid at a dosage of 3 g orally 2 hours before the procedure and 2 g during the night and in the morning after the procedure^[154-158].

The oral administration of either 350 mg/day of α -tocopherol or 300 mg/day of γ -tocopherol (5 days prior to the coronary procedure and continued for a further 2 days post-procedure) in combination with 0.9% saline has been demonstrated to be effective in protecting against CI-AKI in patients with chronic kidney disease undergoing coronary procedures with low-osmolar iopromide^[159,160].

Mesna (mercapto-ethane-sulfonate Na) is an agent with antioxidant properties that has been shown to reduce free radicals and restore reduced glutathione levels after ischemic renal failure^[161]. The i.v. administration of 1,600 mg Mesna versus placebo, together with i.v. hydration with 0.9% saline, resulted in the occurrence of CI-AKI in 7 patients in the placebo group and none in the Mesna group^[162].

Nebivolol, a third-generation β 1-adrenergic receptor antagonist, seems to have a protective effect on the kidney against CI-AKI through its antioxidant and NO-mediated vasodilating action^[163]. At a dosage of 5 mg/day for one week or 5 mg every 24 hours for 4 days it decreased the incidence of CI-AKI in patients with renal dysfunction undergoing coronary angiography^[105,164,165].

Recent studies have shown a beneficial effect of statins to prevent CI-AKI in patients undergoing percutaneous coronary intervention^[105,166,167]. When patients undergoing percutaneous coronary intervention have been given pre-treatment with atorvastatin, 80 mg 12 hours before intervention with another 40 mg pre-procedure, followed by long-term treatment of 40 mg/day, CI-AKI was prevented^[168].

REVERSAL OF IRCA TOXICITY ON HUMAN RENAL PROXIMAL TUBULAR CELLS BY WHITE GRAPE JUICE EXTRACT

In vivo studies using rats fed with grape seed proanthocyanidin extract^[169] have been found to be protective against renal tissue damage due to IRCA. Since grape juice is a rich source of antioxidants and has been shown to increase serum antioxidant capacity in adults^[170] and since it has also been demonstrated that Concord grape juice may activate Akt/PKB kinase by increasing its phosphorylation at Ser 473^[171], it seemed feasible that grape juice may afford protection against the toxic effects of IRCA. Recent work from our laboratory investigated the action of a white grape juice extract (WGJe) on culture human renal proximal tubule cells

(HK-2) treated with the high-osmolar IRCA sodium diatrizoate, to evaluate any changes in the signaling pathways in these cells^[172]. WGJe caused an increase in phosphorylation of the pro-survival kinases Akt and ERK1/2 in HK-2 cells. Treatment of HK-2 cells with 75 mg Iodine/ml sodium diatrizoate for 2.5 h and then further incubation (for 27.5 h) after removal of the IRCA caused a drastic decrease in cell viability. However, pre-treatment with WGJe, prior to incubation with diatrizoate, dramatically improved cell viability. Analysis of key signalling molecules by Western blotting showed that diatrizoate caused a drastic decrease in phosphorylation of Akt (at Ser473), FoxO1 (at Thr24) and FoxO3a (at Thr32) during the initial 2.5 h incubation period, and WGJe pre-treatment caused a reversal of these effects. Further analysis by Western blotting of samples from HK-2 cells cultured for longer periods of time (for up to 27.5h after an initial 2.5h exposure to diatrizoate with or without WGJe pre-treatment) showed that WGJe pre-treatment caused a negative effect on phosphorylation of p38, NF- κ B (at Ser276) and ERK1/2 whilst having a positive effect on the phosphorylation of Akt, FoxO1/ FoxO3a and maintained levels of Pim-1 kinase^[172].

ACKNOWLEDGEMENTS

Dr. Ashour Michael is currently recipient of a Research Check from “Magna Graecia” University of Catanzaro, Italy. Authors’ contributions: M.A. and A.M. wrote most of the paper; T.F. wrote the abstract, took the decisions about tables/figure to insert, wrote the paper’s part related to the prevention and performed the literature search.

CONFLICT OF INTERESTS

The Authors have no conflicts of interest to declare.

REFERENCES

- 1 Katzberg RW. Contrast medium-induced nephrotoxicity: which pathway? *Radiology* 2005; 235: 752-5
- 2 Persson PB, Hansell P, Liss P. Pathophysiology of contrast medium-induced nephropathy. *Kidney international* 2005; 68: 14-22
- 3 Solomon R. The role of osmolality in the incidence of contrast-induced nephropathy: a systematic review of angiographic contrast media in high risk patients. *Kidney international* 2005; 68: 2256-63
- 4 Deray G, Martinez F, Cacoub P, Baumelou B, Baumelou A, Jacobs C. A role for adenosine calcium and ischemia in radiocontrast-induced intrarenal vasoconstriction. *American journal of nephrology* 1990; 10: 316-22.
- 5 Solomon R. Contrast-induced acute kidney injury: is there a risk after intravenous contrast? *Clin J Am Soc Nephrol* 2008;3:1242-3.
- 6 Andreucci M, Faga T, Pisani A, Sabbatini M, Michael A. Acute Kidney Injury by Radiographic Contrast Media: Pathogenesis and Prevention. *BioMed Research Int* 2014, 2014, Article ID 362725, 21 pages <http://dx.doi.org/10.1155/2014/362725>.
- 7 Fuiano G, Mancuso D, Indolfi C, Mongiardo A, Sabbatini M, Conte G, De Nicola L, Minutolo R, Mazza G, Cianfrone P, Andreucci M. Early detection of progressive renal dysfunction in patients with coronary artery disease. *Kidney international* 2005; 68: 2773-80.
- 8 Katzberg RW. Urography into the 21st century: new contrast media, renal handling, imaging characteristics, and nephrotoxicity. *Radiology* 1997; 204: 297-312.
- 9 Michael A, Faga T, Pisani A, Riccio E, Bramanti P, Sabbatini M, Navarra M, Andreucci M. Molecular mechanisms of renal cellular nephrotoxicity due to radiocontrast media. *BioMed research inter-*

- national 2014; 2014: 249810.
10. Morcos SK. Contrast-induced nephropathy: are there differences between low osmolar and iso-osmolar iodinated contrast media? *Clinical radiology* 2009; 64: 468-72.
11. Andreucci M. Side effects of radiographic contrast media. *BioMed research international* 2014; 2014: 872574.
12. Andreucci M, Solomon R, Tasanarong A. Side Effects of Radiographic Contrast Media: Pathogenesis, Risk Factors, and Prevention. *BioMed research international* 2014; 2014: 741018.
13. Andreucci M. [Radiographic contrast nephropathy]. *G Ital Nefrol* 2014, 31(5).
14. Andreucci M, Faga T, De Sarro GB, Michael A. The toxicity of Radiographic Contrast Agents in the Clinical Practice. *J Nephrol Advances* 2015; in press.
15. Andreucci M. [Contrast media and nephrotoxicity: a molecular conundrum]. *G Ital Nefrol* 2011, 28(4): 355.
16. Group KDIGOKAKIW. KDIGO Clinical Practice Guideline for Acute Kidney Injury. *Kidney international* 2012; 2: 1-138.
17. Taliercio CP, Vlietstra RE, Fisher LD, Burnett JC. Risks for renal dysfunction with cardiac angiography. *Annals of internal medicine* 1986; 104: 501-4.
18. McCullough P. Outcomes of contrast-induced nephropathy: experience in patients undergoing cardiovascular intervention. *Catheter Cardiovasc Interv* 2006; 67: 335-43.
19. Cochran ST, Wong WS, Roe DJ. Predicting angiography-induced acute renal function impairment: clinical risk model. *AJR American journal of roentgenology* 1983; 141: 1027-33.
20. Gleeson TG, Bulugahapitiya S. Contrast-induced nephropathy. *AJR American journal of roentgenology* 2004; 183: 1673-89.
21. Delanaye P, Cavalier E, Cristol JP, Delanghe JR. Calibration and precision of serum creatinine and plasma cystatin C measurement: impact on the estimation of glomerular filtration rate. *Journal of nephrology* 2014.
22. Seronie-Vivien S, Delanaye P, Pieroni L, Mariat C, Froissart M, Cristol JP, Sfbc Biology of renal function renal failure working group. Cystatin C: current position and future prospects. *Clinical chemistry and laboratory medicine: CCLM / FESCC* 2008; 46: 1664-86.
23. Inker LA, Schmid CH, Tighiouart H, Eckfeldt JH, Feldman HI, Greene T, Kusek JW, Manzi J, Van Lente F, Zhang YL, Coresh J, Levey AS, Ckd-Epi Investigators. Estimating glomerular filtration rate from serum creatinine and cystatin C. *The New England journal of medicine* 2012; 367: 20-9.
24. Masson I, Maillard N, Tack I, Thibaudin L, Dubourg L, Delanaye P, Cavalier E, Bonneau C, Kamar N, Morelon E, Moranne O, Alalmartine E, Mariat C. GFR estimation using standardized cystatin C in kidney transplant recipients. *American journal of kidney diseases* 2013; 61: 279-84.
25. Mindikoglu AL, Dowling TC, Weir MR, Seliger SL, Christenson RH, Magder LS. Performance of chronic kidney disease epidemiology collaboration creatinine-cystatin C equation for estimating kidney function in cirrhosis. *Hepatology* 2014; 59: 1532-42.
26. Obiols J, Bargnoux AS, Kuster N, Fesler P, Pieroni L, Badiou S, Dupuy AM, Ribstein J, Cristol JP. Validation of a new standardized cystatin C turbidimetric assay: evaluation of the three novel CKD-EPI equations in hypertensive patients. *Clinical biochemistry* 2013; 46: 1542-7.
27. Fan L, Inker LA, Rossert J, Froissart M, Rossing P, Mauer M, Levey AS. Glomerular filtration rate estimation using cystatin C alone or combined with creatinine as a confirmatory test. *Nephrology, dialysis, transplantation* 2014; 29: 1195-203.
28. KDIGO 2012 Clinical Practice Guideline for the Evaluation and Management of Chronic Kidney Disease. *Kidney Int volume 3 Supplement issue 1, January 2013*
29. Eriksen BO, Mathisen UD, Melsom T, Ingebretsen OC, Jenssen TG, Njolstad I, Solbu MD, Toft I. Cystatin C is not a better estimator of GFR than plasma creatinine in the general population.

- Kidney international 2010; 78: 1305-11.
30. Ribichini F, Gambaro G, Graziani MS, Pighi M, Pesarini G, Pasoli P, Anselmi M, Ferrero V, Yabarek T, Sorio A, Rizzotti P, Lupo A, Vassanelli C. Comparison of serum creatinine and cystatin C for early diagnosis of contrast-induced nephropathy after coronary angiography and interventions. *Clinical chemistry* 2012; 58: 458-64.
 31. Kuhn MJ, Chen N, Sahani DV, Reimer D, van Beek EJ, Heiken JP, So GJ. The PREDICT study: a randomized double-blind comparison of contrast-induced nephropathy after low- or isoosmolar contrast agent exposure. *AJR American journal of roentgenology* 2008; 191: 151-7.
 32. Byrd L, Sherman RL. Radiocontrast-induced acute renal failure: a clinical and pathophysiologic review. *Medicine (Baltimore)* 1979; 58: 270-9.
 33. Harkonen S, Kjellstrand C. Contrast nephropathy. *American journal of nephrology* 1981; 1: 69-77.
 34. Andreucci VE, Fuiano G, Russo D, Andreucci M. Vasomotor nephropathy in the elderly. *Nephrology, dialysis, transplantation* 1998; 13 Suppl 7: 17-24.
 35. Andreucci VE, Fuiano G, Stanziale P, Andreucci M. Role of renal biopsy in the diagnosis and prognosis of acute renal failure. *Kidney international Supplement* 1998; 66: S91-5.
 36. Andreucci VE, Russo D, Cianciaruso B, Andreucci M. Some sodium, potassium and water changes in the elderly and their treatment. *Nephrology, dialysis, transplantation* 1996; 11 Suppl 9: 9-17.
 37. Andreucci M, Federico S, Andreucci VE. Edema and acute renal failure. *Seminars in nephrology* 2001; 21: 251-6.
 38. Katzberg RW, Barrett BJ. Risk of iodinated contrast material-induced nephropathy with intravenous administration. *Radiology* 2007; 243: 622-8.
 39. Andreucci M, Faga T, Pisani A, Sabbatini M, Michael A. Pathogenesis of Acute Renal Failure induced by iodinated radiographic contrast media. *Austin J Nephrol Hypertens* 2014; 1(1): 1005.
 40. Andreucci M, Faga T, Pisani A, Sabbatini M, Russo D, Michael A. Prevention of Contrast-Induced Nephropathy through a knowledge of its pathogenesis and risk factors. *Scientific World Journal* 2014; 823169, 16 pages, <http://dx.doi.org/10.1155/2014/823169>
 41. Sabbatini M, Uccello F, Serio V, Troncone G, Varone V, Andreucci M, Faga T, Pisani A. Effects of mycophenolate mofetil on acute ischaemia-reperfusion injury in rats and its consequences in the long term. *Nephrol Dial Transplant.* 2010 May; 25(5): 1443-50
 42. Giaccia AJ, Simon MC, Johnson R. The biology of hypoxia: the role of oxygen sensing in development, normal function, and disease. *Genes Dev* 2004; 18: 2183-94.
 43. Sabbatini M, Santillo M, Pisani A, Paterno R, Uccello F, Seru R, Matrone G, Spagnuolo G, Andreucci M, Serio V, Esposito P, Cianciaruso B, Fuiano G, Avvedimento EV. Inhibition of Ras/ERK1/2 signaling protects against postischemic renal injury. *American journal of physiology Renal physiology* 2006; 290(6): F1408-15.
 44. Pisani A, Sabbatini M, Riccio E, Rossano R, Andreucci M, Capasso C, De Luca V, Carginale V, Bizzarri M, Borrelli A, Schiattarella A, Santangelo M, Mancini A. Effect of a recombinant manganese superoxide dismutase on prevention of contrast-induced acute kidney injury. *Clinical and experimental nephrology* 2014; 18:424-31.
 45. Heyman SN, Rosen S, Khamaisi M, Idee JM, Rosenberger C. Reactive oxygen species and the pathogenesis of radiocontrast-induced nephropathy. *Investigative radiology* 2010; 45: 188-95.
 46. Dawson P, Becker A, Holton JM. The effect of contrast media on the growth of bacteria. *The British journal of radiology* 1983; 56: 809-15.
 47. Sendeski MM. Pathophysiology of renal tissue damage by iodinated contrast media. *Clinical and experimental pharmacology & physiology* 2011; 38: 292-9.
 48. Pisani A, Riccio E, Andreucci M, Faga T, Ashour M, Di Nuzzi A, Mancini A, Sabbatini M. Role of reactive oxygen species in pathogenesis of radiocontrast-induced nephropathy. *BioMed research international* 2013; 2013: 868321.
 49. Pacher P, Beckman JS, Liaudet L. Nitric oxide and peroxynitrite in health and disease. *Physiological reviews* 2007; 87: 315-424.
 50. Franke RP, Fuhrmann R, Hiebl B, Jung F. Influence of radiographic contrast media (iodixanol und iomeprol) on the morphology of human arterial and venous endothelial cells on extracellular matrix *in vitro*. *Clinical hemorheology and microcirculation* 2011; 48: 41-56.
 51. Franke RP, Fuhrmann R, Park JW, Rickert D, Hiebl B, Jung F. The effect of radiographic contrast media on the morphology of human venous endothelial cells. *Clinical hemorheology and microcirculation* 2007; 37: 329-38.
 52. Ramponi S, Grotti A, Morisetti A, Vultaggio S, Lorusso V. Effects of iodinated contrast media on endothelium: An *in vitro* study. *Toxicology in vitro: an international journal published in association with BIBRA* 2007; 21: 191-6.
 53. Sumimura T, Sendo T, Itoh Y, Oka M, Oike M, Ito Y, Oishi R. Calcium-dependent injury of human microvascular endothelial cells induced by a variety of iodinated radiographic contrast media. *Investigative radiology* 2003; 38: 366-74.
 54. Gospos C, Freudenberg N, Staubesand J, Mathias K, Papacharlampos X. The effect of contrast media on the aortic endothelium of rats. *Radiology* 1983; 147: 685-8.
 55. Heyman SN, Clark BA, Kaiser N, Spokes K, Rosen S, Brezis M, Epstein FH. Radiocontrast agents induce endothelin release *in vivo* and *in vitro*. *Journal of the American Society of Nephrology: JASN* 1992; 3: 58-65.
 56. Reinhart WH, Pleisch B, Harris LG, Lutolf M. Influence of contrast media (iopromide, ioxaglate, gadolinium-DOTA) on blood viscosity, erythrocyte morphology and platelet function. *Clinical hemorheology and microcirculation* 2005; 32: 227-39.
 57. Aspelin P. Effect of ionic and non-ionic contrast media on red cell deformability *in vitro*. *Acta radiologica: diagnosis* 1979; 20:1-12.
 58. Aspelin P, Nilsson PE, Schmid-Schonbein H, Schroder S, Simon R. Effect of four non-ionic contrast media on red blood cells *in vitro*. III. Deformability. *Acta radiologica Supplementum* 1987; 370: 89-91.
 59. Hardeman MR, Goedhart P, Koen IY. The effect of low-osmolar ionic and nonionic contrast media on human blood viscosity, erythrocyte morphology, and aggregation behavior. *Investigative radiology* 1991; 26: 810-9.
 60. Jung F, Mrowietz C, Rickert D, Hiebl B, Park JW, Franke RP. The effect of radiographic contrast media on the morphology of human erythrocytes. *Clinical hemorheology and microcirculation* 2008; 38: 1-11.
 61. Kerl JM, Nguyen SA, Lazarchick J, Powell JW, Oswald MW, Alvi F, Costello P, Vogl TJ, Schoepf UJ. Iodinated contrast media: effect of osmolarity and injection temperature on erythrocyte morphology *in vitro*. *Acta radiologica* 2008; 49: 337-43.
 62. Losco P, Nash G, Stone P, Ventre J. Comparison of the effects of radiographic contrast media on dehydration and filterability of red blood cells from donors homozygous for hemoglobin A or hemoglobin S. *American journal of hematology* 2001; 68: 149-58.
 63. Strickland NH, Rampling MW, Dawson P, Martin G. Contrast media-induced effects on blood rheology and their importance in angiography. *Clinical radiology* 1992; 45: 240-2.
 64. Franke RP, Scharnweber T, Fuhrmann R, Mrowietz C, Jung F. Effect of radiographic contrast media (Iodixanol, Iopromide) on the spectrin/actin-network of the membranous cytoskeleton of erythrocytes. *Clinical hemorheology and microcirculation* 2013; 54: 273-85.
 65. Bennett V, Baines AJ. Spectrin and ankyrin-based pathways: metazoan inventions for integrating cells into tissues. *Physiological reviews* 2001; 81: 1353-92.
 66. Jiang J, Magilnick N, Tsurulnikov K, Abuladze N, Atanasov I, Ge P, Narla M, Pushkin A, Zhou ZH, Kurtz I. Single particle electron

- microscopy analysis of the bovine anion exchanger 1 reveals a flexible linker connecting the cytoplasmic and membrane domains. *PLoS one* 2013;8:e55408.
67. Anong WA, Franco T, Chu H, Weis TL, Devlin EE, Bodine DM, An X, Mohandas N, Low PS. Adducin forms a bridge between the erythrocyte membrane and its cytoskeleton and regulates membrane cohesion. *Blood* 2009; 114: 1904-12.
 68. Franke RP, Scharnweber T, Fuhrmann R, Wenzel F, Kruger A, Mrowietz C, Jung F. Effect of radiographic contrast media on the spectrin/actin-network of the membrane skeleton of erythrocytes. *PLoS one* 2014; 9: e89512.
 69. Reinhart WH. Peculiar red cell shapes: Fahraeus Lecture 2011. *Clinical hemorheology and microcirculation* 2011; 49: 11-27.
 70. Mrowietz C, Franke RP, Jung F. Influence of different radiographic contrast media on the echinocyte formation of human erythrocytes. *Clinical hemorheology and microcirculation* 2012; 50: 35-47.
 71. Heyman SN, Brezis M, Epstein FH, Spokes K, Silva P, Rosen S. Early renal medullary hypoxic injury from radiocontrast and indomethacin. *Kidney international* 1991; 40: 632-42.
 72. Tervahartiala P, Kivisaari L, Kivisaari R, Vehmas T, Virtanen I. Structural changes in the renal proximal tubular cells induced by iodinated contrast media. *Nephron* 1997; 76: 96-102.
 73. Heinrich MC, Kuhlmann MK, Grgic A, Heckmann M, Kramann B, Uder M. Cytotoxic effects of ionic high-osmolar, nonionic monomeric, and nonionic iso-osmolar dimeric iodinated contrast media on renal tubular cells in vitro. *Radiology* 2005; 235: 843-9.
 74. Hardiek K, Katholi RE, Ramkumar V, Deitrick C. Proximal tubule cell response to radiographic contrast media. *American journal of physiology Renal physiology* 2001; 280: F61-70.
 75. Heyman SN, Fuchs S, Jaffe R, Shina A, Ellezian L, Brezis M, Rosen S. Renal microcirculation and tissue damage during acute ureteral obstruction in the rat: effect of saline infusion, indomethacin and radiocontrast. *Kidney international* 1997; 51: 653-63.
 76. Hizoh I, Haller C. Radiocontrast-induced renal tubular cell apoptosis: hypertonic versus oxidative stress. *Investigative radiology* 2002; 37: 428-34.
 77. Yano T, Itoh Y, Sendo T, Kubota T, Oishi R. Cyclic AMP reverses radiocontrast media-induced apoptosis in LLC-PK1 cells by activating a kinase/PI3 kinase. *Kidney international* 2003; 64: 2052-63.
 78. Zhang J, Duarte CG, Ellis S. Contrast medium- and mannitol-induced apoptosis in heart and kidney of SHR rats. *Toxicologic pathology* 1999; 27: 427-35.
 79. Andreucci M, Faga T, Russo D, Bertucci B, Tamburrini O, Pisani A, Sabbatini M, Fuiano G, Michael A. Differential activation of signaling pathways by low-osmolar and iso-osmolar radiocontrast agents in human renal tubular cells. *Journal of Cellular Biochemistry* 2014; 115(2): 281-9.
 80. Cross TG, Scheel-Toellner D, Henriquez NV, Deacon E, Salmon M, Lord JM. Serine/threonine protein kinases and apoptosis. *Exp Cell Res* 2000; 256: 34-41.
 81. Datta SR, Brunet A, Greenberg ME. Cellular survival: a play in three acts. *Genes Dev* 1999; 13: 2905-27.
 82. Kyriakis JM, Avruch J. Mammalian mitogen-activated protein kinase signal transduction pathways activated by stress and inflammation. *Physiological reviews* 2001; 81: 807-69.
 83. Woodgett JE. Protein Kinase functions. Oxford University Press; 2000.
 84. Andreucci M, Michael A, Kramers C, Park KM, Chen A, Matthaeus T, Alessandrini A, Haq S, Force T, Bonventre JV. Renal ischemia/reperfusion and ATP depletion/repletion in LLC-PK(1) cells result in phosphorylation of FKHR and FKHL1. *Kidney international* 2003; 64: 1189-98.
 85. Racusen LC, Monteil C, Sgrignoli A, Lucskay M, Marouillat S, Rhim JG, Morin JP. Cell lines with extended in vitro growth potential from human renal proximal tubule: characterization, response to inducers, and comparison with established cell lines. *The Journal of laboratory and clinical medicine* 1997;129:318-29.
 86. Ryan MJ, Johnson G, Kirk J, Fuerstenberg SM, Zager RA, Torok-Storb B. HK-2: an immortalized proximal tubule epithelial cell line from normal adult human kidney. *Kidney international* 1994; 45: 48-57.
 87. Andreucci M, Fuiano G, Presta P, Lucisano G, Leone F, Fuiano L, Bisesti V, Esposito P, Russo D, Memoli B, Faga T, Michael A. Downregulation of cell survival signalling pathways and increased cell damage in hydrogen peroxide-treated human renal proximal tubular cells by alpha-erythropoietin. *Cell Prolif* 2009;42:554-61.
 88. Andreucci M, Fuiano G, Presta P, Esposito P, Faga T, Bisesti V, Procino A, Altieri V, Tozzo C, Memoli B, Michael A. Radiocontrast media cause dephosphorylation of Akt and downstream signaling targets in human renal proximal tubular cells. *Biochem Pharmacol* 2006; 72: 1334-42.
 89. Mosmann T. Rapid colorimetric assay for cellular growth and survival: application to proliferation and cytotoxicity assays. *J Immunol Methods* 1983; 65: 55-63.
 90. Yoon S, Seger R. The extracellular signal-regulated kinase: multiple substrates regulate diverse cellular functions. *Growth Factors* 2006; 24: 21-44.
 91. Kyriakis JM, Avruch J. Mammalian MAPK signal transduction pathways activated by stress and inflammation: a 10-year update. *Physiological reviews* 2012; 92: 689-737.
 92. Nowak DE, Tian B, Jamaluddin M, Boldogh I, Vergara LA, Choudhary S, Brasier, AR. RelA Ser276 phosphorylation is required for activation of a subset of NF-kappaB-dependent genes by recruiting cyclin-dependent kinase 9/cyclin T1 complexes. *Mol Cell Biol* 2008; 28: 3623-38.
 93. Andreucci M, Faga T, Lucisano G, Uccello F, Pisani A, Memoli B, Sabbatini M, Fuiano G, Michael A. Mycophenolic acid inhibits the phosphorylation of NF-kappaB and JNKs and causes a decrease in IL-8 release in H2O2-treated human renal proximal tubular cells. *Chem Biol Interact* 2010; 185: 253-62.
 94. Andreucci M, Lucisano G, Faga T, Bertucci B, Tamburrini O, Pisani A, Sabbatini M, Salzano S, Vitale M, Fuiano G, Michael A. Differential activation of signaling pathways involved in cell death, survival and inflammation by radiocontrast media in human renal proximal tubular cells. *Toxicol Sci* 2011; 119: 408-16.
 95. Weston CR, Davis RJ. The JNK signal transduction pathway. *Curr Opin Cell Biol* 2007; 19: 142-9.
 96. Zarubin T, Han J. Activation and signaling of the p38 MAP kinase pathway. *Cell Res* 2005; 15: 11-8.
 97. Gong X, Celsi G, Carlsson K, Norgren S, Chen M. N-acetylcysteine amide protects renal proximal tubular epithelial cells against iohexol-induced apoptosis by blocking p38 MAPK and iNOS signaling. *American journal of nephrology* 2010; 31: 178-88.
 98. Lee HC, Sheu SH, Yen HW, Lai WT, Chang JG. JNK/ATF2 pathway is involved in iodinated contrast media-induced apoptosis. *American journal of nephrology* 2010; 31: 125-33.
 99. Andreucci M, Faga T, Michael A. The Renal Problems in X-Ray Based Imaging Techniques Using Iodinated Radiographic Contrast Agents. *Open Access Journal of Science and Technology* 2015; in press.
 100. Pflueger A, Larson TS, Nath KA, King BF, Gross JM, Knox FG. Role of adenosine in contrast media-induced acute renal failure in diabetes mellitus. *Mayo Clinic proceedings* 2000; 75: 1275-83.
 101. Khamaisi M, Raz I, Shilo V, Shina A, Rosenberger C, Dahan R, Abassi Z, Meidan R, Lecht S, Heyman SN. Diabetes and radiocontrast media increase endothelin converting enzyme-1 in the kidney. *Kidney international* 2008; 74: 91-100.
 102. Andreucci M, Faga T, Pisani A, Sabbatini M, Michael A. The choice of the iodinated radiographic contrast media to prevent Contrast-Induced Nephropathy. *Advances in Nephrology* 2014; 691623, 11 pages, <http://dx.doi.org/10.1155/2014/691623>
 103. Martin-Mateo MC, Sanchez-Portugal M, Iglesias S, de Paula A,

- Bustamante J. Oxidative stress in chronic renal failure. *Renal failure* 1999; 21: 155-67.
104. Okamura DM, Pennathur S, Pasichnyk K, Lopez-Guisa JM, Collins S, Febbraio M, Heinecke J, Eddy AA. CD36 regulates oxidative stress and inflammation in hypercholesterolemic CKD. *Journal of the American Society of Nephrology : JASN* 2009; 20: 495-505.
 105. Andreucci M, Faga T, Sabbatini M, Pisani A, Russo D, Michael A. How to prevent Contrast-Induced Nephropathy in clinical practice. *J Clin Nephrol Res* 2014; 1(1): 1002.
 106. Keane JJ, Hannon CM, Murray PT. Contrast-induced acute kidney injury: how much contrast is safe? *Nephrology, dialysis, transplantation* 2013; 28: 1376-83.
 107. Yang D, Yang D, Jia R, Tan J. Na⁺/Ca²⁺ exchange inhibitor, KB-R7943, attenuates contrast-induced acute kidney injury. *Journal of nephrology* 2013; 26: 877-85.
 108. Duan SB, Liu FY, Luo JA, Wu HW, Liu RH, Peng YM, Yang XL. Nephrotoxicity of high- and low-osmolar contrast media. The protective role of amlodipine in a rat model. *Acta radiologica* 2000; 41: 503-7.
 109. Yokomaku Y, Sugimoto T, Kume S, Araki S, Isshiki K, Chinkanasaki M, Sakaguchi M, Nitta N, Haneda M, Koya D, Uzu T, Kashiwagi A. Asialoerythropoietin prevents contrast-induced nephropathy. *Journal of the American Society of Nephrology : JASN* 2008; 19: 321-8.
 110. Sharples EJ, Patel N, Brown P, Stewart K, Mota-Philipe H, Sheaff M, Kieswich J, Allen D, Harwood S, Raftery M, Thiemermann C, Yaqoob MM. Erythropoietin protects the kidney against the injury and dysfunction caused by ischemia-reperfusion. *Journal of the American Society of Nephrology : JASN* 2004; 15: 2115-24.
 111. Yang CW, Li C, Jung JY, Shin SJ, Choi BS, Lim SW, Sun BK, Kim YS, Kim J, Chang YS, Bang BK. Preconditioning with erythropoietin protects against subsequent ischemia-reperfusion injury in rat kidney. *FASEB journal : official publication of the Federation of American Societies for Experimental Biology* 2003; 17: 1754-5.
 112. Bagnis C, Beaufils H, Jacquiaud C, Adabra Y, Jouanneau C, Le Nahour G, Jaudon MC, Bourbouze R, Jacobs C, Deray G. Erythropoietin enhances recovery after cisplatin-induced acute renal failure in the rat. *Nephrology, dialysis, transplantation* 2001; 16: 932-8.
 113. Goldfarb M, Rosenberger C, Ahuva S, Rosen S, Heyman SN. A role for erythropoietin in the attenuation of radiocontrast-induced acute renal failure in rats. *Renal failure* 2006; 28: 345-50.
 114. Kodama A, Watanabe H, Tanaka R, Tanaka H, Chuang VT, Miyamoto Y, Wu Q, Endo M, Hamasaki K, Ishima Y, Fukagawa M, Otagiri M, Maruyama T. A human serum albumin-thioredoxin fusion protein prevents experimental contrast-induced nephropathy. *Kidney international* 2013; 83: 446-54.
 115. Ellis JH, Cohan RH. Prevention of contrast-induced nephropathy: an overview. *Radiol Clin North Am* 2009; 47: 801-11, v.
 116. Solomon R, Dauerman HL. Contrast-induced acute kidney injury. *Circulation* 2010; 122: 2451-5.
 117. Mueller C. Prevention of contrast-induced nephropathy with volume supplementation. *Kidney international Supplement* 2006: S16-9.
 118. Merten GJ, Burgess WP, Gray LV, Holleman JH, Roush TS, Kowalchuk GJ, Bersin RM, Van Moore A, Simonton CA 3rd, Rittase RA, Norton HJ, Kennedy TP. Prevention of contrast-induced nephropathy with sodium bicarbonate: a randomized controlled trial. *JAMA* 2004; 291: 2328-34.
 119. Masuda M, Yamada T, Mine T, Morita T, Tamaki S, Tsukamoto Y, Okuda K, Iwasaki Y, Hori M, Fukunami M. Comparison of usefulness of sodium bicarbonate versus sodium chloride to prevent contrast-induced nephropathy in patients undergoing an emergent coronary procedure. *The American journal of cardiology* 2007; 100: 781-6.
 120. Ozcan EE, Guneri S, Akdeniz B, Akyildiz IZ, Senaslan O, Baris N, Aslan O, Badak O. Sodium bicarbonate, N-acetylcysteine, and saline for prevention of radiocontrast-induced nephropathy. A comparison of 3 regimens for protecting contrast-induced nephropathy in patients undergoing coronary procedures. A single-center prospective controlled trial. *Am Heart J* 2007; 154: 539-44.
 121. Tamura A, Goto Y, Miyamoto K, Naono S, Kawano Y, Kotoku M, Watanabe T, Kadota J. Efficacy of single-bolus administration of sodium bicarbonate to prevent contrast-induced nephropathy in patients with mild renal insufficiency undergoing an elective coronary procedure. *The American journal of cardiology* 2009; 104: 921-5.
 122. Navaneethan SD, Singh S, Appasamy S, Wing RE, Sehgal AR. Sodium bicarbonate therapy for prevention of contrast-induced nephropathy: a systematic review and meta-analysis. *American journal of kidney diseases* 2009; 53: 617-27.
 123. Hoste EA, De Waele JJ, Gevaert SA, Uchino S, Kellum JA. Sodium bicarbonate for prevention of contrast-induced acute kidney injury: a systematic review and meta-analysis. *Nephrology, dialysis, transplantation* 2010; 25: 747-58.
 124. Joannidis M, Schmid M, Wiedermann CJ. Prevention of contrast media-induced nephropathy by isotonic sodium bicarbonate: a meta-analysis. *Wien Klin Wochenschr* 2008; 120: 742-8.
 125. Assadi F. Acetazolamide for prevention of contrast-induced nephropathy: a new use for an old drug. *Pediatr Cardiol* 2006; 27: 238-42.
 126. Pakfetrat M, Nikoo MH, Malekmakan L, Tabandeh M, Roozbeh J, Nasab MH, Ostovan MA, Salari S, Kafi M, Vaziri NM, Adl F, Hosseini M, Khajehdehi P. A comparison of sodium bicarbonate infusion versus normal saline infusion and its combination with oral acetazolamide for prevention of contrast-induced nephropathy: a randomized, double-blind trial. *Int Urol Nephrol* 2009; 41: 629-34.
 127. Jang JS, Jin HY, Seo JS, Yang TH, Kim DK, Kim TH, Urm SH, Kim DS, Kim DK, Seol SH, Kim DI, Cho KI, Kim BH, Park YH, Je HG, Ahn JM, Kim WJ, Lee JY, Lee SW. Sodium bicarbonate therapy for the prevention of contrast-induced acute kidney injury - a systematic review and meta-analysis. *Circ J* 2012; 76: 2255-65.
 128. Briguori C, Airolidi F, D'Andrea D, Bonizzoni E, Morici N, Focaccio A, Michev I, Montorfano M, Carlino M, Cosgrave J, Ricciardelli B, Colombo A. Renal Insufficiency Following Contrast Media Administration Trial (REMEDIAL): a randomized comparison of 3 preventive strategies. *Circulation* 2007; 115: 1211-7.
 129. Reddan D, Laville M, Garovic VD. Contrast-induced nephropathy and its prevention: What do we really know from evidence-based findings? *Journal of nephrology* 2009; 22: 333-51.
 130. Zoungas S, Ninomiya T, Huxley R, Cass A, Jardine M, Gallagher M, Patel A, Vasheghani-Farahani A, Sadigh G, Perkovic V. Systematic review: sodium bicarbonate treatment regimens for the prevention of contrast-induced nephropathy. *Annals of internal medicine* 2009; 151: 631-8.
 131. Brar SS, Shen AY, Jorgensen MB, Kotlewski A, Aharonian VJ, Desai N, Ree M, Shah AI, Burchette RJ. Sodium bicarbonate vs sodium chloride for the prevention of contrast medium-induced nephropathy in patients undergoing coronary angiography: a randomized trial. *JAMA* 2008; 300: 1038-46.
 132. Brar SS, Hiremath S, Dangas G, Mehran R, Brar SK, Leon MB. Sodium bicarbonate for the prevention of contrast induced-acute kidney injury: a systematic review and meta-analysis. *Clin J Am Soc Nephrol* 2009; 4: 1584-92.
 133. Shavit L, Korenfeld R, Lifschitz M, Butnaru A, Slotki I. Sodium bicarbonate versus sodium chloride and oral N-acetylcysteine for the prevention of contrast-induced nephropathy in advanced chronic kidney disease. *J Interv Cardiol* 2009; 22: 556-63.
 134. Vasheghani-Farahani A, Sadigh G, Kassaian SE, Khatami SM, Fotouhi A, Razavi SA, Mansournia MA, Yamini-Sharif A, Amirzadegan A, Salarifar M, Sadeghian S, Davoodi G, Borumand

- MA, Esfehiani FA, Darabian S. Sodium bicarbonate plus isotonic saline versus saline for prevention of contrast-induced nephropathy in patients undergoing coronary angiography: a randomized controlled trial. *American journal of kidney diseases* 2009; 54: 610-8.
135. From AM, Bartholmai BJ, Williams AW, Cha SS, Pflueger A, McDonald FS. Sodium bicarbonate is associated with an increased incidence of contrast nephropathy: a retrospective cohort study of 7977 patients at mayo clinic. *Clin J Am Soc Nephrol* 2008; 3: 10-8.
 136. Briguori C, Quintavalle C, Donnarumma E, Condorelli G. Novel Biomarkers for Contrast-Induced Acute Kidney Injury. *BioMed research international* 2014; 2014: 568738.
 137. Ribichini F, Gambaro A, Pighi M, Pesarini G, Ferraro PM, Zuppi C, Baroni S, Penitente R, Ferrero V, Vassanelli C. Effects of prednisone on biomarkers of tubular damage induced by radiocontrast in interventional cardiology. *Journal of nephrology* 2013; 26: 586-93.
 138. Kumar S, Allen DA, Kieswich JE, Patel NS, Harwood S, Mazzon E, Cuzzocrea S, Raftery MJ, Thiernemann C, Yaqoob MM. Dexamethasone ameliorates renal ischemia-reperfusion injury. *Journal of the American Society of Nephrology : JASN* 2009; 20: 2412-25.
 139. Clauser P, Harpey C. Antioxidant properties of an antiischaemic agent: trimetazidine. *Advances in experimental medicine and biology* 1990; 264: 247-50.
 140. Elimadi A, Settaf A, Morin D, Sapena R, Lamchouri F, Cherrah Y, Tillement JP. Trimetazidine counteracts the hepatic injury associated with ischemia-reperfusion by preserving mitochondrial function. *The Journal of pharmacology and experimental therapeutics* 1998; 286: 23-8.
 141. Aubert A, Bernard C, Clauser P, Harpey C, Vaudry H. Effect of phenazine methosulfate on electrophysiological activity of the semicircular canal: antioxidant properties of trimetazidine. *European journal of pharmacology* 1989; 174: 215-25.
 142. Onbasili AO, Yenicerigli Y, Agaoglu P, Karul A, Tekten T, Akar H, Discigil G. Trimetazidine in the prevention of contrast-induced nephropathy after coronary procedures. *Heart* 2007; 93: 698-702.
 143. Rahman MM, Haque SS, Rokeya B, Siddique MA, Banerjee SK, Ahsan SA, Rahman F, Mahmood M, Ahmed K, Bhuiyan MM, Joarder AI, Debnath RC. Trimetazidine in the prevention of contrast induced nephropathy after coronary angiogram. *Mymensingh medical journal : MMJ* 2012; 21: 292-9.
 144. Akgullu C, Saruhan T, Eryilmaz U, Boyacioglu M, Onbasili OA, Meteoglu I, Kum C. The first histopathological evidence of trimetazidine for the prevention of contrast-induced nephropathy. *Renal failure* 2014; 36: 575-80.
 145. Andreucci M, Russo D, Fuiano G, Minutolo R, Andreucci VE. Diuretics in renal failure. *Mineral and electrolyte metabolism* 1999; 25: 32-8.
 146. Andreucci M, Faga T, Perticone F, Michael A. Radiographic contrast agents, drugs useful for diagnostics, but with contrast-induced nephropathy as side effect. *J Nephro Urol* 2014, 1(2): 11.
 147. Solomon R, Werner C, Mann D, D'Elia J, Silva P. Effects of saline, mannitol, and furosemide to prevent acute decreases in renal function induced by radiocontrast agents. *The New England journal of medicine* 1994; 331: 1416-20.
 148. Weinstein JM, Heyman S, Brezis M. Potential deleterious effect of furosemide in radiocontrast nephropathy. *Nephron* 1992;62:413-5.
 149. Weisberg LS, Kurnik PB, Kurnik BR. Risk of radiocontrast nephropathy in patients with and without diabetes mellitus. *Kidney international* 1994; 45: 259-65.
 150. Briguori C, Visconti G, Focaccio A, Airoidi F, Valgimigli M, Sangiorgi GM, Golia B, Ricciardelli B, Condorelli G, Remedial Ii Investigators. Renal Insufficiency After Contrast Media Administration Trial II (REMEDIAL II): RenalGuard System in high-risk patients for contrast-induced acute kidney injury. *Circulation* 2011; 124: 1260-9.
 151. Marenzi G, Ferrari C, Marana I, Assanelli E, De Metrio M, Teruzzi G, Veglia F, Fabbiochi F, Montorsi P, Bartorelli AL. Prevention of contrast nephropathy by furosemide with matched hydration: the MYTHOS (Induced Diuresis With Matched Hydration Compared to Standard Hydration for Contrast Induced Nephropathy Prevention) trial. *JACC Cardiovascular interventions* 2012; 5: 90-7.
 152. Safirstein R, Andrade L, Vieira JM. Acetylcysteine and nephrotoxic effects of radiographic contrast agents--a new use for an old drug. *The New England journal of medicine* 2000; 343: 210-2.
 153. Baker CS, Wragg A, Kumar S, De Palma R, Baker LR, Knight CJ. A rapid protocol for the prevention of contrast-induced renal dysfunction: the RAPPID study. *Journal of the American College of Cardiology* 2003; 41: 2114-8.
 154. Spargias K, Alexopoulos E, Kyrzopoulos S, Iokovis P, Greenwood DC, Manginas A, Voudris V, Pavlides G, Buller CE, Kremastinos D, Cokkinos DV. Ascorbic acid prevents contrast-mediated nephropathy in patients with renal dysfunction undergoing coronary angiography or intervention. *Circulation* 2004; 110: 2837-42.
 155. Alexopoulos E, Spargias K, Kyrzopoulos S, Manginas A, Pavlides G, Voudris V, Lerakis S, McLean DS, Cokkinos DV. Contrast-induced acute kidney injury in patients with renal dysfunction undergoing a coronary procedure and receiving non-ionic low-osmolar versus iso-osmolar contrast media. *Am J Med Sci* 2010; 339: 25-30.
 156. Boscheri A, Weinbrenner C, Botzek B, Reynen K, Kuhlisch E, Strasser RH. Failure of ascorbic acid to prevent contrast-media induced nephropathy in patients with renal dysfunction. *Clin Nephrol* 2007; 68: 279-86.
 157. Jo SH, Koo BK, Park JS, Kang HJ, Kim YJ, Kim HL, Chae IH, Choi DJ, Sohn DW, Oh BH, Park YB, Choi YS, Kim HS. N-acetylcysteine versus AScorbic acid for preventing contrast-Induced nephropathy in patients with renal insufficiency undergoing coronary angiography NASPI study-a prospective randomized controlled trial. *Am Heart J* 2009; 157: 576-83.
 158. Sadat U, Usman A, Gillard JH, Boyle JR. Does ascorbic acid protect against contrast-induced acute kidney injury in patients undergoing coronary angiography: a systematic review with meta-analysis of randomized, controlled trials. *Journal of the American College of Cardiology* 2013; 62: 2167-75.
 159. Tasanarong A, Vohakiat A, Hutayanon P, Piyayotai D. New strategy of alpha- and gamma-tocopherol to prevent contrast-induced acute kidney injury in chronic kidney disease patients undergoing elective coronary procedures. *Nephrology, dialysis, transplantation* 2013; 28: 337-44.
 160. Kongkham S, Sriwong S, Tasanarong A. Protective effect of alpha tocopherol on contrast-induced nephropathy in rats. *Nefrologia* 2013; 33: 116-23.
 161. Kabasakal L, Sehirli AO, Cetinel S, Cikler E, Gedik N, Sener G. Mesna (2-mercaptoethane sulfonate) prevents ischemia/reperfusion induced renal oxidative damage in rats. *Life Sci* 2004; 75: 2329-40.
 162. Ludwig U, Riedel MK, Backes M, Imhof A, Mueche R, Keller F. MESNA (sodium 2-mercaptoethanesulfonate) for prevention of contrast medium-induced nephrotoxicity - controlled trial. *Clin Nephrol* 2011; 75: 302-8.
 163. Toprak O, Cirit M, Tanrisev M, Yazici C, Canoz O, Sipahioglu M, Uzum A, Ersoy R, Sozmen EY. Preventive effect of nebivolol on contrast-induced nephropathy in rats. *Nephrology, dialysis, transplantation* 2008; 23: 853-9.
 164. Avci E, Yesil M, Bayata S, Postaci N, Arikan E, Cirit M. The role of nebivolol in the prevention of contrast-induced nephropathy in patients with renal dysfunction. *Anadolu Kardiyol Derg* 2011; 11: 613-7.
 165. Gunebakmaz O, Kaya MG, Koc F, Akpek M, Kasapkar A, Inanc MT, Yarlioglu M, Calapkorur B, Karadag Z, Oguzhan A. Does

- nebulivolol prevent contrast-induced nephropathy in humans? *Clin Cardiol* 2012; 35: 250-4.
166. Andreucci M. [Statins in CIN: a problem at least partly solved?]. *G Ital Nefrol* 2013, 30(3).
 167. Sabbatini M, Pisani A, Uccello F, Serio V, Seru R, Paterno R, Cianciaruso B, Fuiano G, Andreucci M. Atorvastatin improves the course of ischemic acute renal failure in aging rats. *Journal of the American Society of Nephrology: JASN* 2004; 15: 901-9.
 168. Patti G, Ricottini E, Nusca A, Colonna G, Pasceri V, D'Ambrosio A, Montinaro A, Di Sciascio G. Short-term, high-dose Atorvastatin pretreatment to prevent contrast-induced nephropathy in patients with acute coronary syndromes undergoing percutaneous coronary intervention (from the ARMYDA-CIN [atorvastatin for reduction of myocardial damage during angioplasty--contrast-induced nephropathy] trial. *The American journal of cardiology* 2011; 108: 1-7.
 169. Ozkan G, Ulusoy S, Orem A, Ersoz S, Alkanat M, Yucsan FB, Kaynar K, Al S. Protective effect of the grape seed proanthocyanidin extract in a rat model of contrast-induced nephropathy. *Kidney Blood Press Res* 2012; 35: 445-53.
 170. O'Byrne DJ, Devaraj S, Grundy SM, Jialal I. Comparison of the antioxidant effects of Concord grape juice flavonoids alpha-tocopherol on markers of oxidative stress in healthy adults. *The American journal of clinical nutrition* 2002; 76: 1367-74.
 171. Anselm E, Chataigneau M, Ndiaye M, Chataigneau T, Schini-Kerth VB. Grape juice causes endothelium-dependent relaxation via a redox-sensitive Src- and Akt-dependent activation of eNOS. *Cardiovascular research* 2007; 73: 404-13.
 172. Andreucci M, Faga T, Pisani A, Sabbatini M, Russo D, De Sarro GB, Navarra M, Michael A. Reversal of radiocontrast medium toxicity in human renal proximal tubular cells by white grape juice extract. 2015; 229: 17-25
 173. Pasternak JJ, Williamson EE. Clinical pharmacology, uses, and adverse reactions of iodinated contrast agents: a primer for the non-radiologist. *Mayo Clinic proceedings* 2012; 87: 390-402.
- Peer reviewer:** Neslihan Toyran, Associate Professor, Department of Physiology, Faculty of Medicine, Baskent University, 06530 Ankara, Turkey.