

HIV Disease and the Heart: A Review

Evbu Enakpene, Jinu John, Chukwudi Obiagwu, Suvash Shrestha, Guy Kulbak, Vijay Shetty, Gerald Hollander

Evbu Enakpene, Chukwudi Obiagwu, Suvash Shrestha, Department of Internal Medicine, Maimonides Medical Center, Brooklyn, NY 11219, the United States

Jinu John, Guy Kulbak, Vijay Shetty, Gerald Hollander, Department of Cardiology, Maimonides Medical Center, Brooklyn, NY 11219, the United States

Correspondence to: Jinu John, MD, Department of Cardiology, Maimonides Medical Center, 4802 10th avenue, Brooklyn, NY 11219, the United States.

Email: jjohn3@maimonidesmed.org

Telephone: +1-718-283-6000

Received: January 3, 2015 Revised: January 29, 2015

Accepted: February 3, 2015

Published online: April 10, 2015

ABSTRACT

Human Immunodeficiency Virus (HIV) infection is a pandemic with a huge global burden. The mortality due to HIV has been steadily decreasing with better access to highly active antiretroviral therapy (HAART) and better quality of care. An increase in the life expectancy of HIV infected patients has resulted in the appearance of a different spectrum of diseases due to chronic HIV infection. Though cardiovascular disease due to HIV infection is associated with significant mortality risk, these conditions still remain grossly under diagnosed. This review article discusses the cardiovascular effects of HIV infection and the cardiovascular problems faced due to superimposed opportunistic infections and drug toxicity.

© 2015 ACT. All rights reserved.

Key words: HIV; Cardiomyopathy; QTc prolongation

Enakpene E, John J, Obiagwu C, Shrestha S, Kulbak G, Shetty V, Hollander G. HIV Disease and the Heart: A Review. *Journal of Cardiology and Therapy* 2015; 2(2): 279-284 Available from: URL: <http://www.ghrnet.org/index.php/jct/article/view/1151>

INTRODUCTION

Human Immunodeficiency Virus (HIV) infection has been identified as a major pandemic which transcends racial, ethnic, economic, social, physical and age barriers. It is of major global health importance. The United States Center for Disease Control (CDC) estimates that approximately 50,000 people in the US are infected with HIV yearly and this incidence has remained stable over the past decade^[1]. Over half (53%) of these new infections occurred in homosexual and bisexual men. African American men and women were also strongly affected and were estimated to have an incidence rate that was 7 times as high as the incidence rate among whites^[1,2]. There has been a remarkable reduction in the mortality rate associated with HIV infection and its complications. This has been attributed to better access to highly active antiretroviral therapy (HAART), better quality of care and increasing research and of knowledge of this disease^[3,4]. Consequent to these, several complications of HIV including cardiac complications are becoming more prevalent. HIV-related cardiovascular disease (CVD) is indeed under-diagnosed and overlooked, and is a major risk factor in all-cause mortality in patients with late stage HIV infection^[5,6].

HIV-infected patients are at an increased risk of CVD, reflecting the interaction of the risk associated with the host, the virus, opportunistic infections and antiretroviral therapy (ART). HIV associated cardiovascular (CV) complications are often wrongly attributed to other etiologies due to subclinical presentations and inadequate screening^[5,6]. Although traditional risk factors appear to increase risk to a similar degree in HIV-infected and HIV-uninfected persons, some risk factors such as smoking and illicit drug use may be more common in HIV-infected persons. HIV infection may further increase CVD risk via atherosclerotic effects on smooth muscle cells and macrophages or by increasing inflammation^[5].

MECHANISM OF CARDIOVASCULAR EFFECTS OF HIV

HIV can cause structural and functional injury to the heart (Figure 1)

including direct effect on the cardiac myocytes causing development of myocarditis and cardiomyopathy; drug toxicity from HAART, antiviral agents, antifungals and antimicrobials, leading to conduction abnormalities; nutritional deficiencies (carnitine, selenium and thiamine) leading to development of cardiomyopathy; and immune process involving major histocompatibility complex I, anti-a-myosin autoantibodies and cytokines^[7-9].

CARDIOVASCULAR MANIFESTATIONS OF HIV

The principal HIV associated cardiovascular manifestations include dilated cardiomyopathy, pericarditis with or without effusion, coronary artery disease, systemic arterial hypertension, pulmonary hypertension, endocarditis, cardiac malignancies and drug cardiotoxicity.

Dilated Cardiomyopathy

There is a 3-6% prevalence of HIV among patients with dilated cardiomyopathy and this is increasing as individuals with HIV infection are living longer^[10,11]. The incidence of dilated cardiomyopathy (DCM) in HIV infected individuals has been shown to be 15.9% per year before introduction of HAART, and an autopsy series showed a prevalence of about 25%^[12]. However, the prevalence has been reduced by about 30% in developed countries in the HAART era due to highly potent treatment and management of associated opportunistic infections^[13].

HIV alone cannot directly infect the cardiac myocytes as myocytes lack necessary receptors for viral entry. Reservoir cells in the heart (cardiac interstitial cells) and brain are the site of HIV infection. Cytokines and other inflammatory products produced by these reservoir cells in response to HIV infection are postulated to cause cardiac myocyte toxicity and thus myocardial dysfunction. This is also supported by the fact that in HIV infected patients, those with encephalopathy are more prone to die due to heart failure than those without encephalopathy^[12].

Another proposed mechanism by which HIV can have destructive effects on cardiac myocytes is by co-infection with cardiotropic viruses. Opportunistic infections implicated in causing myocardial dysfunction are Coxsackie virus, Cytomegalovirus (CMV), Epstein-Barr virus (EBV), Adenovirus and Toxoplasma gondii.

Drugs such as zidovudine, doxorubicin and foscarnet sodium have direct cardiotoxicity. Zidovudine destroys cardiac mitochondrial ultrastructure and inhibits mitochondrial DNA replication. Doxorubicin used to treat Kaposi sarcoma causes a dose-related DCM, while foscarnet can cause esophagitis when used to treat CMV infection^[14-16].

DCM is strongly associated with a poor prognosis in HIV infected individuals. Currie *et al*^[17] demonstrated a median survival of 101 days in patients with CD4 count <100, as compared with 472 days in patients with normal hearts at comparable stage of the disease. In the Prospective P2C2 HIV multicenter study, Fisher *et al*^[18] prospectively followed up 185 children with vertical transmission of HIV and they demonstrated that LV function and structure progressively deteriorated in the first 3 years of life resulting in increased LV mass and mild LV dysfunction. All-cause mortality was shown to be increased in chronic LV dysfunction.

Serial cardiologic evaluation and echocardiography in asymptomatic HIV positive individuals is highly recommended in order to detect early features of LV dysfunction with the aim of initiating early therapy in order to reduce the high mortality

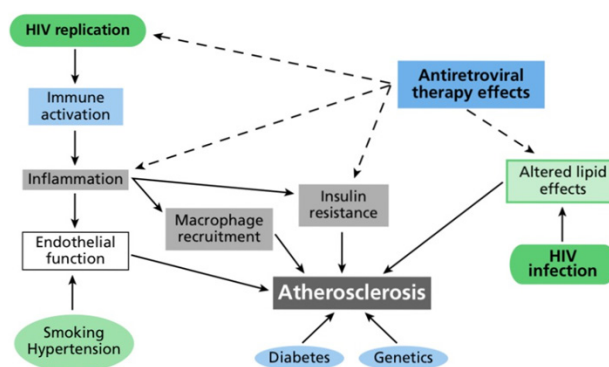


Figure 1 Interaction of host, virus, and antiretroviral therapy effects in cardiovascular disease risk. Reproduced with permission from IAS-USA. Top HIV Med.2009;17(3):98-103.

associated with DCM. Intensified antiretroviral therapy, appropriate nutrition (correcting carnitine, selenium and thiamine deficiency), in addition to conventional treatment of heart failure are the recommended modes of treatment in symptomatic individuals. Improvement in immunologic status of patients and better control of opportunistic infections and co-viral effects on heart muscle could be examples of the beneficial effects of HAART^[11,19]. Intravenous immunoglobulin infusions have also been tested with some improvement in myocardial function further strengthening the postulation that autoimmune mechanisms play a significant role in HIV-induced myocardial dysfunction^[20]. After 2 weeks of initiating intensive medical therapy if the clinical condition does not improve, in an attempt to identify a potentially treatable etiology, right heart catheterization and an endomyocardial biopsy can be considered. Biopsy showing lymphocytic infiltrates would suggest active myocarditis and may necessitate intensification of HAART with good clinical response noted in some studies^[12,20].

Pericardial effusion

Pericardial effusion is often an evidence of advanced HIV disease and it is usually asymptomatic^[21,22]. Prior to the HAART era, the incidence of pericardial effusion among AIDS patients was 11% per year and 22% per year in symptomatic AIDS patients^[11,22]. However, with the advent and use of HAART, the HIV-HEART study showed that only 2 out of 802 HIV-infected patients enrolled in the study had pericardial effusion^[23]. Large or symptomatic pericardial effusions are usually associated with infection or malignancy and often necessitate thorough evaluation and treatment aimed at the specific etiology. In the 5-year prospective evaluation of cardiac involvement in AIDS (PRECIA study)^[24], a high prevalence and incidence of pericardial effusion was found to be related to the stage of HIV infection. Only 1 non-AIDS HIV infected subject developed an effusion during the follow-up period of 5 years, however with the current CD4 criteria, that person would have been classified as AIDS at that time. Pericardial effusion significantly increases mortality in HIV patients. In the PRECIA study, pericardial effusion increased the risk of death among AIDS patient nearly three times.

The etiology of pericardial effusion in HIV is often difficult to identify, but may be related to opportunistic infection, metabolic abnormality or malignancy, and it could be a part of the “capillary leak syndrome” which is related to enhanced cytokine production in the later stages of HIV disease^[19]. There have been isolated case reports of pathogens like Mycobacterium tuberculosis, CMV,

Nocardia and *Cryptococcus*, involving the pericardium in HIV patients^[24-26]. End-stage HIV infection is associated with an increased risk of malignancies such as lymphoma and Kaposi sarcoma which can cause pericardial effusion^[25,26]. Other causes include uremic pericardial effusion as a result of HIV-associated nephropathy and nephrotoxicity^[27].

Pericardial effusion spontaneously resolves in about 42% of patients^[28,29]. The mortality, however, remains high even in patients with spontaneous resolution of effusion. Pericardiocentesis is currently recommended only in large or highly symptomatic effusions, for diagnostic evaluation of systemic illness, or in the presence of cardiac tamponade^[11].

HIV infection is an important differential diagnosis in any case of unexplained pericardial effusion or tamponade. Screening echocardiography has been recommended for HIV infected individuals regardless of the stage of the disease at presentation^[27,30]. Furthermore, all HIV infected patients with evidence of heart failure, Kaposi sarcoma, tuberculosis or other pulmonary infections should undergo baseline electrocardiographic testing and echocardiogram. HAART therapy should be commenced in HIV patients with pericardial effusion if patient is yet to commence^[30]. Overall, pericardial effusion is an independent predictor of mortality and does not correlate with CD4 counts^[22].

Infective Endocarditis

The incidence of Infective Endocarditis (IE) among HIV infected intravenous drug users (IDU) varies from 6.3% to 34% independent of HAART regimens and it is rare among non-IDU HIV infected patients^[31]. The prevalence among HIV patients has been found to be similar to that among HIV-uninfected intravenous drug users in the general population^[31]. The tricuspid valve is predominantly affected. In a study of AIDS patients, Barbaro *et al* showed that the commonest bacterial agents in IE are *Staphylococcus aureus* (which accounts for >75% of the cases), followed by *Streptococcus pneumoniae*, *Haemophilus influenzae* and *Candida albicans*, *Aspergillus fumigatus* and *Cryptococcus neoformans*^[31].

Nahass *et al* examined IDUs with IE and showed that the survival of patients from IE is generally similar in HIV infected patients compared with the general population at 85% and 93% respectively, however, patients with advanced HIV disease have a 30% higher mortality with endocarditis than asymptomatic HIV infected individuals^[32]. This is likely due to the high morbidity and mortality associated with advanced HIV disease. In a retrospective study by Gebo *et al*, IE incidence was found to have decreased from 20.5 to 6.6 per 1000 person-years (PY) over a 12 year period. This was attributed to the introduction of HAART^[33]. Before the advent of HAART, marantic endocarditis was highly prevalent among HIV infected individuals with a prevalence of 4-10% of autopsy cases of HIV patients; however this is less commonly encountered in the post HAART era^[27]. The approach to diagnosis and management of IE is similar in both HIV and HIV-uninfected individuals.

HIV-related cardiac neoplasms

Cardiac malignancies affect many HIV-infected individuals, especially those with the later stages of the disease. Cardiac malignancies are usually metastatic^[27]. Non-Hodgkin lymphoma and Kaposi sarcoma are the most common cardiac neoplasms in HIV-infected patients. Primary cardiac neoplasm associated with HIV is usually due to cardiac lymphoma. Non-Hodgkin lymphoma is often the first manifestation of AIDS in up to 4% of newly diagnosed cases. Patients may be asymptomatic initially and subsequently may present

as right sided heart failure or biventricular heart failure, conduction abnormalities, superior vena cava syndrome and pericardial effusion or tamponade^[27,34]. The overall prognosis is poor, but HAART therapy has reduced the incidence of Kaposi sarcoma and HIV-related non-Hodgkin lymphoma. Cardiac Kaposi sarcoma most commonly affects the visceral and parietal pericardium but the involvement of myocardium, coronary vessels, great vessels, epicardium and epicardial fat has also been described^[35].

Pulmonary hypertension

Pulmonary arterial hypertension (PAH) is a long-term complication of HIV infection, which is being diagnosed with increasing frequency following improved survival of HIV-infected patients with the use of HAART. However, the prevalence of HIV-associated PAH remains low with minimal change when pre-HAART and post-HAART eras are compared; the severity of PAH is not related to degree of immunosuppression^[36]. In a prospective review of 7,648 patients, Sitbon showed a prevalence of 0.46% among HIV infected individuals^[37]. This was similar to previous study by Speich *et al*^[38] in the pre- HAART era in which the prevalence was 0.5%.

The pathogenesis of HIV related pulmonary hypertension is not well understood. *In-vivo* and *in-vitro* studies show that HIV does not infect lung endothelial cells and HIV DNA, RNA or p24 antigen could not be found in the vessels with HIV-related pulmonary hypertension^[39]. Patients with AIDS and primary pulmonary hypertension present with a higher degree of pulmonary hypertension than non-AIDS patients. Pulmonary hypertension associated with HIV infection may be related to a cytokine-related stimulation and proliferation of endothelium^[40]. High levels of cytokines present in AIDS patients is associated with pulmonary hypertension, but the role of a host response to HIV--determined by one or more HLA subtypes--is suspected to enhance high cytokine production levels^[40].

Other causes of PAH in HIV include microvascular septic pulmonary emboli from thrombus, recurrent bronchopulmonary infection and vasculitis from immunologic effects of HIV disease^[38,41]. Treatment of HIV-infected individuals with PAH with standard HAART has been shown in a retrospective analysis of 47 patients in the Swiss HIV cohort to cause significant decline in mortality due to PAH as well as other causes. This suggests a beneficial effect of HAART in PAH^[42]. Oral endothelin receptor antagonist bosentan showed improvement in exercise tolerance and hemodynamic measurements in a study of HIV patients with PAH^[43]. Current guidelines suggest similar treatment of PAH in HIV-infected individuals as in HIV-uninfected individuals other than the HAART in HIV.

Coronary Artery disease in HIV

HIV infection has been associated with an approximately 1 to 2 fold increase in risk to develop coronary artery disease (CAD) compared to the general population^[44-46]. The use of protease inhibitors (PI) and abacavir also increase the risk of myocardial infarction (MI), though abacavir as a culprit is still controversial^[47,48]. HIV infection is known to cause endothelial dysfunction, platelet activation and a hypercoagulable state all of which increase the risk of CAD. Mary-Krause *et al* demonstrated a 3-fold increase in the risk of MI in HIV-infected individuals compared to HIV-uninfected individuals. They showed a duration-related effect relationship between use of PI and MI, with a higher MI incidence rate among men exposed to PI for 18 months or more^[49]. This finding has been observed among many similar studies^[50,51], demonstrating a high association of use of PIs with CAD. However, in a study by Bozzette *et al*, there were no significant negative effects observed by the use of HAART including

PIs on rates of cardiovascular or cerebrovascular events or related mortality^[52]. This study emphasized the fact that there was no need to compromise HAART therapy for the fear of accelerated vascular disease. Recent studies showed that HIV-infected patients presented with large thrombus burdens than atherosclerotic plaques suggesting thrombophilia as a possible cause of CAD events^[53,54]. Longer term studies are needed in this regard to ascertain the pathophysiology and risk-benefit of HAART in relation to coronary atherosclerosis.

In a retrospective study of HIV patients with MI, HIV patients who had undergone coronary angioplasty had a significantly higher rate of restenosis than HIV-uninfected controls. Also, the HIV patients were younger, more likely to be cigarette smokers and had lower HDL levels^[55].

The D:A:D study (Data Collection of Adverse events of Anti-HIV Drugs) is one of the largest databases on cardiovascular disease (CVD) risk factors with 33,308 HIV-infected patients^[56]. The cardiovascular risk assessment model from D: A: D includes CVD risk factors and exposure to antiretroviral drugs known to increase CVD risks. A risk score calculator (<http://www.cphiv.dk/TOOLS/Framingham/tabid/302/Default.aspx>) predicts CVD risk slightly better than the Framingham risk score, as the Framingham risk score overpredicts CVD in HIV population, but underpredicts CVD risk in HIV-infected patients who are females, former smokers and diabetic patients^[57,58].

Metabolic effects of HIV

HIV infection causes a chronic inflammatory state which can worsen atherosclerosis and hence CAD. In untreated HIV-infected patients, there is a decrease in total cholesterol, HDL cholesterol, and LDL-cholesterol with an increase in triglycerides. Following HAART, all these increase except for HDL cholesterol which remains low^[59,60]. Circulating inflammatory cytokines present in HIV-infected patients might be responsible for the increase in basal lipolysis and hepatic de novo lipogenesis seen in these patients. Peripheral fatty acid trapping is impaired and insulin cannot suppress lipolysis effectively in adipocytes^[61].

Dyslipidemia, hypertriglyceridemia, low HDL cholesterol, insulin resistance in the HIV-infected patient on HAART would subsequently lead to lipodystrophy, which is associated with increased mortality^[62,63,64].

Unlike the older antiretroviral drugs (first generation PIs and thymidine-containing reverse transcriptase inhibitors), the newer drugs have not been shown to be associated with new-onset diabetes mellitus^[65,66].

HIV and QTc prolongation

In HIV-infected patients, the prevalence of QT prolongation is reported to be 28%. In patients with AIDS and AIDS with autonomic dysfunction, the percentage goes up to 45% and 65% respectively^[67,68]. Furthermore, the incidence of sudden cardiac death in HIV-infected patients is significantly higher when compared to the general population with similar risk factors^[69,70]. Wongcharoen et al found that independent of autonomic dysfunction or antiretroviral drugs, there is a higher risk of ventricular arrhythmias and mortality arising from prolonged QTc interval and increased QT dispersion in HIV-infected patients receiving combined antiretroviral therapy^[71].

Many drugs used during the treatment of HIV and associated opportunistic infections can also prolong QTc (Atazanavir, IV Pentamidine, Trimethoprim-Sulfamethoxazole, antifungals like Ketoconazole are a few). Hence, it is prudent to closely monitor patients with HIV infection for QTc prolongation and development of related life threatening arrhythmias like Torsades de Pointes^[72].

CONCLUSION

HIV infection has been in existence for so many decades, and it has remained a chronic disease of major public health importance. Its attendant complications are also increasingly more prevalent. The improved medical care and access to early intervention has substantially increased life expectancy in affected individuals. In view of the significant cardiovascular complications associated with HIV, increased awareness is needed among health care professionals to enhance adequate identification and screening of HIV infected patients for cardiovascular diseases. This should be targeted to identify patients early and institute appropriate therapeutic strategies.

CONFLICT OF INTERESTS

There are no conflicts of interest with regard to the present study.

REFERENCES

- Centers for Disease Control and Prevention. Estimated HIV incidence in the United States, 2007–2010. HIV Surveillance Supplemental Report 2012;17(No.4). <http://www.cdc.gov/hiv/topics/surveillance/resources/reports/#supplemental>. Published December 2012.
- Hall HI, Song R, Rhodes P, Prejean J, An Q, Lee LM, Karon J, Brookmeyer R, Kaplan EH, McKenna MT, Janssen RS. Estimation of HIV incidence in the United States. *JAMA* 2008;300:520-9.
- CDC. HIV Surveillance Report, 2012; vol. 24. Published November 2014.
- CDC. Slide Set: HIV Mortality (through 2010).
- Currier JS. Update on cardiovascular complications in HIV infection. *Top HIV Med* 2009;17:98-103.
- Dube MP, Lipshultz SE, Fichtenbaum CJ, Greenberg R, Schecter AD, Fisher SD. Effects of HIV infection and antiretroviral therapy on the heart and vasculature. *Circulation* 2008;118:e36-40.
- Wongcharoen W, Suaklin S, Tantisirivit N, Phrommintikul A, Chattapakorn N. QT dispersion in HIV-infected patients receiving combined antiretroviral therapy. *Ann Noninvasive Electrocardiol* 2014 Nov;19(6):561-6.
- Orenstein JM. Replication of HIV-1 in vivo and in vitro. *Ultrastruct Pathol* 2007;31:151-67.
- Khunnawat C, Mukerji S, Havlicek D, Jr., Touma R, Abela GS. Cardiovascular manifestations in human immunodeficiency virus-infected patients. *Am J Cardiol* 2008;102:635-42.
- Rerkpattanapipat P, Wongpraparut N, Jacobs LE, Kotler MN. Cardiac manifestations of acquired immunodeficiency syndrome. *Arch Intern Med* 2000;160:602-8.
- Barbaro G, Fisher SD, Lipshultz SE. Pathogenesis of HIV-associated cardiovascular complications. *Lancet Infect Dis* 2001;1:115-24.
- Barbaro G, Di Lorenzo G, Grisorio B, Barbarini G. Incidence of dilated cardiomyopathy and detection of HIV in myocardial cells of HIV-positive patients. Gruppo Italiano per lo Studio Cardiologico dei Pazienti Affetti da AIDS. *N Engl J Med* 1998;339:1093-9.
- Bijl M, Dieleman JP, Simoons M, Van Der Ende ME. Low prevalence of cardiac abnormalities in an HIV-seropositive population on antiretroviral combination therapy. *J AIDS* 2001; 27: 318-20.
- Lewis W, Grupp IL, Grupp G, Hoit B, Morris R, Samarel AM, et al. Cardiac dysfunction in the HIV-1 transgenic mouse treated with zidovudine. *Lab Invest* 2000;80: 187-97.
- Bristow MR, Mason JW, Billingham ME, Daniels JR. Doxorubicin cardiomyopathy: evaluation by phonocardiography, endomyocardial biopsy and cardiac catheterization. *Ann Intern Med*

- 1978;88: 168-75.
16. Brown DL, Sather S, Cheitlin MD. Reversible cardiac dysfunction associated with foscarnet therapy for cytomegalovirus esophagitis in an AIDS patient. *Am Heart J* 1993; 125: 1439-41
 17. Currie PF, Jacob AJ, Foreman AR, Elton RA, Brettle RP, Boon NA. Heart muscle disease related to HIV infection: prognostic implications. *BMJ* 1994;309:1605-7.
 18. Fisher SD, Easley KA, Orav EJ, Colan SD, Kaplan S, Starc TJ, Bricker JT, Lai WW, Moodie DS, Sopko G, Lipshultz SE. Mild dilated cardiomyopathy and increased left ventricular mass predict mortality: the prospective P2C2 HIV Multicenter Study. *Am Heart J* 2005;150:439-47.
 19. Pugliese A, Isnardi D, Saini A, Scarabelli T, Raddino R, Torre D. Impact of highly active antiretroviral therapy in HIV-positive patients with cardiac involvement. *J Infect* 2000;40:282-4.
 20. Wilkins CE, Sexton DJ, McAllister HA. HIV-associated myocarditis treated with zidovudine (AZT). *Tex Heart Inst J* 1989;16:44-5.
 21. Mitiku TY, Heidenreich PA. A small pericardial effusion is a marker of increased mortality. *Am Heart J*;161:152-7.
 22. Velasquez EM, Glancy DL. Cardiovascular disease in patients infected with the human immunodeficiency virus. *J La State Med Soc* 2003;155:314-24.
 23. Lind A, Reinsch N, Neuhaus K, et al. Pericardial effusion of HIV-infected patients - results of a prospective multicenter cohort study in the era of antiretroviral therapy. *European Journal of Medical Research* 2011;16(11):480-483.
 24. Heidenreich PA, Eisenberg MJ, Kee LL, Somelofski CA, Hollander H, Schiller NB, Cheitlin MD. Pericardial effusion in AIDS. Incidence and survival. *Circulation* 1995;92:3229-34.
 25. Braza JM, Sullivan RJ, Bhargava P, Pantanowitz L, Dezube BJ. Images in HIV/AIDS. Pericardial primary effusion lymphoma. *AIDS Read* 2007;17:250-2.
 26. Danbauchi SS, Oyati IA, Alhassan MA, Yusufu LM, David SO. Pericardial effusion and tamponade in Zaria: the association of HIV/AIDS. *Trop Doct* 2004;34:124.
 27. Bonow ROMDLZ, D.P.; Libby P. Braunwald's Heart Disease: A Textbook of Cardiovascular Medicine. Elsevier, 2011.
 28. Silva-Cardoso J, Moura B, Martins L, Mota-Miranda A, Rocha-Goncalves F, Lecour H. Pericardial involvement in human immunodeficiency virus infection. *Chest* 1999;115:418-22.
 29. Sudano I, Spieker LE, Noll G, Corti R, Weber R, Luscher TF. Cardiovascular disease in HIV infection. *Am Heart J* 2006;151:1147-55.
 30. Lipshultz SE, Fisher SD, Lai WW, Miller TL. Cardiovascular risk factors, monitoring, and therapy for HIV-infected patients. *AIDS* 2003;17 Suppl 1:S96122.
 31. Barbaro G, Di Lorenzo G, Grisorio B, Barbarini G. Cardiac involvement in the acquired immunodeficiency syndrome: a multicenter clinical-pathological study. Gruppo Italiano per lo Studio Cardiologico dei pazienti affetti da AIDS Investigators. *AIDS Res Hum Retroviruses* 1998;14:1071-7.
 32. Nahass RG, Weinstein MP, Bartels J, Gocke DJ. Infective endocarditis in intravenous drug users: a comparison of human immunodeficiency virus type 1 negative and -positive patients. *J Infect Dis* 1990;162:967-70.
 33. Gebo KA, Burkey MD, Lucas GM, Moore RD, Wilson LE. Incidence of, risk factors for, clinical presentation, and 1-year outcomes of infective endocarditis in an urban HIV cohort. *J Acquir Immune Defic Syndr* 2006;43:426-32.
 34. Aboulaflia DM. Human immunodeficiency virus-associated neoplasms: epidemiology, pathogenesis, and review of current therapy. *Cancer Pract* 1994;2:297-306.
 35. Barbaro G. Cardiovascular manifestations of HIV infection. *J R Soc Med* 2001;94:384-90.
 36. Morris A, Crothers K, Beck JM, et al; Disease ATSCoHP. An official ATS workshop report: emerging issues and current controversies in HIV associated pulmonary diseases. *Proc Am Thorac Soc* 2011;8:17-26.
 37. Sitbon O. HIV-related pulmonary arterial hypertension: clinical presentation and management. *AIDS* 2008;22 Suppl 3:S55-62.
 38. Speich R, Jenni R, Opravil M, Pfab M, Russi EW. Primary pulmonary hypertension in HIV infection. *Chest* 1991;100:1268-71.
 39. Kanmogne GD, Kennedy RC, Grammas P. Is HIV involved in the pathogenesis of non-infectious pulmonary complications in infected patients? *Curr HIV Res* 2003;1:385-93.
 40. Pellicelli AM, Barbaro G, Palmieri F, Girardi E, D'Ambrosio C, Rianda A, Barbarini G, Frigiotti D, Borgia MC, Petrosillo N. Primary pulmonary hypertension in HIV patients: a systematic review. *Angiology* 2001;52:31-41.
 41. Silva-Cardoso J, Moura B, Ferreira A, Martins L, Bravo-Faria D, Mota-Miranda A, Rocha-Goncalves F, Lecour H, Cerqueira-Gomes M. Predictors of myocardial dysfunction in human immunodeficiency virus-infected patients. *J Card Fail* 1998;4:19-26.
 42. Zuber JP, Calmy A, Evison JM, Hasse B, Schiffer V, Wagels T, Nuesch R, Magenta L, Ledergerber B, Jenni R, Speich R, Opravil M. Pulmonary arterial hypertension related to HIV infection: improved hemodynamics and survival associated with antiretroviral therapy. *Clin Infect Dis* 2004;38:1178-85.
 43. Sitbon O, Gressin V, Speich R, Macdonald PS, Opravil M, Cooper DA, Fourme T, Humbert M, Delfraissy JF, Simonneau G. Bosentan for the treatment of human immunodeficiency virus-associated pulmonary arterial hypertension. *Am J Respir Crit Care Med* 2004;170:1212-7.
 44. Friis-Møller N, Reiss P, Sabin CA, et al. Class of antiretroviral drugs and the risk of myocardial infarction. *N Engl J Med*. 2007;356:1723-1735.
 45. Freiberg MS, Chang CC, Kuller LH, et al. HIV infection and the risk of acute myocardial infarction. *JAMA Intern Med*. 2013;173:614-622.
 46. Hakeem A, Bhatti S, Cilingiroglu M. The spectrum of atherosclerotic coronary artery disease in HIV patients. *Curr Atheroscler Rep*. 2010;12:119-124.
 47. Bavinger C, Bendavid E, Niehaus K, et al. Risk of cardiovascular disease from antiretroviral therapy for HIV: a systematic review. *PLoS One*. 2013;8:e59551.
 48. Ding X, Andraca-Carrera E, Cooper C, et al. No association of abacavir use with myocardial infarction: findings of an FDA meta-analysis. *J Acquir Immune Defic Syndr*. 2012;61:441-447.
 49. Mary-Krause M, Cotte L, Simon A, Partisani M, Costagliola D. Increased risk of myocardial infarction with duration of protease inhibitor therapy in HIV-infected men. *AIDS* 2003;17:2479-86.
 50. Jutte A, Schwenk A, Franzen C, Romer K, Diet F, Diehl V, Fatkenheuer G, Salzberger B. Increasing morbidity from myocardial infarction during HIV protease inhibitor treatment? *AIDS* 1999;13:1796-7.
 51. Salzberger B, Rockstroh J, Wieland U, Franzen C, Schwenk A, Jutte A, Hegener P, Cornely O, Morchen C, Gaensicke T, Diehl V, Fatkenheuer G. Clinical efficacy of protease inhibitor based antiretroviral combination therapy--a prospective cohort study. *Eur J Med Res* 1999;4:449-55.
 52. Bozzette SA, Ake CF, Tam HK, Chang SW, Louis TA. Cardiovascular and cerebrovascular events in patients treated for human immunodeficiency virus infection. *N Engl J Med* 2003;348:702-10.
 53. Becker AC, Sliwa K, Stewart S, et al. Acute coronary syndromes in treatment-naïve black South Africans with human immunodeficiency virus infection. *J Interv Cardiol*. 2010;23:70-77.
 54. Becker AC, Jacobson B, Singh S, et al. The thrombotic profile of treatment-naïve HIV-positive Black South Africans with acute coronary syndromes. *Clin Appl Thromb Hemost*. 2011;17:264-272.
 55. Hsue PY, Giri K, Erickson S, MacGregor JS, Younes N, Shergill A, Waters DD. Clinical features of acute coronary syndromes in patients with human immunodeficiency virus infection. *Circulation* 2004;109:316-9.
 56. Data Collection on Adverse Events of Anti H. I. V. drugs Study

- Group, Smith C, Sabin CA, Lundgren JD, Thiebaut R, Weber R, Law M, Monforte A, Kirk O, Friis-Moller N, Phillips A, Reiss P, El Sadr W, Pradier C, Worm SW. Factors associated with specific causes of death amongst HIV-positive individuals in the D:A:D study. *AIDS* 2010;24:1537–1548.
57. Friis-Moller N, Thiebaut R, Reiss P, Weber R, Monforte AD, De Wit S, El-Sadr W, Fontas E, Worm S, Kirk O, Phillips A, Sabin CA, Lundgren JD, Law MG, D. A. D. study group. Predicting the risk of cardiovascular disease in HIV-infected patients: the data collection on adverse effects of anti-HIV drugs study. *Eur J Cardiovasc Prev Rehabil* 2010;17:491–501.
 58. Hemkens LG, Bucher HC. HIV infection and cardiovascular disease. *European Heart Journal*. Jan 2014, DOI: 10.1093/eurheartj/ehs528.
 59. Riddler SA, Smit E, Cole SR, Li R, Chmiel JS, Dobs A, Palella F, Visscher B, Evans R, Kingsley LA. Impact of HIV infection and HAART on serum lipids in men. *JAMA* 2003;289:2978–2982.
 60. Grunfeld C, Pang M, Doerrler W, Shigenaga JK, Jensen P, Feingold KR. Lipids, lipoproteins, triglyceride clearance, and cytokines in human immunodeficiency virus infection and the acquired immunodeficiency syndrome. *J Clin Endocrinol Metab* 1992;74:1045–1052.
 61. Stanley TL, Grinspoon SK. Body composition and metabolic changes in HIV-infected patients. *J Infect Dis* 2012;205(Suppl 3): S383–S390.
 62. Grunfeld C, Saag M, Cofrancesco J Jr, Lewis CE, Kronmal R, Heymsfield S, Tien PC, Bacchetti P, Shlipak M, Scherzer R, Study of Fat Redistribution Metabolic Change in H. I. V. Infection. Regional adipose tissue measured by MRI over 5 years in HIV-infected and control participants indicates persistence of HIV-associated lipodystrophy. *AIDS* 2010;24:1717–1726.
 63. Grunfeld C, Rimland D, Gibert CL, Powderly WG, Sidney S, Shlipak MG, Bacchetti P, Scherzer R, Haffner S, Heymsfield SB. Association of upper trunk and visceral adipose tissue volume with insulin resistance in control and HIV-infected subjects in the FRAM study. *J Acquir Immune Defic Syndr* 2007;46:283–290.
 64. Scherzer R, Heymsfield SB, Lee D, Powderly WG, Tien PC, Bacchetti P, Shlipak MG, Grunfeld C, Study of Fat Redistribution Metabolic Change in H. I. V. Infection. Decreased limb muscle and increased central adiposity are associated with 5-year all-cause mortality in HIV infection. *AIDS* 2011;25:1405–1414.
 65. Rasmussen LD, Mathiesen ER, Kronborg G, Pedersen C, Gerstoft J, Obel N. Risk of diabetes mellitus in persons with and without HIV: a Danish nationwide population based cohort study. *PLoS One* 2012;7:e44575.
 66. De Wit S, Sabin CA, Weber R, Worm SW, Reiss P, Cazanave C, El-Sadr W, Monforte A, Fontas E, Law MG, Friis-Moller N, Phillips A, Data Collection on Adverse Events of Anti H. I. V. Drugs study. Incidence and risk factors for new-onset diabetes in HIV-infected patients: the Data Collection on Adverse Events of Anti-HIV Drugs (D:A:D) study. *Diabetes Care* 2008;31:1224–1229.
 67. Sani MU, Okeahialam BN. QTc interval prolongation in patients with HIV and AIDS. *J Natl Med Assoc* 2005;97:1657–61.
 68. Villa A, Foresti V, Confalonieri F. Autonomic neuropathy and prolongation of QT interval in human immunodeficiency virus infection. *Clin Auton Res* 1995;5:48–52.
 69. Chugh SS, Jui J, Gunson K, et al. Current burden of sudden cardiac death: Multiple source surveillance versus retrospective death certificate-based review in a large U.S. community. *J Am Coll Cardiol* 2004;44:1268–1275.
 70. Tseng ZH, Secemsky EA, Dowdy D, et al. Sudden cardiac death in patients with human immunodeficiency virus infection. *J Am Coll Cardiol* 2012;59:1891–1896.
 71. Wongcharoen, W., Suaklin, S., Tantisirivit, N., Phrommintikul, A. and Chattipakorn, N. QT Dispersion in HIV-Infected Patients Receiving Combined Antiretroviral Therapy. *Annals of Noninvasive Electrocardiology*, 2014; 19: 561–566.
 72. John J, Amley X, Bombino G, Gitelis C, Topi B, Hollander G, Ghosh J. Torsade de Pointes due to methadone use in a patient with HIV and Hepatitis C Co-infection. *Cardiol Res Pract*. 2010 Dec 30;2010:524764

Peer reviewers: Laszlo Buga, Oxford University Hospitals, Oxford Heart Centre, Cardiology Department, John Redcliff Hospital Headington, Oxford OX3 9DU, the United Kingdom; Giuseppe Barbaro, Chief, Cardiology Unit, Department Of Experimental Medicine, Section Of Medical Pathophysiology, Policlinico Umberto I°, University of Rome La Sapienza, Viale Del Policlinico 155, 00161 Rome, Italy; AKM Monwarul Islam, Department of Cardiology, Jessore Medical College, Jessore, Bangladesh.