

An Unusual Right to Left Shunt: A case report

Jinu John, Suvash Shrestha, Chukwudi Obiagwu, Vinod Namana, Bernard Topi, Ramesh Kumar Chellamuthu, Sergey Ayzenberg, Jacob Shani

Suvash Shrestha, Chukwudi Obiagwu, Ramesh Kumar Chellamuthu, Department of Internal Medicine, Maimonides Medical Center, Brooklyn, NY, USA

Jinu John, Vinod Namana, Bernard Topi, Sergey Ayzenberg, Jacob Shani, Department of Cardiology, Maimonides Medical Center, Brooklyn, NY, USA

Correspondence to: Jinu John, MD, Department of Cardiology, Maimonides Medical Center, 4802 10th avenue, Brooklyn, NY 11219, United States of America.

Email: jjohn3@maimonidesmed.org

Telephone: +1-718-283-6000

Received: January 3, 2015 Revised: January 29, 2015

Accepted: February 3, 2015

Published online: April 10, 2015

ABSTRACT

Persistent Left Superior Venacava (PLSVC) is the most common venous anomaly affecting the thoracic venous system. If present, the usual site of drainage of a PLSVC is the right atrium via the coronary sinus. Here, we present a case of PLSVC which drained into left atrium instead. The patient, thus, had right to left shunt, making him persistently hypoxemic despite supplementary oxygen. This condition is extremely uncommon and can be easily overlooked if not specifically searched for.

© 2015 ACT. All rights reserved.

Key words: Persistent left sided superior venacava; Congenital heart disease; Right to left shunt

John J, Shrestha S, Obiagwu C, Namana V, Topi B, Chellamuthu RK, Ayzenberg S, Shani J. An Unusual Right to Left Shunt: A case report. *Journal of Cardiology and Therapy* 2015; 2(2): 309-310 Available from: URL: <http://www.ghrnet.org/index.php/jct/article/view/1156>

INTRODUCTION

Persistent left superior venacava (PLSVC) is a rare venous anomaly

that occurs in 0.3% to 0.5% of general population^[1,2]. It results when left cardinal vein fails to obliterate. It usually drains into right atrium via dilated coronary sinus. Thus, majority of these cases remain asymptomatic. However, in some cases, the PLSVC drains into left atrium instead of the right forming a right to left shunt. They may have exercise intolerance, and difficulty breathing. Here we present a case of PLSVC who had persistent hypoxemia.

CASE REPORT

A 54 year old male with past medical history of congenital cleft lip and unilateral right kidney presented to the emergency room with mild exertional shortness of breath of 3 months duration. On admission, he was hemodynamically stable and had an oxygen saturation of 91% on room air which was not improving despite oxygen administration. Examination of the heart and lungs was unremarkable.

Routine labs were all normal except for a borderline renal function. An arterial blood gas (ABG) on room air showed a borderline high A-a (alveolar arterial) gradient. Chest X-ray was normal. Electrocardiography (ECG) and transthoracic echocardiogram did not reveal any abnormalities. Computed Tomography (CT) chest was performed to assess any parenchymal lung disease that could have caused persistent hypoxemia. It suggested the possibility of a persistent left superior venacava (PLSVC). A subsequently done Magnetic Resonance Angiography (MRA) chest confirmed a PLSVC draining into the left atrium and a relatively diminutive right superior venacava draining into right atrium (Figure 1 and 2).

The patient was advised to undergo a transesophageal echocardiogram (TEE) for better delineation of the anatomy and evaluate the possibility of any intra-cardiac shunt. But he refused further treatment and was discharged.

DISCUSSION

Although rare, PLSVC is an important thoracic venous anomaly, especially when it drains into left atrium. During normal development of the embryo, the right cardinal vein draining into the right horn of sinus venosus persists and forms the right superior venacava. At

the same time the left cardinal vein which drains into the left horn of sinus venosus obliterates and forms the ligament of left superior venacava^[3]. The right horn of sinus venosus develops into smooth part of right atrium and the proximal portion of left horn of sinus venosus forms the coronary sinus. PLSVC is due to the failure of obliteration of the left cardinal vein during fetal development. In majority of the cases it eventually drains into the right atrium via a dilated coronary sinus. In 10% of the cases, the left SVC drains into the left atrium thus forming a right to left shunt^[1,2]. This was the case in our patient and we believe a surgical correction of the right to left shunt would have improved his symptoms.

PLSVC is often associated with other congenital cardiac malformations like atrial septal defect, ventricular septal defect, bicuspid aortic valve and coarctation of the aorta^[4,5]. In a study of 17,219 children, Perles et al reported that the odds of having PLSVC among children with a congenital cardiac anomaly are five times higher compared to the children with structurally normal heart^[5].

Literature shows association of PLSVC with extra-cardiac anomalies as well like vertebral defects, anal atresia, renal dysplasia, Tracheo-esophageal fistula, and ear anomalies among many others^[6]. Our patient had unilateral right kidney and cleft lip.

PLSVC is frequently diagnosed incidentally during imaging of the chest or during placement of a central venous catheter when the catheter is seen coursing the left border of the heart with good blood return. Echocardiography, CT or MR angiography are the usual diagnostic tools. A transthoracic echocardiography can pick up a dilated coronary sinus. Likewise, injection of agitated saline through a left sided venous catheter would show air bubble opacification in the coronary sinus, right atrium and right ventricle sequentially whereas injection through right sided catheter would enhance the right atrium first^[7]. However, CT or MR angiography is diagnostic. While evaluating PLSVC, the high possibility of other co-existing cardiac anomalies should always be kept in mind. Thus, a transesophageal echocardiography should be done to confirm any intracardiac shunts.

Surgical correction is the treatment of choice. The basic idea is to divert blood flow to right atrium and various techniques have been described in the literature. The blood flow could be rerouted intra-atrially using a baffle. Likewise, the Left SVC could be end-to-side anastomosed to the right SVC or to right atrium^[8].

An oxygen saturation not improving despite supplemental oxygenation should always make us think about a right to left shunt especially if there is a high A-a gradient on the ABG. This case brings out a type of a right to left shunt which can be easily missed unless specifically searched for.

CONFLICT OF INTERESTS

There are no conflicts of interest with regard to the present study.

REFERENCES

1. Biffi M, Boriani G, Frabetti L, Bronzetti G, Branzi A. Left superior vena cava persistence in patients undergoing pacemaker or cardioverter-defibrillator implantation: a 10-year experience. *Chest* 2001;120:139-44.
2. Perloff JK. Congenital anomalies of vena caval connection. *The Clinical Recognition of Congenital Heart Disease*. 4th ed. Philadelphia:WB Saunders Company; 1994. p.703-14.
3. Erdoğan M, Karakaş P, Uygur F, Meşe B, Yamak B, Bozkir MG. Persistent left superior vena cava: the anatomical and surgical importance. *West Indian Med J*. 2007 Jan;56(1):72-6.

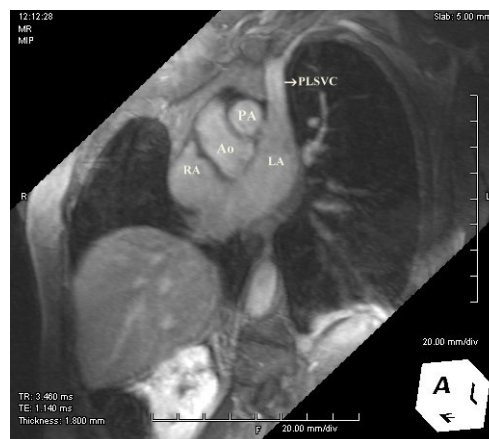

Figure 1 Dark blood MRA of the chest showing a left superior venacava draining into the left atrium. PLSVC: Persistent left superior venacava. Ao: Aorta, PA: Pulmonary artery, LA: Left atrium, RA: Right atrium.

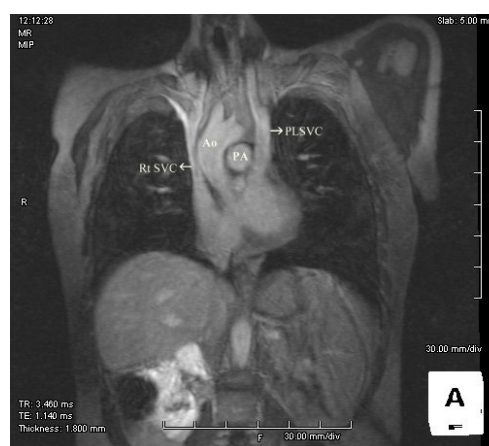


Figure 2 PLSVC drains into the left atrium. Also a diminutive right superior venacava is seen draining into right atrium. PLSVC: Persistent left superior venacava. Ao: Aorta, PA: Pulmonary artery.

4. Marcu CB, Beek AM, van Rossum AC. Unusual variation in upper-body venous anatomy found with cardiovascular MRI. *Canadian Medical Association Journal*. 2006;175(1):27.
5. Perles Z, Nir A, Gavri S, Golender J, Tashma A, Ergaz Z, Rein AJ. Prevalence of persistent superior vena cava and association with congenital heart anomalies. *Am J Cardiol*. 2013 Oct 15;112(8):1214-8.
6. Postema PG, Rammeloo LA, van Litsenburg R, Rothuis EG, Hruda J. Left superior vena cava in pediatric cardiology associated with extra-cardiac anomalies. *Int J Cardiol*. 2008 Jan 24;123(3):302-6.
7. Kim H, Kim JH, Lee H. Persistent left superior vena cava: diagnosed by bedside echocardiography in a liver transplant patient - a case report. *Korean J Anesthesiol* 2014;67(6):429-432.
8. Ugaki S, Kasahara S, Fujii Y, Sano S. Anatomical repair of a persistent left superior vena cava into the left atrium. *Interactive Cardiovascular and Thoracic Surgery* 2010 Aug;11(2):199-201.

Peer reviewers: Gulden Aydogdu Tacoy, Gazi University Faculty Of Medicine, Cardiology Department, Besevler, Ankara, Turkey; Mark M. Tettey, Department of Surgery, Korle Bu Teaching Hospital, National Cardiothoracic Centre, Accra, Ghana; Humberto Manuel Severim de Morais, MD, Cardiology, Hospital Militar Principal/Instituto Superior, Rua Nicolau Gomes Spencer, Ingombotas, Luanda, R. Angola.