

A Rare Case of Mumps Myocarditis

Berous Marion, Lattuca Benoit, Akodad Mariama, Monnin-Bares Valérie, Roubille François

Berous Marion, Lattuca Benoit, Akodad Mariama, Roubille François, Department of cardiology, Arnaud de Villeneuve University Hospita, Montpellier, France

Monnin-Bares Valérie, Department of radiology, Arnaud de Villeneuve University Hospita, Montpellier, France

Correspondence to: François Roubille, Department of cardiology, Arnaud de Villeneuve University Hospita, Montpellier, France
Email: benoit.lattuca@gmail.com

Telephone: +33-467335953

Fax: + 33-467336230

Received: October 11, 2014

Revised: November 4, 2014

Accepted: November 11, 2014

Published online: June 10, 2015

ABSTRACT

“We report the case of a 26-years-old man hospitalized with a typical clinical presentation of Mumps. Indeed, he was admitted for epiglottitis and developed during his hospitalization an orchiepididymitis, a pancreatitis and a rare but well-known complication of this infection: myocarditis confirmed by Cardiac MRI.

© 2015 ACT. All rights reserved.

Key words: Myocarditis; Mumps; Cardiac MRI; MMR vaccine

Berous M, Lattuca B, Akodad M, Monnin-Bares V, Roubille F. A Rare Case of Mumps Myocarditis. *Journal of Cardiology and Therapy* 2015; 2(3): 329-331 Available from: URL: <http://www.ghrnet.org/index.php/jct/article/view/1209>

INTRODUCTION

Mumps is a human viral disease affecting usually the salivary glands, pancreas and testis. Myocarditis is a rare but well-known complication of this infection whose incidence has been reported between 4 to 15 % of the cases of mumps in old series^[1]. We report

the case of mumps myocarditis occurring in a typical presentation of the disease.

CASE REPORT

A 26-years-old man was admitted at hospital to manage an epiglottitis. He had no relevant past medical history except a benign asthma and no recent contact with infected people. The patient consulted for persistent fever to 106°F and right sub- and retro-mandibular adenopathies in spite of antibiotherapy by Amoxicillin/clavulanic acid. Blood analysis revealed an elevation of inflammatory markers: CRP 406 mg/L (normal value<3mg/L), white blood cell count $12 \times 10^9/l$. The cervical computed tomography (CT) scan as well as the nasofibroscope confirmed the epiglottitis diagnosis without necrotic, collected or obstructive complications and associated to latero-cervical localized cellulitis^[1] (Figure 1). An antibiotherapy with metronidazole/cefotaxime was started.

Two day later he complained from left testicular pain associated to a scrotal inflammation consistent with the diagnosis of orchiepididymitis. Moreover the blood analysis showed a lipase elevation to 828 UI/L (normal value<60UI/L) without abdominal pain; an abdominal scan was performed and showed a minor increase in volume of the pancreas without necrotic signs matching with a Balthazar B score pancreatitis. Taken altogether these typical presentations of mumps combining: epiglottitis, orchiepididymitis, pancreatitis and negative blood culture, antibiotherapy was stopped. The patient had been never given the Measles-Mumps-Rubella (MMR) vaccine.

Five day later, he had a retrosternal chest pain increasing with inspiration, electrocardiogram revealed T negative waves in the inferior and apicolateral territory^[2] (Figure 2), high-sensitivity troponin assay was elevated to 585 ng/L (N<14 ng/L) therefore the patient was hospitalized in the intensive care unit of cardiology.

There was no sign of cardiac heart failure. Transthoracic echocardiogram showed normal left ventricular segmental kinetic, volumes and ejection fraction and a minor pericardial effusion of 6mm in diastole near the right ventricle. Myocarditis diagnosis was stated and treatment by colchicin, aspirin and beta-blockers was begun.

Physical activity was prohibited until the next cardiology consultation one month later.

Cardiovascular magnetic resonance imaging (Cardiac-MRI) confirmed the diagnosis of myocarditis showing multiple sub-epicardial and mid-myocardial late enhancement foci in anterior, inferior and apical territories^[3] (Figure 3). All the routine serologies were negative including the mumps serology. However, the methods used in our center may lack of sensitivity if the serology test is realized too early and a negative result does not exclude the diagnosis in cases of strong clinical suspicion.

The evolution was favorable without development of heart failure signs or arrhythmia and the patient was discharged few days later.

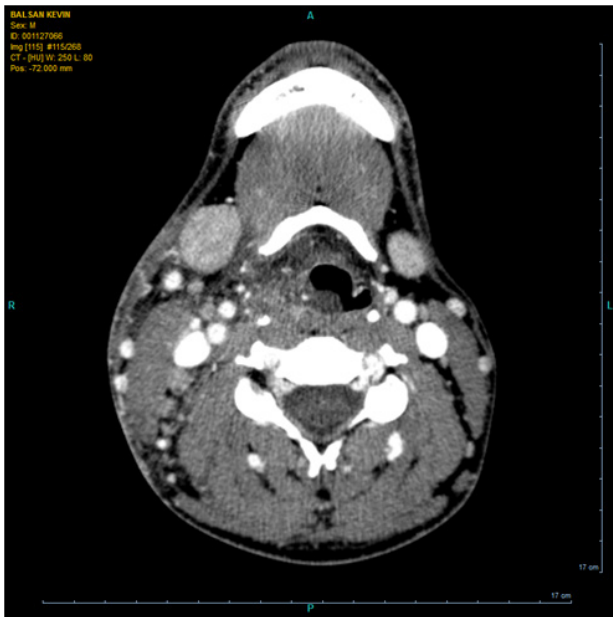

Figure 1 Cervical CT scan: Epiglottitis without necrotic collection or obstructive complications, latero-cervical localized cellulitis.

DISCUSSION

We report here a typical case of mumps associating epiglottitis, orchiepididymitis, pancreatitis and a rare but well-known complication: myocarditis^[2,3]. Pujol suggested for the first time in 1918 that myocarditis could be a complication of mumps. Later, Rosenberg in 1945 described 15% of electrocardiogram abnormalities in the cases of mumps contrasting with 4% for Bengtsson in 1954^[1].

Myocarditis occurs usually in the first week of the disease and electrocardiogram abnormalities disappear few weeks later but can persist in rare cases. Few cases of life-threatening^[4,5] mumps myocarditis are described in the literature: cardiac arrest due to complete atrioventricular block persistent in spite of the medical treatment and requiring pacemaker implantation^[6], cardiogenic shock requiring circulatory assist device^[7], severe left ventricular dysfunction associated with apical thrombus and responsible for systemic emboli, progression to dilated cardiomyopathy^[8,9] and so on. These few cases remain very uncommon and the evolution is generally benign as reported there.

This case underlines the necessity to promote the MMR vaccine generalization in the population that permits to eradicate this disease occurring by seasonal epidemics usually at the end of winter and spring. Indeed very few cases of myocarditis mumps have been reported in the literature in France and Europe in the last ten years probably due to a more frequent vaccination.

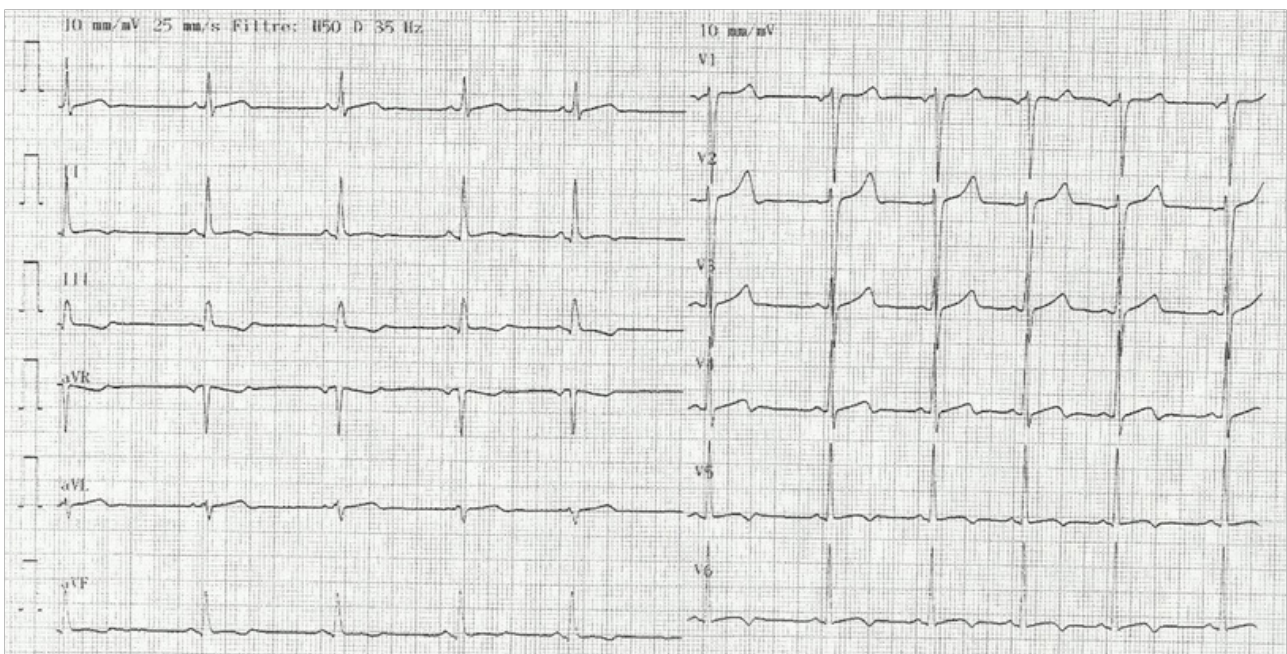


Figure 2 Electrocardiogram: T negative waves in apicolateral and inferior territories.

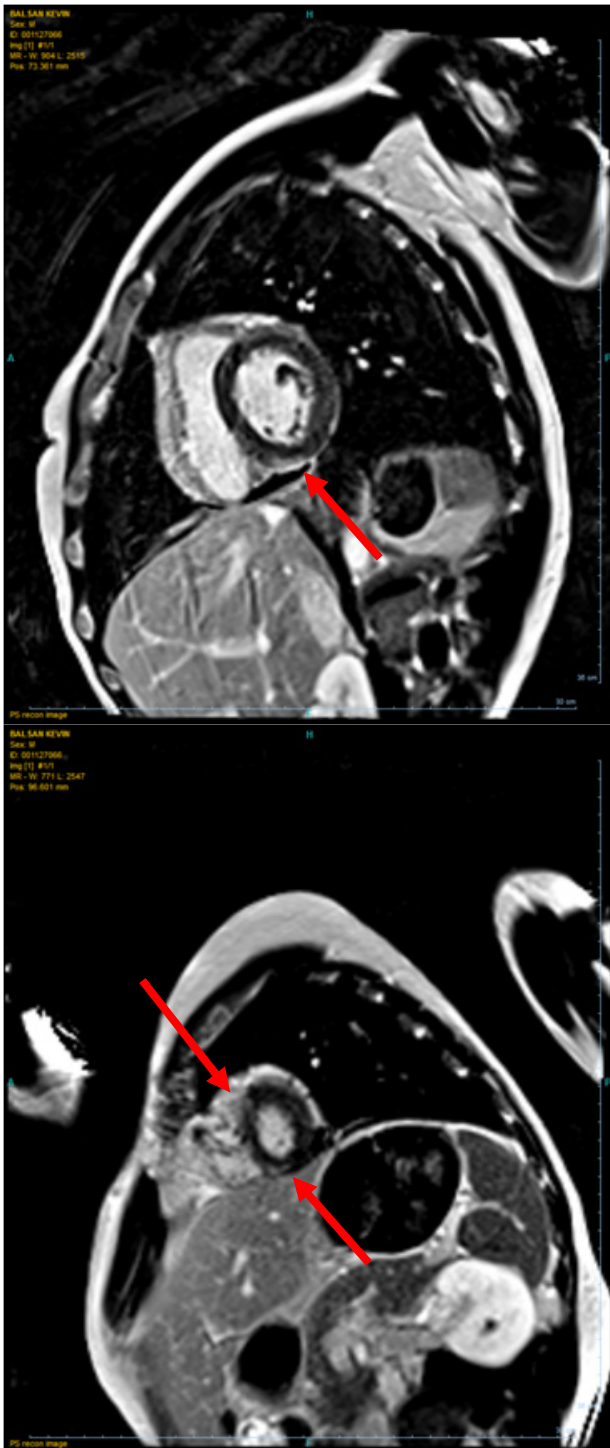


Figure 3 Cardiac MRI: PSIR (Phase Sensitive inversion Recovery) sequences showing multiple sub-epicardial and mid-myocardial late enhancement foci in antero-apical, infero-median and infero-apical territories.

CONFLICT OF INTERESTS

There are no conflicts of interest with regard to the present study.

REFERENCES

1. Bengtsson E, Orndahl G. Complications of mumps with special reference to the incidence of myocarditis. *Acta Med Scand.* 1954;149(5):381-388.
2. Silva ML, Baiao Filho TL, Fernandes VR, Lopes SL, Chang ML. Case report: post-parotitis myocarditis. *J Pediatr (Rio J)* 1996 Sep-Oct; 72(5): 345-8
3. S.C Ward, M.J Wiselka and K.G Nicholson. Still's disease and myocarditis associated with recent mumps infection. *Postgraduate medical Journal* (1988) 64, 693-695
4. Kabadus N, Aydinoglu H, Yekeler H, Arskan IN. Fatal mumps nephritis and myocarditis. *J Trop Pediatr.* 1999 dec; 45(6): 358-60
5. Mohd Shah AS, Sulaiman MD, Saidin N, Maskon O. Fatal perimyocarditis in a migrant worker to the tropics from an unexpected aetiology: a case report. *Journal of Clinical Pathology* 60, no 10 (octobre 2007): 1180-81.
6. M. Arita, Y. Ueno, Y. Masuyama. Complete heart block in mumps myocarditis. *Br Heart J* 1981; 46:432-4
7. Sibat Chaudary, MD, and Brian E. Jaski, MD. Fulminant Mumps Myocarditis. *Annals of Internal Medicine* 1989; 110: 569-570
8. Ni J, Bowles NE, Kim YH, Demmler G, Kearney D, Bricker JT, Towbin JA. Viral infection of the myocardium in endocardial fibroelastosis. Molecular evidence of the role of mumps virus as an etiologic agent. *Circulation* 1997 Jan 7;95(1):133-9
9. Calabrese F, Rigo E, Milanesi O, Boffa GM, Angelini A, Valente M, Thiene G. Molecular Diagnosis of Myocarditis and Dilated Cardiomyopathy in Children: Clinicopathologic Features and Prognostic Implications. *Diagnostic Molecular Pathology: The American Journal of Surgical Pathology, Part B* 11, no 4 : 212-21.

Peer reviewers: Sigita Glaveckaite MD, PhD, Cardiology and angiology centre, Vilnius University hospital Santariskiu klinikos, Santariskiu 2, LT 08661, Vilnius; Lithuania Makram, Department of Infectious Diseases, Hedi Chaker University Hospital, Sfax 3029, Tunisia.