

Multimodality Imaging of an Isolated Pulmonary Native Valve Infective Endocarditis Due to *Staphylococcus Hominis*

Guilhem Malclès, Romain Eschalier, Claire Dauphin, Jean-René Lusson

Guilhem Malclès, Romain Eschalier, Claire Dauphin, Jean-René Lusson, Department of Cardiology, Gabriel Montpied Hospital, Clermont-Ferrand University Hospital, 58 rue Montalembert, 63003 Clermont-Ferrand, cedex 1, France

Romain Eschalier, Jean-René Lusson, Clermont Université, Université d'Auvergne, Cardio Vascular Interventional Therapy and Imaging (CaVITI), Image Science for Interventional Techniques (ISIT), UMR6284, F-63000 Clermont-Ferrand, France

Correspondence to: Guilhem Malclès, MD, Department of Cardiology, Gabriel Montpied Hospital, Clermont-Ferrand University Hospital, 58 rue Montalembert, 63003 Clermont-Ferrand, cedex 1, France

Email: guilhem.malcles@gmail.com

Telephone: +33-473751410 Fax: +33-473754814

Received: November 11, 2014 Revised: December 17, 2014

Accepted: December 18, 2014

Published online: June 10, 2015

ABSTRACT

We report a case of isolated pulmonary native valve infectious endocarditis due to *staphylococcus hominis* in a patient without predisposing factors. Multimodality imaging is essential to diagnose and manage this uncommon clinical entity.

© 2015 ACT. All rights reserved.

Key words: Infective endocarditis; Cardiac imaging techniques; Three-dimensional transesophageal echocardiography; *Staphylococcus hominis*

Malclès G, Eschalier R, Dauphin C, Lusson JR. Multimodality Imaging of an Isolated Pulmonary Native Valve Infective Endocarditis due to *Staphylococcus Hominis*. *Journal of Cardiology and Therapy* 2015; 2(3): 332-333 Available from: URL: <http://www.ghrnet.org/index.php/jct/article/view/1210>

INTRODUCTION

Isolated pulmonary IE is extremely rarely reported^[1,2]. Moreover, the right side heart infectious endocarditis involves the tricuspid valve. The absence of predisposing factors (intravenous drug abuse, alcoholism or catheter related infection) makes difficult an early diagnosis especially in patients without underlying heart disease. Up to 2014, only few cases have been reported.

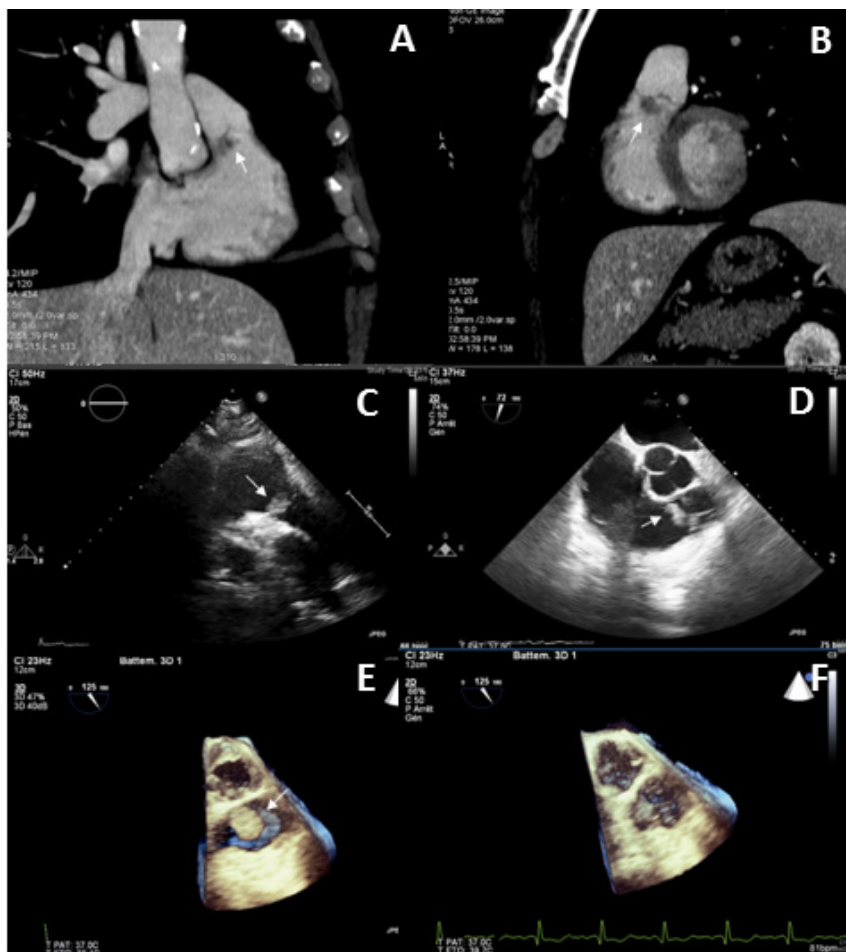
CASE REPORT

A 71-year-old man was admitted because of fever with a 4 kg weight loss during the last 8 weeks. Physical examination on admission was unremarkable with no sign of septic shock; no heart murmur was detected. Biological samples showed an inflammatory anaemia (haemoglobin: 10.3 g/dL, C-Reactive Protein: 37 mg/L, fibrinogen: 6.2 g/L). Because of the fever, a systematic thoracic computed tomography scan was performed. It revealed an unexpected mass in the right ventricular outflow tract, with no lung abscess (Figure 1 A, B). Blood cultures were positive for *staphylococcus hominis* oxacillin sensible. Transthoracic echocardiography (Figure 1 C) showed a vegetation on the ventricular side of a pulmonary valvular leaflet. No valvular mutilation, no significant pulmonary regurgitation and no stenosis were seen. The tricuspid valve was vegetation free.

We confirmed the diagnosis of isolated pulmonary native valve infective endocarditis (IE) by transesophageal echocardiogram (TOE) (Figure 1 D). Three-dimensional (3D) live acquisitions showed a sessil mass attached to a three leaflets pulmonary valve (Figure 1 E, F). An intravenous (IV) antibiotic therapy (gentamycin for 2 days and penicillin M) was given for six weeks, and no cardiac surgery was mandatory. Negative CRP was obtained 3 days later and blood cultures remained sterile 5 days later.

DISCUSSION

Isolated pulmonary endocarditis is an extremely rare entity^[1,2].



Figures A, B: Thoracic computed tomography revealing the mass (arrows) attached to a valvular leaflet in the pulmonary outflow tract. Figure C: Transthoracic echocardiography (parasternal short axis view) confirming the sessile and heterogeneous vegetation (arrow). Figure D: Seventy degree transesophageal echocardiogram view with a vegetation (arrow) in the pulmonary outflow tract. Figure E, F: One hundred twenty five three-dimensional transesophageal echocardiogram view demonstrating a three leaflets normal pulmonary native valve with the vegetation (arrow), and a three leaflets aortic valve above.

Moreover, the right side heart endocarditis involves the tricuspid valve and comes on a specific terrain (drug abuse, IV catheter, cirrhotic). The absence of underlying heart disease makes difficult an early diagnosis^[3,4]. One case is described on a bicuspid pulmonary valve^[5]. The most common pathogens reported are *staphylococcus aureus*, *streptococcus viridans* and coagulase-negative *staphylococcus*^[5]. The involvement of *enterococcus faecalis* is reported in a few cases^[6]. Treatment cannot be based on current guidelines due to the rarity of this pathology. Specific management is needed, usually using antibiotics only. Sometimes surgical management is required to control sepsis. In our case the diagnosis was initially suspected by a thoracic CT scan, before being confirmed by TTE and TOE. As we show here multimodality imaging is required to manage this rare pathology, with the pivotal role of 3D TOE to confirm the absence of structural valvular disease.

List of abbreviations

IE: Infective endocarditis; IV: intravenous; TOE: transesophageal echocardiography; 3D: three-dimensional.

ACKNOWLEDGMENTS

We thank Dr Hakim Lazaar for computed tomography scan.

CONFLICT OF INTERESTS

There are no conflicts of interest with regard to the present study.

REFERENCES

1. Akram M, Khan IA. Isolated pulmonic valve endocarditis caused by group B streptococcus (*Streptococcus agalactiae*)—a case report and literature review. *Angiology*. mars 2001;52(3):211-215.
2. Ramadan FB, Beanlands DS, Burwash IG. Isolated pulmonic valve endocarditis in healthy hearts: a case report and review of the literature. *Can J Cardiol*. oct 2000;16(10):1282-1288.
3. Hamza N, Ortiz J, Bonomo RA. Isolated pulmonic valve infective endocarditis: a persistent challenge. *Infection*. juin 2004;32(3):170-175.
4. Davlourous PA, Polyzogopoulou EV, Syrokosta I, Alexopoulos D, Gogos CA, Manolis AS. Pulmonary valve staphylococcal endocarditis in a nondrug addict with alcoholic cirrhosis. *Int. J. Cardiol*. déc 2004;97(3):575-576.
5. Amonkar GP, Deshpande JR. Infective endocarditis of bicuspid pulmonary valve. *Cardiovasc. Pathol*. avr 2006;15(2):119-120.
6. Gonzalez-Juanatey C, Testa-Fernandez A, Lopez-Alvarez M. Isolated pulmonary native valve infectious endocarditis due to *Enterococcus faecalis*. *Int. J. Cardiol*. 26 oct 2006;113(1):E19-20.

Peer reviewers: Josip Vincelj, MD, PhD, Professor, Department of Cardiology, Dubrava University Hospital, Av. Gojka Suska 6, HR-10000 Zagreb, CROATIA.