

A Massive Intake of Dabigatran: Case-Report and Short Review

Pierre Moronval, Lorraine Legeleux, Sarah Thomann, Jean-François Schved, Jean-Marc Davy, François Roubille

Pierre Moronval, Lorraine Legeleux, Sarah Thomann, Jean-Marc Davy, François Roubille, Department of Cardiology, University Hospital of Montpellier, France

Jean-François Schved, Haematology Laboratory, University Hospital of Montpellier, France

Jean-Marc Davy, François Roubille, PhyMedExp, University of Montpellier, INSERM U1046, CNRS UMR 9214. 34295 Montpellier cedex 5, François

Correspondence to: François Roubille, 371 Avenue du Doyen GASTON GIRAUD, Department of Cardiology, University Hospital of Montpellier, 34 295 Cedex 05, France

Email: francois.roubille@gmail.com

Telephone: +33-788014136 Fax: +33-467336230

Received: December 23, 2014 Revised: January 30, 2015

Accepted: February 5, 2014

Published online: June 10, 2015

© 2015 ACT. All rights reserved.

Key words: Anticoagulant; Dabigatran; Overdose; Massive Intake

Moronval P, Legeleux L, Thomann S, Schved JF, Davy JM, Roubille F. A Massive Intake of Dabigatran: Case-Report and Short Review. *Journal of Cardiology and Therapy* 2015; 2(3): 338-340 Available from: URL: <http://www.ghrnet.org/index.php/jct/article/view/1214>

INTRODUCTION

Consequences of massive intake of non vitamin K oral anticoagulants (NOAC) are not often encountered in a clinical setting. Here, we describe the haemostatic abnormalities after a massive ingestion of dabigatran.

CASE REPORT

A 69-year-old woman was admitted for voluntary massive ingestion of multiple drugs.

Her previous medical history was mainly a depression with four suicide attempts including one past event with 10 pills of dabigatran 150 mg. She also complained from atypical chest pain with normal coronary angiograms in December 2004, palpitations without documented arrhythmia in 2004 treated by fluindione and amiodarone, hypertension, and recurrent superficial phlebitis (of sural right leg in December 2008 and of a dorsal vein of the right foot in April 2011). Fluindione was replaced by acetylsalicylic acid then by dabigatran after a transient ischemic event in 2012 because of presumed atrial fibrillation. Neither thrombophilia nor constitutional or acquired biological abnormality was found in 2009.

The patient was found unconscious in a hotel room after ingestion of 60 pills of dabigatran 150mg, 80 pills of neбиволол 5 mg, 60 pills of diazepam 10 mg and 60 pills of amitriptyline 25 mg. The patient had a Glasgow coma scale score of 3 and was therefore immediately intubated and hospitalized in intensive care unit.

Despite the massive dose of dabigatran ingested the patient did not suffer from any bleeding events. Norepinephrin and isoprenalin

ABSTRACT

Objective: The toxicity profile of new oral anticoagulants is well established and with their increasing use the adverse events are frequently encountered in clinical practice. Here, we describe the haemostatic abnormalities after a massive ingestion of dabigatran.

Case summary: A 69-year-old woman was admitted for suicidal attempt after ingestion of 9 grams of dabigatran (60 x 150mg pills), associated with 400 mg of neбиволол, 600 mg of diazepam and 1.5 grams of amitriptyline. The patient did not suffer from any bleeding events. Only few voluntary massive intakes are until now reported.

Discussion: There are only few cases reporting such a massive voluntary intake of dabigatran leading to biological disorders contrasting with no clinically significant intake. This surprising absence of bleeding events in our case could be at least partly explained by the poor gastrointestinal intake of the drug, a functional gastroparesis, and a theoretically self-limiting biological effect.

Conclusion: As no antidote is currently available in routine use for dabigatran, a systematic collection of cases of dabigatran toxicity provide an insight into the clinical manifestations and potential therapeutic implications.

were initiated for the initial 72 hours for pressor support. The patient was extubated quickly on the first day but suffered from pulmonary lesions of the right base treated by amoxicilline/clavulanic acid. Two days later, she was admitted to the cardiology intensive care unit. She had a psychomotor retardation without tachypnea or signs of respiratory distress. Importantly no bleeding was noticed during the hospitalization stage. The ECG was normal five days after the admission, with a 72 bpm sinus rhythm.

On admission the blood cell count was normal. Coagulation tests were modified: thrombin clotting time at 52.6 seconds for the patient and 10.8 seconds for the control, factor II < 1%, factor V 5%, factor VII 42 %, factor X 33 %, and activated partial thromboplastin time (APTT) above 150 seconds. Concentration of dabigatran was first quite low (256 ng/mL, 10h after the ingestion, then increased at first day (400 ng/mL) and finally diminished dramatically (undetectable at discharge a few days later) (Figure 1). Thrombin clot time gradually increased in the following days (Figure 1). By contrast, APTT decreased slowly (Figure 1). A transthoracic echocardiography at discharge was normal except for moderate mitral regurgitation. Noticeably, the patient did not benefit from hemodialysis or gastric lavage/ charcoal treatment for acute poisoning.

Given the massive ingestion, treatment was collegially re-evaluated. Dabigatran and nebulol were discontinued at discharge.

DISCUSSION

Here, we report a rare case of suicide attempts by using large amounts of direct anticoagulants.

Dabigatran is an orally active direct thrombin inhibitor, has been recently approved for stroke prophylaxis in patients with atrial fibrillation, prevention of venous thromboembolism (VTE) after hip surgery and treatment of acute VTE. Formulations available include 75 mg, 110 mg and 150 mg capsules with standard therapy being 150 mg twice daily. As regards to normal pharmacodynamics, the plasma concentration is maximal after 1 to 3 h, protein-binding is 35 %, half-life is 12-17h depending on patient GFR, and elimination is primarily through renal excretion (~85 % via urine). The pro-drug is converted to the active form through in vivo plasma and hepatic enzymes and reversibly inhibits thrombin, the final step in the coagulation cascade^[1].

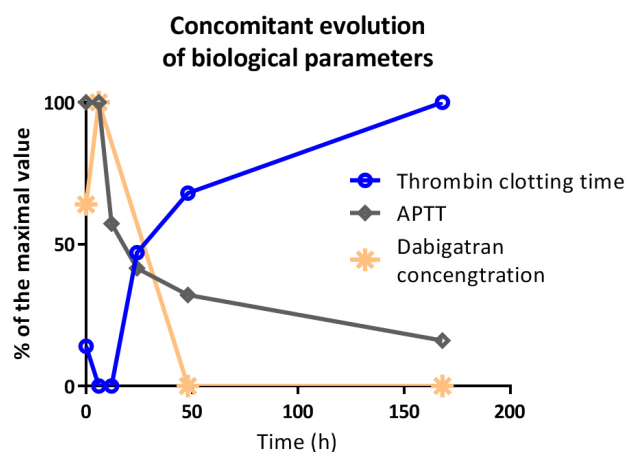


Figure 1 Concomitant evolutions of thrombin clotting time (blue), APTT (grey) and dabigatran concentrations (orange). Values are expressed as percentages of maximal values. APTT: activated partial thromboplastin time.

There have been various documented cases of dabigatran-related bleeding complications, including intracranial haemorrhages, postoperative bleeding complications, and significant gastrointestinal bleeding. Taken altogether these aspects and the favourable results in the main studies, the drug appears to be at least as safer as anti-vitamin K oral anticoagulants^[2]. The purpose of this case report is to describe a patient with acute, intentional dabigatran massive intake without any clinically significant bleeding event.

There are only few reported cases of intoxications with high doses of dabigatran. One patient took various drugs including 11 g of dabigatran^[3]. A 66-year-old male presented following a poly-pharmacy overdose of dabigatran in combination with metoprolol, amlodipine, olmesartan, and moxonidine. Extracorporeal elimination followed by continuous veno-venous hemodiafiltration was implemented and was preferred over intermittent hemodialysis as the patient developed worsening biological coagulopathy, renal impairment and was hemodynamically unstable.

In another case report, a 57-year-old woman with a medical history of depression and atrial fibrillation had taken 11.25 g of dabigatran in a suicide attempt^[4]. Despite an ecchymosis indicative of prior trauma, there was no evidence of acute bleeding. On presentation, dabigatran blood levels measured 970 ng/mL and thrombin clot times measured above the testable limits (>120 s) until 52 h post-arrival. By contrast she presented with no additional clinically significant outcomes.

Importantly, several case reports are collected in a poison control center in California. From January 2011 to July 2013^[5] a total of 56 cases were identified, with 7 ultimately excluded, leaving 37 dabigatran and 12 rivaroxaban cases. Among all of them, there were only 4 cases of acute self-harm overdose with dabigatran ranging from 1800 to 3900 mg. Mild bleeding was reported in only one of these overdose cases. Coagulation parameters did not correlate well with bleeding.

As far as we know, there are only few cases reporting such a massive voluntary intake of dabigatran leading to biological disorders contrasting with no clinically significant intake. This surprising effect could be at least partly explained by the poor gastrointestinal intake of the drug^[6]. Secondly in case of various drugs massive intake and all the more as hemodynamic is usually compromised, a functional gastroparesis is very likely. Third a self-limited biological effect could be advocated. Finally, as a prodrug, the normal relationship from prodrug to drug could be largely slowed. These pathophysiological explanations should deserve to be explored and only cautious evaluation in case of massive intake could provide additional data.

CONCLUSION

Although no antidote is currently available in routine use as regards dabigatran, only few voluntary massive intakes are reported. A systematic collection of cases is mandatory to show whether bleeding complications are life-threatening or surprisingly limited, in order to help physicians with clinical decisions. Obviously favourable evolution as reported here could be only exceptional and such overdoses have to be managed carefully.

CONFLICT OF INTERESTS

There are no conflicts of interest with regard to the present study.

REFERENCES

1. Eriksson BI, Quinlan DJ, Weitz JI. Comparative pharmacodynamics and pharmacokinetics of oral direct thrombin and factor xa inhibitors

Moronval P *et al.* A massive ingestion of dabigatran

- in development. *Clinical pharmacokinetics*. 2009;48:1-22
2. Connolly SJ, Ezekowitz MD, Yusuf S, Eikelboom J, Oldgren J, Parekh A, Pogue J, Reilly PA, Themeles E, Varrone J, Wang S, Alings M, Xavier D, Zhu J, Diaz R, Lewis BS, Darius H, Diener HC, Joyner CD, Wallentin L, Committee R-LS, Investigators. Dabigatran versus warfarin in patients with atrial fibrillation. *The New England journal of medicine*. 2009;361:1139-1151
 3. Chiew AL, Khamoudes D, Chan BS. Use of continuous venovenous haemodiafiltration therapy in dabigatran overdose. *Clinical toxicology*. 2014;52:283-287
 4. Woo JS, Kapadia N, Phanco SE, Lynch CA. Positive outcome after intentional overdose of dabigatran. *Journal of medical toxicology: official journal of the American College of Medical Toxicology*. 2013;9:192-195
 5. Stevenson JW, Minns AB, Smollin C, Albertson TE, Cantrell FL, Tomaszewski C, Clark RF. An observational case series of dabigatran and rivaroxaban exposures reported to a poison control system. *The American journal of emergency medicine*. 2014
 6. Tripodi A. The laboratory and the new oral anticoagulants. *Clinical chemistry*. 2013;59:353-362

Peer reviewers: Amir Shaikh, MD, University of Massachusetts Medical School, Tri-River Clinic, 281 E, Hartford Ave, Uxbridge, MA 01569, USA.