

Role of Myocardial Strain Imaging in Chemotherapy Related Cardiotoxicity

Adedotun Anthony Ogunsua, Amartya Kundu, Amir Y. Shaikh

Adedotun Anthony Ogunsua, Amartya Kundu, Amir Y. Shaikh, Department of Medicine, University of Massachusetts Medical School, 55 Lake Avenue North, Worcester, MA 01655, USA
Correspondence to: Amir Y. Shaikh, MD, Assistant Professor, Department of Medicine, University of Massachusetts Medical School, 55 Lake Avenue North, Worcester, MA 01655, USA
Email: shaikha@ummhc.org
Telephone: +1-508-278-5573 Fax: +1-508-278-0347
Received: March 5, 2015 Revised: March 30, 2015
Accepted: April 3, 2015
Published online: August 10, 2015

Cardiology and Therapy 2015; 2(4): 345-349 Available from: URL: <http://www.ghrnet.org/index.php/jct/article/view/1132>

INTRODUCTION

Over the past few decades, there has been significant advancement in the field of oncology with new chemotherapeutic agents being developed at an exponential rate. Many of these effective anti-neoplastic chemotherapeutic agents have well recognized short and long-term cardiotoxicity^[1,2]. Cardiotoxicity resulting from targeted cancer therapy is more common than originally thought^[1]. Cardiac side effects related to many newer agents were, in many instances, not fully appreciated because of the way in which cardiac surveillance has traditionally been conducted. Robust data are lacking on the optimal strategy for surveillance and treatment of chemotherapy-related cardiotoxicity^[2].

Guidance from major cardiology societies, including the American Heart Association, the American College of Cardiology, and the Heart Failure Society of America are limited and based on expert opinion and observational studies^[1]. A burgeoning cardio-oncology field has emerged recently to manage the cardiac side effects of these increasingly sophisticated chemotherapy agents. The aim of this review is to elucidate the role of myocardial strain imaging in chemotherapy related cardiotoxicity.

CHEMOTHERAPY RELATED CARDIOTOXICITY

Different chemotherapeutic agents have been associated with cardiotoxicity. A brief overview of such chemotherapeutic agents is listed in table 1^[3].

The most effective treatment for chemotherapy-induced cardiotoxicity is likely prevention^[3]. Much current effort in the realm of cardioprotection focuses on the early detection of left ventricular (LV) impairment, either by noninvasive imaging modalities such as echocardiography or with circulating biomarkers. The rationale for

ABSTRACT

With an increase in the survival rate and longevity of cancer patients and rapid development of novel anti neoplastic agents, there have been growing concerns about the potential long-term side effects of these drugs. Cardiotoxicity resulting from targeted chemotherapy is a common adverse effect encountered in clinical practice. Traditionally, the cardiac side effects of chemotherapeutic agents have been evaluated primarily by measurement of reduction in systolic function of the heart by assessment of left ventricular ejection fraction (LVEF). Recently, there has been increasing emphasis on earlier and more accurate prediction of cardiotoxicity using imaging modalities besides evaluation of LVEF. Such methods include myocardial strain imaging. We present a review elaborating the role of myocardial strain imaging in chemotherapy related cardiotoxicity.

© 2015 ACT. All rights reserved.

Key words: Chemotherapy; Cardiotoxicity; Speckle tracking; Myocardial strain; Heart failure

Ogunsua AA, Kundu A, Shaikh AY. Role of Myocardial Strain Imaging in Chemotherapy Related Cardiotoxicity. *Journal of*

Table 1 Chemotherapeutic agents implicated in cardiotoxicity Reproduced with permission from Shaikh AY, Shih JA. Chemotherapy-induced diotoxicity. *Curr Heart Fail Rep.* 2012; 9(2): 117-127

Condition	Agent	Incidence %	Mechanism of cardiotoxicity	Clinical features	Cancers used in Breast cancer,	Comments
Left ventricular dysfunction	Anthracyclines		ROS damaging DNA,	Acute, early onset	sarcoma,	Doxorubicin analogues
	Doxorubicin	3-26	apoptosis,	chronic progressive,	lymphoma, MM,	
	Epirubicin	0.9-3.3	cardiomyocyte	late-onset chronic	ALL,	have significantly
	Idarubicin	5-18	death, sarcopenia,	progressive. Dilated	Wilm’s tumor,	lower risk of
	Liposomal doxorubicin	6-13	other	cardiomyopathy and HF, other	hepatoblastoma	cardiotoxicity
	Anthraquinone					
	Mitoxantrone					
	Alkylating agents					
	cyclophosphamide	7-28	Direct endothelial	Pericardial effusion,	Lymphoma, bone	Acute cardiotoxicity,
	ifosfamide	17	injury	myopericarditis, HF	marrow transplant regimens	relatively high mortality, no long-term effects
	Taxanes					
	Docetaxel	2.3-8	? Microtubule inhibition	HF	Breast cancer	
	TKI: Monoclonal Ab					
	Trastuzumab (Herceptin a)	2-28	HER2/ErB2 inhibition	Reduced EF, HF	Breast cancer	Usually reversible
	Bevacuzimab (avastin a)	1.7-3	VEGF inhibition	Uncontrolled HTN	Breast cancer	HF due to LV pressure overload
	TKI Small molecules					
	Sunitinib	2.7-11	Off-target inhibition of		CML, ALL, GIST,	Several agents in
	Dasatinib	2-4	kinases (e.g., AMPK).	Reduced EF, HF,	RCC,	pipeline, long-term and
Imatinib mesylate	0.5-1.7	On-target c-Abl inhibition	HTN	breast cancer,	large populationbased	
Lapatinib	1.5-2.2			NSCLC	studies required, usually lifelong therapy	
Antimetabolites						
Clofarabine	27		Transient LVD	ALL		
Proteasome inhibitor				MM		
Bortezomib	2-5		HF			
Hypertension	TKI: Monoclonal Ab					
	Bevacuzumab(Avastin)	4-35	VEGF inhibition	HTN, HF	Breast, colon	
	TKI Small molecules					
	Sorafenib	17-43		HTN	RCC, HCC	
Sunitinib	5-47					

ROS reactive oxygen species; HF heart failure; MM multiple myeloma; ALL acute lymphoblastic leukemia; TKI tyrosine kinase inhibitor; Ab antibodies; HER2/ErB2 human epidermal growth factor receptor 2; EF ejection fraction; VEGF vascular endothelial growth factor; HTN hypertension; LV left ventricular; AMPK adenosine monophosphate-activated protein kinase; CML chronic myeloid leukemia; GIST gastrointestinal stromal tumors; RCC renal cell carcinoma; NSCLC non-small cell lung cancer; LVD left ventricular dysfunction; RCC renal cell carcinoma; HCC hepatocellular cancer
 a Manufactured by Genentech, Inc., South San Francisco, CA

such a strategy is that early recognition of sub-clinical ventricular dysfunction permits an intervention: either modification to chemotherapy, institution of a cardioprotective agent to ameliorate or prevent cardiotoxic manifestations, or early aggressive heart failure management to prevent further clinical progression^[1]. There is evidence that the potential for cardiac recovery may decrease significantly with longer time to detection^[4].

MYOCARDIAL IMAGING MODALITIES

The most common noninvasive method of monitoring myocardial toxicity has been the assessment of left ventricular systolic function, with either radionuclide angiography or echocardiography, but it is not sensitive for early detection of subclinical cardiac disease^[5]. Radionuclide angiography is noninvasive, making it an attractive option for routine clinical monitoring. However, the pitfalls of radionuclide angiography include the lack of information other than ejection fraction; and the radiation exposure. Echocardiography, which is also noninvasive, can identify both systolic and diastolic dysfunction, as well as valvular and pericardial disease^[6].

Traditionally, for the purpose of surveillance chemotherapy-related cardiotoxicity has been defined as a drop in left ventricular ejection fraction (LVEF) of > 10% or a LVEF <50% in the presence or

absence of symptoms of heart failure (HF)^[3].

Recently 2D and 3D Speckle Tracking Echocardiography (STE) have emerged as new modalities for the evaluation of regional and global cardiac function in different clinical scenarios^[7]. Speckles are dots or groups of pixels created via the interaction between the myocardium and ultrasonographic waves. They have specific characteristics and the ability to track them throughout the cardiac cycle is the basis of the speckle tracking echocardiography (STE)^[8] (Figure 1). Strain is the percentage thickening or deformation of the myocardium during the cardiac cycle. It is the measurement of an object when an external force is applied. Strain calculation could be either langragian or natural. Langragian represents a deformation from its original length while natural is the deformation relative to original length at a previous point in time^[9]. Strain can either indicate lengthening, in which case it is positive, or shortening, in which case it is negative. Longitudinal strain is the percentage decrease in the length of the myocardium from apex to base during systole. Radial and transverse strain are measures of thickening of the myocardium during the inward movement of the ventricle. Circumferential strain measures the change in length along the circumference of the left ventricle during systole. Strain rate is the rate of deformation per unit time. The strain rate has the same direction as the strain and is positive during lengthening and negative during shortening^[10].

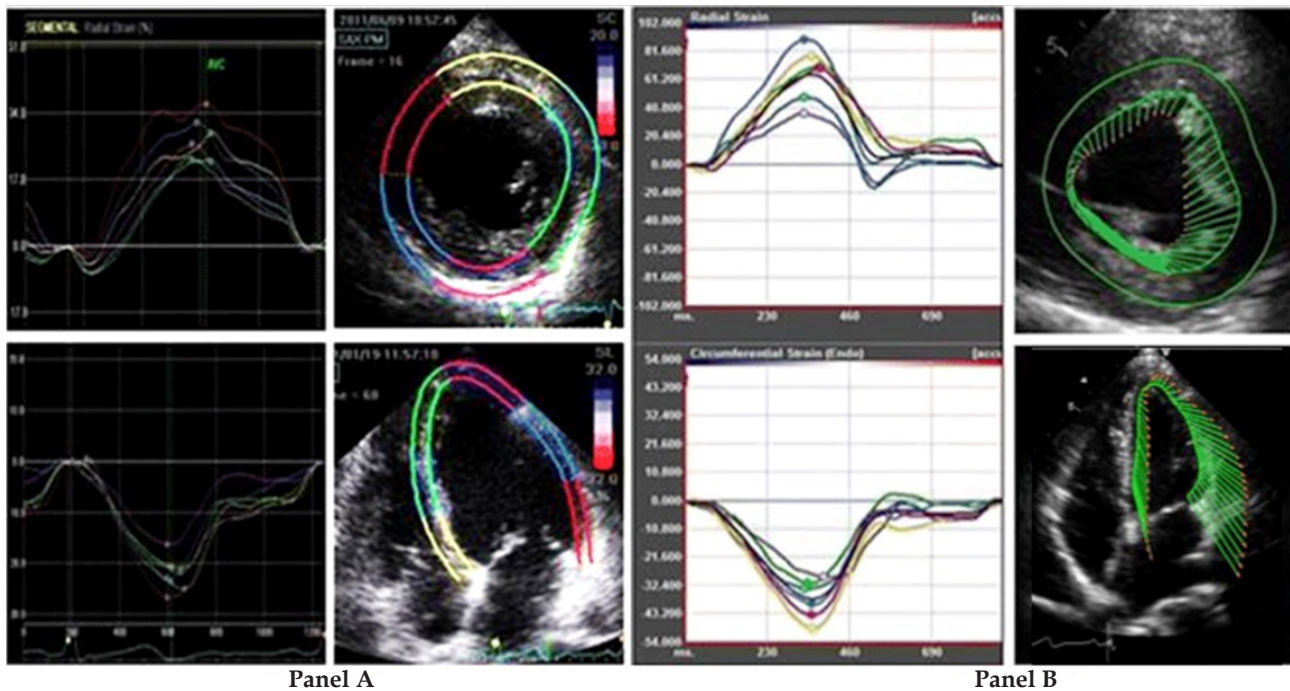


Figure 1 Strain imaging modalities. Panel A: Speckle tracking imaging based on tracking speckles throughout the myocardium. (Short axis view shown in the upper half and apical four-chamber view shown in the lower half, with respective strain measurements). Panel B: Vector velocity imaging based on tracking the endocardium. (Short axis view shown in the upper half and apical four-chamber view shown in the lower half, with respective strain measurements).

Dyssynchrony occurs when the normal ventricular activation sequence is disrupted, resulting in incoordination of left ventricular segments. Those segments that contract early do not contribute to ejection of blood from the left ventricle while those that contract late, do so at a higher wall stress. This leads to a decline in systolic function and mechanical efficiency. During systole there is a twisting motion of the ventricles. This motion is maximal at the apex and minimal at the base. Torsion is defined as the net difference between the apical and base rotations during systole. Typically the base rotates clockwise while the apex rotates counterclockwise when viewed from the apex^[11].

Rotation refers to myocardial rotation along the long axis of the left ventricle. Rotation is expressed in degrees^[12]. Twist, also expressed in degrees, is the absolute difference in apex to base rotation. Strain rate is the rate of change in rate and is expressed as 1/sec^[12]. Displacement is the measurement of the distance that a speckle has moved between two consecutive frames. It is measured in centimeters. The advantage of strain and strain rate over displacement is the reflection of regional function, which is independent of translational motion.

Global strain represents an average of all the strain measurements^[8]. Acquisition of strain images is not much different from conventional echocardiography. Images are acquired during the end expiration of a breath-holding episode. Apical four chamber, two chamber, and three chamber views are used for estimation of longitudinal and transverse strain, strain rate, time to peak strain, and dyssynchrony. Longitudinal strain is considered to be the most robust and reproducible of all the parameters. The STE derived strain pattern correlates well with Tissue Doppler Imaging (TDI) derived strain pattern. Longitudinal strain is used in most outcomes because the sub-endocardial fibers are the most vulnerable in many disease processes. Radial and circumferential strains are more sensitive than segmental wall motion abnormalities as the latter is visually assessed

subjectively. As the disease process worsens, all strain parameters are affected. It has been shown that the global radial strain from 2D echo detected early doxorubicin induced cardiomyopathy and the reduction in radial strain is associated with the onset and degree of histological damage^[13].

The advantage of 3D over 2D STE is enhanced by the fact that the larger pyramidal volume enhances better capture of the speckles during all phases of the cardiac cycle, which is not evident in 2D STE. Acquisition of images during a single cardiac beat also enables evaluation of patients with arrhythmias. In addition, 3D STE enables evaluation of area strain, which is a combination of longitudinal and circumferential strain. The simultaneous acquisition of images of the basal and apical segments is only possible in 3D, which is more time-efficient. A major disadvantage of 3D STE is that it has not yet been validated, especially in chemotherapy related cardiotoxicity.

In Tissue Doppler Imaging (TDI), doppler techniques are used to quantify wall motion velocity. TDI can be performed in pulsed wave and color modes. Pulsed wave is particularly useful for measurement of peak myocardial velocities because the endocardial fibers are parallel to the ultrasound waves in the apical view. As such, mitral annular motion is used as an estimate for left ventricular contraction and relaxation. Color TDI has the ability to view multiple structures and segments in one view and is created by superimposition of color-coded myocardial velocities on 2D images, which indicate the direction, and velocity of myocardial motion. TDI is not able to differentiate active from passive motion and is only able to measure velocities that are parallel to the echocardiographic waveforms^[14]. Velocity vector tracking (VVI) is a novel imaging based on 2D speckle tracking, and combines speckle tracking and endocardial contour tracking^[9,15]. VVI allows angle independent measurement of strain.

APPLICATIONS OF STRAIN IMAGING

Predictors of early cardiac toxicity

Longitudinal and radial strain rates predict cardiotoxicity before reduction in EF in patients treated with chemotherapy agents^[16]. Kang *et al* demonstrated that in patients with Non-Hodgkins lymphoma, decrease in longitudinal strain between initiation and the completion of the third cycle of an anthracycline based chemotherapy, was the best predictor of future development of cardiotoxicity in a multivariable model including sex, age, hypertension, smoking history, radial strain, cardiac troponin T, left ventricular mass, left ventricular diameter and left atrial diameter^[17]. Also, similar results were found in HER2 positive breast cancer patients who were initially treated with anthracycline, followed by taxanes and then by trastuzumab^[18]. Majority of patients (53%) with at least 19% reduction in peak systolic longitudinal strain after anthracycline treatment developed cardiotoxicity. A decrease of at least 10% in peak systolic longitudinal strain between initial and third dose of anthracycline was a statistically significant predictor of later development of cardiotoxicity ($p=0.01$). Of note, elevations in cardiac troponin I of $\geq 30\text{pg/mL}$ after completion of the anthracycline dose was also indicative of subsequent cardiotoxicity and achieved statistical significance ($p=0.04$). These results could be explained by the observation that chemotherapy induced myocardial damage is a regional effect of which longitudinal strain is a better indicator^[17].

Also, the subendocardium is the most vulnerable aspect of the myocardium due to left ventricular mechanics and is therefore most prone to damage as indicated by the elevation in cardiac troponin. This observation is buttressed by the fact that in the same study, an elevation in pro-BNP did not predict subsequent development of cardiotoxicity^[18]. Additionally, decrease in global systolic strain occurs as early as 7 days after anthracycline chemotherapy in HER2 negative breast cancer patients and also 6 months following treatment, while EF did not change over the same period of time^[19]. This lends further support to the role of myocardial strain imaging as an early predictor of cardiotoxicity and for monitoring of systolic function following chemotherapy.

In a long term follow up of patients treated with trastuzumab and anthracycline, longitudinal strain was reduced in chemotherapy group compared to a control group while there was no difference in radial strain. Longitudinal strain reductions were found in the septal, lateral, anterior and posterior walls when compared to the control group. Smoking was a significant predictor of longitudinal strain reduction in patients that received trastuzumab therapy^[20]. In a different population treated for solid organ tumors, an index comprising of the global longitudinal strain and left ventricular twist deformation performed better than other strain measurements in predicting future cardiotoxicity in patient treated with anthracycline^[21].

Predictors of late cardiac toxicity

There have been few studies in cancer survivors that predict subsequent development of cardiovascular events such as heart failure. Most such studies have been in the pediatric population cancer survivors. Using TDI based strain imaging, there was detection of a reduction in the longitudinal strain rate in the interventricular septum, left ventricular lateral wall and right ventricular free wall in survivors of anthracycline based chemotherapy compared to a control population up to 4 years post therapy. This difference in strain rate holds despite different anthracycline regimens, suggesting that the late effect of anthracycline is not dose dependent. Similar results were reproduced using STE showing a reduction in strain of up to

6% compared to control population. Furthermore, with 3D STE there has been shown to be reductions in global systolic strain, twist and torsion compared to control population. Shortfall of studies examining prediction of late effects of chemotherapeutic agents is the absence of baseline strain imaging to compare pre and post results and therefore it is not evident if these patient population already have deformation at baseline^[22].

CONCLUSION

Novel, non-invasive and inexpensive imaging modalities like speckle tracking imaging and velocity vector imaging can be utilized in measuring strain variables of the myocardium for surveillance of chemotherapy related cardiotoxicity. Further large studies are needed to further validate and leverage the role of strain variables as predictors of short- and long-term specific chemotherapeutic agent related cardiotoxicity.

CONFLICT OF INTERESTS

There are no conflicts of interest with regard to the present study.

REFERENCES

- 1 Shaikh AY, McGuinness ME, Shih JA. Cardiovascular toxicity of Newer chemotherapeutic agents: the heart of the matter. *Oncology (Williston Park)*. 2014;28(6):493-496.
- 2 Eschenhagen T, Force T, Ewer MS, et al. Cardiovascular side effects of cancer therapies: a position statement from the Heart Failure Association of the European Society of Cardiology. *Eur J Heart Fail* 2011; 13:1–10.
- 3 Shaikh AY, Shih JA. Chemotherapy-induced cardiotoxicity. *Curr Heart Fail Rep*. 2012; 9(2):117-27.
- 4 Cardinale D, Colombo A, Lamantia G, et al. Anthracycline-induced cardiomyopathy: clinical relevance and response to pharmacologic therapy. *J Am Coll Cardiol*. 2010;55(3):213-20.
- 5 Albin A, Pennesi G, Donatelli F, et al. Cardiotoxicity of anticancer drugs: the need for cardio-oncology and cardio-oncological prevention. *J Natl Canc Inst*. 2010;102(1):14–25.
- 6 Ganz WI, Sridhar KS, Ganz SS, et al. Review of tests for monitoring doxorubicin-induced cardiomyopathy. *Oncology*. 1996; 53:461–70.
- 7 Solomon SD, Janardhanan R, Verma A, et al. Effect of angiotensin receptor blockade and antihypertensive drugs on diastolic function in patients with hypertension and diastolic dysfunction: a randomized trial. *Lancet* 369:2079–2087.
- 8 Biswas M, Sudhakar S, Nanda NC, et al. Two- and three-dimensional speckle tracking echocardiography: clinical applications and future directions. *Echocardiography*. 2013; 30(1):88-105.
- 9 Hoit BD. Strain and strain rate echocardiography and coronary artery disease. *Circ Cardiovasc Imaging*. 2011;4(2):179-90.
- 10 Dandel M, Lehmkühl H, Knosalla C, Suramelashvili N, Hetzer R. Strain and strain rate imaging by echocardiography - basic concepts and clinical applicability. *Curr Cardiol Rev*. 2009;5(2):133-48.
- 11 Shaw SM, Fox DJ, Williams SG. The development of left ventricular torsion and its clinical relevance. *Int J Cardiol*. 2008;130(3):319-25.
- 12 Mor-Avi V, Lang RM, Badano LP, et al. Current and evolving echocardiographic techniques for the quantitative evaluation of cardiac mechanics: ASE/EAE consensus statement on methodology and indications endorsed by the Japanese Society of Echocardiography. *Eur J Echocardiogr*. 2011;12(3):167-205.
- 13 Migrino RQ, Aggarwal D, Konorev E, Brahmabhatt T, Bright M,

- Kalyanaraman B. Early detection of doxorubicin cardiomyopathy using two-dimensional strain echocardiography. *Ultrasound Med Biol.* 2008;34(2):208-14.
- 14 Ho CY, Solomon SD. A clinician's guide to tissue Doppler imaging. *Circulation.* 2006;113(10):e396-8.
 - 15 Azam S, Desjardins CL, Schluchter M, et al. Comparison of velocity vector imaging echocardiography with magnetic resonance imaging in mouse models of cardiomyopathy. *Circ Cardiovasc Imaging.* 2012;5(6):776-81.
 - 16 Migrino RQ, Aggarwal D, Konorev E, Brahmabhatt T, Bright M, Kalyanaraman B. Early detection of doxorubicin cardiomyopathy using two-dimensional strain echocardiography. *Ultrasound Med Biol.* 2008;34(2):208-14.
 - 17 Kang Y, Xu X, Cheng L, et al. Two-dimensional speckle tracking echocardiography combined with high-sensitive cardiac troponin T in early detection and prediction of cardiotoxicity during epirubicin-based chemotherapy. *Eur J Heart Fail.* 2014;16(3):300-8.
 - 18 Sawaya H, Sebag IA, Plana JC, et al. Assessment of echocardiography and biomarkers for the extended prediction of cardiotoxicity in patients treated with anthracyclines, taxanes, and trastuzumab. *Circ Cardiovasc Imaging.* 2012;5(5):596-603.
 - 19 Stoodley PW, Richards DA, Boyd A, et al. Left ventricular systolic function in HER2/neu negative breast cancer patients treated with anthracycline chemotherapy: a comparative analysis of left ventricular ejection fraction and myocardial strain imaging over 12 months. *Eur J Cancer.* 2013; 49(16):3396-403.
 - 20 Ho E, Brown A, Barrett P, et al. Subclinical anthracycline and trastuzumab induced cardiotoxicity in the long-term follow-up of asymptomatic breast cancer survivors: a speckle tracking echocardiographic study. *Heart.* 2010;96(9):701-7.
 - 21 Mornoş C, Petrescu L. Early detection of anthracycline-mediated cardiotoxicity: the value of considering both global longitudinal left ventricular strain and twist. *Can J Physiol Pharmacol.* 2013; 91(8):601-7.
 - 22 Thavendiranathan P, Poulin F, Lim KD, Plana JC, Woo A, Marwick TH. Use of myocardial strain imaging by echocardiography for the early detection of cardiotoxicity in patients during and after cancer chemotherapy: a systematic review. *J Am Coll Cardiol.* 2014; 63(25 Pt A):2751-68.
- Peer reviewer:** Francesco Giallauria, MD, PhD, Department of Translational Medical Sciences, Cardiac Rehabilitation Unit, University of Naples "Federico II", Via S. Pansini 5, 80131 - Naples (NA), Italy.