

Role of 123-Iobenguane Myocardial Scintigraphy in Predicting Short Term Left Ventricular Functional Recovery and Indication to ICD Implantation after Coronary Revascularization: A Work Hypothesis

Testa Marzia, Chauvie Stephane, Biggi Alberto, Terulla Alessandra, Feola Mauro

Testa Marzia, Feola Mauro, Department of vascular Rehabilitation-Heart Failure Unit, Ospedale SS Trinita' Fossano, Italy

Chauvie Stephane, Biggi Alberto, Terulla Alessandra, Department of Nuclear Medicine Service, Ospedale S Croce-Carle Cuneo, Italy

Correspondence to: Mauro Feola MD, FESC, Department of Cardiovascular Rehabilitation-Heart Failure Unit, Ospedale SS Trinita', Via Ospedale 4 12045, Fossano (CN), Italy

Email: m_feola@virgilio.it

Telephone: +390172699365

Fax: +390172699364

Received: March 23, 2015

Revised: April 21, 2015

Accepted: April 26, 2015

Published online: August 10, 2015

ABSTRACT

AIM: 123-Iobenguane myocardial scintigraphy (MIBG), which identifies sympathetic nervous system dysfunction, has been shown to be an effective predictor of sudden cardiac mortality in patient with congestive heart failure (CHF) and could be a useful instrument to early identify adverse clinical events.

METHODS: patients with CHF, a New York Heart Association classification (NYHA) of II or III and a left ventricular ejection fraction (LVEF) $\leq 35\%$ were eligible for cardiac defibrillator (ICD) placement under current LVEF-based criteria in the guidelines. All patients listed for ICD underwent a MIBG before the implantation, in order to assess the prognostic value of an early cardiac MIBG to predict appropriate ICD indication.

RESULTS: 11 patients (100% males; age 65.1 ± 8.9 years) with mean LVEF $29.1 \pm 4.9\%$ entered the study. All patients had a coronary artery disease (CAD) treated by coronary artery bypass graft (CABG) in six cases, by a percutaneous coronary angioplasty (PTCA) in seven and both procedures in two patients. In all subjects the heart/mediastinum (H/M) ratio was calculated < 1.6 (mean 1.27 ± 0.13) and the mean

wash-out rate (WR) was $4.88 \pm 3.80\%$. The LVEF improved at follow-up from $29.1 \pm 4.9\%$ to $30.9 \pm 6.2\%$ and in three patients proved to be $> 35\%$. An ICD was implanted in six patients (54.5%). The sensitivity, specificity, positive and negative predictive value of an H/M ratio ≤ 1.25 at MIBG was calculated in 75%, 75%; 85.7%, 60%.

CONCLUSION: MIBG might be a promising method for excluding a 3-month left ventricular functional recovery.

© 2015 ACT. All rights reserved.

Key words: MIBG myocardial scintigraphy; Congestive heart failure

Testa M, Chauvie S, Biggi A, Terulla A, Feola M. Role of 123-Iobenguane Myocardial Scintigraphy in Predicting Short Term Left Ventricular Functional Recovery and Indication to ICD Implantation after Coronary Revascularization: A Work Hypothesis. *Journal of Cardiology and Therapy* 2015; 2(4): 371-376 Available from: URL: <http://www.ghrnet.org/index.php/jct/article/view/1317>

INTRODUCTION

An implantable cardioverter defibrillator (ICD) is effective in reducing mortality for ventricular arrhythmias in patients with chronic heart failure (CHF), a New York Heart Association classification (NYHA) of II or III and a left ventricular ejection fraction (LVEF) $\leq 35\%$ ^[1-2].

However, many devices never deliver electric therapy during their lifetime, whereas a lot of patients, ineligible for ICD placement under current LVEF-based criteria in the guidelines, die of sudden cardiac death (SCD)^[3].

Moreover, according to the current guidelines, a period of at least 3 months after a cardiac revascularization or optimization of medical therapy in CHF, or 40 days after a myocardial infarction should be waited before implanting an ICD and this "waiting period" could

be at high risk of major arrhythmic events^[4]. 123I-Iobenguane myocardial scintigraphy (MIBG), which identifies sympathetic nervous system dysfunction, has been shown to be an effective predictor of SCD mortality in patient with CHF and could be a useful instrument to early identify adverse clinical events^[5-7]. In this preliminary experience we followed eleven patients listed for ICD, who underwent an early MIBG scintigraphy (within one month after a cardiac revascularization or myocardial infarction) before the implantation, in order to assess the prognostic value of a cardiac MIBG in predicting appropriate ICD indications according to the left ventricular functional recovery.

METHODS

Eleven consecutive patients with New York Heart Association (NYHA) functional class II/III HF and left ventricular ejection fraction (LVEF) $\leq 35\%$ underwent MIBG scintigraphy one month after a cardiac revascularization or at least 15 days after a primary percutaneous coronary angioplasty (PTCA). All these patients received optimal pharmacologic therapy prior to be reviewed and listed for ICD devices as primary prevention, according to the current guidelines^[1-2]. These patients were then followed up three months later, in order to assess if there still were indications for an ICD implantation in primary prevention or if there had been any major arrhythmic events that needed ICD intervention. The indication for an ICD implantation has been considered according to the current guidelines based on NYHA functional class and LVEF. The SPECT result has been considered only in the determining of clinical prognosis.

MIBG scintigraphy variables evaluated were heart-to-mediastinum (H/M) ratio (computed for early and late imaging), cardiac washout rate (WR) and MIBG defect score according to the current recommendations^[8].

At forty-day and at three-month follow-up after the revascularization, a transthoracic echocardiography was performed to evaluate LV function. Echocardiograms were performed with a GE Vivid 7 Pro, according to the recommendations of the American Society of Echocardiography^[9]. Two-dimensional apical 2- and 4-chamber views were used for volume measurements; LVEF was calculated with a modified Simpson's method using biplane apical (2- and 4-chamber) views. Left ventricular systolic dysfunction was defined as an LVEF $<50\%$. All the echo examinations were performed by expert operators; the intra-observer variability was found to be $<5\%$. The medical therapy was normally assumed before the echocardiogram examination.

Any cardiac arrhythmic event requiring device therapy was registered in the implanted ICD patients using the devices' memory.

MIBG scintigraphy

180-230 MBq 123I-Iobenguane were injected (intravenous injection) at rest. Drugs that interfere with MIBG uptake were excluded. Cardiac medication was stopped 1 day prior to the investigation. 200 mg of Pertiroid were given orally 3 times day 1 day prior to the investigation and 2 days after investigation. Static planar acquisition of the thorax was performed at 15 minutes and 4 hours post-injection, with a 128x128 matrix size. At 3h30 min post-injection a single photon emission computed tomography (SPECT) was performed; projection images were acquired for 35 s at 3° increments over 180° circular orbits from 45° right anterior oblique to 45° left posterior oblique, matrix size 64x64. Just before SPECT, a CT images with the Hawkeye system (General Electric, Fairfield-Connecticut, USA) was

acquired for attenuation correction (2.5 mA, 129 s tot, 140 kV, 5 mm slice thickness, 256x256 matrix, 2.21 mm pixel size, helical, pitch 1.9, interval 4.42 mm). Images were acquired with a dual-head camera, Millenium VG for planar images, INFINIA Hawkeye tomo-CT for SPECT images (General Electric, Fairfield-Connecticut, USA) equipped with a high-resolution low-energy (LEHR) parallel-hole collimator. Energy discrimination was provided by a 20% window centred on the 159-keV photo peak of ¹²³I.

Two independent observers, unaware of the clinical status of patients, processed all planar images to measure cardiac MIBG uptake. Left ventricular activity was recorded using a manually drawn region of interest (ROI) over the whole left ventricular myocardium, and mean heart counts were calculated. A rectangular mediastinal ROI (50 pixels) was drawn in the upper mediastinum, and the mean counts calculated.

The H/M ratio was determined using the following formula:

$$H/M \text{ ratio} = [H]/[M]^{[10]}$$

where [H] = mean counts per pixel in the left ventricle, and [M] = mean counts per pixel in the upper mediastinum.

Myocardial washout was calculated using three different methods [11-12]:

$$[(\text{early } [H]/[M]) - (\text{delayed } [H]/[M])] / [(\text{early } [H]/[M]) * 100]$$

$$[(\text{early } [H]) - (1.21 * \text{delayed } [H])] / [(\text{early } [H]) * 100]$$

$$[(\text{early } [H] - [M]) - (1.21 * \text{delayed } [H] - [M])] / [(\text{early } [H] - [M]) * 100]$$

where 1.21 is 123I decay correction for 3h and 30min. SPECT images were processed using Myovation evolution software (General Electric, Fairfield-Connecticut, USA), that offers an iterative reconstruction algorithms with the ordered subsets expectation maximization (OSEM) resolution recovery (RR) method, in order to realize a combination of software and hardware to perform attenuation and collimator response compensation.

From SPECT images, the defect score was calculated by assessment of patient's segmental tracer uptake score using the 17-segment model^[12]. Each myocardial segment was scored according to the following tracer uptake scale:

- 0, normal tracer uptake;
- 1, mildly reduced tracer uptake;
- 2, moderately reduced tracer uptake;
- 3, severely reduced tracer uptake;
- 4, no tracer uptake;
- NA, not assessable.

To create a single aggregate SPECT SS, the average of individual reader scores was calculated, excluding SS values based on 17 segments (at least one segment scored NA).

In addition, aggregate SS results for each of the three coronary vascular territories were determined based on the seven segments assigned to the left anterior descending artery (LAD) and five each to the right coronary artery (RCA) and left circumflex (LCx) territories in the 17-segment model^[12]. Before the first MIBG SPECT reading session, all readers (2 blinded and independent observers) received training on the image display systems and the appearance of normal and abnormal MIBG planar and SPECT images, supplementing their prior experience in examining such studies. The training cases included approximately five MIBG SPECT studies on normal volunteers (derived from previous investigator-initiated studies) to provide the readers with an adequate basis for visual assessment of severity of abnormalities on study subject images. As a further element of the training, the readers were instructed that the unprocessed projection images should be used as a guide to the overall myocardial uptake of MIBG SPECT. This was done because, unlike for myocardial perfusion imaging (MPI) SPECT, where there

is usually at least one myocardial region with preserved uptake, MIBG imaging abnormalities can involve all wall segments. In such a circumstance, global uptake as judged on the projection images can be used as an aid for determining the score of the myocardial segment with the best uptake. In addition, the readers were advised to consider the relation of myocardial to background (eg, lung) activity on SPECT images as another means to assess for the presence of global reduction in myocardial MIBG uptake.

MPI scintigraphy

The subjects received an intravenous administration of 9,25 MBq/kg 99mTc-tetrofosmin (MYOVUE, GE Healthcare) at rest; drugs that interfere with MYOVUE uptake were excluded. Cardiac medication was stopped 1 day prior to the investigation.

ECG-gated SPECT imaging (16 frames) was started 60-180 minutes later. Imaging was performed using a dual-head camera INFINIA Hawkeye tomo-CT (General Electric, Fairfield-Connecticut, USA), low-energy, high-resolution collimators and a 20% energy window centered at the 140 keV photopeak of 99mTc. Projection images were acquired for 25 s at 3° increments over 180° circular orbits from 45° right anterior oblique to 45° left posterior oblique, matrix size 64×64.

Just before ECG-gated SPECT imaging, a static planar acquisition of the thorax (matrix size 64×64) were performed to evaluate extracardiac activity. Just before SPECT, a CT images with the Hawkeye system (General Electric, Fairfield-Connecticut, USA) was acquired for attenuation correction (2.5 mA, 129 s tot, 140 kV, 5 mm slice thickness, 256×256 matrix, 2.21 mm pixel size, helical, pitch 1.9, interval 4.42 mm).

SPECT images were processed using QGS/QPS software (General Electric, Fairfield-Connecticut, USA), that offers an iterative reconstruction algorithms with the ordered subsets expectation maximization (OSEM) method, to perform attenuation compensation. Two blinded readers (the same readers who interpreted the MIBG images) analyzed images using the same scoring system used as for the MIBG images, including the creation of a single aggregate SS. There was no association between the 99mTc-tetrofosmin and 123I-mIBG images for a given patient, because the different SPECT studies were presented in separate sessions (only one image type per session) and with random code identifiers. In addition to the aggregate 99mTc-tetrofosmin SS, the mismatch score for each subject was calculated as the difference between the late 123I-mIBG and 99mTc-tetrofosmin SS values. For consistency, the MIBG SS used in this calculation was the mean of the scores from the two readers who interpreted the 99mTc-tetrofosmin images.

Statistical Analysis

Continuous variables were expressed as mean±standard deviation (SD). Categorical variables (NYHA class) were analysed using the chi-square test or Fisher’s exact test. All probability values were two-tailed and differences were considered significant with a *p* value <0.05. The 7.5 version of the SPSS software for Windows, release 12.0, SPSS Inc. Chicago USA was used.

RESULTS

The population examined consisted of eleven patients with chronic ischemic heart failure with a NYHA classification of II or III and a LVEF less than or equal to 35% (mean LVEF 29.1±4.9%). The mean age of patients was 65.1±8.9 years, all of them were male and their mean NYHA class at admission was 2.4±0.7. Six patients

were smokers, five affected by dyslipidemia, seven suffered from hypertension and four of them had diabetes. All of them had coronary artery disease (CAD) treated by coronary artery bypass graft (CABG) in six cases, by a PTCA in seven and both procedures in two patients. The population baseline characteristics are given in Table 1 and each patient’s characteristics are briefly summarized below.

(1) T.G., male, aged 74, smoker suffered from hypertension, diabetes type II and had a myocardial infarction treated by CABG. Transthoracic echocardiogram showed a diffused hypokinesia (LVEF 30%) and MIBG scintigraphy demonstrated an early H/M ratio of 1.28, and a late H/M of 1.25 (normal threshold ≥1.60) with a calculated WR of 2.2%. He was evaluated three months later by a transthoracic echocardiogram which showed a stable LVEF 30%. Considering his dyspnoea as class NYHA II-III and LVEF at 3-month follow-up, T.G. was then ICD implanted for primary prevention.

(2) B.O., male, aged 76, suffered from hypertension and diabetes and underwent a CABG intervention. A month later, a MIBG scintigraphy found an early H/M ratio of 1.17, and a late H/M of 1.06 with a WR of 9.5 %; LVEF was 25%. The patient received an ICD according to the current guidelines for primary prevention as his LVEF at follow-up was 29% with a NYHA class II-III.

(3) G.B., male, aged 55, smoker suffered from hypertension and dyslipidemia. After a myocardial infarction treated with a PTCA, he had a hypokinetic heart disease (LVEF 35%) with NYHA class II-III. MIBG scintigraphy showed an early H/M ratio of 1.38, and a late H/M of 1.37 with a WR of 0.7 %. At the follow up visit 3-months later his LVEF improved (LVEF 40%) and there were no more indications for receiving an ICD in primary prevention.

(4) O.F., male, aged 78, suffered from hypertension, dyslipidemia and had a hypertensive cardiomyopathy evolved into a hypokinetic and dilated left ventricle (LVEF 30%) with a NYHA class of III although an optimal medical therapy for CHF. He had a single vessel disease (right coronary artery) treated with a PTCA+bare metal stenting. MIBG scintigraphy found an early H/M ratio of 1.36, a late H/M of 1.22 and a calculated WR of 8.9% (Figure 1). This case was collegially discussed and, considering that the presence of a single vessel disease (right coronary) detected at the angiography, difficultly might explain the hypokinetic evolution of the cardiopathy, we postulated the presence of a critical coronary lesion in a dilated cardiomyopathy. He early received an ICD/CRT and, a week after the device implantation, multiple episodes of monomorphic, fast,

Table 1 Population baseline characteristics.

	N = 11
Age	65.1±8.9 (48-78)
Males	11
Smoking habit	6
Diabetes	4
Hypertension	7
Dyslipidemia	5
NYHA class	2.4±0.7
H/M early	1.32±0.13
H/M late	1.27±0.13
WR [%]	4.88±3.80
LVEF baseline [%]	29.1±4.9 (20-35)
LVEF follow-up [%]	30.9±6.2 (20-40)
CABG	6
PTCA	7
CABG+PTCA	2
ICD	6

NYHA: New York Heart Association; CAD: Coronary Artery Disease; H/M: heart/mediastinum; WR: wash out rate; LVEF: left ventricular ejection fraction; CABG: coronary artery bypass graft; PTCA: percutaneous transluminal coronary angioplasty; ICD: implantable cardioverter defibrillator; CRT: Cardiac Resynchronisation Therapy.

non-sustained symptomatic ventricular tachycardia registered the necessity of ICD intervention in order to interrupt the cardiac arrhythmias (Figure 2). He was then evaluated 3-month later by a transthoracic echocardiogram which showed a stable LVEF of 30%.

(5) T.A., male, aged 68, mild smoker, suffered from dyslipidemia. He had a myocardial infarction treated with a percutaneous coronary intervention in a single-vessel disease. His transthoracic echocardiogram showed a severe and diffused hypokinesia (LVEF 25%) with a NYHA class II-III. MIBG scintigraphy demonstrated an early H/M ratio of 1.18, a late H/M of 1.15 with a WR of 2.5%. LVEF at the follow up did not improve (LVEF 28%), his NYHA class was worst (III-IV) and he was treated with high doses of loop diuretics. The patient underwent an ICD implantation which, at the follow up visit, had not jet delivered therapy.

(6) D.G., male, aged 62, suffered from hypertension and had a myocardial infarction treated with a percutaneous coronary intervention+drug eluting stent on anterior interventricular artery; a remaining critical stenosis of right coronary artery was considered for an elective treatment. A month later, on a follow-up transthoracic echocardiogram, a severe mitral regurgitation was found with a left ventricular aneurysmatic evolution and a moderate reduction of LVEF (35%) with a NYHA class of II-III. He, therefore, underwent a CABG intervention, a mitral valve repair and a ventricular aneurysmectomy. A month later a MIBG scintigraphy was performed (early H/M ratio of 1.18, late H/M of 1.12, WR of 4.8%). On his follow-up echocardiogram, three months later, LVEF improved (LVEF 40%).

(7) S.C., aged 63, male, smoker with diabetes type II, hypertension and dyslipidemia had a chronic coronary artery disease and a severe mitral regurgitation that required a CABG intervention and a mitral valve repair. His baseline echocardiogram showed a moderate reduction of LVEF (30%) and MIBG scintigraphy found an early H/M ratio of 1.33, a late H/M of 1.26 and a WR of 5.2%. At the follow-up visit his LVEF was not improved (LVEF 31%), his NYHA class II and an ICD implantation was suggested.

(8) P.L., aged 48, smoker, suffered from dyslipidemia. He had an acute myocardial infarction treated with a percutaneous coronary intervention+bare metal stenting on anterior interventricular artery. His baseline LVEF was 35% and MIBG scintigraphy found an early H/M ratio of 1.5, a late H/M of 1.42 and a WR of 10.7%. At follow-up visit three months later his LVEF improved (LVEF 38%).

(9) B.G., aged 62 without particular cardiovascular risk factors, underwent a CABG intervention+mitral valve repair after an acute myocardial infarction. His baseline transthoracic echocardiogram showed a diffused hypokinesia (LVEF 30%) with a NYHA class II-III. A MIBG scintigraphy was evaluated above nine months later (because of patient reasons) and showed an early H/M ratio of 1.51, and a late H/M of 1.47 with a WR of 2.65 %; in that occasion his transthoracic echocardiogram still showed a LVEF impairment (LVEF=29%). No decision about ICD implantation was taken and a month later, he was re-evaluated by a transthoracic echocardiogram showing an improvement of LVEF (45%).

(10) C.M., aged 63, smoker with diabetes type II, hypertension and dyslipidemia had an acute myocardial infarction treated with a percutaneous coronary intervention and bare metal stenting on anterior interventricular artery; a month later he underwent a CABG intervention+ventricular aneurysmectomy because of persisting of CAD symptoms with a left ventricular aneurysmatic evolution. His baseline LVEF was 20% and MIBG scintigraphy found an early H/M ratio of 1.26, a late H/M of 1.25 and a WR of 1%. At follow-up visit his LVEF did not improve (LVEF 20%), his NYHA class was worst (IV) and the patient underwent an ICD implantation.

(11) M.C., aged 65 without any particular cardiovascular risk factors, had an acute myocardial infarction treated with a PTCA on anterior interventricular artery. His baseline LVEF was 25% and MIBG scintigraphy found an early H/M ratio of 1.42, a late H/M of 1.36 and a WR of 4.23%. At follow-up visit his LVEF did not improve (LVEF 25%), his NYHA class was II-III and he underwent an ICD implantation (Table 2).

A perfusion/innervation study had been carried out finding these results: the mean MIBG summed score was 18.9 ± 11.9 whereas the mean myocardial perfusion imaging (MPI) score was 12.8 ± 11.3 . In two patients MIBG and MPI scores were normal, in other two cases MPI score was higher than MIBG score, whereas in six patients out of ten MIBG score proved to be higher than MPI score.

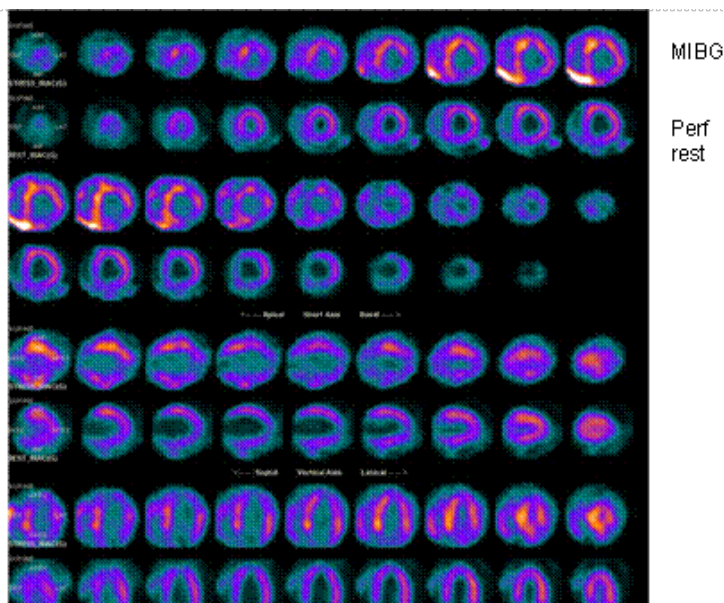


Figure 1 Comparison of Iobenguane and rest perfusion ^{99m}Tc tetrofosmin SPECT images in patient O.F.: a severe reduction of MIBG and TC-99 uptake in the apex emerged; the reduction of myocardial uptake of Iobenguane in the inferior wall appear to be more severe than perfusion, describing a denervation pattern after PTCA similar to images obtained in diabetic patients after revascularization.

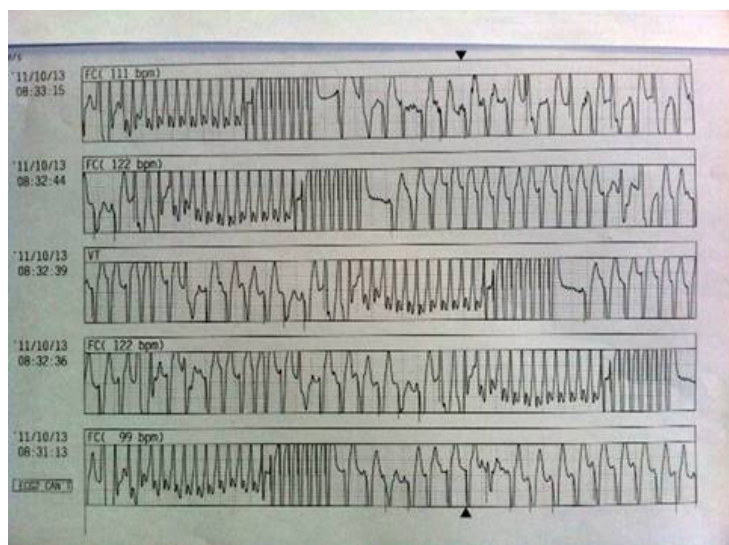


Figure 2 ECG trace from a telemetric registration of O.F. patient: repetitive non-sustained fast, monomorphic ventricular tachycardias interrupted by overdrives from ICD and followed by a PM Rhythm.

Table 2 Clinical features, MIBG imaging and LVEF evolution from baseline to 3-month follow-up in the population analysed.

	Age	Clinical feature	One-month LVEF	Three-months LVEF	Late H/M MIBG
Pt 1	74	CABG	30%	30%	1.25
Pt 2	76	CABG	25%	29%	1.06
Pt 3	55	PTCA	35%	40%	1.37
Pt 4	78	PTCA	30%	30%	1.22
Pt 5	68	PTCA	25%	28%	1.15
Pt 6	62	PTCA-CABG	35%	40%	1.12
Pt 7	63	CABG	30%	31%	1.26
Pt 8	48	PTCA	35%	38%	1.42
Pt 9	62	CABG	30%	45%	1.47
Pt 10	63	PTCA+CABG	20%	20%	1.25

CABG: coronary artery bypass graft; PTCA: percutaneous transluminal coronary angioplasty; LVEF: left ventricular ejection fraction; H/M: heart/mediastinum.

According to the MIBG results the sensitivity, specificity and negative predictive value of an H/M ratio ≤ 1.25 at MIBG was calculated in 75%, 75%, 85.7% and 60%. However, a summed MIBG score >26 seemed to obtain a worst performance in predicting the functional recovery (sensitivity 42.8%; specificity 75%; PPV 75% and NPV 42.8%).

DISCUSSION

Current American guidelines recommend ICD placement for primary prevention in patients with chronic heart failure, a NYHA functional class of II or III, a LVEF $\leq 35\%$ and at least 3 months after a cardiac revascularization or 40 days after an acute myocardial infarction^[1-2]. However, the support for these recommendations derived from the enrolment criteria of major ICD trials^[13]; in fact the existing scientific data do not clarify what the optimal ‘waiting period’ is after such events. This ‘waiting period’ can be at high risk of major arrhythmic events and an early evaluation and stratification could be important as well as finding a reliable instrument that may help the selection for ICD implantation. In fact, interesting data derived from the Wearable Cardioverter-Defibrillator (WCD) registry^[14] demonstrating as the 3-months mortality rate after revascularization in patients with LVEF $< 35\%$ was 7% after CABG and 10% after PTCA in non-WCD users. All these arrhythmic deaths occurred in the ‘waiting period’ in which cardiologists are limited in the decision about an ICD implantation in primary prevention. Moreover, it must be considered that only approximately one-third of patients, who die of sudden cardiac death, have LVEF that meets LVEF-based criteria for prophylactic ICD implantation^[3], whereas many patients, ineligible for ICD devices, die suddenly for SCD. Cardiac imaging MIBG scintigraphy can detect impaired global left ventricle sympathetic innervation and regional myocardial sympathetic heterogeneity, which are highly arrhythmogenic^[15-16] and could be a useful instrument into the decision process of ICD implantation.

In several recent studies imaging with MIBG has been shown to be an effective predictor of mortality, and specifically of SCD, in patients with heart failure^[5-7,17]. These studies underlined as the heart to mediastinum ratio (H/M) and the LVEF to be the only independent predictors of mortality considering especially an H/M ratio < 1.60 to be a significant predictor of major arrhythmic events. HF patients with reduced late H/M or increased (123)I-MIBG washout rate have a worse prognosis and an increased incidence of SCD as compared with patients with normal (123)I-MIBG uptake and washout parameters^[5-7]. In contrast, Boogers *et al* demonstrated as the late MIBG SPECT defect score seemed to be an independent

predictor of appropriate ICD therapy, whereas H/M ratio and WR were not^[18]. Recently, the ADMIRE-HF study demonstrated a relevant relationship between severity of myocardial sympathetic neuronal dysfunction and risk for subsequent cardiac death in patient with heart failure^[19]. Moreover, the ADMIRE-HF study had shown significant differences in the occurrence of arrhythmic events in those subjects with a H/M < 1.60 and a LVEF $< 30\%$ than in those in which LVEF $> 30\%$. Importantly, the two-year event rate was calculated 15% for patients with H/M ≥ 1.60 and 37% in those with H/M < 1.60 ^[19] and no cardiac death was experienced among CHF patients with LVEF between 30-35% and H/M ≥ 1.60 .

The results of our single-centre, observational preliminary study underlined as a very low H/M ratio (≤ 1.25) early after revascularization might predict an absence of improvement of functional left ventricular recovery (LVEF $> 35\%$) at 3-months follow-up (positive predictive value 85.7%). In our experience all patients have shown an important reduced MIBG uptake and normal washout parameters, revealing significant sympathetic innervation defects and an high risk for malignant arrhythmias. The prognostic role of WR results is still not completely clear, also according to the recent literature^[5-7,18-19], and further studies are needed to investigate this interest field.

Almost fifty-five percent of this study’s patients (54.5%) received ICD indication after the waiting period suggested by the current guidelines, having a LVEF $\leq 35\%$ and a NYHA functional class II-III. One of these patients was early implanted and this therapeutic choice seemed to be correct according to the appropriate device intervention few days after implantation. Moreover, in these patients an early MIBG scintigraphy had been predictive of the appropriate ICD indications for primary prevention after the ‘waiting period’ suggested by the guidelines. It also be considered that many therapeutic approaches used in CHF patients (as beta-blockers, spironolactone, valsartan and cardiac resynchronization therapy) could change the cardiac innervation quantified by MIBG scintigraphy^[20], indicating that MIBG imaging might clearly point out a favourable haemodynamic and clinical effect induced by pharmacological and non-pharmacological therapies.

As concern the perfusion/innervation study, we found a MIBG score higher than MPI score in 60% of patients and this confirmed previous studies^[21].

In conclusion, the role of sympathetic nerve imaging should be considered into the decision-making process for ICD placement in primary prevention in patients with left ventricular systolic dysfunction waiting after coronary revascularization^[22-25]. The challenge would be understanding which MIBG scintigraphy’s parameter is the most reliable and if this instrument could early predict the necessity of ICD implantation.

CONFLICT OF INTERESTS

There are no conflicts of interest with regard to the present study.

REFERENCES

- 1 Tracy CM, Epstein AE, Darbar D, *et al.* 2012 ACCF/AHA/HRS Focused Update of the 2008 Guidelines for Device-Based Therapy of Cardiac Rhythm Abnormalities: A Report of the American College of Cardiology Foundation/American Heart Association Task Force on Practice Guidelines. *J Am Coll Cardiol.* 2012 Oct 2;60(14):1297-313.
- 2 Epstein AE, DiMarco JP, Ellenbogen KA, *et al.* ACC/AHA/HRS 2008 guidelines for device-based therapy of cardiac rhythm ab-

- normalities: executive summary: a report of the American College of Cardiology/American Heart Association Task Force on Practice Guidelines (Writing Committee to Revise the ACC/AHA/NASPE 2002 Guideline Update for Implantation of Cardiac Pacemakers and Antiarrhythmia Devices). *J Am Coll Cardiol* 2008; 51:e1-e62.
- 3 Stecker EC, Vickers C, Waltz J, et al. Population-based analysis of sudden cardiac death with and without left ventricular systolic dysfunction. Two-year findings from the Oregon Sudden Unexpected Death Study. *J Am Coll Cardiol* 2006;47:1161–6.
 - 4 Steinbeck G, Andresen D, Seidl K, et al.; IRIS Investigators. Defibrillator implantation early after myocardial infarction. *N Engl J Med* 2009;361:1427–36.
 - 5 Agostini D, Verberne HJ, Burchert W, et al. I-123-mIBG myocardial imaging for assessment of risk for a major cardiac event in heart failure patients: insights from a retrospective European multicenter study. *Eur J Nucl Med Mol Imaging* 2008;35:535–46.
 - 6 Nagahara D, Nakata T, Hashimoto A, et al. Predicting the need for an implantable cardioverter defibrillator using cardiac metaiodobenzylguanidine activity together with plasma natriuretic peptide concentration or left ventricular function. *J Nucl Med* 2008;49:225–33.
 - 7 Arora R, Ferrick KJ, Nakata T, et al. I-123 MIBG imaging and heart rate variability analysis to predict the need for an implantable cardioverter defibrillator. *J Nucl Cardiol* 2003;10:121–31.
 - 8 Cerqueira MD, Weissman NJ, Dilsizian V, et al. Standardized myocardial segmentation and nomenclature for tomographic imaging of the heart: a statement for healthcare professionals from the Cardiac Imaging Committee of the Council on Clinical Cardiology of the American Heart Association. *Circulation* 2002;105:539–42
 - 9 Sahn DJ, Allen HD, George W, Mason M, Goldberg SJ. The utility of contrast echocardiographic techniques in the care of critically ill infants with cardiac and pulmonary disease. *Circulation* 1977; 56: 959–68.
 - 10 Guertner C, Klepzig H, Maul FD et al. Noradrenaline depletion in patients with coronary artery disease before and after percutaneous transluminal coronary angioplasty with iodine-123 metaiodobenzylguanidine and single-photon emission tomography. *Eur J Nucl Med* 1993; 20: 776–782
 - 11 Verberne H J, Sokole EB, van Moerkerken AF, Deeterink JHWM, Ensing G, Stabin GB, Somsen GA, van Eck-Smit BLF. Clinical performance and radiation dosimetry of no-carrier-added vs carrier-added 123I-metaiodobenzylguanidine (MIBG) for the assessment of cardiac sympathetic nerve activity. *Eur J Nucl Med Mol Imaging* 2008; 35: 798–807
 - 12 Flotats A, Carriò I, Agostini D, Le Guludec D, Marcassa C, Schaffers M, Somsen Ma, Unlu M, Verberne HJ. Proposal for standardization of 123I-metaiodobenzylguanidine (MIBG) cardiac sympathetic imaging by the EANM Cardiovascular Committee and the European Council of Nuclear Cardiology. *Eur J Nucl med Mol Imaging* 2010; 37: 1802–12
 - 13 Kedia R, Saeed M. Implantable cardioverter-defibrillators. Indications and unresolved issues. *Tex Heart Inst J* 2012; 39: 335–41
 - 14 Zishiri ET, Williams S, Cronin EM et al. Early risk of mortality after coronary revascularization in patients with left ventricular dysfunction and potential role of the wearable cardioverter defibrillator. *Circ Arrhythm Electrophysiol* 2013; 6: 117
 - 15 Wichter T, Hindricks G, Lerch H, et al. Regional myocardial sympathetic dysinnervation in arrhythmogenic right ventricular cardiomyopathy. An analysis using 123I-meta-iodobenzylguanidine scintigraphy. *Circulation* 1994;89:667–83.
 - 16 Merlet P, Benvenuti C, Moyses D, et al. Prognostic value of MIBG imaging in idiopathic dilated cardiomyopathy. *J Nucl Med* 1999;40:917–23.
 - 17 Tamaki S, Yamada T, Okuyama Y, et al. Cardiac iodine-123 metaiodobenzylguanidine imaging predicts sudden cardiac death independently of left ventricular ejection fraction in patients with chronic heart failure and left ventricular systolic dysfunction. *J Am Coll Cardiol* 2009;53:426–35.
 - 18 Boogers MJ, Borleffs CJ, Henneman MM, et al. Cardiac sympathetic denervation assessed with 123-iodine metaiodobenzylguanidine imaging predicts ventricular arrhythmias in implantable cardioverter-defibrillator patients. *J Am Coll Cardiol* 2010;15:2769e77.
 - 19 Jacobson AF, Senior R, Cerqueira MD, et al. Myocardial Iodine-123 Meta-iodobenzylguanidine Imaging and Cardiac Events in Heart Failure. Results of the Prospective ADMIRE-HF (AdreView Myocardial Imaging for Risk Evaluation in Heart Failure) Study. *J Am Coll Cardiol* 2010; 55: 2212–21
 - 20 Perrone-Filardi P, Paolillo S, Dellegrottaglie S et al. Assessment of cardiac sympathetic activity by MIBG imaging in patients with heart failure: a clinical appraisal. *Heart* 2011; 97: 1828–33
 - 21 Todiere G, Marzilli M. Role of cardiac imaging in heart failure. *Minerva Cardioangiol.* 2012 Aug;60(4):347–62.
 - 22 Currie GM, Iqbal B, Wheat JM, et al. Risk Stratification in Heart Failure Using 123I-MIBG. *J Nucl Med Technol.* 2011 Dec;39(4):295–301.
 - 23 Savarese G, Losco T, Parente A, et al. Clinical applications of MIBG SPECT in chronic heart failure. *G Ital Cardiol (Rome).* 2012 Feb;13(2):91–7.
 - 24 Marshall A, Cheetham A, George RS, et al. Cardiac iodine-123 metaiodobenzylguanidine imaging predicts ventricular arrhythmia in heart failure patients receiving an implantable cardioverter-defibrillator for primary prevention. *Heart.* 2012 Sep;98(18):1359–65.
 - 25 Ketchum ES, Jacobson AF, Caldwell JH, Senior R, Cerqueira MD, Thomas GS, Agostini D, Narula J, Levy WC. Selective improvement in Seattle Heart Failure Model risk stratification using iodine-123 meta-iodobenzylguanidine imaging. *J Nucl Cardiol.* 2012 ; 19(5): 1007–16

Peer reviewers: Kee-Lung Chang, Professor, Department of Biochemistry, Faculty of Medicine, College of Medicine, Kaohsiung Medical University, No.100 Shih-Chuan 1st Rd., Kaohsiung 80708, Taiwan; Elisabete Martins, MD, PhD, Department of Medicine, Oporto Medical School, Cardiology Department, São João University Hospital, Porto, Portugal.