

Giant Left Ventricular Pseudoaneurysm after Acute Myocardial Infarction Secondary to Cocaine Use

Alexandre de Matos Soeiro, Felipe Lourenço Fernandes, Maria Cardoso Guerreiro, Thiago Marques Mendes, Maria Carolina Feres de Almeida Soeiro, Tatiana de Carvalho Andreucci Torres Leal, Débora Yuri Moura Nakamura, Fábio Antônio Gaiotto, Múcio Tavares Oliveira Jr.

Alexandre de Matos Soeiro, Felipe Lourenço Fernandes, Maria Cardoso Guerreiro, Thiago Marques Mendes, Maria Carolina Feres de Almeida Soeiro, Tatiana de Carvalho Andreucci Torres Leal, Débora Yuri Moura Nakamura, Fábio Antônio Gaiotto, Múcio Tavares Oliveira Jr., Emergency Care Unit, Heart Institute (InCor), University of São Paulo, Brazil

Correspondence to: Alexandre de Matos Soeiro, Av. Dr. Eneas de Carvalho Aguiar, 44, Cep 05403-900, Cerqueira César, São Paulo, Brazil.

Email: alexandre.soeiro@bol.com.br

Telephone: +55-11-99913-4377

Received: April 9, 2015

Revised: June 1, 2015

Accepted: June 4, 2015

Published online: August 10, 2015

385 Available from: URL: <http://www.ghrnet.org/index.php/jct/article/view/1319>

INTRODUCTION

The recreational usage of cocaine dates from the beginning of the 19th century and nowadays is the second illegal drug used in Europe, behind only of cannabis. Its regular use has been associated with cardiovascular, neurological and mental health problems, and with an elevated risk of accident and dependence^[1-2].

This case report aimed to describe a younger Brazilian patient with myocardial dysfunction and giant left ventricular pseudoaneurysm secondary to the usage of cocaine and previous myocardial infarction who were treated surgically.

ABSTRACT

The patient is a 19-year-old male that reported a 7-year history of regular cocaine presenting at this moment with dyspnea after moderate exertion, orthopnea and paroxysmal nocturnal dyspnea for 30 days. The echocardiogram and the cardiac magnetic resonance imaging showed a giant left ventricle pseudoaneurysm secondary to the usage of cocaine and previous myocardial infarction. The combination of these situations made this patient a unique case. We showed that the surgical treatment may be an option.

© 2015 ACT. All rights reserved.

Key words: Acute coronary syndromes; Aneurysm; Cocaine

de Matos Soeiro A, Fernandes FL, Guerreiro MC, Mendes TM, de Almeida Soeiro MCF, de Carvalho Andreucci Torres Leal T, Nakamura DYM, Gaiotto FA, Jr MTO. Giant Left Ventricular Pseudoaneurysm after Acute Myocardial Infarction Secondary to Cocaine Use. *Journal of Cardiology and Therapy* 2015; 2(4): 383-

CASE REPORT

A 19-year-old-man was admitted to the Emergency Department because of dyspnea, orthopnea and paroxysmal nocturnal dyspnea for 30 days. The patient has not past medical problems. He reported a 7-year history of chronic and regular cocaine use (last use seven days ago). Physical examination revealed blood pressure of 120 × 80 mmHg, heart rate of 103 beats per minute, with rhythmic and normophonic sounds, regurgitant systolic murmur + 2/+ 6 in the mitral area, with bilateral crackles in the lung bases. Electrocardiogram showing sinus tachycardia with left bundle branch block and thorax X-ray has signs of pulmonary congestion, right pulmonary effusion and cardiomegaly. Performed transthoracic echocardiogram that showed apical aneurysm of the left ventricle (LV) and the anterior wall. Significant mitral regurgitation was demonstrated additionally. Coronary angiography with total occlusion in the middle third of the anterior descending artery and extensive aneurysm in apical and anterior region of the LV. Conducted cardiac magnetic resonance imaging (MRI) showed LV systolic dysfunction with LV ejection fraction of 14%, prior myocardial infarction in

extensive anterior wall, middle and apical segments (Figure 1). In addition, it became clear a giant pseudoaneurysm in anterior, anteroseptal and apical region of the left ventricle (end-systolic volume of 596 mL, end diastolic volume of 695 mL), with thrombus inside. The apical aneurysm also had thrombus adhered to your wall. The patient was submitted by a surgical approach with median sternotomy. Cardiopulmonary bypass was installed thru the cannulation of the aorta and the cava-atrial drainage. The dissection and exposure of the pseudoaneurysm was completed after aortic clamping, in order to prevent embolization of clots presented in the left ventricle. After heart exposure, an anterior ventriculotomy was performed on the fibrotic area, removing of great amount of clots. After cleaning the cavity, there were a good visualization of papillary muscle, septum and viable portions of inferior and lateral wall. Mitral valve repair was performed duplicating the mitral orifice with Alfieri technic, as show in figure 2. Left ventricular reconstruction was performed using bovine pericardium patch. The left ventricular geometry was preserved with suture of the retail by traction of septal, lateral and inferior wall towards ventricular apex. The retail was not covered with fibrotic cover (Figure 2).

The intraoperative trans esophageal echocardiography, observed LV ejection fraction of 35%, mild mitral insufficiency and bovine pericardial patch correctly positioned.

The postoperative evolution was satisfactory. The patient had progressive weaning of vasoactive drugs and was extubated on the third postoperative day. He was discharged on the ninth postoperative medicated for heart failure with beta-blocker, angiotensin converting enzyme inhibitors, diuretics and acetylsalicylic acid. New MRI performed before discharge showed an ejection fraction of 43% (Figure 1). In outpatient return on the 30th day after surgery, the patient was asymptomatic.

DISCUSSION

The patient we reported had symptoms of heart failure as first manifestation of the disease. He is a chronic dependent of cocaine and had no history of clinical myocardial infarction and no increase in myocardial biomarkers. There is only one case reported of a patient that had recreational use of cocaine with dilated cardiomyopathy without an increase in conventional cardiac markers of ischemia, but with pseudoaneurysm this is the first one.

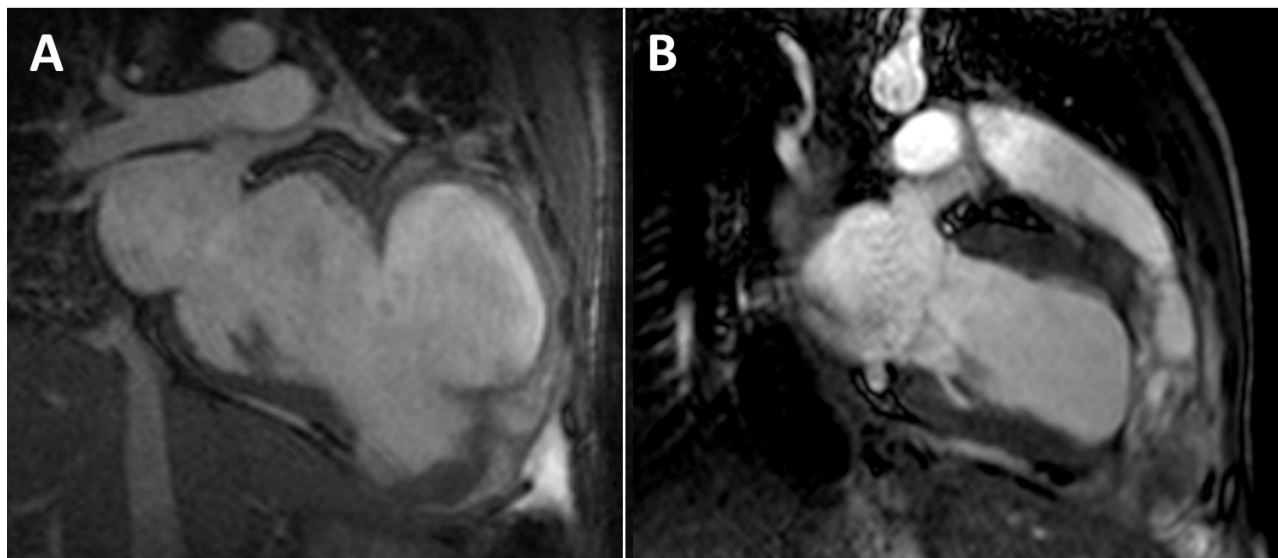


Figure 1 A: Pseudoaneurysm in anterior, anteroseptal and apical region of the left ventricle in MRI. B: Left ventricle after surgery with geometrical correction.

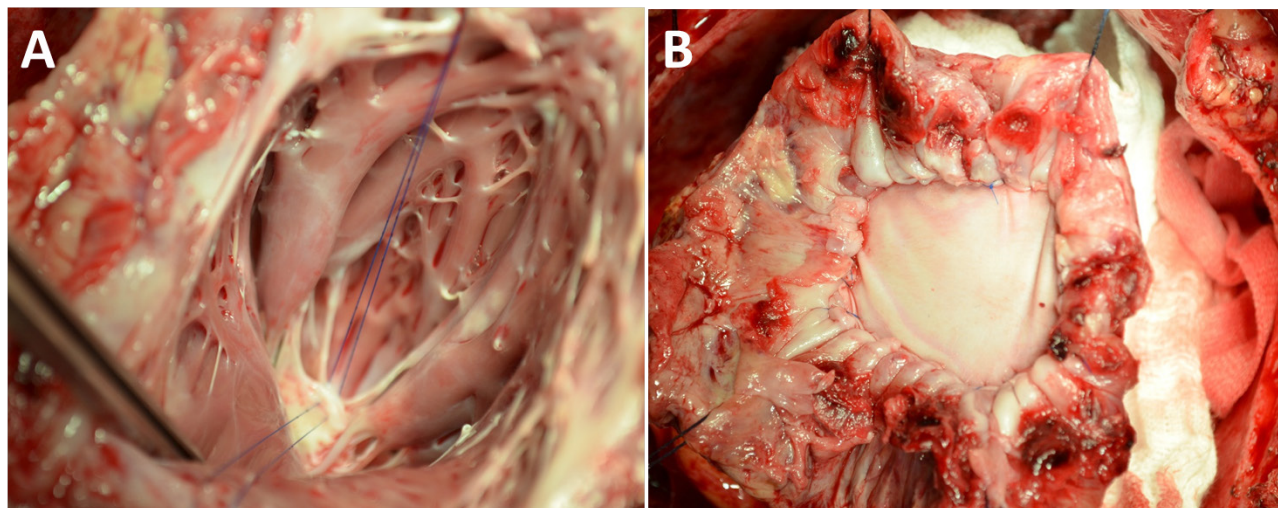


Figure 2 A: Mitral valve repair. B: Bovine pericardial patchnot recovered by fibrous cap fixed in septal, lateral and inferior walls.

Myocardial infarction or sudden cardiac death can occur in association with cocaine use. Most of time, the patient is admitted to a coronary unit with a history of chest pain during an acute coronary syndrome episode. Cocaine exposure within the last 72 hours or a positive urine test for cocaine is reported in 0.9% of all cases in the ACTION Registry^[3]. Patients with positive history of cocaine are more frequently associated with ST elevation myocardial infarction (STEMI) and cardiogenic shock at presentation, they are younger with fewer risk factors and multivessel coronary artery syndrome^[3-6].

In our case, the mechanism of the cardiomyopathy is due to ischemia, besides the patient had no history of previous infarction. The magnetic resonance of the heart showed a transmural infarction on the anterior wall in the presence of a giant pseudoaneurysm and the cinecoronarygraphy showed the middle portion of the left anterior descending artery occluded. We really believe that vasospasm was the major mechanism of myocardial infarction, as described in most of cases related to cocaine use.

On rare occasions, after an acute myocardial infarction, a rupture of the free wall can happen and be contained by pericardial and fibrous tissue, creating a left ventricular pseudoaneurysm. Two thirds of all left ventricular pseudoaneurysms occur after myocardial infarction^[5-7]. Thus, this wall is thin and may easily rupture and cause bleeding into the chest cavity and death. Surgery is considered the treatment of choice^[7,8], however it is frequently unsuccessful. Suturing into the necrotic myocardium may fail. The quoted surgical mortality is 23% and the best technique was not described. Medical therapy has higher mortality (30-45%)^[7]. The patient we described had a giant pseudoaneurysm with presence of thrombus inside and had an important mitral regurgitation, because of this, he was surgically treated.

Once the patient is clinically stabilized, psychiatric management and psychotherapy are highly recommended.

CONCLUSION

By our knowledge, this is the first case of patient with giant myocardial pseudoaneurysm due to chronic recreational use of cocaine treated successfully by surgery. We propose that cocaine abuse should be

considered in patients presenting with myocardial dysfunction and myocardial aneurysm and that the surgical treatment may be an option.

CONFLICT OF INTERESTS

There are no conflicts of interest with regard to the present study.

REFERENCES

- 1 Muscholl E. Effect of cocaine and Related drugs on the uptake of noradrenaline by Heart and Spleen. *Brit J Pharmacol.* 1961;16:352-9
- 2 Fanari Z, Kennedy KK, Lim MJ, Laddu AA, Stolker JM. Comparison of In-Hospital Outcomes for Beta-Blockers Use versus Non-Beta Blockers Use in Patients Presenting with Cocaine-Associated Chest Pain. *Am J Cardiol* 2014;113:1802-1806
- 3 Gupta N, Washam JB, PharmD, Mountantonakis SE, Li S, Roe MT, et al. Characteristics, Management, and Outcomes of cocaine-positive patients with acute coronary syndrome (from the National Cardiovascular Data Registry. *Am J Cardiol.* 2014;113:749-756
- 4 Missouri CG, Swift PA, Singer DRJ. Cocaine use and acute left ventricular dysfunction. *Lancet.* 2001;357:1586
- 5 Lange RA, Cigarroa RG, Flores ED, McBride W, Kim AS, Wells PJ, et al. Potentiation of cocaine-induced coronary vasoconstriction by beta-adrenergic blockade. *Ann Intern Med* 1990;113(12):897-903
- 6 McCord J, Jneid H, Hollander JE, de Lemos JA, Cercek B, Hsue P, et al. Management of cocaine-associated chest pain and myocardial infarction: a scientific statement from American Heart Association Acute Cardiac Care Committee of the Council on Clinical Cardiology. *Circulation* 2008;117:1897-1907
- 7 Frances C, Romero A, Grady D. Left ventricular pseudoaneurysm. *J Am CollCardiol.* 1998;32:557-61
- 8 Petrou E, Vartela V, Kostopoulou A, Georgiadou P, Mastorakou I, Kogerakis N, et al. Left ventricular pseudoaneurysm formation: Two cases and review of the literature. *World J Clin Cases.* 2014 Oct 16;2(10):581-6

Peer reviewer: Bo Xu, Department of Cardiology, St. Vincent's Hospital Melbourne, Victoria Parade, Fitzroy, VIC 3065, Australia.