

Safety and Efficacy of A Single Embolic Protection Device-Stent Combo for Carotid Revascularization

Arturo Giordano, Paolo Ferraro, Nicola Corcione, Stefano Messina, Gennaro Maresca, Gabriele Giordano, Rosario Mancusi, Raffaella Avellino, Mariangela Peruzzi, Giuseppe Biondi-Zoccai

Arturo Giordano, Paolo Ferraro, Nicola Corcione, Stefano Messina, Gennaro Maresca, Gabriele Giordano, Rosario Mancusi, Raffaella Avellino, Unità Operativa di Interventistica Cardiovascolare, Presidio Ospedaliero Pineta Grande, Castel Volturno, and Unità Operativa di Emodinamica, Casa di Salute Santa Lucia, San Giuseppe Vesuviano, Italy

Mariangela Peruzzi, Giuseppe Biondi-Zoccai, Department of Medico-Surgical Sciences and Biotechnologies, Sapienza University of Rome, Latina, Italy (MP, GBZ)

Giuseppe Biondi-Zoccai, Department of AngioCardioNeurology, IRCCS Neuromed, Pozzilli, Italy (GBZ)

Correspondence to: Giuseppe Biondi-Zoccai, Department of Medico-Surgical Sciences and Biotechnologies, Sapienza University of Rome, Corso della Repubblica 79, 04100 Latina, Italy.

Email: giuseppe.biondizoccai@uniroma1.it

Telephone: +3906302511

Fax: +390630811972

Received: March 6, 2016

Revised: April 28, 2016

Accepted: May 6, 2016

Published online: August 10, 2016

ABSTRACT

AIM: Carotid artery stenting (CAS) yields similar safety and efficacy results in comparison to carotid endarterectomy. There is however a plethora of devices for CAS, and selection remains problematic. We hypothesized that operators proficient with a single embolic protection device-stent combination can use it effectively for most CAS cases.

METHODS: We collected data on all patients undergoing CAS at our institutions, distinguishing patients undergoing revascularization with or without the Angioguard-Precise embolic protection-stent combo. The primary outcome was the risk of major adverse events (MAE), i.e. the composite of death, stroke, transient ischemic attack, or myocardial infarction.

RESULTS: A total of 532 patients were treated on 562 lesions. Angioguard-Precise could be used in 447 (84%) patients [471 (84%)

lesions], whereas other approaches were used in 85 (16%) patients [91 (16%) lesions]. The groups were similar for most characteristics, but prior carotid revascularization, brachial/radial access, common carotid target lesion, and predilation were less common in the single combo group, whereas stenting and use of embolic protection were less frequent in the other cases (all $p < 0.05$). Procedural success was achieved in 462 (98%) of cases in the combo group and 89 (98%) in the other group ($p=0.695$). No significant differences in MAE were found in-hospital [respectively 7 (2%) vs 0, $p = 0.604$], at 30 days [8 (1.7%) vs 1 (1.2%), $p = 1$], or at long-term [44 (10%) vs 11 (13%), $p = 0.294$].

CONCLUSIONS: Operators proficient with a specific embolic protection-stent combination can use it with favorable results in the vast majority of patients.

Key words: Carotid artery disease; Carotid artery stenting; Embolic protection; Stroke

© 2016 The Authors. Published by ACT Publishing Group Ltd.

Giordano A, Ferraro P, Corcione N, Messina S, Maresca G, Giordano G, Mancusi R, Avellino R, Peruzzi M, Biondi-Zoccai G. Safety and Efficacy of A Single Embolic Protection Device-Stent Combo for Carotid Revascularization. *Journal of Cardiology and Therapy* 2016; 3(4): 560-565 Available from: URL: <http://www.ghrnet.org/index.php/jct/article/view/1810>

INTRODUCTION

Surgical carotid endarterectomy (CEA) is beneficial in patients with significant carotid artery stenosis, especially when associated with symptoms or signs of cerebral ischemia. Carotid artery stenting (CAS) has recently emerged as a suitable alternative to surgery, especially in patients at high risk of peri-procedural myocardial infarction, given its lower invasiveness^[1-3]. There is however mounting debate on its comparative effectiveness and safety, especially in light of the fact that the risk of stroke appears higher after CAS than CEA^[4].

The dominating paradigm for CAS is that the choice of technique and device is paramount to maximize the safety and efficacy of CAS, with some techniques and devices potentially better than others in specific lesion or patient subsets^[1,5]. This may lead indeed to better outcomes if the best device is used appropriately and expertly, but may also be followed by unfavorable results if the plethora of devices and techniques is not faced properly and instead overwhelms the operator training and experience^[1,5].

Since the beginning of our percutaneous carotid revascularization program, we have chosen in our practice not to dilute our experience and skill among the many available devices for CAS, and instead have relied on a single embolic protection-dedicated stent system as routine approach for all our CAS procedures, leaving other approaches only as bailout in every selected case. This is based on the premise that safe and efficient use of a single embolic protection-stent combo may be at least as safe and effective than adopting a plethora of different devices and techniques for CAS.

We hereby report our experience with this approach spanning several years of practice and several hundreds of cases to inform the scholarly community on the risk-benefit profile of this strategy.

METHODS

This was a retrospective study stemming from our institutional database. All patients provided written informed consent. The competent ethics committees were notified of the study in keeping with national regulations.

We identified from Cardioplanet (Ebit, Genova, Italy) all patients undergoing percutaneous transluminal angioplasty (PTA) with or without stenting in the common or internal carotid artery at the two institutions where our interventional team operates. No exclusion criterion was enforced. All patients underwent preliminary carotid angiography followed by PTA or CAS as appropriate. Specifically, subjects without prior stroke or transient ischemic attack (TIA) were treated if showing a diameter stenosis > 60%, whereas symptomatic patients were treated if showing a diameter stenosis > 50% and one or more high risk features for surgery^[6-7].

While choice of technique and device were theoretically at the operator's discretion, since inception of our CAS program, in our team we chose to mainly rely on a single embolic protection device-stent combination as default strategy for all are suitable cases, namely the Angioguard-Precise combination (Cordis, Miami, FL, USA). This was based on the ease of use of these devices and the wealth of supportive data^[2]. Whenever use of the Angioguard could not be envisioned, we did not use embolic protection device at all (e.g. in case of very tortuous distal vessels or subocclusive stenoses). Accordingly, when the lesion was not suitable for Precise implantation (e.g. in case of in-stent restenosis or when the reference vessel diameter was too large), we used balloon-only angioplasty or employed other types of stents^[8-9]. All devices were used according to their instructions for use, unless in bailout conditions.

Carotid revascularization was typically performed using as default approach site the right femoral artery, because of vessel size and operator comfort. Other approaches were chosen when use of such site was not feasible. Then, after diagnostic angiography, a 7 French 11 cm sheath was exchanged (Cordis) and a 7 French JR4 guiding catheter was deployed tracking over an AmplatzSuperstiff 0.035" guidewire (St. Jude Medical, Minneapolis, MN, USA) previously deployed in the common carotid artery. Through the guiding catheter, the Angioguard was deployed and used, sparingly and only when deemed appropriate, for predilation with an undersized balloon

(typically 3.0 × 20 mm). Specifically, predilation was used in case of tight lesions which could not be crossed by the filter directly, or by the stent. The Precise stent was then deployed, and always postdiluted with a slightly undersized balloon (typically 5.0 × 30 mm).

Antithrombotic therapy encompassed unfractionated heparin (70 IU/kg) plus further boluses depending on procedure duration and provisional tirofiban IV bolus (at a dose ¼ to ½ of the one approved for percutaneous coronary intervention) in case of complex patient or lesion features^[10-11]. Antiplatelet therapy consisted in aspirin and a thienopyridine for at least 3 days before the procedure, with clopidogrel 300 mg front-loading in those not pre-treated. After PTA or CAS, all patients were prescribed aspirin 100 mg qd and clopidogrel 75 mg qd for at least 1 month.

The primary outcome of interest of this work was the composite of death, myocardial infarction (MI), stroke or TIA. Other outcomes included the individual components of the composite endpoint, the composite of death, myocardial infarction, or stroke, the composite of death or stroke, hospital stay, and repeat revascularization. All outcomes were adjudicated in-hospital and at long-term. Diagnosis of TIA or stroke was based on clinical symptoms or signs suggestive of neurologic disease, with imaging such as computed tomography or magnetic resonance imaging performed only if clinically indicated. Patients were followed by ambulatory visits and phone interviews, every 3-6 months.

Continuous variables are reported as mean and categorical variables as n (%). Continuous variables were compared with unpaired Student t test and categorical variables with Fisher exact test. Sensitivity analysis was performed with non-parsimonious propensity score matching using the Stata teffects ps match command, using as covariates age, female gender, hypertension, diabetes, dyslipidemia, smoking, obesity, prior MI, prior percutaneous coronary intervention, prior coronary artery bypass grafting, ejection fraction, heart failure, renal failure, prior TIA, prior stroke, prior carotid revascularization, access site, access side, lesion site, lesion side, baseline diameter stenosis, lesion length, and calcification, relying on a 0.001 propensity score caliper for 1:1 matching^[12]. Statistical significance was set at the 2-tailed 0.05 level, with p values unadjusted for multiplicity reported throughout. Computations were performed with Stata 13 (Stata Corp, College Station, TX, USA).

RESULTS

A total of 532 patients underwent carotid revascularizations on 562 carotid lesions (Table 1). The Angioguard-Precise combo was used in 447 (84%) patients [471 (84%) lesions], whereas other approaches were used in 85 (16%) patients [91 (16%) lesions]. Comparison of the Angioguard-Precise combo group versus the group with other strategies showed that the two were largely similar for baseline features, including age, prevalence of atherosclerotic risk factors, and neurologic symptoms. However, a lower prevalence of prior carotid revascularization was found in the Angioguard-Precise combo group [3 (0.7%) vs 15 (17.7%) in the other approaches group, $p < 0.001$].

Table 2 provides lesion and procedural details. Specifically, significant differences in lesion and procedural features included a lower prevalence of brachial or radial access for the Angioguard-Precise combo [5 (1.1%) vs 4 (4.4%), $p = 0.042$], of common carotid artery target lesions [7 (1.5%) vs 8 (8.8%), $p = 0.001$], and a lower prevalence of prior ipsilateral PTA or CEA [3 (0.6%) vs 15 (16.5%), $p < 0.001$]. Conversely, other lesion features were similar in the two groups, including baseline diameter stenosis, lesion length, and extent of calcification.

Predilation was required less often in the Angioguard-Precise group [53 (11.3%) vs 31 (34.1%), $p < 0.001$], whereas stents were used more commonly and extensively in the Angioguard-Precise group (total stent length 37.3 ± 5.7 mm vs 35.8 ± 6.2 mm, $p = 0.020$), but minimum stent diameter was not significantly different. As expected, embolic protection devices were used in only 5 (5.5%) of cases not belonging to the Angioguard-Precise combo group, whereas balloon-expandable stents were required only in 3 (3.3%) cases. Despite these differences, final diameter stenosis and procedural success rate were similarly favorable in the two groups [respectively $1.2 \pm 0.5\%$ vs $1.2 \pm 0.6\%$, $p = 0.998$, and 462 (98.1%) vs 89 (97.8%), $p = 0.695$].

Clinical outcomes were also similar in the two groups, with the in-hospital composite of death, MI, stroke or TIA occurring in 7 (1.6%) patients in the Angioguard-Precise combo group versus 0 in the other approaches group ($p = 0.604$) (Table 3). Similar results in the two groups were also obtained for individual in-hospital rates of death, MI, stroke, TIA, the composite of death, myocardial infarction, or stroke, the composite of death or stroke, and total hospital stay. These findings were confirmed at 1-month follow-up. Long-term follow-up, after 19.3 ± 20.8 months, also showed similar results for the

Angioguard-Precise combo and the other approaches group in terms of death, MI, stroke, TIA, or their composite, as well as for the risk of repeat carotid revascularization, which was required in only 1 patient per group (0.2% vs 1.2%, $p = 0.249$).

Sensitivity analysis based on propensity score also showed that the Angioguard-Precise combination was associated with a similar long-term rate of death, MI, stroke or TIA even at adjusted analysis [odds ratio=0.98 (0.91-1.06), $p = 0.668$].

DISCUSSION

Our findings, stemming from a consistent series of real-world patients undergoing carotid revascularization, support the routine use of an embolic protection-stent combination such as the Angioguard-Precise for most percutaneous carotid revascularization procedures. Rather than simply implying that an expert operator can safely and effectively use a single embolic protection-stent combination, we believe our results may suggest that operators proficient with a specific embolic protection-stent combination can use it with favorable results in most of their carotid revascularization cases.

Table 1 Baseline characteristics.

Characteristics	Angioguard-Precise combo (N=447)	Other approaches (N=85)	Total (N=532)	P value
Age (years)	70.7±8.5	70.9±9.4	70.8±8.6	0.834
Obesity	51 (11.4%)	9 (10.6%)	60 (11.3%)	1
Hypertension	384 (85.9%)	74 (87.1%)	458 (86.1%)	0.866
Dyslipidemia	208 (46.5%)	38 (44.7%)	246 (46.2%)	0.813
Diabetes				0.124
No	262 (58.6%)	60 (70.6%)	322 (60.5%)	
Non-insulin-dependent	132 (29.5%)	19 (22.4%)	151 (28.4%)	
Insulin-dependent	53 (11.9%)	6 (7.1%)	59 (11.1%)	
Smoking status				0.839
Never	310 (69.4%)	61 (71.8%)	371 (69.7%)	
Former	65 (14.5%)	10 (11.8%)	75 (14.1%)	
Current	72 (16.1%)	14 (16.5%)	86 (16.2%)	
Prior stroke or transient ischemic attack (TIA)	61 (13.7%)	12 (14.1%)	73 (13.7%)	0.865
Prior carotid revascularization	3 (0.7%)	15 (17.7%)	18 (3.4%)	<0.001
Prior myocardial infarction	76 (17.0%)	13 (15.3%)	76 (17.0%)	0.874
Prior percutaneous coronary intervention	117 (26.2%)	22 (25.9%)	139 (26.1%)	1
Prior coronary artery bypass grafting	57 (12.8%)	12 (14.1%)	69 (13.0%)	0.726
Symptomatic heart failure	4 (0.9%)	1 (1.2%)	5 (0.9%)	0.583
Left ventricular ejection fraction (%)	49.5±2.9	49.2±4.2	49.5±2.9	0.329
Renal failure	50 (11.2%)	8 (9.4%)	58 (10.9%)	0.708

Table 2 Lesion and procedural features.

Features	Angioguard-Precise combo (N=471)	Other approaches (N=91)	Total (N=562)	P value
Brachial or radial access	5 (1.1%)	4 (4.4%)	9 (1.6%)	0.042
Lesion site				0.001
Common carotid artery	7 (1.5%)	8 (8.8%)	15 (2.7%)	
Internal carotid artery	464 (98.5%)	83 (91.2%)	547 (97.3%)	
Lesion side				0.732
Right	238 (50.5%)	44 (48.4%)	282 (50.2%)	
Left	233 (49.5%)	47 (51.7%)	280 (49.8%)	
Prior ipsilateral carotid revascularization	3 (0.6%)	15 (16.5%)	18 (3.2%)	<0.001
Moderate or severe calcification	49 (10.4%)	11 (12.1%)	60 (10.7%)	0.583
Baseline diameter stenosis (%)	80.5±8.5	82.2±12.3	80.8±12.3	0.123
Lesion length (mm)	23.9±6.7	23.4±7.5	23.8±6.9	0.501
Predilation	53 (11.3%)	31 (34.1%)	84 (15.0%)	<0.001
Stents implanted				0.001
None	0	4 (4.4%)	4 (0.7%)	
One	466 (98.9%)	87 (95.6%)	553 (98.4%)	
Two	5 (1.1%)	0	5 (0.9%)	
Minimum stent diameter (mm)	7.0±0.6	6.9±0.8	7.0±0.7	0.074
Total stent length (mm)	37.3±5.7	35.8±6.2	37.1±5.8	0.020
Embolic protection device	471 (100%)	5 (5.5%)	476 (84.7%)	<0.001
Balloon-expandable stent	0	3 (3.3%)	3 (0.5%)	0.004
Final diameter stenosis (%)	1.2±0.5	1.2±0.6	1.2±0.6	0.998
Procedural success	462 (98.1%)	89 (97.8%)	551 (98.0%)	0.695

Carotid artery disease is a relatively common cause of neurologic disability^[1,5]. Surgical CEA has been showed in several seminal trials beneficial in selected symptomatic and asymptomatic patients with significant carotid stenosis^[13]. Due to its relative invasiveness, other approaches for carotid revascularization have been sought. Carotid angioplasty and stenting have been revolutionized by the development of embolic protection devices^[2], which have clearly proved beneficial to minimize thromboembolic complications occurring during angioplasty of lesions at high risk^[14]. Indeed, in the seminal trial by Yadav *et al* comparing CEA versus CAS with Angioguard and Precise in patients at high surgical risk, CAS prove at least equivalent in safety and effectiveness to surgery, with similarly favorable results subsequently reported in other trials, among others (Table 4; Figure 1)^[2-3,15-20].

Yet, over the years a plethora of devices have been introduced into the interventionist's armamentarium, with ensuing uncertainty on which device is best in general or in specific patient subsets. The common paradigm is that no single device is better than the other, but that each device may have its pros and cons, and a specific niche where it has a particularly favorable risk-benefit balance^[1,5]. Another

important issue is the optimal choice of the embolic protection device. Proximal embolic protection devices have been particularly advocated in specific cases at higher risk of thromboembolic complications instead of distal protection devices such as the Angioguard device^[1,5,19].

Our study represents in our opinion a unique opportunity to reflect on the best approach to CAS. Given our ongoing strategy to use the Angioguard-Precise combo as default strategy for most of our cases, and the reassuringly favorable results obtained so far, notwithstanding the high prevalence of asymptomatic carotid disease, we may speculate on how to best choose and adopt a specific set of devices. Indeed, we were able to use a single embolic protection-stent combination in 84% of our 532 cases of carotid revascularization, reserving other approaches and devices to only a minority of patients and lesions. Yet, our choice in favor of the Angioguard-Precise combo does not imply that this is necessarily the best one. Other operators confident with other specific combos (e.g. Epifilter-Wallstent, Boston Scientific, Natick, MA, USA, just to name one among the many available ones) are likely to achieve similarly satisfactory results as those hereby reported with the

Table 3 Clinical outcomes.

Outcomes	Angioguard-Precise combo (N=447)	Other approaches (N=85)	Total (N=532)	P value
In-hospital follow-up				
Hospital stay (days)	2.0±1.2	2.0±1.0	2.0±1.2	0.766
Death	1 (0.2%)	0	1 (0.2%)	1
MI	0	0	0	1
Stroke	5 (1.1%)	0	5 (0.9%)	1
TIA	2 (0.5%)	0	2 (0.4%)	1
Death, MI, stroke or TIA	7 (1.6%)	0	7 (1.3%)	0.604
Death, MI, or stroke	6 (1.3%)	0	6 (1.1%)	0.596
Death or stroke	6 (1.3%)	0	6 (1.1%)	0.596
Cumulative 1-month follow-up				
Death	3 (0.7%)	1 (1.2%)	4 (0.8%)	0.503
MI	0	0	0	1
Stroke	5 (1.1%)	0	5 (0.9%)	1
TIA	2 (0.5%)	0	2 (0.4%)	1
Death, MI, stroke or TIA	10 (2.2%)	1 (1.2%)	11 (2.1%)	1
Death, MI, or stroke	8 (1.7%)	1 (1.2%)	9 (1.7%)	1
Death or stroke	8 (1.7%)	1 (1.2%)	9 (1.7%)	1
Cumulative follow-up				
Follow-up duration (months)	18.9±20.7	21.3±24.5	19.3±20.8	0.351
Death	31 (6.9%)	10 (11.8%)	41 (7.7%)	0.125
MI	17 (3.8%)	2 (2.4%)	17 (3.8%)	0.752
Stroke	15 (3.4%)	1 (1.2%)	16 (3.0%)	0.488
TIA	2 (0.5%)	1 (1.2%)	3 (0.6%)	0.407
Death, MI, stroke or TIA	44 (9.8%)	11 (12.9%)	55 (10.3%)	0.436
Death, MI, or stroke	44 (9.8%)	10 (11.8%)	54 (10.2%)	0.560
Death or stroke	43 (9.6%)	10 (11.8%)	53 (10.0%)	0.554
Repeat carotid revascularization	1 (0.2%)	1 (1.2%)	2 (0.4%)	0.294

MI: myocardial infarction; TIA: transient ischemic attack.

Table 4 Comparative 1-month results of key clinical trials on carotid stenting.

Study	SAPPHIRE	EVA-3S	SPACE	ICSS	CREST	EPIC	EMPIRE	PROTECT	Giordano et al
Year	2004	2006	2006	2010	2010	2010	2011	2012	2015
Patients with carotid PTA	167	261	599	853	1262	237	245	220	532
Age (years)	73	70	68	70	69	74	70	73	71
Symptomatic carotid disease	58%	100%	100%	100%	53%	20%	32%	13%	14%
Embolic protection	100%	92%	27%	72%	100%	100%	100%	100%	85%
Death	1.2%	1.2%	0.7%	2.3%	0.7%	0.4%	0.8%	0.5%	0.8%
Myocardial infarction (MI)	2.4%	0.8%	-	-	1.1%	0.8%	0.8%	0.5%	0
Stroke	3.6%	3.5%	7.5%	7.7%	4.1%	2.1%	2.9%	1.8%	0.9%
Death, MI, or stroke	4.8%	4.7%	-	8.5%	5.2%	3.0%	3.7%	2.3%	1.7%
Death or stroke	5.5%	3.9%	7.7%	8.5%	4.4%	2.5%	2.9%	1.8%	1.7%

CREST: Carotid Revascularization Endarterectomy Versus Stenting Trial; EMPIRE: Embolic Protection with Reverse Flow; EPIC: FiberNet Embolic Protection System in Carotid Artery Stenting Trial; EVA-3S: Endarterectomy Versus Angioplasty in Patients With Symptomatic Severe Carotid Stenosis; ICSS: International Carotid Stenting Study; PROTECT: Protected Carotid Artery Stenting in Patients at High Risk for Carotid Endarterectomy; PTA: percutaneous transluminal angioplasty; SAPPHIRE: Stenting and Angioplasty with Protection in Patients at High Risk for Endarterectomy; SPACE: Stent-Supported Percutaneous Angioplasty of the Carotid Artery versus Endarterectomy.

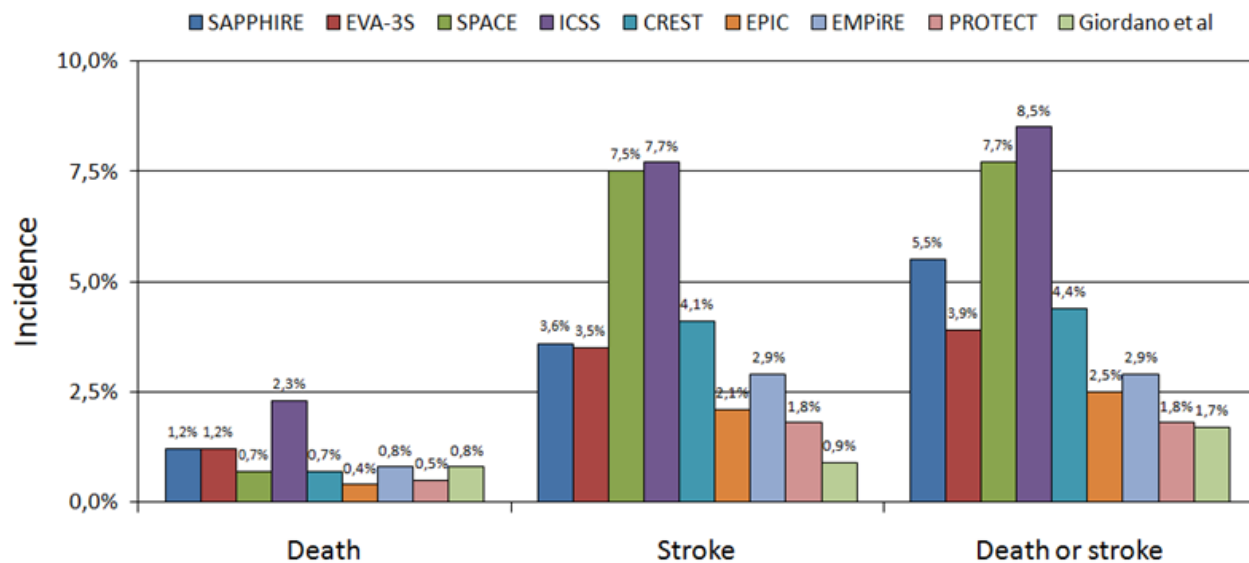


Figure 1 Comparative 1-month results of key clinical trials on carotid stenting. CREST: Carotid Revascularization Endarterectomy Versus Stenting Trial; EMPiRE: Embolic Protection with Reverse Flow; EPIC: FiberNet Embolic Protection System in Carotid Artery Stenting Trial; EVA-3S: Endarterectomy Versus Angioplasty in Patients With Symptomatic Severe Carotid Stenosis; ICSS: International Carotid Stenting Study; PROTECT: Protected Carotid Artery Stenting in Patients at High Risk for Carotid Endarterectomy; PTA: percutaneous transluminal angioplasty; SAPHIRE: Stenting and Angioplasty with Protection in Patients at High Risk for Endarterectomy; SPACE: Stent-Supported Percutaneous Angioplasty of the Carotid Artery versus Endarterectomy

Angioguard-Precise combination^[21]. Notably, prices of devices for carotid revascularization have plummeted recently, at least in Italy, making the choice of a single protection device-stent from the same vendor very appealing in terms of costs in comparison to less obvious combinations or vascular surgery.

This work has several limitations and should be regarded mainly as hypothesis generating, with the ensuing need for external confirmation from observational and, hopefully, randomized studies. In particular, this is a retrospective, observational and pragmatic study involving two centers with extensive experience in endovascular procedures. In addition, the administrative database registry design bears by definition the risk of selection, information, attrition, and adjudication bias, especially for small infarctions or strokes^[13]. Indeed, the main take home message of our study is not that the the AngioGuard-Precise combination is better than other devices or strategies. The main result is instead that a default strategy of routinely using the AngioGuard-Precise combination for most cases of carotid artery stenting, with other approaches reserved to unsuitable cases, is feasible, and seems associated with favorable clinical results in terms of safety and efficacy. Moreover, being this a non-randomized study, there are obvious differences between groups. For instance, the ‘other approaches’ group includes more restenotic cases, which are known to have a lower risk of complications. Accordingly, our routine combo approach seems feasible, safe and effective in most routine cases, reserving other approaches to selected patients and lesions. Finally, we did not extract in detail all medications data. However, all patients were pretreated with aspirin and loaded with clopidogrel as appropriate.

In conclusion, operators who are proficient with a specific embolic protection-stent combination can use it with favorable results in the vast majority of patients with an indication to percutaneous carotid revascularization.

CONFLICT OF INTERESTS

Dr. Biondi-Zoccai has consulted and lectured for several companies manufacturing endovascular devices.

REFERENCES

- White CJ. Carotid artery stenting. *J Am Coll Cardiol* 2014; **64**: 722-31.
- Yadav JS, Wholey MH, Kuntz RE, Fayad P, Katzen BT, Mishkel GJ, Bajwa TK, Whitlow P, Strickman NE, Jaff MR, Popma JJ, Snead DB, Cutlip DE, Firth BG, Ouriel K; Stenting and Angioplasty with Protection in Patients at High Risk for Endarterectomy Investigators. Protected carotid-artery stenting versus endarterectomy in high-risk patients. *N Engl J Med* 2004; **351**: 1493-501.
- Brott TG, Hobson RW 2nd, Howard G, Roubin GS, Clark WM, Brooks W, Mackey A, Hill MD, Leimgruber PP, Sheffett AJ, Howard VJ, Moore WS, Voeks JH, Hopkins LN, Cutlip DE, Cohen DJ, Popma JJ, Ferguson RD, Cohen SN, Blackshear JL, Silver FL, Mohr JP, Lal BK, Meschia JF; CREST Investigators. Stenting versus endarterectomy for treatment of carotid-artery stenosis. *N Engl J Med* 2010; **363**: 11-23.
- Bangalore S, Kumar S, Wetterslev J, Bavry AA, Gluud C, Cutlip DE, Bhatt DL. Carotid artery stenting vs carotid endarterectomy: meta-analysis and diversity-adjusted trial sequential analysis of randomized trials. *Arch Neurol* 2011; **68**: 172-84.
- White CJ. Carotid artery stent placement. *J Am Coll Cardiol Intv* 2010; **3**: 467-74.
- Kernan WN, Ovbiagele B, Black HR, Bravata DM, Chimowitz MI, Ezekowitz MD, Fang MC, Fisher M, Furie KL, Heck DV, Johnston SC, Kasner SE, Kittner SJ, Mitchell PH, Rich MW, Richardson D, Schwamm LH, Wilson JA; American Heart Association Stroke Council, Council on Cardiovascular and Stroke Nursing, Council on Clinical Cardiology, and Council on Peripheral Vascular Disease. Guidelines for the prevention of stroke in patients with stroke and transient ischemic attack: a guideline for healthcare professionals from the American Heart Association/American Stroke Association. *Stroke* 2014; **45**: 2160-236.
- Brott TG, Halperin JL, Abbara S, Bacharach JM, Barr JD, Bush RL, Cates CU, Creager MA, Fowler SB, Friday G, Hertzberg VS, McIlff EB, Moore WS, Panagos PD, Riles TS, Rosenwasser RH, Taylor AJ. 2011 ASA/ACCF/AHA/AANN/AANS/ACR/ASNR/CNS/SAIP/SCAI/SIR/SNIS/SVM/SVS guideline on the management of patients with extracranial carotid and vertebral artery disease: executive summary: a report of the American College of Cardiol-

- ogy Foundation/American Heart Association Task Force on Practice Guidelines, and the American Stroke Association, American Association of Neuroscience Nurses, American Association of Neurological Surgeons, American College of Radiology, American Society of Neuroradiology, Congress of Neurological Surgeons, Society of Atherosclerosis Imaging and Prevention, Society for Cardiovascular Angiography and Interventions, Society of Interventional Radiology, Society of NeuroInterventional Surgery, Society for Vascular Medicine, and Society for Vascular Surgery. *J Am Coll Cardiol* 2011; **57**: 1002-44.
- 8 Sangiorgi G, Romagnoli E, Biondi-Zoccai G. Commentary: drug-eluting balloons for carotid in-stent restenosis: can this technology deliver the goods? *J Endovasc Ther* 2012; **19**: 743-8.
 - 9 Ventoruzzo G, Biondi-Zoccai G, Bellandi G. Commentary: choose the appropriate access route in bovine arch and you will turn a complex left carotid artery stenting procedure into a simple one. *J Endovasc Ther* 2014; **21**: 137-9.
 - 10 Giordano A, D'Angelillo A, Romano S, D'Arrigo P, Corcione N, Bisogni R, Messina S, Polimeno M, Pepino P, Ferraro P, Romano MF. Tirofiban induces VEGF production and stimulates migration and proliferation of endothelial cells. *Vascul Pharmacol* 2014; **61**: 63-71.
 - 11 Valgimigli M, Biondi-Zoccai G, Tebaldi M, van't Hof AW, Campo G, Hamm C, ten Berg J, Bolognese L, Saia F, Danzi GB, Briguori C, Okmen E, King SB, Moliterno DJ, Topol EJ. Tirofiban as adjunctive therapy for acute coronary syndromes and percutaneous coronary intervention: a meta-analysis of randomized trials. *Eur Heart J* 2010; **31**: 35-49.
 - 12 Biondi-Zoccai G, Romagnoli E, Agostoni P, Capodanno D, Castagno D, D'Ascenzo F, Sangiorgi G, Modena MG. Are propensity scores really superior to standard multivariable analysis? *Contemp Clin Trials* 2011; **32**: 731-40.
 - 13 Rothwell PM, Slattery J, Warlow CPA. Systematic review of the risks of stroke and death due to endarterectomy for symptomatic carotid stenosis. *Stroke* 1996; **27**: 260-5.
 - 14 Baim DS, Wahr D, George B, Leon MB, Greenberg J, Cutlip DE, Kaya U, Popma JJ, Ho KK, Kuntz RE; Saphenous vein graft Angioplasty Free of Emboli Randomized (SAFER) Trial Investigators. Randomized trial of a distal embolic protection device during percutaneous intervention of saphenous vein aorto-coronary bypass grafts. *Circulation* 2002; **105**: 1285-90.
 - 15 Ringleb PA, Allenberg J, Brückmann H, Eckstein HH, Fraedrich G, Hartmann M, Hennerici M, Jansen O, Klein G, Kunze A, Marx P, Niederkorn K, Schmiedt W, Solymosi L, Stinge R, Zeumer H, Hacke W; SPACE Collaborative Group. 30 day results from the SPACE trial of stent-protected angioplasty versus carotid endarterectomy in symptomatic patients: a randomised non-inferiority trial. *Lancet* 2006; **368**: 1239-47.
 - 16 Mas JL, Chatellier G, Beyssens B, Branchereau A, Moulin T, Becquemin JP, Larrue V, Lièvre M, Leys D, Bonneville JF, Watelet J, Pruvo JP, Albucher JF, Viguier A, Piquet P, Garnier P, Viader F, Touzé E, Giroud M, Hosseini H, Pillet JC, Favrole P, Neau JP, Ducrocq X; EVA-3S Investigators. Endarterectomy versus stenting in patients with symptomatic severe carotid stenosis. *N Engl J Med* 2006; **355**: 1660-71.
 - 17 Ederle J, Dobson J, Featherstone RL, Bonati LH, van der Worp HB, de Borst GJ, Lo TH, Gaines P, Dormann PJ, Macdonald S, Lyrer PA, Hendriks JM, McCollum C, Nederkoorn PJ, Brown MM; International Carotid Stenting Study investigators. Carotid artery stenting compared with endarterectomy in patients with symptomatic carotid stenosis (International Carotid Stenting Study): an interim analysis of a randomised controlled trial. *Lancet* 2010; **375**: 985-97.
 - 18 Myla S, Bacharach JM, Ansel GM, Dippel EJ, McCormick DJ, Popma JJ. Carotid artery stenting in high surgical risk patients using the FiberNet embolic protection system: the EPIC trial results. *Catheter Cardiovasc Interv* 2010; **75**: 817-22.
 - 19 Clair DG, Hopkins LN, Mehta M, Kasirajan K, Schermerhorn M, Schönholz C, Kwolek CJ, Eskandari MK, Powell RJ, Ansel GM; EMPiRE Clinical Study Investigators. Neuroprotection during carotid artery stenting using the GORE flow reversal system: 30-day outcomes in the EMPiRE Clinical Study. *Catheter Cardiovasc Interv* 2011; **77**: 420-9.
 - 20 Matsumura JS, Gray W, Chaturvedi S, Yamanouchi D, Peng L, Verta P. Results of carotid artery stenting with distal embolic protection with improved systems: Protected Carotid Artery Stenting in Patients at High Risk for Carotid Endarterectomy (PROTECT) trial. *J Vasc Surg* 2012; **55**: 968-76.
 - 21 Hobson RW 2nd, Howard VJ, Roubin GS, Brott TG, Ferguson RD, Popma JJ, Graham DL, Howard G; CREST Investigators. Carotid artery stenting is associated with increased complications in octogenarians: 30-day stroke and death rates in the CREST lead-in phase. *J Vasc Surg* 2004; **40**: 1106-11.